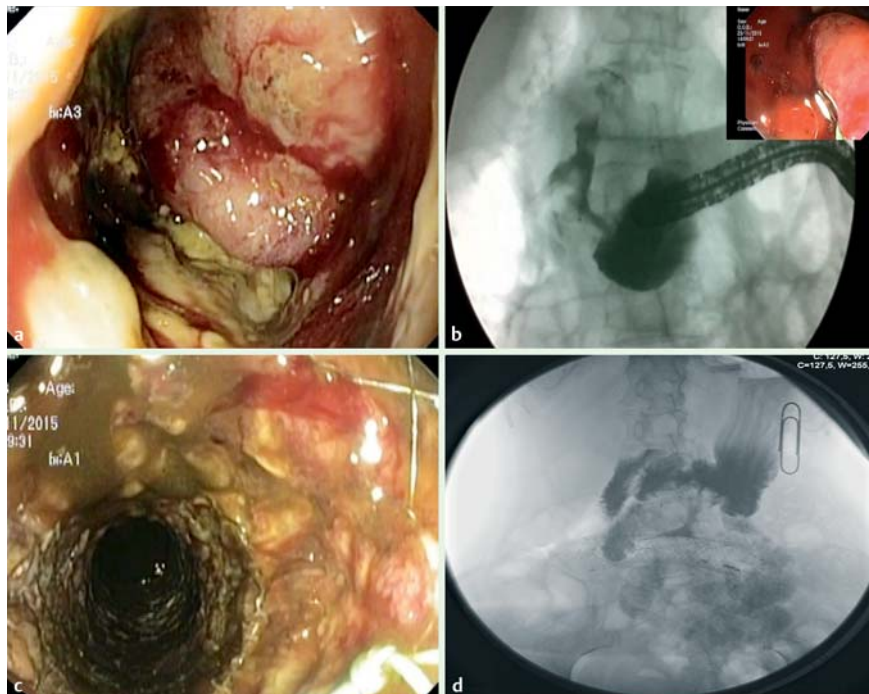


## Two-step two-stent technique to manage a large gastrocolonic fistula

Gastrocolonic malignant fistulas can occur, although rarely, complicating gastric or colonic neoplasms. En bloc resection of the fistulous tract and involved segments is the first-line treatment whenever possible, with endoscopic treatment an alternative. Endoscopic closure has been described using covered stents [1,2], over-the-scope clips [3], and atrial septal defect occlusion devices [4]. However, in the colon, covered stents are associated with a high migration risk [5]. We therefore developed a new technique to allow fistula closure, overcoming the risks of stent migration by initially placing an uncovered stent, which is followed by the deployment of a covered stent inside the first stent a few days later and fixation of the two stents to each other using through-the-scope clips.

Our patient, a 58-year-old woman, had a metastatic and locally advanced intestinal-type gastric cancer with colonic invasion. After receiving 12 cycles of palliative chemotherapy, she was admitted with fecaloid emesis and a computed tomography (CT) scan showed a large fistulous tract (approximately 5 cm in length with a large orifice) between the stomach and the transverse colon. Although the patient had a good performance status, surgical resection was not considered feasible and endoscopic palliation was proposed.

Esophagogastroduodenoscopy (EGD) showed a large ulcerated neoplasm in the greater curvature of the gastric antrum, with a large orifice communicating with an ulcerated fistulous tract. Colonoscopy revealed a stenosis in the transverse colon and contrast instillation allowed characterization of the stricture and of the fistulous tract. An uncovered metal stent (WallFlex; 22–27 mm × 90 mm; Boston Scientific, Marlborough, Massachusetts, USA) was then placed in the strictured transverse colon where the colonic fistulous orifice was located. After 3 days (to allow time for embedment of the uncovered stent in the colonic wall), a similar



► **Fig. 1** Endoscopic and fluoroscopic images showing a partially covered stent that was placed inside a previously deployed uncovered colonic stent to provide endoscopic closure of a large gastrocolonic fistulous tract.

### ▶ VIDEO 1



► **Video 1:** An uncovered colonic stent was initially placed through the stricture at the orifice of the gastrocolonic fistula. After 3 days, which allowed time for the stent to embed in the colonic wall, a partially covered stent was deployed inside the first one and to avoid migration the stents were attached to each other using metal clips.

caliber partially covered stent (Hanaro-stent; 26–20–26 mm × 90 mm; M. I. Tech, Pyeongtaek-si, Gyeonggi, South Korea) was deployed inside the previously placed stent in order to occlude the fistulous tract. Finally, the meshes of the two metal stents were fixed to each other with two metal clips (► **Fig. 1**; ► **Video 1**).

This innovative approach allowed the fistulous tract to be closed, as seen in a gastroduodenal series performed after 3 days, and the patient was discharged 3 days later on an oral diet. Closure of the fistula allowed the patient's palliative chemotherapy to be continued and 6 months later she was still alive, without any fistula-related symptoms and with the stents in place. We believe that this technique should be considered to decrease the risk of migration whenever an enteral covered stent is needed to occlude a fistulous tract or dehiscence.

Endoscopy\_UCTN\_Code\_TTT\_1AQ\_2AG

### Competing interests

None

### The Authors

**Diogo Libânio, Jorge Lage, Sara Pires, Rui Silva, Mário Dinis-Ribeiro**

Gastroenterology Department, Portuguese Oncology Institute of Porto, Porto, Portugal

### Corresponding author

**Diogo Libânio, MD**

Gastroenterology Department, Portuguese Oncology Institute of Porto, Rua Dr. António Bernardino de Almeida, 4200-072 Porto, Portugal,  
diogolibaniomonteiro@gmail.com

### References

- [1] Fernandes C, Pinho R, Proenca L et al. Palliation of a gastrocolic fistula secondary to colon cancer with a covered colonic stent using a simultaneous dual-scope approach. *Tech Coloproctol* 2015; 19: 367–368
- [2] Lim CH, Kim SW, Kim JS et al. Successful palliation of a gastrocolic fistula secondary to gastric cancer by insertion of a covered colonic stent. *Gastrointest Endosc* 2011; 73: 1314–1317
- [3] Monkemuller K, Peter S, Alkurdi B et al. Endoscopic closure of a gastrocolic fistula using the over-the-scope-clip-system. *World J Gastrointest Endosc* 2013; 5: 402–406
- [4] Malespin M, Gaspar JP, Boulay B. Palliation of a malignant gastrocolic fistula with the use of an atrial septal defect occlusion device. *Endoscopy* 2014; 46 (Suppl. 01): E4
- [5] Choi JH, Lee YJ, Kim ES et al. Covered self-expandable metal stents are more associated with complications in the management of malignant colorectal obstruction. *Surg Endosc* 2013; 27: 3220–3227

### Bibliography

DOI <http://dx.doi.org/10.1055/s-0042-118456>

*Endoscopy* 2017; 49: E7–E8

© Georg Thieme Verlag KG

Stuttgart · New York

ISSN 0013-726X