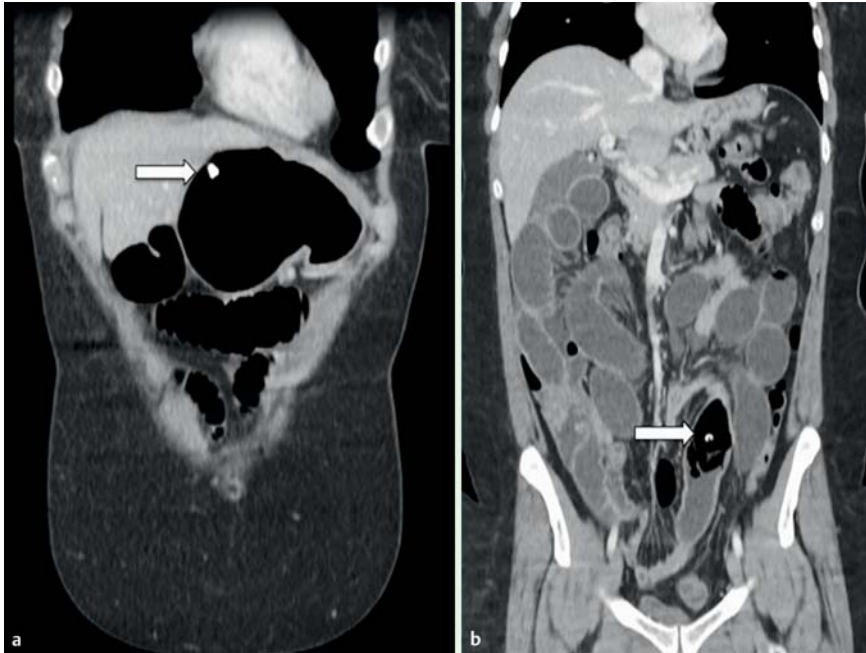
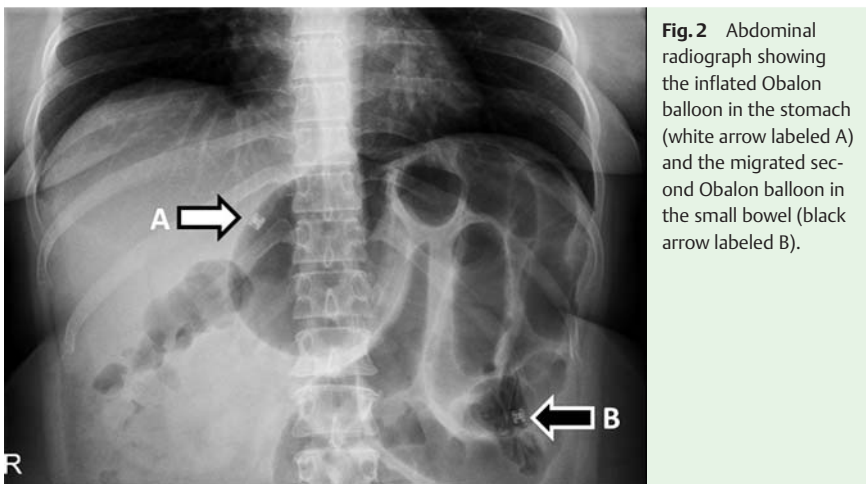


## Small bowel obstruction caused by a migrated Obalon gastric bariatric balloon: nonsurgical management by antegrade double-balloon panenteroscopy



**Fig. 1** Abdominal computed tomography (CT) scan showing: **a** an inflated Obalon balloon in the stomach; **b** the migrated second Obalon balloon in the small bowel (in coronal view).



**Fig. 2** Abdominal radiograph showing the inflated Obalon balloon in the stomach (white arrow labeled A) and the migrated second Obalon balloon in the small bowel (black arrow labeled B).

A 46-year-old woman presented with small-bowel obstruction (SBO) 2 months after placement of two Obalon gastric balloons (Obalon Therapeutics, California, USA) for weight loss [1]. A computed tomography (CT) scan confirmed SBO caused by a partially deflated balloon that had migrated into the ileum; the other balloon remained inflated and in

situ within the stomach (● Fig. 1 and ● Fig. 2).

After 72 hours of conservative management, a sudden worsening of her symptoms warranted intervention. For avoidance of surgery, we performed an antegrade double-balloon enteroscopy (DBE) with the patient under general anesthesia.

The first (intra-gastric) balloon was deflated and extracted to enable friction-free DBE. The enteroscope was then inserted down to the distal ileum to an estimated depth of 6.4 m from the pylorus, where the second partially deflated retained balloon was identified approximately 20 cm proximal to the ileocecal valve (ICV). The retained balloon was then completely deflated by aspirating through an endoscopic injection needle before the balloon was carefully pushed through the ICV into the ascending colon with endoscopic graspers (● Fig. 3). No strictures were encountered during the uncomplicated panenteroscopy. The patient's symptoms of obstruction resolved completely and the balloon was passed in the stools 2 days later (● Fig. 4).

Migration of partially deflated gastric balloons into the small bowel is a recognized but uncommon complication that may warrant surgical intervention [2]. Although DBE has been shown to be useful for retrieval of foreign objects retained within the small bowel [3,4], to the best of our knowledge, this is only the second reported case of management of gastric balloon-related SBO by DBE [5]. Ours is the first report of this being achieved through antegrade panenteroscopy with endoscopic deflation of the impacted balloon and advancement of this through the ICV into the ascending colon. The antegrade route was the only DBE approach possible in this patient with SBO and an unprepared colon. Our case highlights the usefulness of DBE for the potential avoidance of surgery in such cases.

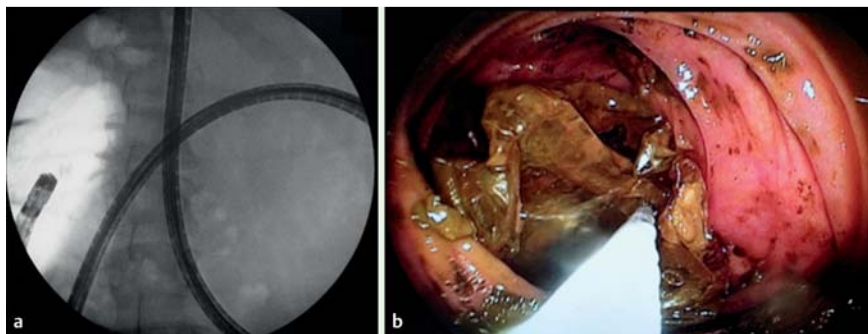
Endoscopy\_UCTN\_Code\_CCL\_1AC\_2AH

**Competing interests:** Edward J. Despott and Erasmia Vlachou have received research and education grants from Fujifilm and Aquilant Medical. The remaining authors have no conflicts of interest.

**Erasmia Vlachou<sup>1</sup>, Shamindra Direkz<sup>1</sup>, Alberto Murino<sup>1</sup>, Peter Wylie<sup>2</sup>, Mark I. Hamilton<sup>1</sup>, Charles D. Murray<sup>1</sup>, Edward J. Despott<sup>1</sup>**

<sup>1</sup> Royal Free Unit for Endoscopy, The Royal Free Hospital and University College London (UCL) Institute for Liver and Digestive Health, London, United Kingdom

<sup>2</sup> Department of Radiology, The Royal Free Hospital and University College London (UCL) Institute for Liver and Digestive Health, London, United Kingdom



**Fig. 3** The retained balloon was pushed out into the ascending colon during double-balloon panenteroscopy (DBE), as shown on: **a** fluoroscopic view; **b** enteroscopic view.



**Fig. 4** The retrieved Obalon balloon, passed in the stool 2 days later.

## References

- 1 Mion F, Ibrahim M, Marjoux S et al. Swallowable Obalon® gastric balloons as an aid for weight loss: a pilot feasibility study. *Obes Surg* 2013; 23: 730–733
- 2 Vanden Eynden F, Urbain P. Small intestine gastric balloon impaction treated by laparoscopic surgery. *Obes Surg* 2001; 11: 646–648
- 3 May A, Nachbar L, Ell C. Extraction of entrapped capsules from the small bowel by means of push-and-pull enteroscopy with the double-balloon technique. *Endoscopy* 2005; 37: 591–593
- 4 Neumann H, Fry LC, Rickes S et al. A 'double-balloon enteroscopy worth the money': endoscopic removal of a coin lodged in the small bowel. *Dig Dis* 2008; 26: 388–389
- 5 Halm U, Grothoff M, Lamberts R. Gastric balloon causing small bowel obstruction: treatment by double-balloon enteroscopy. *Endoscopy* 2013; 45 (Suppl. 02): E78–E79

## Bibliography

**DOI** <http://dx.doi.org/10.1055/s-0042-120289>  
*Endoscopy* 2016; 48: E403–E404  
 © Georg Thieme Verlag KG  
 Stuttgart · New York  
 ISSN 0013-726X

## Corresponding author

**Edward J. Despott, MD, MRCP, FASGE**  
 Royal Free Unit for Endoscopy  
 The Royal Free Hospital and University College  
 London (UCL) Institute for Liver and Digestive  
 Health  
 Hampstead  
 London  
 United Kingdom  
 Fax: +44-20-74315261  
[edespott@doctors.org.uk](mailto:edespott@doctors.org.uk)