

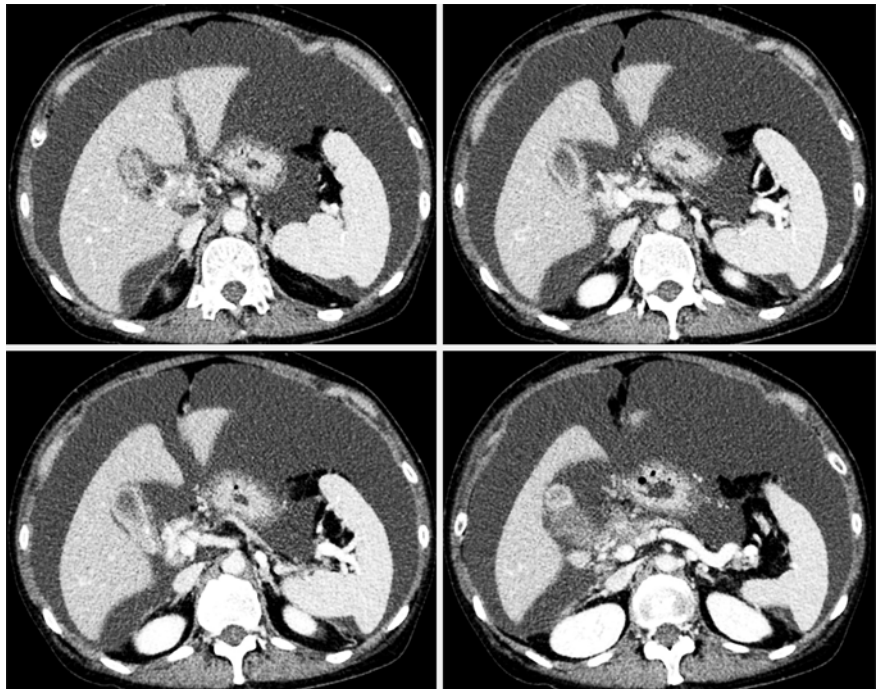Rescue technique using a diathermic dilator for an unremovable stent in malignant perihilar biliary obstruction

Endoscopic biliary stenting is a useful and safe technique for malignant biliary obstructions. A plastic stent is frequently used because of its low cost and ease of deployment. However, it is occasionally difficult to remove a plastic stent because of severe stricture. We describe a rescue technique for immovable plastic stents, using a diathermic dilator in a case of perihilar biliary obstruction.

A 63-year-old woman with jaundice due to hilar biliary obstruction was referred to our hospital. A diagnosis of gallbladder cancer was made from findings of a thickened gallbladder wall and massive ascites revealed by computed tomography (► Fig. 1) and magnetic resonance cholangiopancreatography (► Fig. 2). For biliary decompression and pathological confirmation, endoscopic retrograde cholangiography (ERC) was performed, and a 7-Fr plastic stent was placed (► Fig. 3, ► Video 1).

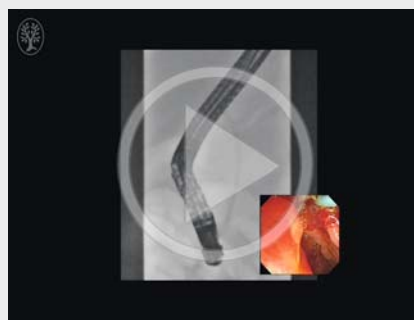
The patient underwent a second ERC 4 days later because of elevated biliary enzymes. The plastic stent could not be removed using forceps and snares, and the torn-off stent was left in place (► Fig. 4). Although needle-knife sphincterotomy was performed to expose the residual plastic stent, the stent could not be grasped. A 0.025-inch guidewire could be advanced alongside the plastic stent, but a sphincterotome (CleverCut 3V; Olympus, Tokyo, Japan) could not. Successful dilation of the perihilar biliary stricture was achieved by advancing a 6-Fr wire-guided diathermic dilator (Cysto-Gastro-Set; Endo-Flex GmbH, Voerde, Germany) (► Fig. 5). However, the remaining plastic stent also migrated. Thus, a 10-mm lumen partially covered, self-expandable, metallic stent (WallFlex biliary stent; Boston Scientific Japan, Tokyo, Japan) was deployed alongside the plastic stent (► Fig. 6).

In cases of malignant biliary stricture, removal of a plastic stent is time-consuming and might cause complications. The

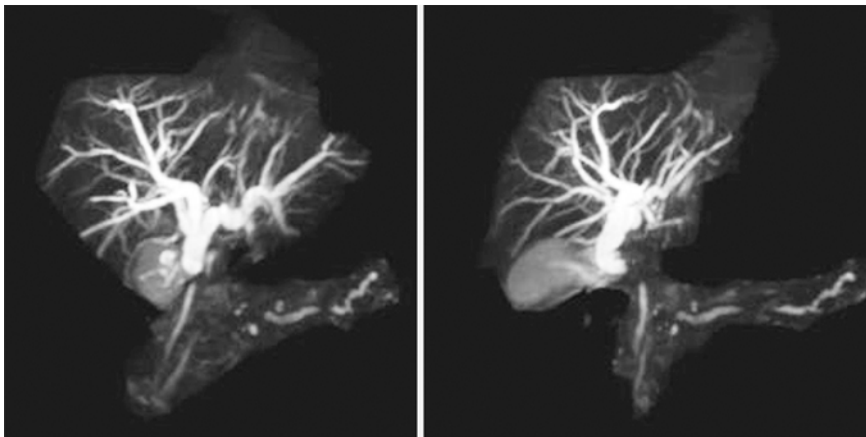


► Fig. 1 Contrast-enhanced computed tomography showed a thickened gallbladder wall and massive ascites.

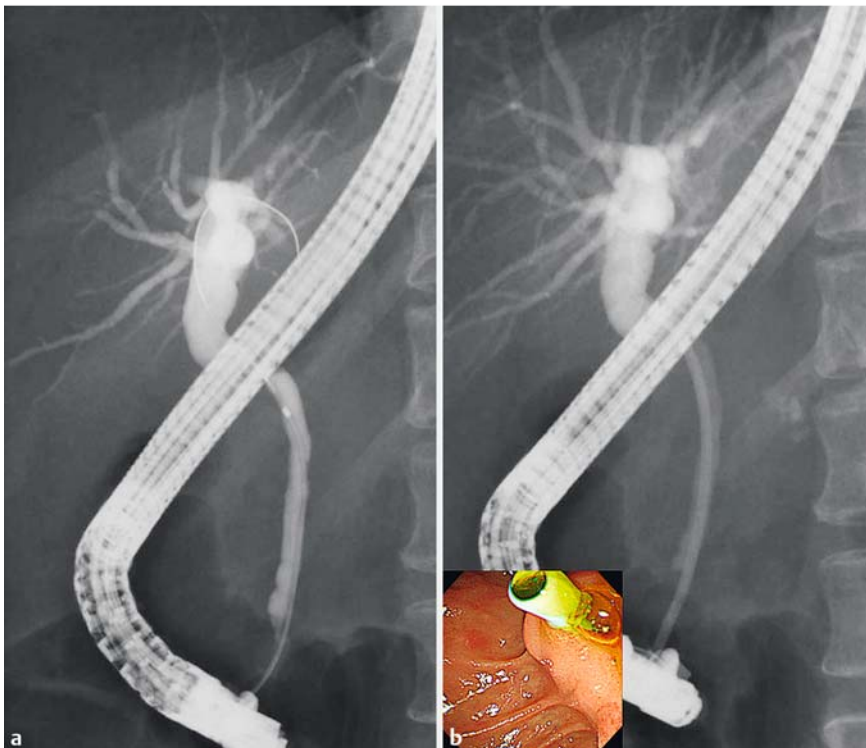
► VIDEO 1



► Video 1: A plastic stent was placed during the first endoscopic retrograde cholangiography (ERC) for malignant perihilar biliary obstruction. At the second ERC, the plastic stent could not be removed and a sphincterotome could not be advanced through the perihilar biliary obstruction. However, a 6-Fr diathermic dilator could be advanced beyond the perihilar biliary obstruction. Finally, a partially covered, self-expandable, metallic stent was placed successfully alongside the plastic stent.



► **Fig. 2** Magnetic resonance cholangiopancreatography showed a perihilar biliary stricture with dilation of the intrahepatic bile duct.



► **Fig. 3** Radiographic images. **a** The perihilar biliary stricture. **b** A 7-Fr plastic stent was placed across the perihilar biliary stricture (inset: endoscopic view of the plastic stent through the ampulla of Vater).

usefulness of a diathermic dilator for severe biliary strictures has been reported [1–5]. The use of diathermic dilation is also an effective rescue technique for unremovable occluded plastic stents.

Endoscopy_UCTN_Code_CPL_1AK_2AD

Competing interests

None

The Authors

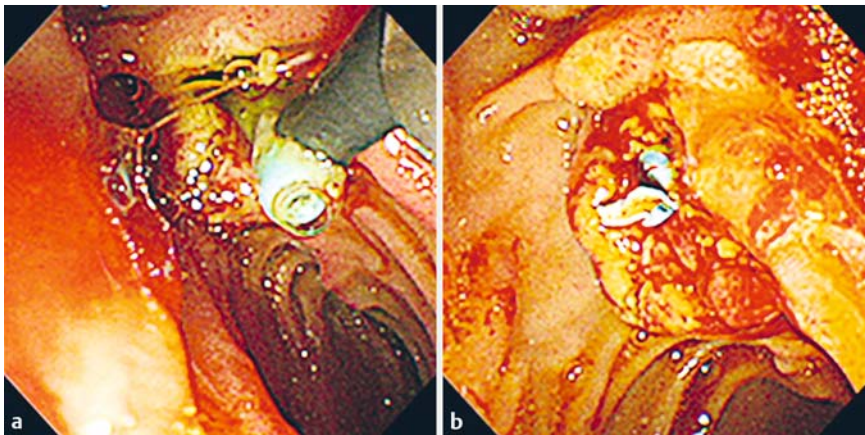
Ryo Sugiura^{1,2}, **Hiroshi Kawakami**^{2,3,4}, **Nobuyuki Ehira**¹, **Ichiro Iwanaga**¹, **Minoru Uebayashi**¹, **Masaki Kuwatani**⁵, **Naoya Sakamoto**²

- 1 Department of Gastroenterology, Japanese Red Cross Kitami Hospital, Kitami, Japan
- 2 Department of Gastroenterology and Hepatology, Hokkaido University Hospital, Sapporo, Japan
- 3 Department of Gastroenterology and Hepatology, University of Miyazaki, Miyazaki, Japan
- 4 Center for Digestive Disease, University of Miyazaki Hospital, Miyazaki, Japan
- 5 Division of Endoscopy, Hokkaido University Hospital, Sapporo, Japan

Corresponding author

Hiroshi Kawakami, MD, PhD

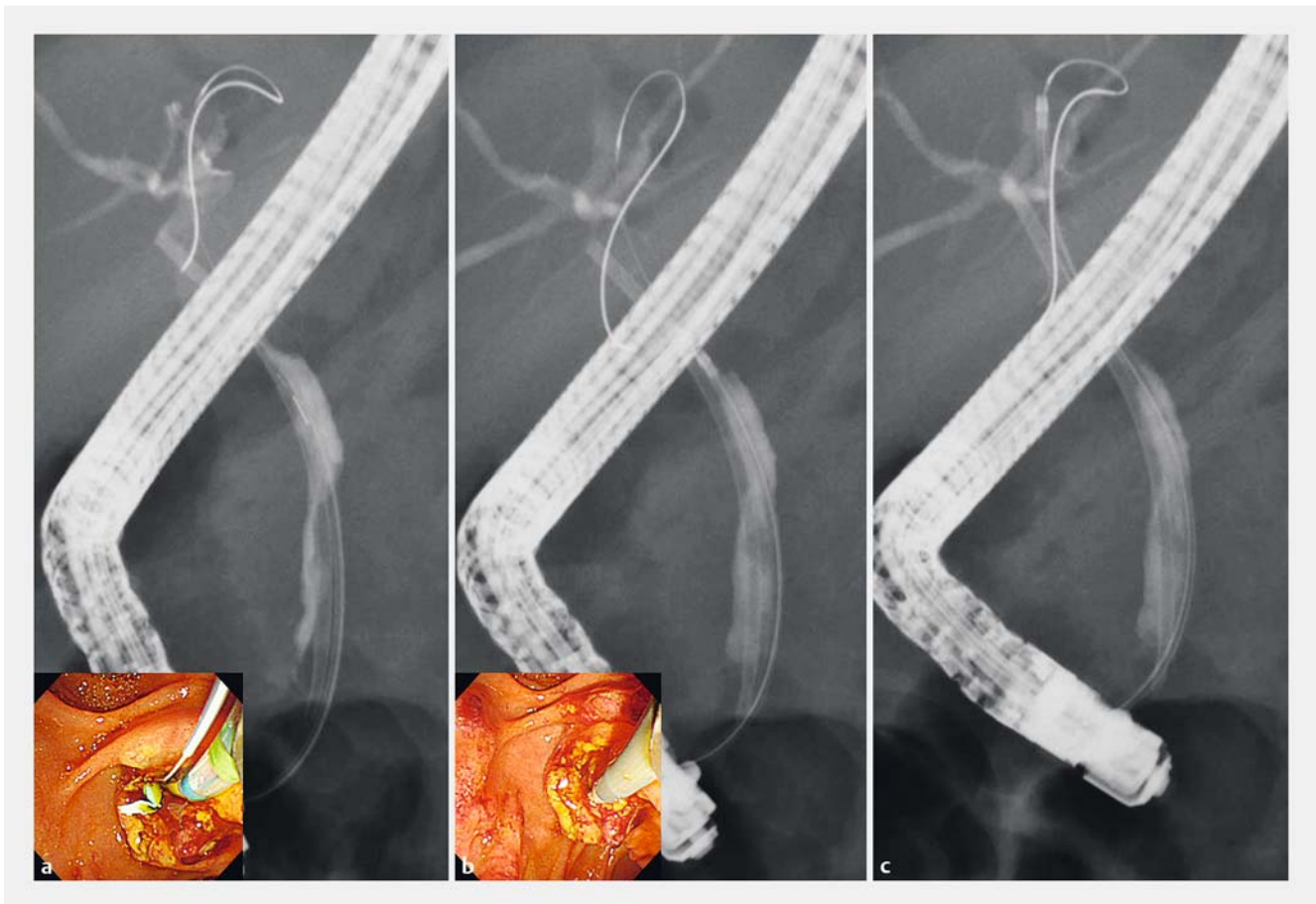
Department of Gastroenterology and Hepatology, University of Miyazaki, Center for Digestive Disease, 5200, Kihara, Kiyotake-cho, 889-1692 Miyazaki, Japan
 Fax: +81-985-859802
 hiropon@med.miyazaki-u.ac.jp



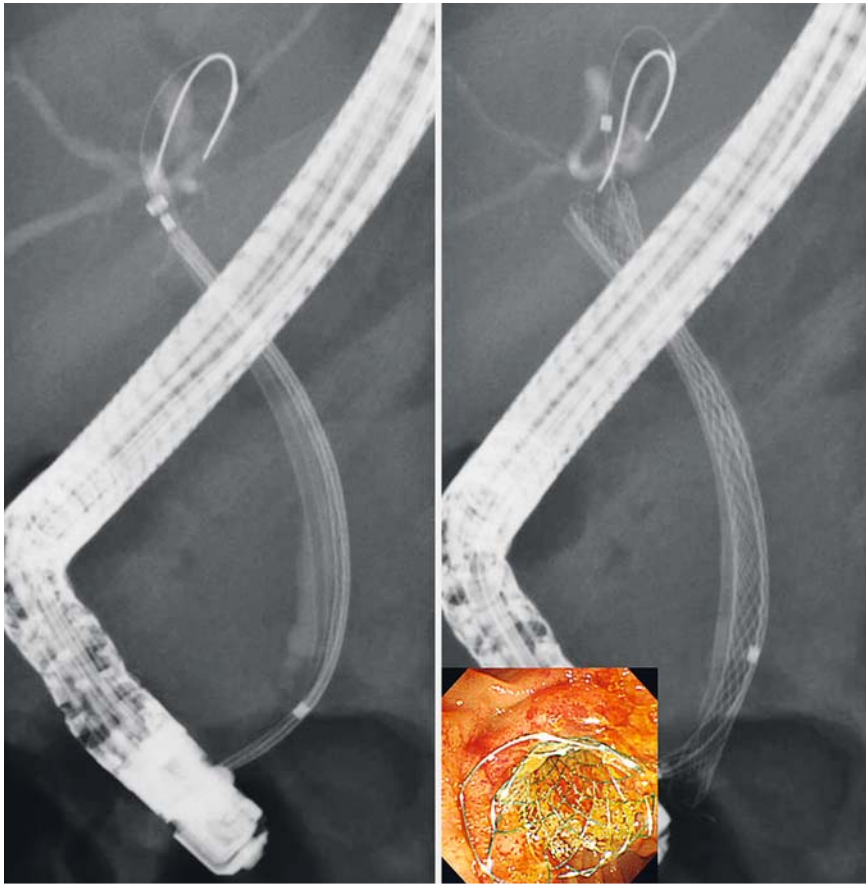
► **Fig. 4** Endoscopic images. **a** Snaring of the plastic stent after precut sphincterotomy with a needle-knife. **b** The torn-off plastic stent was left in place.

Acknowledgment

We express our deepest appreciation to Dr. Yunosuke Takishin, Kazuharu Suzuki, and Naoki Kawagishi (Department of Gastroenterology, Japanese Red Cross Kitami Hospital) for clinical advice.



► **Fig. 5** Radiographic images. **a** A 0.025-inch guidewire was advanced alongside the plastic stent (inset: endoscopic view). **b, c** A 6-Fr diathermic dilator was advanced alongside the perihilar biliary stricture (inset: endoscopic view).



► **Fig. 6** Radiographic images showing the partially covered, self-expandable, metallic stent placed over the stricture alongside the plastic stent.

References

- [1] Kawakami H, Kuwatani M, Eto K et al. Resolution of a refractory severe biliary stricture using a diathermic sheath. *Endoscopy* 2012; 44 (Suppl. 02): E119–120
- [2] Kawakami H, Kuwatani M, Kawakubo K et al. Transpapillary dilation of refractory severe biliary stricture or main pancreatic duct by using a wire-guided diathermic dilator (with video). *Gastrointest Endosc* 2014; 79: 338–343
- [3] Kawakami H, Kuwatani M, Sakamoto N. Endoscopic ultrasound-guided antegrade diathermic dilation followed by self-expandable metallic stent placement for anastomotic stricture after hepaticojejunostomy (with video). *Dig Endosc* 2014; 26: 121–122
- [4] Kawakami H, Kuwatani M, Kawakubo K et al. Endoscopic ultrasound-guided antegrade diathermic dilation followed by self-expandable metal stent placement for malignant distal biliary stricture. *Endoscopy* 2014; 46 (Suppl. 01): E328–329
- [5] Kawakami H, Abo D, Kawakubo K et al. Rendezvous biliary recanalization combining percutaneous and endoscopic techniques using a diathermic dilator for bile duct obstruction. *Endoscopy* 2014; 46 (Suppl. 01): E460–461

Bibliography

DOI <http://dx.doi.org/10.1055/s-0042-121010>
Endoscopy 2017; 49: E42–E45
 © Georg Thieme Verlag KG
 Stuttgart · New York
 ISSN 0013-726X