

Urological Impact of Epididymo-orchitis in Patients with Anorectal Malformation: An ARM-Net Consortium Study

Anna Morandi¹ Maria Fanjul² Barbara Daniela Iacobelli³ Inbal Samuk⁴ Dalia Aminoff⁵
 Paola Midrio⁶ Ivo de Blaauw⁷ Eberhard Schmiedeke⁸ Alessio Pini Prato⁹ Wout Feitz¹⁰
 Hendrik J. J. van der Steeg⁷ Dario Guido Minoli¹¹ Cornelius E. J. Sloots¹² Francesco Fascetti-Leon¹³
 Igor Makedonsky¹⁴ Araceli Garcia¹⁵ Pernilla Stenström¹⁶

¹ Department of Pediatric Surgery, Fondazione IRCCS Ca' Granda Ospedale Maggiore Policlinico, Milano, Italy

² Department of Pediatric Surgery, Hospital Gregorio Marañón, Madrid, Spain

³ Newborn Surgery Unit, Department of Medical and Surgical Neonatology, Research Institute, Bambino Gesù Children's Hospital, Rome, Italy

⁴ Department of Pediatric and Adolescent Surgery, Schneider Children's Medical Center, Sackler Faculty of Medicine, Tel Aviv University, Tel Aviv, Israel

⁵ AIMAR-Italian Patients' and Parents' Organization for Anorectal Malformation, Rome, Italy

⁶ Pediatric Surgery Unit, Cà Foncello Hospital, Treviso, Italy

⁷ Department of Pediatric Surgery, Radboudumc Amalia Children's Hospital, Nijmegen, the Netherlands

⁸ Clinic for Paediatric Surgery and Paediatric Urology, Klinikum Bremen-Mitte, Bremen, Germany

⁹ Pediatric Surgery Unit, The Children Hospital, Azienda Ospedaliera SS Antonio e Biagio e Cesare Arrigo, Alessandria, Italy

Address for correspondence Anna Morandi, MD, Department of Pediatric Surgery, Fondazione IRCCS Ca' Granda, Ospedale Maggiore Policlinico, Via F. Sforza 28, 20122 Milano, Italy (e-mail: anna.morandi@policlinico.mi.it).

¹⁰ Division of Paediatric Urology, Department of Urology, Radboudumc Amalia Children's Hospital, Nijmegen, the Netherlands

¹¹ Pediatric Urology Unit, Fondazione IRCCS Ca' Granda Ospedale Maggiore Policlinico, Milano, Italy

¹² Department of Pediatric Surgery, Erasmus MC Sophia Children's Hospital, Rotterdam, the Netherlands

¹³ Pediatric Surgery Unit, Department of Women's and Children's Health, University of Padua, Padua, Italy

¹⁴ Department of Pediatric Surgery, Rudnev Dnipropetrovsk Specialized Clinical Medical Center for Mother and Child Health, Dnipro, Ukraine

¹⁵ Pediatric Surgery Unit, University Hospital 12 de Octubre, Madrid, Spain

¹⁶ Department of Pediatric Surgery, Skane University Hospital, Lund University, Lund, Sweden

Eur J Pediatr Surg 2022;32:504–511.

Abstract

Keywords

- ▶ urology
- ▶ LUTD
- ▶ anorectal malformation
- ▶ epididymo-orchitis
- ▶ acute scrotum

Introduction To investigate the current experience of the ARM-Net Consortium in the management of epididymo-orchitis (EO) in patients with anorectal malformations (ARMs), and to identify specific risk factors and the need for urological care involvement.

Materials and Methods We retrospectively collected data of EO in patients with ARM between 2015 and 2019. Data on urological aspects, ARM type, surgical approach, associated anomalies, diagnosis, and treatment of EO were collected and analyzed.

Results Twenty-nine patients were reported by 12 centers. Twenty-six patients with EO (90%) had ARM with a rectourinary fistula. Median age at first EO was 2 years (range: 15 days–27 years). Twenty patients (69%) experienced multiple EO, and 60% of recurrences were ipsilateral. Associated urological anomalies included vesicoureteral reflux (48%), urethral anomalies (41%), neurogenic bladder (41%), and ectopic vas (10%). A positive urine culture during EO was present in 69%. EO was treated with antibiotics (90%), limiting surgical exploration to 14%. Prevention of recurrences

received
 September 21, 2021
 accepted
 December 13, 2021
 published online
 January 24, 2022

© 2022, Thieme. All rights reserved.
 Georg Thieme Verlag KG,
 Rüdigerstraße 14,
 70469 Stuttgart, Germany

DOI <https://doi.org/10.1055/s-0042-1742300>.
 ISSN 0939-7248.

included surgery (bulking agents 15%, vasectomy 15%, and orchiectomy 5%) and antibiotic prophylaxis (20%).

Conclusion Urologists may encounter patients with EO in ARM patients, frequently with positive urine culture. An appropriate urologic work-up for most ARM patients is necessary to identify and treat underlying risk factors. A practical scheme for the work-up is suggested for a close collaboration between pediatric surgeons and urologists.

Introduction

Urologists often encounter patients with an epididymo-orchitis (EO) of whom patients with anorectal malformations (ARMs) form a specific subgroup.^{1–4} This subgroup calls for a close collaboration between urologists and pediatric surgeons. EO involves an inflammatory reaction of the epididymis to a variety of agents or conditions (infection, trauma, sterile urine, lower urinary tract dysfunction [LUTD], strictures, anatomical anomalies),¹ and represents one of the causes of acute scrotum in children. It should be distinguished from acute testicular torsion, which requires prompt surgical exploration.

Without proper treatment, recurrent EO may result in complications such as testicular abscess, testicular infarction and destruction, and consequently, subfertility or even infertility.^{5,6} Despite the risk of subfertility or infertility, etiology and management of EO in ARM patients are still undefined, and only few case series and collective reviews have been reported in the literature.^{1–4,7,8} This is likely the result of the rarity of patients with ARM, making the incidence of EO even rarer. The ARM-Net Consortium was founded in 2010 for the knowledge limitations in the care of ARM patients, joining clinical data of several expert centers involved in the treatment of patients with ARM.⁹

The aim of our study was to review the current experience of EO in patients registered within the ARM-Net Consortium to ideally identify risk factors, and propose a practical algorithm for pediatric surgeons and urologists.

Patients and Methods

In the European pediatric surgical centers that founded the ARM-Net Consortium in 2010, urologists collaborate with pediatric surgeons in the treatment of ARM patients. This consortium involves pediatric surgeons, epidemiologists, psychologists, geneticists, representatives of patient organizations, and urologists on specific consultation basis. The principal aim of this consortium is to exchange data and knowledge to improve clinical care, and to perform research on genetic, epidemiological and clinical subjects, as well as registering and monitoring frequencies of ARM types, additional malformations, surgical procedures, complications, and outcomes.⁹ The ARM-Net Consortium has a data registry of more than 1,800 ARM patients. The data are included prospectively for patients born from 2011, and retrospec-

tively for patients born from 2007 till 2011. ARM-Net members were asked to collect the data of patients within their series who suffered from EO in the last 5 years (2015–2019) with no age limits. The working group developed a specific questionnaire to retrospectively collect these data, as some patients may not have been part of the ARM-Net registry (being born before 2007). EO was defined as inflammation of epididymis and/or testis, presenting as acute scrotum. The questionnaire (see >Fig. 1) consisted of 27 items, divided into three sections: (1) general information (age of patient, type of ARM, etc.) and associated anomalies, (2) diagnostic information on EO (urine culture, semen analysis, etc.), and (3) therapeutic information on EO (prophylaxis/antibiotics,

GENERAL INFO

1. Age of patient
2. Type of ARM
3. Colostomy
4. Anoplasty
5. Urologic anomalies
6. Sacral anomalies
7. Tethered cord
8. Pubertal development
9. Neurogenic bladder
10. Urinary continence
11. Poor stream
12. Abdominal pressure to urinate
13. CIC
14. Constipation
15. Fecal incontinence
16. Age at presentation of EO
17. Number of episodes of EO

DIAGNOSTIC INFO

18. Urine culture
19. Semen analysis
20. Testicular Ultrasound
21. KUB Ultrasound
22. Cystoscopy
23. MCUG
24. Pelvic MRI
25. Urodynamics:
 - Uroflowmetry
 - Pre-post-micturition evaluation
 - Invasive urodynamic

THERAPY

26. Prophylaxis/antibiotics
27. Surgery

Fig. 1 Questionnaire developed to retrospectively collect data of ARM patients who had EO in the last 5 years (2015–2019). ARM, anorectal malformation; EO, epididymo-orchitis.

surgery). Data were exported for analysis, creating an Excel database. All data were collected and stored according to the Data Protection Act. Descriptive statistics, including mean with standard deviation, median and range, as well as percentages, were performed.

Results

General Information and Associated Anomalies

A total number of 29 patients were reported by 12 different centers. The median age of patients at the time of data collection was 8.5 years (range: 8 months–29 years). The median age at first EO episode was 2 years (range: 15 days–27 years). Twenty-six patients (90%) had ARM with rectourinary fistula: 6 (21%) bulbar, 13 (45%) prostatic, 4 (14%) bladder neck, 2 (7%) not specified, and 1 (3%) complex H-type. Two patients (7%) had ARM without fistula, and one (3%) anal stenosis. Enterostomy was opened in all cases at birth: 28 (97%) colostomy (descending 62%, sigmoid 32%, unknown 3%) and 1 ileostomy (3%) due to left hemicolectomy for necrotizing enterocolitis. Type of enterostomy included divided 24 (83%), loop 4 (14%), and for 1 case (3%), no information was available. Mean age at anorectal reconstruction was 5.3 ± 3.5 months. Two patients (7%) required redo surgery. Enterostomy was subsequently closed in 28 patients (97%), while 1 patient (3%) still had a colostomy at the time of study. One patient asked for colostomy reopening later in his life due to continence challenges.

Data on EO in our series of ARM patients are summarized in **Table 1**. All patients who had EO before ARM repair had a rectourinary fistula. They all had a divided colostomy at the time of EO. Three of them had no recurrences after ARM repair, while in two, EO recurred after anorectal reconstruction.

Associated additional urological and spinal anomalies are summarized in **Table 2**. Almost half of the patients with EO had vesicoureteral reflux (VUR), and 41% had congenital urethral anomalies. Neuropathic/neurogenic bladder anomaly was reported in 41% of our patients. Among patients with multiple episodes of EO, patients with ipsilateral recurrences (12 patients, total number of episodes 41, median 2.5, and range 2–9) were found to have the following anomalies: urethral anomalies including stenosis, hypoplastic urethra, duplication and posterior urethra valves (50%), VUR (42%), neurogenic bladder (33%), documented ipsilateral vasal reflux (17%), original or persistent rectourinary fistula (17%), ectopic vas into bladder (8%), documented urethroejaculatory reflux (8%), and ectopic verumontanum inside the fistula remnant (8%). Four patients (33%) were not investigated for anomalies despite recurrences: specifically, they undergo neither micturating cystourethrography (MCUG), nor cystoscopy, nor urodynamics. Patients with bilateral EO had urethral stenosis in 75%, neurogenic bladder in 50%, and VUR in 50%.

The majority of patients (20/29, 69%) were still below pubertal development age at the time of study. Twenty-three patients completed the toilet training. Concerning the uri-

Table 1 Data on epididymo-orchitis in our series of ARM patients

Epididymo-orchitis in ARM patients	
Median age	2 y (range: 15 d–27 y)
Timing of EO, n (%)	
Before PSARP	5 (17%)
After PSARP	24 (83%)
No. of EO episodes	
Total	74
Mean no. of episodes/patient	2.5 ± 2
Single episode, n (%)	8 (28%)
Multiple episodes	20 (69%)
Unknown	1 (3%)
Side of EO, n (%)	
Right	13 (45%)
Left	9 (31%)
Bilateral	2 (7%)
Unknown	5 (17%)
Side of recurrences, n (%)	
Ipsilateral	12 (60%)
Contralateral	2 (10%)
Bilateral since presentation	2 (10%)
Unknown	4 (20%)

Abbreviations: ARM, anorectal malformations; EO, epididymo-orchitis; PSARP, posterior sagittal anorectoplasty.

nary outcome, nine (39%) were reported as spontaneously continent, nine (39%) on intermittent catheterization, and five (22%) as incontinent. Concerning bowel function, 2 patients (9%) had regular bowel movement with no need for therapy, 14 (61%) were constipated (3 requiring stool softeners, 5 laxatives, 5 transanal irrigations, and 1 a combination of laxatives and transanal irrigations), and 7 (30%) were incontinent (6 on transanal irrigations and 1 on transanal irrigations plus loperamide).

Diagnostic Information on EO

Data on diagnostics performed in our series of patients are summarized in **Table 3**. Ultrasound was performed in most cases during acute presentation (79%), showing inflammation in all cases. During EO episodes, 13 patients (45%) had a urine culture test. The culture was positive for bacteria in 9/13 (69%), including *Escherichia coli*, *Klebsiella pneumoniae*, *Klebsiella oxytoca*, *Enterococcus faecium*, and *Pseudomonas aeruginosa*. A cystourethroscopy was performed in 13 patients (45%) and MCUG in 17 patients (59%). Pathologic findings were found in 14/17 patients (82%) at MCUG. Uroflowmetry was performed in 10 patients (34%). Pelvic magnetic resonance imaging (MRI) and invasive urodynamics were performed in a limited number of patients (21 and 14%, respectively).

Table 2 Data on associated urological and spinal anomalies in 29 patients with anorectal malformations and at least one episode of epididymo-orchitis

Urologic anomalies	
Vesicoureteral reflux	14 (48%)
Urethral anomalies	12 (41%)
Hypospadias	5 (17%)
Urethral stenosis/hypoplasia	4 (14%)
Urethral duplication	2 (7%)
Posterior urethra valves	1 (3%)
Ectopic vas deferens including a case of persistent mesonephric duct	3 (10%)
Kidney hypoplasia	4 (14%)
Persistent mesonephric duct	1 (3%)
Multicystic dysplastic kidney	1 (3%)
Renal agenesis	1 (3%)
Hourglass bladder	1 (3%)
Penile torsion	1 (3%)
Neurogenic bladder	12 (41%)
Sacral anomalies	11 (38%)
Tethered cord	9 (31%)

Therapeutic Information on EO

The majority of patients were treated with antibiotics (26/29, 90%) at onset, being amoxicillin/clavulanate the most used. Surgical exploration was limited to four cases (14%). In one of these patients, exploration was performed to rule out possible metastatic localization of a previous thoracic neuroblastoma. The testicle was biopsied and severe inflammation was reported.

In case of recurrences, antibiotic prophylaxis was administered only to four patients (20%), while surgery was the strategy of choice for six patients (30%): bulking agent injection (dextranomer microspheres, Deflux^R) for deferential reflux in two patients, vasectomy in two, both these procedures in one, and orchiectomy for severe chronic inflammation in one.

Discussion

EO can seldom represent a severe urological complication in male patients with ARM. Being a retrospective collection of data by different centers, and considering that some patients with EO within the series of ARM patients managed by the ARM-Net members may have been missed, our study was not aimed to give data on incidence. With respect to this aspect, literature reports an incidence estimated between 1.2 and 7.3%,^{1,2,10} roughly 10 times higher than in the pediatric general population.¹¹ Recurring EO may lead to devastating complications, such as subfertility or infertility.¹² The identification of underlying urological risk factors is always needed to prevent recurrences and their consequences.

Table 3 Data on diagnostic performed in patients with ARM and EO

Diagnostics performed in patients with ARM and EO	N (%)
Urine culture during EO	13 (45)
Positive (<i>E. coli</i> , <i>K. oxytoca</i> , <i>E. faecium</i> , <i>P. aeruginosa</i>)	9 (69)
Testicular ultrasound during EO	23 (79)
Cystourethroscopy	13 (45)
Urethral stricture	2 (15)
Urethral inflammation	1 (8)
Ectopic verumontanum	2 (15)
MCUG	17 (59)
VUR	8 (47)
Deferential reflux	6 (35)
Urethral anomalies	2 (12)
Seminal vesicle reflux	1 (6)
Normal	3 (18)
Pelvic MRI	6 (21)
Urinary fistula before repair	2 (33)
Left renal atrophy	1 (17)
Bilateral hydronephrosis	1 (17)
Thin pelvic muscles	1 (17)
No info available	1 (17)
Uroflowmetry	10 (34)
Pre-postmicturition scan	8 (31)
Normal	4 (50)
Pathologic residual volumes and thickened bladder wall	4 (50)
Invasive urodynamics	4 (14)
Abnormal	3 (75)
Semen analysis	1 (3)
Asthenoteratozoospermia	1 (100)

Abbreviations: ARM, anorectal malformations; EO, epididymo-orchitis; MCUG, micturating cystourethrography; MRI, magnetic resonance imaging; VUR, vesicoureteral reflux.

In our series, patients with EO and ARM were found to frequently have underlying urological anatomical alterations, mainly represented by urethral abnormalities, and functional anomalies such as neurogenic bladder and voiding dysfunction (LUTD) with associated VUR. In the current literature on pediatric population presenting with EO, an underlying genitourinary anomaly is often found.^{13–15} The most frequent underlying anomalies described are posterior urethral valves, urethral strictures, neurogenic bladder and voiding dysfunction, ectopic vas deferens,¹⁶ persistent mesonephric duct syndrome,¹⁷ Müllerian remnants,^{18,19} and seminal vesicle anomalies, such as cysts or stones.²⁰ Infectious etiology has been strongly suggested as well.²¹

In the patients with ARM, literature indicates that EO more frequently affects patients with a rectourinary fistula^{1,2,7,8} and this was confirmed by our series. More specifically, patients with a prostatic fistula were affected most, representing almost half of the cases in our series. It has been indeed reported that rectourinary fistula may disturb the anatomy of the verumontanum in the prostatic urethra.¹³ In addition, surgery for ARM might interfere with the normal anatomy and functioning of bladder (additional risk on LUTD), prostate, and urethra.

EO may present either before or after the anorectal repair. Only a limited number of patients in our case collection presented with EO before anorectal repair (17%) and all of them had a rectourinary fistula. The passage of stool or mucous into the urinary tract through the fistula has been advocated as the potential underlying mechanism.² The fact this happened only in limited cases could be ascribable to the presence of a colostomy in all the patients. Some authors indeed speculated that the presence of a loop colostomy may facilitate the passage of stool in the distal bowel, and therefore into the fistula.⁸ Despite this consideration, all our patients had a divided colostomy with separated stomas, thus a diverting colostomy does not seem to completely prevent EO, and this finding was also reported by Raveenthiran and Sam.² Since many of our patients received colonic wash-outs, it would be interesting to assess the role of this procedure in the occurrence of EO. Kiyan et al¹ in their study concluded that distal wash-outs probably caused bacterial entry into the ejaculatory duct. Unfortunately, data on distal bowel wash-outs for our patients were not available. In our series, anorectal repair with division of the rectourinary fistula was curative in only 60% of cases. Therefore, the division of the fistula can be considered effective in the absence of other predisposing factors. In particular, one patient from our series presented several EO episodes after fistula ligation, and multiple predisposing factors were indeed encountered (urethral duplication, ectopic vas deferens, and hourglass bladder), ultimately leading to vasectomy.

The age at EO onset was variable and no side predilection was observed, as previously described by other series.^{2,7,8} However, recurrences were most likely to present on the same side, and this supports the existence of underlying risk factors.

From our series both anatomical and functional predisposing factors, that can lead to reflux into the vas deferens, were identified. The anatomical anomalies that might promote deferential reflux include congenital or acquired urethral strictures, and ectopic vas deferens, including persistent mesonephric duct syndrome.

Deferential reflux was reported in 35% of patients who underwent MCUG and urethral anomalies in 41%, including hypospadias, urethral stenosis/hypoplasia, urethral duplication, and posterior urethral valves. The evidence that the majority of our patients originally had a prostatic fistula might lead to the hypothesis that the surgical treatment of ARM with a prostatic fistula, dissecting close to the prostatic urethra and verumontanum, might induce iatrogenic urethral injury and subsequent stricture. Despite the fact that

we cannot specifically report on the incidence of iatrogenic strictures in our series, Hong et al²² suggested that urethral injuries may occur in up to 20% of patients undergoing repair of the ARM. In addition, surgery may interfere with the normal course of the ejaculatory duct entering the prostatic urethra and promote reflux. Ectopic vas deferens can be considered as an additional anatomic condition that might predispose to EO, and it was reported in 10% of our patients. Despite the low incidence in our series (3%), “persistent mesonephric duct syndrome” should also be considered as a predisposing factor. This term describes an embryological anomaly in which an ectopic vas deferens joins the ureter or renal pelvis and is then drained by a common channel.²³ **Fig. 2** shows this finding in one patient of our series.

Functional anomalies, such as neuropathic bladder and LUTD with high voiding pressures or detrusor sphincter dyssynergia, could also be considered as promoters of reflux and triggers of epididymal inflammation. In particular, external urethral sphincter dyssynergia may lead to voiding dysfunction with high urethral pressures and subsequent urethral valsal reflux and epididymal inflammation.^{24,25} Neurogenic bladder was reported in 41% of our population with ARM and EO, thus supporting this hypothesis, but urodynamic data are lacking in this study. In addition, VUR was reported in almost half of our population, and this was similar to the series reported by VanderBrink et al.⁸ VUR might be the indirect expression of voiding dysfunctions. Accordingly, Zaccara et al⁷ compared ARM patients with rectourinary fistula experiencing EO to those without EO, and they found a significantly higher occurrence of VUR in the first group. Moreover, the majority of patients in our series had treatment for constipation. Fecal impaction is known to potentially interfere with the normal bladder emptying and functioning²⁶; therefore, it is mandatory to

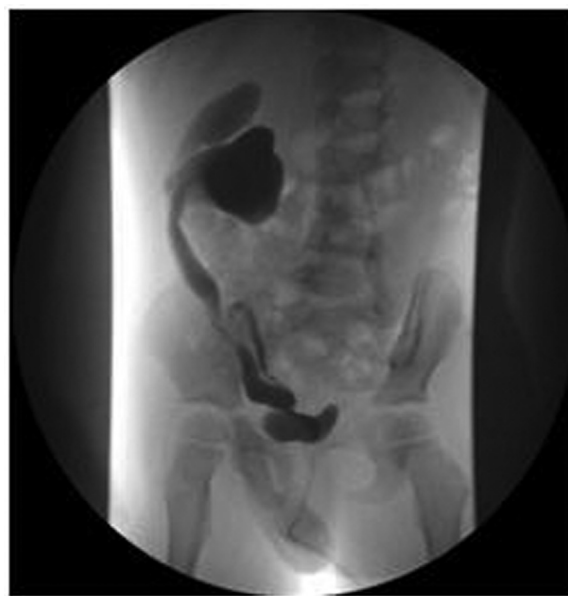

Fig. 2 Radiologic findings of a patient in our series with evidence of “persistent mesonephric duct syndrome,” in which an ectopic vas deferens joins the ureter and is then drained by a common channel.

adequately manage the bowel function and avoid fecal impaction.

Urinary tract infections may also be implicated in the pathogenesis of EO. Raventhiran and Sam² reported urinary tract infections in 54% of the patients in their series. A high incidence of bacterial infection was also noticed in our series, where almost 70% of the urine cultures were positive for bacteria. This finding might encourage the need for urine culture during EO episodes, and support the use of antibiotics for EO in this population. The utility of antibiotic prophylaxis to prevent recurrences should also be considered, although in our series this strategy was chosen only in a limited number of patients with unknown effects.

Only 14% of our cases underwent surgical exploration during EO, as reported by others.² This finding supports the presumption that acute scrotum in ARM is highly suggestive for EO. Moreover, some previous studies reported the need for surgery to drain scrotal abscesses,^{2,8} but this did not occur in our series. Therefore, we recommend that surgical exploration should be limited to cases of testicular torsion, or in case of EO with scrotal abscess. This will help avoid unnecessary surgery to patients who are already exposed to several surgeries.

Recurrent episodes of EO might lead to fibrosis and scarring, thus interfering with fertility.^{5,6,12} Holt et al⁶

reported that 20% of male infertility in ARM may be ascribed to recurrent EO. Therefore, we strongly suggest a complete urologic work-up in patients with ARM who present with EO and recurrent EO. We propose a diagnostic and therapeutic algorithm for practical use for pediatric surgeons and urologists dealing with EO in ARM patients (→ Fig. 3). This work-up should help identify underlying risk factors, elucidate the etiology, and prevent recurrences to minimize the risk of long-term consequences. The first step in the diagnostic work-up is a renal ultrasound^{8,26} with a further nuclear kidney scan in case of an abnormal ultrasound. In addition, we recommend that all boys with (recurrent) EO should undergo MCUG²⁷ and urodynamic evaluation regardless of spinal cord or sacral anomalies. Video urodynamic studies could give useful further information and support traditional imaging in the diagnostic assessment of these patients. Endoscopic evaluation with cystoscopy should also be considered, especially in case of recurrent EO.

The therapeutic management of recurrent EO is considered a challenge for urologists and pediatric surgeons involved in the care for these patients. Our study suggests that first of all the presence of a recurrent rectourinary fistula needs to be assessed. Provided the rectourinary tract fistula has been divided, urethral obstruction needs to be treated, and neurogenic bladder and voiding dysfunction properly managed. To prevent urethroejaculatory reflux,

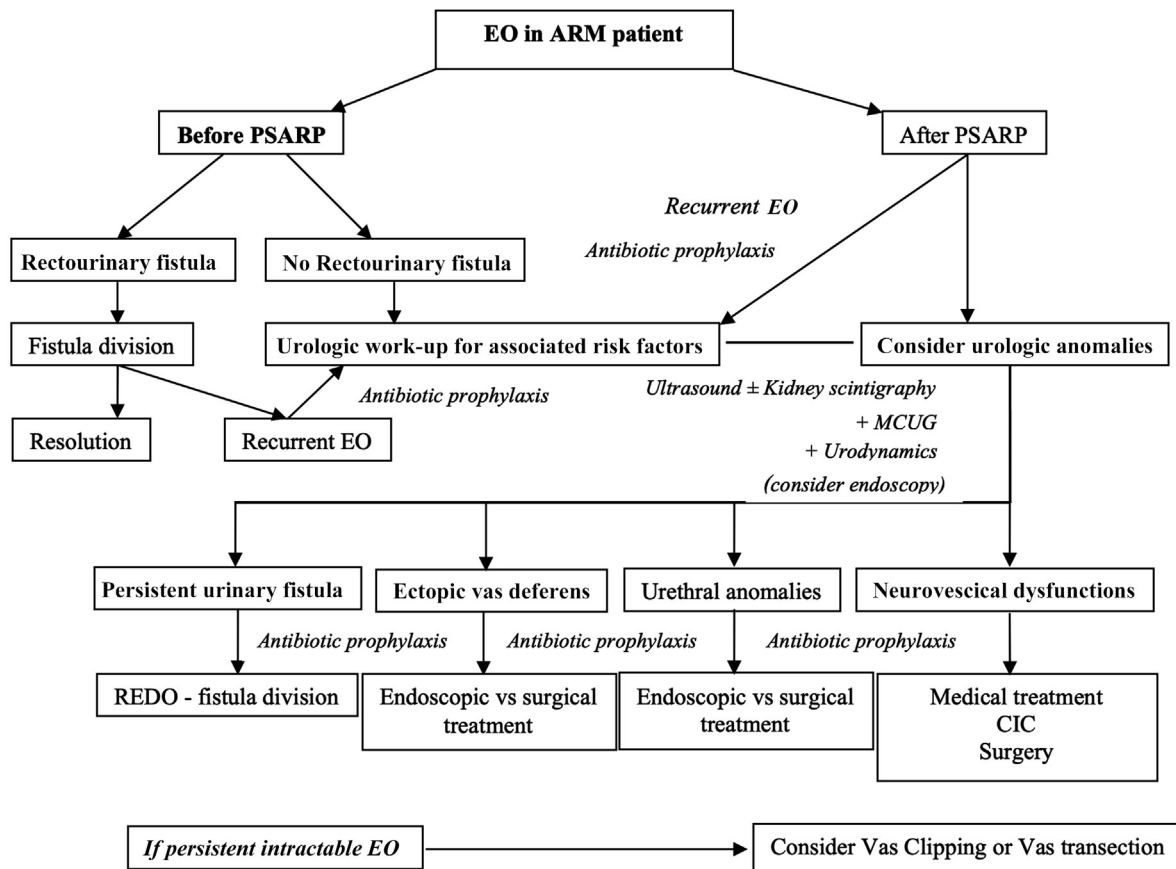


Fig. 3 The figure reports the diagnostic and therapeutic algorithm that we suggest in case of EO in ARM patients. ARM, anorectal malformation; EO, epididymo-orchitis; MCUG, micturating cystourethrography; PSARP, posterior sagittal anorectoplasty.

endoscopic injections of bulking agents at the verumontanum around the ejaculatory ducts might also be considered.²⁷ Although some authors have reported unsatisfactory results of endoscopic correction,^{16,28} Faure et al²⁷ showed that endoscopic injection effectively prevented recurrent EO in 73% of patients at a mean follow-up of 3 years. In their experience, the procedure did not result in perioperative complication nor contraindicate subsequent surgical procedures, such as vas clipping. However, bulking agent injections may lead to calcifications, and the long-term consequences of calcifications in the bladder mucosa, as well as in the growing prostate (prostatitis), are unknown. Therefore, parents and children should be informed that calcification associated with endoscopic injections of bulking agents can occur.²⁷

In case of intractable EO, vas clipping or vas transection might be considered even in children, as the risks of spermatogenic cells damage in case of recurrent EO are likely. Holt et al⁶ reported that more than 50% of cases of infertility were the result of delayed vas surgery. We believe that vas transection should be taken into consideration for recurrent EO, only after exclusion and/or treatment of other underlying risk factors. The advances in reproductive technology, with vas transection reversal and assisted reproduction,²⁹ may help these patients in the future.

Our study presents some limitations. First, the retrospective collection of patients, based on a questionnaire, cannot provide any epidemiologic information on incidence of EO in ARM patients. In addition, we do not have complete data for all the patients; therefore, associated anomalies might be underreported as well. Due to the wide age range, not all patients reached the pubertal age and data on fertility are not yet available. Finally, our multicenter study shows high variability in diagnostic, treatment, and prevention strategies between different European centers thus calling for standardization of care.

Conclusion

EO may present in ARM patients and expose them to the risk of subfertility or infertility, especially in case of recurrences. A complete urologic work-up is necessary in these patients to identify and treat underlying anatomical and functional risk factors, thus minimizing risks. We propose a practical algorithm for these cases, and support a clear collaboration between urologists and pediatric surgeons in the multidisciplinary teams for the care of patients with ARM.

Funding

None.

Conflict of Interest

None declared.

Acknowledgements

We would like to thank Dr David Ben-Meir (Schneider Children's Medical Center, Petah Tikva, Tel Aviv University, Israel), Dr Antonio Zaccaria (Ospedale Bambino Gesù,

Rome, Italy), and Dr Jose Maria Angulo (Hospital Gregorio Marañón, Madrid, Spain), urologists involved in the management of ARM patients in the participating Centers.

References

- 1 Kiyan G, Dagli TE, Iskit SH, Tugtepe H. Epididymitis in infants with anorectal malformation. *Eur Urol* 2003;43(05):576–579
- 2 Raveenthiran V, Sam CJ. Epididymo-orchitis complicating anorectal malformations: collective review of 41 cases. *J Urol* 2011;186(04):1467–1472
- 3 Oğuzkurt P, Tanyel FC, Büyükpamukçu N. Acute scrotum due to edidymo-orchitis associated with vasal anomalies in children with anorectal malformations. *J Pediatr Surg* 1998;33(12):1834–1836
- 4 Rubio Cordero JL, Nuñez Nuñez R, Blesa Sanchez E. Ano-rectal malformation and recurring orchioepididymitis in infants. *Eur J Pediatr Surg* 1994;4(01):46–48
- 5 Graves RS, Engel WJ. Experimental production of epididymitis with sterile urine; clinical implications. *J Urol* 1950;64(04):601–613
- 6 Holt B, Pryor JP, Hendry WF. Male infertility after surgery for imperforate anus. *J Pediatr Surg* 1995;30(12):1677–1679
- 7 Zaccara A, Ragozzino S, Iacobelli BD, et al. Epididymo-orchitis and anorectal malformations: when and in whom? *Pediatr Surg Int* 2015;31(03):305–309
- 8 VanderBrink BA, Sivan B, Levitt MA, Peña A, Sheldon CA, Alam S. Epididymitis in patients with anorectal malformations: a cause for urologic concern. *Int Braz J Urol* 2014;40(05):676–682
- 9 Wijers CH, de Blaauw I, Marcelis CL, et al. Research perspectives in the etiology of congenital anorectal malformations using data of the International Consortium on Anorectal Malformations: evidence for risk factors across different populations. *Pediatr Surg Int* 2010;26(11):1093–1099
- 10 Khan K, Khan MJ, Khan MY. Anorectal malformations: functional outcome of posterior sagittal anorectoplasty. *J Postgrad Med Inst* 2011;22(04):304–308
- 11 Somekh E, Gorenstein A, Serour F. Acute epididymitis in boys: evidence of a post-infectious etiology. *J Urol* 2004;171(01):391–394, discussion 394
- 12 Trovalusci E, Rossato M, Gamba P, Midrio P. Testicular function and sexuality in adult patients with anorectal malformation. *J Pediatr Surg* 2020;55(09):1839–1845
- 13 Likitnukul S, McCracken GH Jr, Nelson JD, Votteler TP. Epididymitis in children and adolescents. A 20-year retrospective study. *Am J Dis Child* 1987;141(01):41–44
- 14 Siegel A, Snyder H, Duckett JW. Epididymitis in infants and boys: underlying urogenital anomalies and efficacy of imaging modalities. *J Urol* 1987;138(4 Pt 2):1100–1103
- 15 Merlini E, Rotundi F, Seymandi PL, Canning DA. Acute epididymitis and urinary tract anomalies in children. *Scand J Urol Nephrol* 1998;32(04):273–275
- 16 Umeyama T, Kawamura T, Hasegawa A, Ogawa O. Ectopic ureter presenting with epididymitis in childhood: report of 5 cases. *J Urol* 1985;134(01):131–133
- 17 Kajbafzadeh AM, Payabvash S. Endoscopic treatment of vesicovasal and vesicoureteral reflux in infants with persisting mesonephric duct. *J Urol* 2006;176(6 Pt 1):2657–2662
- 18 Gupta AD, Loeb S, Stec A, Wang MH. Unusual presentation of a Mullerian remnant in an infant with recurrent epididymo-orchitis. *Urology* 2011;78(06):1414–1416
- 19 Hester AG, Kogan SJ. The prostatic utricle: an under-recognized condition resulting in significant morbidity in boys with both hypospadias and normal external genitalia. *J Pediatr Urol* 2017;13(05):492.e1–492.e5
- 20 Carachi R, Gobara D. Recurrent epididymo-orchitis in a child secondary to a stone in the seminal vesicle. *Br J Urol* 1997;79(06):997

- 21 Gkentzis A, Lee L. The aetiology and current management of prepubertal epididymitis. *Ann R Coll Surg Engl* 2014;96(03): 181–183
- 22 Hong AR, Acuña MF, Peña A, Chaves L, Rodriguez G. Urologic injuries associated with repair of anorectal malformations in male patients. *J Pediatr Surg* 2002;37(03):339–344
- 23 Vordermark JS II. The persisting mesonephric duct syndrome: the description of a new syndrome. *J Urol* 1983;130(05): 958–961
- 24 Thind P, Gerstenberg TC, Bilde T. Is micturition disorder a pathogenic factor in acute epididymitis? An evaluation of simultaneous bladder pressure and urine flow in men with previous acute epididymitis. *J Urol* 1990;143(02):323–325
- 25 Franco I. Functional bladder problems in children: pathophysiology, diagnosis, and treatment. *Pediatr Clin North Am* 2012;59(04):783–817
- 26 Santos JD, Lopes RI, Koyle MA. Bladder and bowel dysfunction in children: an update on the diagnosis and treatment of a common, but underdiagnosed pediatric problem. *Can Urol Assoc J* 2017;11(1-2Suppl1):S64–S72
- 27 Faure A, Haddad M, Hery G, Merrot T, Guys JM. Endoscopic injection of bulking agent around the ejaculatory ducts at the verumontanum for recurrent paediatric epididymitis. *J Pediatr Urol* 2018;14(05):476–482
- 28 Kajbafzadeh AM, Shirazi M, Dianat S, Mehdizadeh M. Management of recurrent epididymitis in children: application of neurovascular sparing vas clipping in refractory cases. *J Pediatr Urol* 2011;7(05):552–558
- 29 Negri L, Albani E, Di Rocco M, Levi-Setti PE. Aspermia and chronic testicular pain after imperforate anus correction. Cryopreservation of sperm cells extracted from whole orchiectomized testis: case report. *Hum Reprod* 2002;17(11):2935–2937