



Anatomical Variations of the Sinonasal Area and Their Clinical Impact on Sinus Pathology: A Systematic Review

Anna-Maria Papadopoulou¹ Nikolaos Bakogiannis² Ioanna Skrapari³ Chris Bakoyiannis²

¹Department of Otolaryngology, Athens General Children's Hospital "Pan & Aglaia Kyriakou", Athens, Greece

²First Department of Surgery, Laikon General Hospital, Athens, Greece

³First Department of Internal Medicine, Evangelismos General Hospital, Athens, Greece

Address for correspondence Anna-Maria Papadopoulou, MD, Department of Otolaryngology, Athens General Children's Hospital "Pan. & Aglaia Kyriakou", Thivon & Levadeias Str., Goudi, 11527, Athens, Greece (e-mail: annamariadc@hotmail.com).

Int Arch Otorhinolaryngol 2022;26(3):e491–e498.

Abstract

Introduction Anatomical variations of the nasal cavity and of the paranasal sinuses are frequently encountered and play an important role in dysfunctional drainage of sinuses. However, it is not clear in the literature whether they predispose to sinus pathology.

Objectives The aim of the present review is to summarize the understanding of the association between anatomical variations of the sinonasal area and sinus pathology.

Data Synthesis The present review was conducted according to the Preferred Reporting Items for Systematic Reviews and Meta-Analysis (PRISMA) guidelines. We performed a thorough research on PubMed from October 2004 until May 2020 by using the search terms *paranasal sinus anatomical variations* and *sinus disease, sinusitis, and mucosal disease*.

Thirty studies were eligible and were included in the analysis. Overall, the studies encompassed a total of 6,999 patients included in the present review. In many studies, it has been statistically established that certain anatomical variations increase the risk of sinus disease. On the other hand, the rest of the collected studies failed to show any statistically significant correlation between anatomical variants and sinus pathology.

Conclusion The present study highlights the possible correlation between some anatomical variations of the sinonasal area and pathologies of the paranasal sinuses. Careful assessment and computed tomography (CT) in patients with chronic rhinosinusitis is needed, especially in those undergoing endoscopic surgery, to identify and treat anatomical variations in the paranasal sinuses that may be correlated with rhinosinusitis. Due to contradictory results in the literature, further research is needed to elucidate the effects of anatomical variants of the sinonasal area.

Keywords

- ▶ anatomical variations
- ▶ paranasal sinuses
- ▶ nasal cavity
- ▶ sinus pathology

received
April 22, 2021
accepted after revision
October 17, 2021
published online
January 28, 2022

DOI <https://doi.org/10.1055/s-0042-1742327>.
ISSN 1809-9777.

© 2022. Fundação Otorrinolaringologia. All rights reserved.
This is an open access article published by Thieme under the terms of the Creative Commons Attribution-NonDerivative-NonCommercial-License, permitting copying and reproduction so long as the original work is given appropriate credit. Contents may not be used for commercial purposes, or adapted, remixed, transformed or built upon. (<https://creativecommons.org/licenses/by-nc-nd/4.0/>)
Thieme Revinter Publicações Ltda., Rua do Matoso 170, Rio de Janeiro, RJ, CEP 20270-135, Brazil

Introduction

Diseases of the nasal cavity and of the paranasal sinuses are among the most common disorders encountered in otorhinolaryngology clinics.¹ Anatomical variations of this region are also frequently seen and have an important role in dysfunctional drainage of the sinuses, generally resulting in chronic sinusitis.² Inflammatory sinus disease occurs due to impaired or deranged mucociliary drainage pathways of the sinuses into the ostiomeatal complex. Theoretically, anatomical variations in the ostiomeatal complex narrows this area and then a minimal amount of mucosal edema can predispose to maxillary, ethmoid, frontal, and sphenoid sinus disease, with recurrent infection and chronic inflammatory changes in the mucosa.² Functional endoscopic sinus surgery (FESS) has become a popular technique, being applied in chronic and recurrent sinusitis in recent years.¹ In FESS, a minor manipulation of these key sites in the lateral nasal wall helps to resolve enormous pathologies in the sinuses.² Although the effects of anatomical variations on sinus diseases have been widely investigated, any consensus regarding their role in the etiology of sinus pathology seems to be remote.³ The aim of the present review is to summarize the understanding of the association between anatomical variations of the sinonasal area and sinus pathology.

Review of the Literature

Materials and Methods

The present systematic review was performed in accordance with the Preferred Reporting Items for Systematic Reviews and Meta-Analyses (PRISMA) guidelines. Eligible articles were identified by a search in the PubMed bibliographical database for the period from October 2004 to May 2020. All coauthors agreed on the study protocol. The search strategy included the following keywords: (*paranasal sinus anatomical variations* AND (*sinus disease* OR *sinusitis*)). Two investigators (Papadopoulou A-M. and Bakogiannis N.), working independently, searched the literature and extracted data from each eligible study. All prospective and retrospective studies, as well as case reports, were eligible for the present systematic review. In addition, we checked all the references of relevant reviews and eligible articles that our search retrieved, so as to identify potentially eligible conference abstracts. Titles of interest were further reviewed by reading of their abstracts. Moreover, reference lists of eligible studies were manually assessed to detect any potential relevant article (“snowball” procedure). Language restrictions were applied (only articles in English, French, and German were considered eligible). Reviews were not eligible, while manuscripts that did not state the names of the authors were also excluded.

Article Selection and Study Demographics

The search strategy retrieved 93 articles that were evaluated for full-text evaluation. Thirty studies were deemed eligible and were included in the analytic cohort. Overall, the studies encompassed a total of 6,999 patients, who have been included in the present systematic review. The search strategy is depicted in ► Fig. 1.

Clinical Conditions

Chronic rhinosinusitis (CRS) is defined by inflammation of the paranasal sinus mucosa persisting for at least 3 months. Chronic sinusitis has many causes, including infections, allergies, anatomical abnormalities, defects of immunity, and disorders of mucociliary transport.⁴ It is thought that, in some CRS cases, structural or anatomical factors predispose patients to the disease process because of compromise or narrowing of the outflow tract(s) of the sinus in question. Such anatomical factors block the adequate aeration of the paranasal sinuses, which is necessary for healthy mucosa maintenance, and lead to mucosal thickening and retained fluid in the sinuses.⁵ Currently, the initial treatment for uncomplicated CRS is conservative medical therapy, including antibiotics and corticosteroids. Surgical intervention with endoscopic sinus surgery is considered if appropriate medical therapies fail.⁶ The most common symptoms include post or anterior nasal discharge, headache and facial pains, nasal obstruction, sneezing, and epistaxis.⁷

Chronic rhinosinusitis has been classified as occurring in two predominant forms: chronic (persistent) rhinosinusitis and recurrent acute rhinosinusitis (RARS).⁸ Recurrent acute rhinosinusitis is clinically defined as the occurrence of > 4 acute rhinosinusitis (ARS) events within a 12-month period.⁹ Patients with RARS manifest similar levels of sinonasal symptomatology and overall disease burden as those with standard CRS. Despite its significant health burden, the pathophysiology and underlying risk factors that predispose certain patients to RARS is not well understood, with host, infectious, and environmental factors potentially implicated. The impact of anatomical variants as a predisposing factor in RARS has not been completely investigated.⁹ With continually evolving technologies for sinus surgery, there has been a renewed interest in RARS. Preliminary data suggest that appropriately selected patients with verified RARS may respond favorably to endoscopic sinus surgery.⁸

Another clinical condition that is discussed in one of the collected studies is barosinusitis. Sinus barotrauma occurs because the relatively rigid walls of the sinus cavity cannot expand or contract in response to pressure changes in accordance with the Boyle’s Law. The resultant sinus squeeze and counter squeeze can produce pain.¹⁰

Analytical Description

In many studies, it has been statistically established that certain anatomical variations increase the risk of sinus disease. In particular, Fadda et al. found a statistically significant association between the presence of common anatomical variations – septal deviation, bilateral concha bullosa, medial deviation of the uncinat process, haller cell, hypertrophic ethmoidal bulla, agger nasi cell – and the presence of sinus mucosal disease ($p < 0.05$).¹¹ Similar results were obtained by three other studies.^{1,12,13} Mendiratta et al. found a statistically significant correlation between septal deviation, concha bullosa, and paradoxical middle turbinate and maxillary sinusitis, as well as between medial deviation of the uncinat process and anterior ethmoid sinusitis.⁷ Sedaghat et al. found a statistically significant association between the presence of Haller cells and

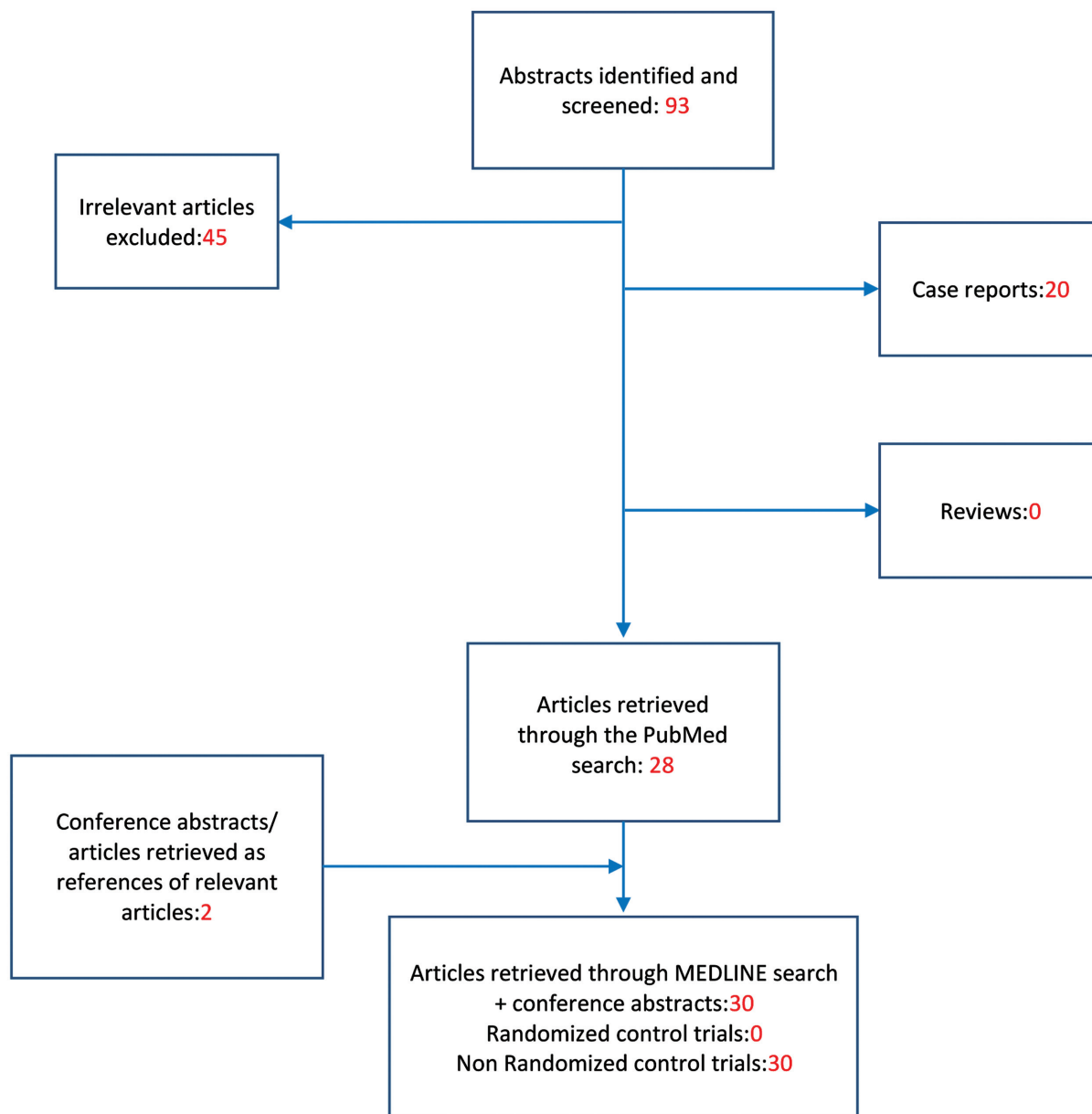


Fig. 1 Flowchart of the search strategy.

frontal intersinus cells with the development of CRS.⁶ As far as frontal recess cells are concerned, two studies concluded that the presence of recess terminalis, suprabullar, supraorbital,¹⁴ and frontal bullar cells^{14,15} was significantly associated with the development of frontal sinusitis by multiple logistic regression models.¹⁴ Furthermore, Langille et al. revealed a significant association of frontal sinus mucosal thickening with the presence of frontal sinus cells.⁵ Regarding the accessory maxillary ostium (AMO), Bani-ata et al.¹⁶ and Yenigun et al.¹⁷ found a statistically significant correlation between the presence of accessory maxillary ostium and mucosal thickening and maxillary sinusitis, while Hung et al. concluded that morphological changes of the maxillary sinus mucosa were positively associated with the length and area of the AMO.¹⁸ Surprisingly, the presence of an AMO exhibited a negative association with endodontic pathology.¹⁸ According to Dasar et al., supraorbital ethmoid cells appear to be highly associated with and most

often are responsible for orbital proptosis in patients with CRS ($p = 0.000002$).¹² Finally, Rudmik et al. analyzed the sinonasal anatomy of patients with headache due to sinus barotrauma and concluded that the presence of a concha bullosa and sphenoidal cell (Onodi cell) appeared to predispose to headaches ($p = 0.004$). Headache patients also had larger maxillary sinus size (right, $p = 0.015$, and left, $p = 0.002$).¹⁰

On the other hand, the rest of the collected studies failed to show any statistically significant correlation between anatomical variants and sinus disease. More specifically, Kaygusuz et al. found no significant correlation between the most common anatomical variations and any pathology of the paranasal sinuses.³ According to Jain et al., the frequency of total anatomical variants in the limited anterior sinonasal disease group was significantly higher than in the diffuse pansinusitis and control groups ($p < 0.003$), but there was no significant difference in the total number of

anatomical variants between the diffuse disease and control groups. There was also no significant correlation between other common and uncommon anatomical variations and mucosal pathologies.¹⁹ According to three more studies, no association between a deviated septum or concha bullosa and the side of any sinus inflammatory disease was found.^{4,20,21} Neither Kim et al. nor Al-Qudah et al. found a significant correlation between anatomical variants and the extent of chronic sinusitis in the pediatric population; this could be attributed to the fact that anatomical variations were not large enough to cause mechanical blockage.^{22,23} Another study demonstrated that although there was no statistically significant association between any type of middle turbinate concha and sinusitis, sinusitis was more predominant with the extensive type of concha.²⁴ According to Alkire et al., despite the fact that RARS patients were more likely to manifest concha bullosa (41.7 versus 28.6%) or impinging septal spurs (27.8 versus 19.0%), these differences were not statistically significant ($p = 0.165$ and $p = 0.260$, respectively),⁸ which is in line with the results of Loftus et al.⁹ However, patients with RARS were significantly more likely to radiographically demonstrate Haller cells (39.9 versus 11.9%, respectively, $p = 0.006$).⁸ Furthermore, Tsai et al. could not demonstrate any statistically significant correlation between nasal septal deviation or concha bullosa and paranasal sinus fungus balls.²⁵ Somer et al. concluded that despite a partially strong narrowing of the frontal recess due to frontoethmoidal anatomical variations, no increased occurrence of radiological signs of opacification could be detected ($p > 0.05$).²⁶ Finally, Mathew et al. found no statistically significant association between the existence and size of Haller cells and maxillary sinusitis.²⁷

► **Table 1** illustrates the correlation between the most common anatomical variants in the sinonasal area and sinus diseases.

Discussion

Advances in the understanding of mucociliary drainage patterns and of the pathophysiology of paranasal sinus inflammatory disease, coupled with the availability of high resolution computed tomography (CT) and the improvement in endoscopic instrumentation, necessitate the clinician to have a precise knowledge of nasal sinus anatomy and its variation in this region.⁷ The extent of sinonasal inflammatory pathology, as well as of important anatomical landmarks and their variations can be easily detected on CT scan, which provides a reliable road map for endoscopic sinus surgery.⁷ Actually, Alsovey et al. have found a very good agreement between CT and endoscopy in diagnosing most anatomical variations ($p < 0.001$).²⁸ The ostiomeatal complex is a functional entity of the anterior ethmoid complex that represents the final common pathway for drainage and ventilation of the frontal, maxillary, and anterior ethmoid cells. Thus, anatomical variations that redirect nasal airflow or narrow the ostiomeatal complex have been implicated in the development of chronic rhinosinusitis.¹¹ Due to the variations in the sinonasal region, the sinus ostia or the

meatus can be narrowed or obliterated. In these situations, patients are considered to have a tendency especially for mucosal diseases of the sinonasal region.¹² Consequently, the ostiomeatal complex and the maxillary sinus were most commonly involved in most studies, followed by the anterior and posterior ethmoids, the frontal sinuses, and the sphenoids, which were minimally involved.⁷ The greater involvement of the maxillary sinus in children may be attributed to the smaller dimensions of the middle meatus, as compared with adults.^{22,23} The mucosal abnormalities were graded according to the Lund Mackay score, a widely used method for radiologic staging of chronic rhinosinusitis.²⁹

One of the most common variations of the sinonasal region is septum deviation, referring to the opening of the nasal septum to the left or the right. The prevalence of nasal septum deviation has been reported to vary from 20 to 79%.¹² The mere presence of a septal deviation does not suggest pathology. However, a marked deviation can force the middle turbinate laterally, thus narrowing the ostiomeatal complex.⁷ There are studies reporting that nasal septum deviation could lead to infection of all sinuses through contacting with hypertrophic or bullous concha, narrowing the meatus or impairing normal mucociliary activity and mucus drainage. It has also been reported that paranasal sinusitis is discovered more often on the ipsilateral side than on the contralateral side of the septal deviation.^{3,22} Still, most studies mention lack of any association between septum deviation and sinus infection. Since septal deviation is a very common variation,²⁸ it can have a role in the development of sinusitis in association with other variations.¹

Concha bullosa is a ballooned-out middle turbinate due to pneumatization. It can be associated with other abnormal structures of the ostiomeatal complex, such as septal deviation, or independently compress the middle nasal meatus and obstruct normal air passages, causing mucosal hyperemia, inflammation changes, hypertrophy, coherence, and desiccation by blocking the ethmoid infundibulum.²² The pneumatization can grow to such an extent that the bulging end of the turbinate completely fills the space between the septum and the lateral wall, resulting in the blockade to the entrance to the middle meatus.⁷ The degree of pneumatization correlates with the severity of symptoms. The lamellar type usually does not manifest any symptoms, but the bulbous and extensive types may alter the normal airflow and the mucous drainage pathways, causing edema within the middle meatus, which can lead to maxillary or ethmoid sinusitis.²³ Indeed, patients with a large concha bullosa had more extensive mucosal disease⁷ and suffered from recurrent ethmoid sinusitis.¹¹ It has also been reported that a larger superior turbinate or superior concha bullosa could lead to headache and nasal obstruction due to mucosal contact. Therefore, even in patients without signs of sinonasal infection, nasal endoscopy is recommended to determine whether the reason of complaints is mucosal contact.^{12,30} The concha bullosa, when filled with fluid and pus, rarely results in mucopyocele. Concha bullosa mucopyocele happens due to chronic obstruction of the concha bullosa ostium, which prevents the optimal air current flow between its cavity and the surrounding structures, such as the frontal

Table 1 Correlation between the most common anatomical variants in the sinonasal area and sinus diseases

Author, year	n	Disease	Parameter	p-value
Mogre et al., 2018 ³²	46	Midfacial pain	NSD/AN/CB/HC/UP	> 0.05
			PMT	0.02
Mendiratta et al., 2015 ⁷	40	Sinusitis	NSD/CB/PMT/UP	< 0.05
Loftus et al., 2016 ¹⁰	26	RARS	NSD/AN/CB/HC/FC/MSH	> 0.05
Kaygusuz et al., 2013 ³	99	Sinusitis	NSD/AN/CB/HC/PMT	> 0.05
JunKim et al., 2006 ²²	113	Sinusitis	NSD/HC/CB/AN/OC/PMT	> 0.05
Fadda et al., 2012 ¹¹	200	Sinusitis	NSD/HC/CB/AN/UP/EB	< 0.05
Dasar et al., 2016 ¹²	400	Mucosal disease	NSD/AN/CB/HC/PMT/FC/FBC	> 0.05
			UP variations/EB	< 0.005
		Orbital proptosis	SOEC	< 0.0001
Cho et al., 2011 ⁴	491	Sinusitis	NSD/CB/PMT	> 0.05
Balikci et al., 2016 ²⁰	296	Sinusitis	NSD/CB	> 0.05
Tsai et al., 2012 ²⁵	52	Fungus balls	NSD/CB	> 0.05
Stallmann et al., 2004 ²¹	998	Sinusitis	NSD/CB	> 0.05
Rudmik et al., 2009 ¹⁰	65	Barosinusitis	NSD/AN/PMT/HC/FC	> 0.05
			CB/OC	0.004
Lien et al., 2010 ¹⁴	192	Frontal sinusitis	AN/FC/FBC	> 0.05
			SBC/SOEC/RT	< 0.005
Langille et al., 2016 ⁵	399	Frontal thickening	AN/SBC/IFSC	> 0.05
			FC/FBC	< 0.005
Kubota et al., 2015 ¹⁵	150	Frontal sinusitis	AN/FC/SBC/SOEC	> 0.05
			FBC	0.043
Al-Qudah et al., 2008 ²³	65	Sinusitis	AN/CB/HC/PMT	> 0.05
Kalairasi et al., 2018 ²⁴	202	Sinusitis	CB	> 0.05
Alkire et al., 2010 ⁸	78	RARS	CB	0.165
			HC	0.006
Sedaghat et al., 2012 ⁶	24	Sinusitis	CB/FC	> 0.05
			HC/IFSC	< 0.05
Roman et al., 2015 ¹³	157	Sinusitis	CB/HC/UP	< 0.05
Mathew et al., 2013 ²⁷	50	Sinusitis	HC	> 0.05
Jain et al., 2013 ¹⁹	77	Limited CRS	Total abnormalities	< 0.002
Hung et al., 2019 ¹⁸	113	Endodontic pathology	AMO	0.028
		Maxillary sinus mucosal pathology		0.828
Bani-ata et al., 2020 ¹⁶	928	Maxillary sinusitis	AMO	0.018
Azila et al., 2011 ³¹	240	CRS	CB/PMT/NSD/AN/UP/HC	> 0.05
Selcuk et al., 2008 ³³	330	Mucosal pathology	MSS.MSH	> 0.05
Shpilberg et al., 2015 ³⁰	192	Significant CRS	Total abnormalities	> 0.05
Sommer et al., 2019 ²⁶	249	Frontal sinus opacification	Supra AN/SBC	> 0.05
Yenigun et al., 2015 ¹⁷	377	Maxillary sinusitis	AMO	0.03
		Mucosal thickening		< 0.001
		Retention cysts		< 0.001
Kaya et al., 2017 ¹	350	Sinusitis	NSD/PMT/EB	> 0.05
			AN/CB/HC/UP	< 0.001

Abbreviations: AMO, accessory maxillary ostium; AN, agger nasi cells; CB, concha bullosa; CRS, chronic rhinosinusitis; EB, ethmoid bullae; FBC, frontal bullar cells; FC, frontal cells; HC, Haller cells; IFSC, interfrontal sinus cells; MSH, maxillary sinus hypoplasia; MSS, maxillary sinus septa; n, sample size; NSD, nasal septal deviation; OC, Onodi cells; PMT, paradoxical middle turbinate; RARS, recurrent acute rhinosinusitis; RT, recess terminalis; SBC, suprabullar cells; SOEC, supraorbital ethmoid cells; UP, uncinat process.

recess, ethmoidal cells, or the middle meatus.²⁴ Mucosal thickening and polyp formation within a concha bullosa are also uncommon. The inner surface of the concha bullosa is lined with mucous membrane and any inflammatory process will incite mucosal hypertrophy and polyp formation. Usually, the concha bullosa contains only a single air cell. Multiple air cells are relatively rare, and the clinical importance of this discovery is still unclear.²⁴ The presence of concha bullosa is not associated with increased risk of sinusitis in most of the collected studies. However, in one study, sinus disease was detected more often in patients with bulbous and extensive type.²⁰ Additionally, it is unknown how concha bullosa may contribute to sinus barotrauma and related facial pain. An explanation could be that it increases the relative volume of the sinonasal cavity. This may increase the intensity of the squeeze and counter squeeze during pressure changes.¹⁰

The medial convexity that a normal middle concha possesses has a paradoxical configuration in some cases.¹ This anomaly consists of a reversal of the normal outward concavity of the middle turbinate. The inferior edge of the middle turbinate may have various shapes, with excessive curvature, which, in turn, may obstruct the nasal cavity, the infundibulum, and the middle meatus.⁷ In most studies, a clear association with sinusitis is not detected. These findings showed that presence of paradoxical middle concha could not simply participate in the etiology of chronic rhinosinusitis. Nevertheless, the size and degree of the convexity of the middle turbinate may be an important factor to cause the obstruction that will lead to rhinosinusitis.^{30,31} Only few of the cases with this variation presented mucosal inflammation throughout the literature; some of them on the contralateral site, not proving to have any implication in the presence of mucosal inflammation.¹³ Moreover, in one study, midfacial segment pain was statistically correlated with the presence of paradoxical middle turbinate.³²

Hyperpneumatized ethmoid bulla is excessive pneumatization of ethmoid bulla, the largest and least varying cell of frontal ethmoid cells. Hyperpneumatized ethmoid bulla is located between the middle concha and the uncinate process and could displace the uncinate process toward medial. It has been associated with mucosal disease.¹²

The uncinate process was largely studied, being a major part of the ostiomeatal unit that allows air flow and also mucus drainage. Morphological variations of this hook-like process, which forms the anterior part of the hiatus semilunaris, can be a factor of narrowing the unit, thus blocking the drainage and consequently producing inflammation.¹³ It has been considered that medial deviation of the uncinate process can obstruct the middle meatus, while lateral deviation can obstruct the infundibulum.¹ It has also been suggested that the angle of the deviation of the uncinate process is related to maxillary and ethmoidal sinusitis.¹ In particular, Fadda et al. showed that medial deviation of the uncinate process was statistically associated with anterior ethmoidal sinusitis.¹¹ Pneumatization of the uncinate process (uncinate bulla) refers to an aeration of air cells into the uncinate process. The uncinate process projects from the ethmoid bone to the ethmoid process of the inferior

nasal concha. This entity is rarely observed when compared with the other sinonasal anatomical variations.³ Authors think that pneumatized uncinate process can cause significant functional blockage of the ostiomeatal complex. Therefore, it is considered as a predisposing factor for the development of sinusitis in the anterior ethmoid and frontal cells, disrupting the sinus ventilation at the infundibular region,³ which is statistically proven in most studies. Azila et al. emphasize that the severity of the degree of medialization of the uncinate process (causing mucosal contact with the middle turbinate or covering up the ostium of the maxillary sinus) and the presence of some other anatomical variation, such as Haller cells, may be an important associated factor that may increase pathogenic effects that lead to CRS rather than the presence of this variation alone.³¹

When the uncinate process inserts into the lamina papyracea, the ethmoid infundibulum is closed superiorly to form a blind pouch called the terminal recess (recessus terminalis, or RT). The lack of an anatomical barrier between the frontal recess and the middle meatus against ascending irritants, allergens, and rhinogenic infections explains the possible correlation between the presence of RT and frontal sinusitis.¹⁴

Haller cells (or infraorbital cells) are developed along the middle turbinate adhesion and the exterior wall of the nasal cavity and are usually located on the lateral side of the ethmoid infundibulum.²² These ethmoid cells may grow into the floor of the orbit and may narrow the adjacent ostium of the maxillary sinus, especially if they become infected and enlarged.^{3,7} Haller cells have been implicated as a possible etiologic factor in CRS due to their negative influence on maxillary sinus ventilation by narrowing the infundibulum and the ostium depending on its degree of pneumatization and size.³⁰ Furthermore, several radiographic studies have shown a significant relationship between the size of Haller cells (> 3 mm) and maxillary sinusitis.^{23,27}

The pathophysiology of frontal sinusitis is associated with ventilation of the sinus via the sinus ostium. The size of the frontal sinus ostium is key to frontal sinus drainage. Generally, frontal recess cells and their inflammation can influence frontal sinus ventilation by narrowing the frontal sinus drainage pathway.¹⁵

The agger nasi cell is a structure located in the lateral nasal wall in front of or over a place where the middle turbinate is situated. It is generally located bilaterally, and it narrows the frontal recess depending on its pneumatization level.¹² Its effect on the drainage way of the frontal sinus has been widely discussed.³ The agger nasi cells have been associated with a high rate of sinusitis, which is attributed to the drainage of the frontal recess.¹ Even when not diseased, they may narrow the frontal recess depending on their pneumatization and may completely block it when diseased.⁷ Actually, agger nasi cell air disease correlates strongly with frontal sinus disease as assessed by sinus CT scan in patients undergoing revision FESS.¹⁴

Frontal sinus cells are clinically significant anatomical structures, which can impact proper frontal sinus drainage and aeration.⁵ The significance of the correlation between

type 2 frontal cells and RARS is also unclear and suggests a possible predisposing cofactor.⁹

Suprabullar cells may obstruct the frontal recess posteriorly, as do frontal bullar cells, but this has not been definitely elucidated in the literature.¹⁴ It is also assumed that the existence of supraorbital ethmoid cells might narrow the frontal sinus drainage pathway and produce significant obstruction.¹⁴

Maxillary sinus hypoplasia (MSH) is the most important anatomical variation among those involving the maxillary sinus and is associated with mucosal pathology.¹¹ The accompanying anterior ethmoid cell anomalies may cause drainage problems or surgical complications, while thickening of the sinus wall may be confused with chronic sinusitis. Maxillary sinus hypoplasia may also lead to dental problems by causing canine fossa elevation and could clinically lead to silent sinus syndrome by causing hypogloba and enophthalmos. Lastly, patients may present to the ophthalmology department complaining of orbital asymmetry and double vision.³³

The accessory maxillary ostium (AMO) is regarded as any extra opening other than the primary ostium and is usually present in the region of the nasal fontanelle or of the hiatus semilunaris. The presence of an AMO not only enables an increase of the ventilation rate of the maxillary sinus, but also leads to an inverse drainage from the middle meatus into the sinus. This results in a reduced nitric oxide concentration and in mucus accumulation in the sinus, which possibly contributes to pathological changes such as mucosal thickening, mucous retention cyst formation, and maxillary sinusitis.¹⁸ Conversely, the greater frequency of AMO in patients with a previous history of multiple episodes of maxillary sinusitis suggests that accessory ostia may occur as a consequence of pathology.¹⁶ A possible mechanism for the development of accessory ostia is impediment of the main ostium by mucosal edema due to chronic sinusitis or to other anatomical or pathological factors in the middle meatus that lead to rupture of the membranous part of the lateral nasal wall. Fontanelle defects and formation of accessory ostia could serve to maintain chronic inflammation of the maxillary sinus by permitting mucus recirculation between adjacent openings.¹⁶ Moreover, Yenigun et al. observed mucus retention cysts more often in patients with AMO. This result indicates that there might have been an increased combination of retention cyst, mucosal thickening, and accessory ostium that develop as complications following maxillary sinusitis. Retention cysts may result in symptoms such as headache, facial pain in the sinus areas, and symptoms related to postnasal drainage and nasal drainage.¹⁷

The results from the collected studies diverge and the clinical significance of anatomical variations in the sinonasal area is still in question. There might be several causes for this discrepancy. For example, studies differ from each other mainly due to study design. It can be assumed that most studies conducted on both symptomatic patients and healthy controls^{3,4,6,8,10,15,19,25} have found a strong relationship between anatomical variants and sinonasal pathology, while most studies conducted on symptomatic patients only

have concluded that there is no such significant relationship.^{1,5,7,9,11,13,14,16–18,20–24,26,27} Moreover, patients with clinically significant sinusitis may have no or minimal evidence of sinusitis, such as mucosal thickening, at imaging. It is also possible that patients with CT scans showing no or minimal evidence of sinus inflammation may have had significant sinusitis on previous CT scans that improved or resolved even though they continued to experience sinusitis symptoms.³⁰ Another cause is that not all studies discuss the same pathology; Tsai et al. concluded from their findings that it is possible for the pathogenesis of paranasal fungus balls to be different from that of bacterial rhinosinusitis, that is, the ostiomeatal complex may be sufficiently patent so as to provide an entrance for fungal spores in the process of fungus ball formation.²⁵

Definitely, CRS is a multifactorial disease and combinations of risk factors may have an impact on the process of the disease.⁹ Authors who showed no specific association of anatomical variations with rhinosinusitis claimed that local, systemic, and environmental factors or intrinsic mucosal disease were more significant in the pathogenesis of rhinosinusitis. Our study is consistent with previous conclusions that the role of anatomical variations in predisposition to sinonasal pathology is under investigation. We believe that sinus inflammation is caused by multiple factors, including anatomical variations, mucosal inflammation, upper respiratory tract infection, allergic rhinitis, adenoid hypertrophy, impaired immunity, gastroesophageal reflux disease, and environmental factors. These factors will jointly determine the effect on the development of sinus pathology.

Final Comments

The results of the present review highlight the possible correlation between some anatomical variations of the sinonasal area and pathologies of the paranasal sinuses. The present investigation also reinforces the fact that careful assessment and CT in patients with chronic rhinosinusitis is needed, especially in those undergoing endoscopic surgery, to identify the presence of anatomical variations in the paranasal sinuses that may be correlated with rhinosinusitis. This also helps to identify and treat variations that may be associated with persistence or recurrence of disease, with a favorable long-term prognosis following reversal of the anatomical obstruction.^{11,19} Finally, due to contradictory results in the literature, further research is needed to elucidate the effects of anatomical variants of the sinonasal area.

Conflict of Interests

The authors have no conflict of interests to declare.

References

- 1 Kaya M, Çankal F, Gumusok M, Apaydin N, Tekdemir I. Role of anatomic variations of paranasal sinuses on the prevalence of sinusitis: Computed tomography findings of 350 patients. *Niger J Clin Pract* 2017;20(11):1481–1488
- 2 Mokhasanavisu VJP, Singh R, Balakrishnan R, Kadavigere R. Ethnic Variation of Sinonasal Anatomy on CT Scan and Volumetric

- Analysis. *Indian J Otolaryngol Head Neck Surg* 2019;71(3, Suppl 3):2157–2164
- 3 Kaygusuz A, Haksever M, Akduman D, Aslan S, Sayar Z. Sinonasal anatomical variations: their relationship with chronic rhinosinusitis and effect on the severity of disease—a computerized tomography assisted anatomical and clinical study. *Indian J Otolaryngol Head Neck Surg* 2014;66(03):260–266
 - 4 Cho JH, Park MS, Chung YS, Hong SC, Kwon KH, Kim JK. Do anatomic variations of the middle turbinate have an effect on nasal septal deviation or paranasal sinusitis? *Ann Otol Rhinol Laryngol* 2011;120(09):569–574
 - 5 Langille M, Walters E, Dziegielewski PT, Kotylak T, Wright ED. Frontal sinus cells: identification, prevalence, and association with frontal sinus mucosal thickening. *Am J Rhinol Allergy* 2012;26(03):e107–e110
 - 6 Sedaghat AR, Gray ST, Wilke CO, Caradonna DS. Risk factors for development of chronic rhinosinusitis in patients with allergic rhinitis. *Int Forum Allergy Rhinol* 2012;2(05):370–375
 - 7 Mendiratta V, Baisakhiya N, Singh D, Datta G, Mittal A, Mendiratta P. Sinonasal Anatomical Variants: CT and Endoscopy Study and Its Correlation with Extent of Disease. *Indian J Otolaryngol Head Neck Surg* 2016;68(03):352–358
 - 8 Alkire BC, Bhattacharyya N. An assessment of sinonasal anatomic variants potentially associated with recurrent acute rhinosinusitis. *Laryngoscope* 2010;120(03):631–634
 - 9 Loftus PA, Lin J, Tabaei A. Anatomic variants of the paranasal sinuses in patients with recurrent acute rhinosinusitis. *Int Forum Allergy Rhinol* 2016;6(03):328–333
 - 10 Rudmik L, Muzychuk A, Oddone Paolucci E, Mechor B. Chinook wind barosinusitis: an anatomic evaluation. *Am J Rhinol Allergy* 2009;23(06):e14–e16
 - 11 Fadda GL, Rosso S, Aversa S, Petrelli A, Ondolo C, Succo G. Multi-parametric statistical correlations between paranasal sinus anatomic variations and chronic rhinosinusitis. *Acta Otorhinolaryngol Ital* 2012;32(04):244–251
 - 12 Dasar U, Gokce E. Evaluation of variations in sinonasal region with computed tomography. *World J Radiol* 2016;8(01):98–108
 - 13 Roman RA, Hedeşiu M, Gersak M, Fidan F, Băciuş G, Băciuş M. Assessing the prevalence of paranasal sinuses anatomical variants in patients with sinusitis using Cone Beam Computer Tomography. *Clujul Med* 2016;89(03):419–421
 - 14 Lien CF, Weng HH, Chang YC, Lin YC, Wang WH. Computed tomographic analysis of frontal recess anatomy and its effect on the development of frontal sinusitis. *Laryngoscope* 2010;120(12):2521–2527
 - 15 Kubota K, Takeno S, Hiraoka K. Frontal recess anatomy in Japanese subjects and its effect on the development of frontal sinusitis: computed tomography analysis. *J Otolaryngol Head Neck Surg* 2015;44(01):21
 - 16 Bani-Ata M, Aleshawi A, Khatatbeh A, et al. Accessory Maxillary Ostia: Prevalence of an Anatomical Variant and Association with Chronic Sinusitis. *Int J Gen Med* 2020;13:163–168
 - 17 Yenigun A, Fazliogullari Z, Gun C, Uysal II, Nayman A, Karabulut AK. The effect of the presence of the accessory maxillary ostium on the maxillary sinus. *Eur Arch Otorhinolaryngol* 2016;273(12):4315–4319
 - 18 Hung K, Montalvao C, Yeung AWK, Li G, Bornstein MM. Frequency, location, and morphology of accessory maxillary sinus ostia: a retrospective study using cone beam computed tomography (CBCT). *Surg Radiol Anat* 2020;42(02):219–228
 - 19 Jain R, Stow N, Douglas R. Comparison of anatomical abnormalities in patients with limited and diffuse chronic rhinosinusitis. *Int Forum Allergy Rhinol* 2013;3(06):493–496
 - 20 Balikci HH, Gurdal MM, Celebi S, Ozbay I, Karakas M. Relationships among concha bullosa, nasal septal deviation, and sinusitis: Retrospective analysis of 296 cases. *Ear Nose Throat J* 2016;95(12):487–491
 - 21 Stallman JS, Lobo JN, Som PM. The incidence of concha bullosa and its relationship to nasal septal deviation and paranasal sinus disease. *AJNR Am J Neuroradiol* 2004;25(09):1613–1618
 - 22 Kim HJ, Jung Cho M, Lee JW, et al. The relationship between anatomic variations of paranasal sinuses and chronic sinusitis in children. *Acta Otolaryngol* 2006;126(10):1067–1072
 - 23 Al-Qudah M. The relationship between anatomical variations of the sino-nasal region and chronic sinusitis extension in children. *Int J Pediatr Otorhinolaryngol* 2008;72(06):817–821
 - 24 Kalaiarasi R, Ramakrishnan V, Poyyamoli S. Anatomical Variations of the Middle Turbinate Concha Bullosa and its Relationship with Chronic Sinusitis: A Prospective Radiologic Study. *Int Arch Otorhinolaryngol* 2018;22(03):297–302
 - 25 Tsai TL, Lan MY, Ho CY. There is no structural relationship between nasal septal deviation, concha bullosa, and paranasal sinus fungus balls. *ScientificWorldJournal* 2012;2012:181246
 - 26 Sommer F, Hoffmann TK, Harter L, et al. Incidence of anatomical variations according to the International Frontal Sinus Anatomy Classification (IFAC) and their coincidence with radiological signs of opacification. *Eur Arch Otorhinolaryngol* 2019;276(11):3139–3146
 - 27 Mathew R, Omami G, Hand A, Fellows D, Lurie A. Cone beam CT analysis of Haller cells: prevalence and clinical significance. *Dentomaxillofac Radiol* 2013;42(09):20130055
 - 28 Alsowey AM, Abdulmonaem G, Elsammak A, Fouad Y. Diagnostic Performance of Multidetector Computed Tomography (MDCT) in Diagnosis of Sinus Variations. *Pol J Radiol* 2017;82:713–725
 - 29 Lund VJ, Mackay IS. Staging in rhinosinusitis. *Rhinology* 1993;31(04):183–184
 - 30 Shpilberg KA, Daniel SC, Doshi AH, Lawson W, Som PM. CT of Anatomic Variants of the Paranasal Sinuses and Nasal Cavity: Poor Correlation With Radiologically Significant Rhinosinusitis but Importance in Surgical Planning. *AJR Am J Roentgenol* 2015;204(06):1255–1260
 - 31 Azila A, Irfan M, Rohaizan Y, Shamim AK. The prevalence of anatomical variations in osteomeatal unit in patients with chronic rhinosinusitis. *Med J Malaysia* 2011;66(03):191–194
 - 32 Mogre D, Banhegyi G, Tsang HK, Leong SC. Anatomical variants of the paranasal sinuses in patients with mid-facial segment pain: Our experience of a cohort of twenty-three patients. *Clin Otolaryngol* 2018;43(05):1410–1414
 - 33 Selcuk A, Ozcan KM, Akdogan O, Bilal N, Dere H. Variations of maxillary sinus and accompanying anatomical and pathological structures. *J Craniofac Surg* 2008;19(01):159–164