Article published online: 2022-04-25

Outcomes of Extended Curettage with and without Bone Allograft for Grade II Giant Cell Tumors around the Knee. A Retrospective Comparative Study

Resultados da curetagem estendida com e sem aloenxerto ósseo para tumores de células gigantes de grau II no joelho. Um estudo comparativo retrospectivo

Badaruddin Sahito[1] Sheikh Muhammad Ebad Ali[1] Bushra Majid[1] Muhammad Soughat Katto[1] Asif Jatoi[1] Syed Jahanzeb[1]

[1] Department of Orthopedics, Dr Ruth KM Pfau Civil Hospital Karachi, Pakistan

Rev Bras Ortop 2023;58(1):141–148.

Address for correspondence Sheikh Muhammad Ebad Ali, Medical Officer, Dr Ruth KM Pfau, Civil Hospital Karachi, Orthopedics Surgery Baba e Urdu Road, Saddar, Karachi 74400, Pakistan (e-mail: sheikh.muhammadebadali14@dmc.duhs.edu.pk).

Abstract

Objective This is the first study to establish the utility of extended curettage with or without bone allograft for Grade II giant cell tumors GCTs around the knee joint with the aim of exploring postoperative functional outcomes.

Methods We retrospectively reviewed 25 cases of Campanacci grade II GCTs undergoing extended curettage between January 2014 and December 2019. The participants were divided into two groups: one group of 12 patients underwent extended curettage with bone allograft and bone cement, while the other group of 13 patients underwent extended curettage with bone cement only. Quality of life was assessed by the Revised Musculoskeletal Tumor Society Score and by the Knee score of the Knee Society; recurrence and complications were assessed for each cohort at the last follow-up. The Fisher test and two-sample t-tests were used to compare the categorical and continuous outcomes, respectively.

Results The mean age was 28.09 (7.44) years old, with 10 (40%) males and 15 females (60%). The distal femur and the proximal tibia were involved in 13 (52%) and in 12 (48%)

Keywords
- giant cell tumors
- bone grafting
- bone cementing
- extended curettage
- knee/surgery

Work developed at Department of Orthopaedics Dr Ruth KM Pfau, Civil Hospital Karachi, Pakistan.

received
August 12, 2021
accepted after revision
November 22, 2021
article published online
April 25, 2022

DOI https://doi.org/10.1055/s-0042-1742603.
ISSN 0102-3616.

© 2022. Sociedade Brasileira de Ortopedia e Traumatologia. All rights reserved.
This is an open access article published by Thieme under the terms of the Creative Commons Attribution-NonDerivative-NonCommercial-License, permitting copying and reproduction so long as the original work is given appropriate credit. Contents may not be used for commercial purposes, or adapted, remixed, transformed or built upon. (https://creativecommons.org/licenses/by-nc-nd/4.0/)
Thieme Revinter Publicações Ltda., Rua do Matoso 170, Rio de Janeiro, RJ, CEP 20270-135, Brazil

patients, respectively. There was no significant difference in the musculoskeletal tumor society score (25.75 versus 27.41; $p = 0.178$), in the knee society score (78.67 versus 81.46; $p = 0.33$), recurrence (0 versus 0%; $p = 1$), and complications (25 versus 7.69%; $p = 0.21$).

Conclusions Extended curettage with or without bone allograft have similar functional outcomes for the knee without any major difference in the incidence of recurrence and of complications for Grade II GCTs. However, surgical convenience and cost-effectiveness might favor the bone cement only, while long-term osteoarthritis prevention needs to be investigated to favor bone allograft.

Resumo

Objetivo Este é o primeiro estudo a estabelecer a utilidade da curetagem estendida com ou sem enxerto ósseo em tumores de células gigantes (TCGs) de grau II na articulação do joelho com o objetivo de explorar os resultados funcionais pós-operatórios.

Métodos Revisamos retrospectivamente 25 casos de TCGs de grau II de Campanacci submetidos a curetagem estendida entre janeiro de 2014 e dezembro de 2019. Os participantes foram divididos em 2 grupos: um grupo de 12 pacientes foi submetido a curetagem estendida com aloenxerto ósseo e cimento ósseo, enquanto o outro grupo, com 13 pacientes, foi submetido a curetagem estendida apenas com cimento ósseo. A qualidade de vida foi avaliada pela Pontuação Revista da Musculoskeletal Tumor Society (MTS, na sigla em inglês) e pela Pontuação da Knee Society (KS, na sigla em inglês), enquanto as taxas de recidiva e complicações foram avaliadas em cada coorte na última consulta de acompanhamento. O teste de Fisher e os testes t de duas amostras foram usados para comparação de resultados categóricos e contínuos, respectivamente

Resultados A média de idade dos pacientes foi de 28,09 (7,44) anos; 10 (40%) pacientes eram do sexo masculino e 15 (60%) pacientes eram do sexo feminino. O fêmur distal e a tíbia proximal foram acometidos em 13 (52%) e 12 (48%) dos pacientes, respectivamente. Não houve diferença significativa na pontuação revista da MTS (25,75 *versus* 27,41; $p = 0,178$), na pontuação da KS (78,67 *versus* 81,46; $p = 0,33$) e nas taxas de recidiva (0 *versus* 0%; $p = 1$) e complicações (25 *versus* 7,69%; $p = 0,21$).

Conclusões A curetagem estendida com ou sem aloenxerto ósseo tem resultados funcionais semelhantes em pacientes com TCGs de grau II no joelho, sem qualquer diferença importante na incidência de recidivas e complicações. No entanto, a conveniência cirúrgica e o custo-benefício podem favorecer a utilização apenas de cimento ósseo, enquanto a prevenção da osteoartrite em longo prazo precisa ser investigada para favorecer o enxerto ósseo.

Palavras-chave
- tumores de células gigantes
- enxerto ósseo
- cimento ósseo
- curetagem estendida
- joelho/cirurgia

Introduction

Giant cell tumor (GCT) of the bone is a benign primary bone tumor. However, it is highly aggressive and rarely metastasizes.[1] With the knee being the most frequent site, it usually manifests in the third and fourth decades of life with a slight female preponderance.[2] On a plain radiograph, GCT has a characteristic radiolucent expansile cystic appearance in epiphyseal or metaphysical regions. Hence, a radiological classification of GCT was described by Campanacci et al.[3] Histologically, it is diagnosed by the presence of multinucleated giant cells derived from the activation of receptor activator nuclear factor K-B ligand (RANKL). Usually, it is heralded by pain, swelling, mass or inability to bear weight.

Giant cell tumors pose therapeutic challenges due to variable outcomes, necessitating longer follow-ups and revision surgeries. Grade III GCTs are treated with wide margin resection and reconstruction.[4] However, there is no widely accepted agreement regarding a method selection for the ideal treatment of Grade I and II GCT and it may result in discrepancies in management plans among the surgeons.[5] Curettage, wide excision, and Denosumab have all been commonly employed for the treatment of Grade I and II GCT under previous studies.[2] Extended curettage remained the preferred option for Grade I and II GCT due to least postoperative morbidity, cost-effectiveness, and surgical convenience.

Due to extensive curettage for GCT, the larger bone defect remained a matter of concern among surgeons. A difference

 © 2022. Sociedade Brasileira de Ortopedia e Traumatologia. All rights reserved.

of opinion stems in terms of using bone cement with or without bone allograft to fill the defect after curettage and achieve better results. Various studies have been conducted to compare different methods used for treating and reconstructing the defect, which also aimed to minimize the incidence of recurrence and metastasis.[6] While studies have evaluated the outcomes of GCT treated with bone allografts for the radius, the humerus and metacarpals, similar articles for knee GCT have been unfrequently published.[7,8] During our literature review, a study by Saibaba et al.[9] showed the use of bone allograft for GCT around the knee, but the study design was single-armed and Grade III GCTs were also included, while another study by Datta et al.[10] coupled the allograft with arthrodesis. To the best of our knowledge, according to our literature review, this is the first study to establish the utility of extended curettage with or without bone allograft for Grade II GCT around the knee joint with the aim of exploring postoperative outcomes.

Materials and Methods

Study Design

We retrospectively reviewed record files of patients from the Orthopedic Surgery Department of a tertiary care hospital who were treated between January 2014 and December 2019. The patient data included their name, age, diagnosis with radiographs and biopsy reports, bone involved, management, status at the last follow-up, and contact for correspondence. Following the Declaration of Helsinki, the second author contacted each patient individually to obtain a signed informed consent form before the registration process.

Inclusion and Exclusion Criteria

We included patients who had a diagnosis of Campanacci grade II GCT around the knee joint, including the distal femur and the proximal tibia, which were proven by biopsy evaluation and had received extended curettage. The included study population was stratified into two cohorts according to the use of bone allograft with extended curettage. All patients who were treated by extended curettage and did not receive bone allograft but only bone cement was stratified into the "non-bone allograft" group while all patients who were treated by extended curettage and received bone allograft with bone cement were included in "bone allograft group". Patients who were skeletally immature or their age was missing in the records were excluded. We also excluded patients who had primary and secondary malignant GCT, who were lost to follow-up before 24 months, who had grade I or III GCT, and any recurrent giant cell tumor after curettage.

Study Population

We retrospectively recovered 70 patients with GCT from the hospital records. Out of 70 patients, 25 candidates fulfilled the inclusion and exclusion criteria. The mean age was 28.09 (7.44) years with 10 (40%) males and 15 females (60%). According to the bone involvement, the distal femur and the proximal tibia were involved in 13 (52%) and in 12 (48%) patients, respectively. The mean follow-up duration was 3.1 (1.7) years, ranging from 2 years to 5 year. The comparison of groups is shown in ►**Table 1**. Follow-up details were documented on progress charts with radiographs for each patient individually. They were also documented for reappearance of signs and symptoms of GCT clinically and radiographically. The histopathology report of the biopsy was reviewed at the first follow-up.

Surgical Technique

After consent and counseling and under aseptic measures, a medial or lateral incision was made according to the site of the tumor, and a cortical window around the GCT was made for curettage. After curettage, burring was used to clear the remaining tumor and to level the surface. Once the surface became smooth and tumor-free, cauterization was used to burn the micro tumor particles. The site was then washed with hydrogen peroxide and saline before further assessment of articular cartilage and the remaining subchondral bone. In the patients in whom no subchondral bone was left after an extensive curettage, we took chips of femoral head allograft and impacted them in the subchondral part. 7.3 mm titanium screws or T-locking plate or distal femur locking plate along with bone cement were used to augment the construct. These patients were stratified to the bone allograft

Table 1 Baseline study characteristics comparison of Bone Allograft with non- Bone Allograft group

	Bone Allograft	Non-Bone Allograft	*p-value*
Number of patients (n)	12 (48%)	13 (52%)	–
Age in mean (years old)**	27.67 (5.43)	28.15 (5.08)	0.81
Gender*	5:7 (41.67%: 58.33%)	5 :8 (38.46%: 61.53%)	0.87
Bone involved*			
Distal Femur	6 (50%)	7 (53.85%)	0.88
Proximal Tibia	6 (50%)	6 (46.15%)	0.88
Follow-up in years**	2.2 (1.8)	3.5 (3.2)	0.23

**Mean (standard deviation)
*Frequency (sercentage)
Follow-up range: 2 to 5 years

 © 2022. Sociedade Brasileira de Ortopedia e Traumatologia. All rights reserved.

group. Patients with sufficient subchondral bone were treated with extended curettage and bone cement and were supported with screws or plate. These patients were stratified into the non-bone allograft group. The wound was closed in layers. The technique is shown in ►**Fig. 1**.

Early knee movement was encouraged postoperatively, and weight bearing was resumed once the patients were able to tolerate it. Stitches were removed after 2 weeks and patients were followed-up fortnightly for 3 months, then monthly for 6 months, then every 3 months for 2 years and, subsequently, biannually. On each visit, knee movements were assessed and documented on follow-up charts.

Comparative Outcomes Analysis

Our primary end point was postoperative functional outcome of the treated knee on the last follow-up, ranging from 2 years to 5 years, assessed via the Knee score of the Knee Society Score, where 0–25 means poor results; 26–50 means fair results; 51–75 means good results, and 76–100 means excellent results. The Revised Musculoskeletal Tumor Society Score for lower extremity was employed, where 0–7 means poor result; 8–14 means fair results; 15–22 means good results; and > 22 means excellent results. The secondary end points were to determine the incidence of recurrence and of complications, including wound infections, deep infections, postoperative fractures, and early-arthritis.

Statistical Analysis

All descriptive statistics are represented as means with standard deviations (SDs) for continuous variables. Categorical variables are presented as frequencies with percentages. Comparisons of baseline characteristics and outcomes between the two groups are made by either the independent sample t-test for the continuous variables or the Fisher exact test for two categorical variables with a confidence interval (CI) of 95% for both according to the statistically small sample size.[11] Data was analyzed using IBM SPSS Statistics for Windows, version 22.0 (IBM Corp., Armonk, NY, USA) and XLSTAT software. All the baseline study characteristics are categorical variables, except age, which is a continuous variable. The knee score of the Knee Society Score and of the Revised Musculoskeletal Tumor Society Score are continuous variables, while the incidence of recurrence and complications are categorical variables.

Results

No statistical difference was observed between the bone allograft and non-bone allograft groups in terms of age (27.67 [5.43] versus 28.15 [5.08]; $p = 0.81$) gender (5:7 [41.67%: 58.33%] versus 5:8 [38.46%: 61.53%]; $p = 0.87$]; distal femur (6 [50%] versus 7 [53.85%]; $p = 0.88$), proximal tibia (6 [50%] versus 6 [46.15%]; $p = 0.88$], and mean follow-up (2.2 [1.8] versus 3.5 [3.2]; $p = 0.23$], as shown in ►**Table 1**.

Revised Musculoskeletal Tumor Society Score

According to the Revised Musculoskeletal Tumor Society Score, there was no statistically significant difference between the bone allograft group and the non-bone allograft group (26.25 versus 26.15; $p = 0.93$). In the bone allograft group, two patients reported intermediate functions, while three patients were using support intermediately. All patients were walking without limitations except for one patient, who had intermediate limitation while walking on slopes. In the non-bone allograft group, one patient had intermediate limb functions while three patients were using intermediate supports. However, six patients had intermediate walking limitations. All patients in the bone allograft and non-bone allograft groups reported no pain and gait issues and were satisfied with the surgical outcomes.

Knee score of Knee Society Score

The non-bone allograft group showed slightly better results compared with the bone allograft group. However, the difference was not statistically significant (78.67 versus 81.46; $p = 0.33$). All patients in both groups showed anteroposterior and mediolateral stability < 5, and no varus or valgus deformity was present is any candidate. A similar range of flexion between 100° and 125° and an extension lag of between 0° and10° was also present in both groups. Two patients in the bone allograft group had a contracture of 20°, while 2 patients presented a contracture of 9°. Only one patient in the non-bone allograft group had a contracture of 20°.

Recurrence

There was no incidence of recurrence in any group postoperatively within 5 years of follow-up (0% versus 0%; $p = 1$).

Complications

The difference in complications between each group is not statistically significant (3 [25%] versus 1 [7.69%]; $p = 0.21$). However, three patients reported superficial infections in the bone allograft group, while only 1 patient reported superficial infections in the non-bone allograft group within 7 days. They were initially treated with antibiotics and daily dressings. Out of three, one patient in the bone allograft group did not respond to antibiotics and the daily dressings and was therefore taken to the operating room due to the deep extension of the infection. The site was reexplored, and bone cement was removed with copious washing of the site and reconstructed, after which the wound was closed as usual and followed-up closely (►**Table 2** and ►**Fig. 2**).

Discussion

Extended curettage has been used for GCT for many years. However, the reconstruction of bone defect has remained a controversial issue since then. Different trials have reported reconstruction of the bone defect with either bone cement and/or bone grafts. The literature currently lacks good-quality comparatively designed studies focusing specifically on the GCT around the knee joint with defined Campanacci grading in their inclusion criteria. Our study is the largest comparative study with 25 participants with only Grade II GCT, divided into 2 cohorts. We have

 © 2022. Sociedade Brasileira de Ortopedia e Traumatologia. All rights reserved.

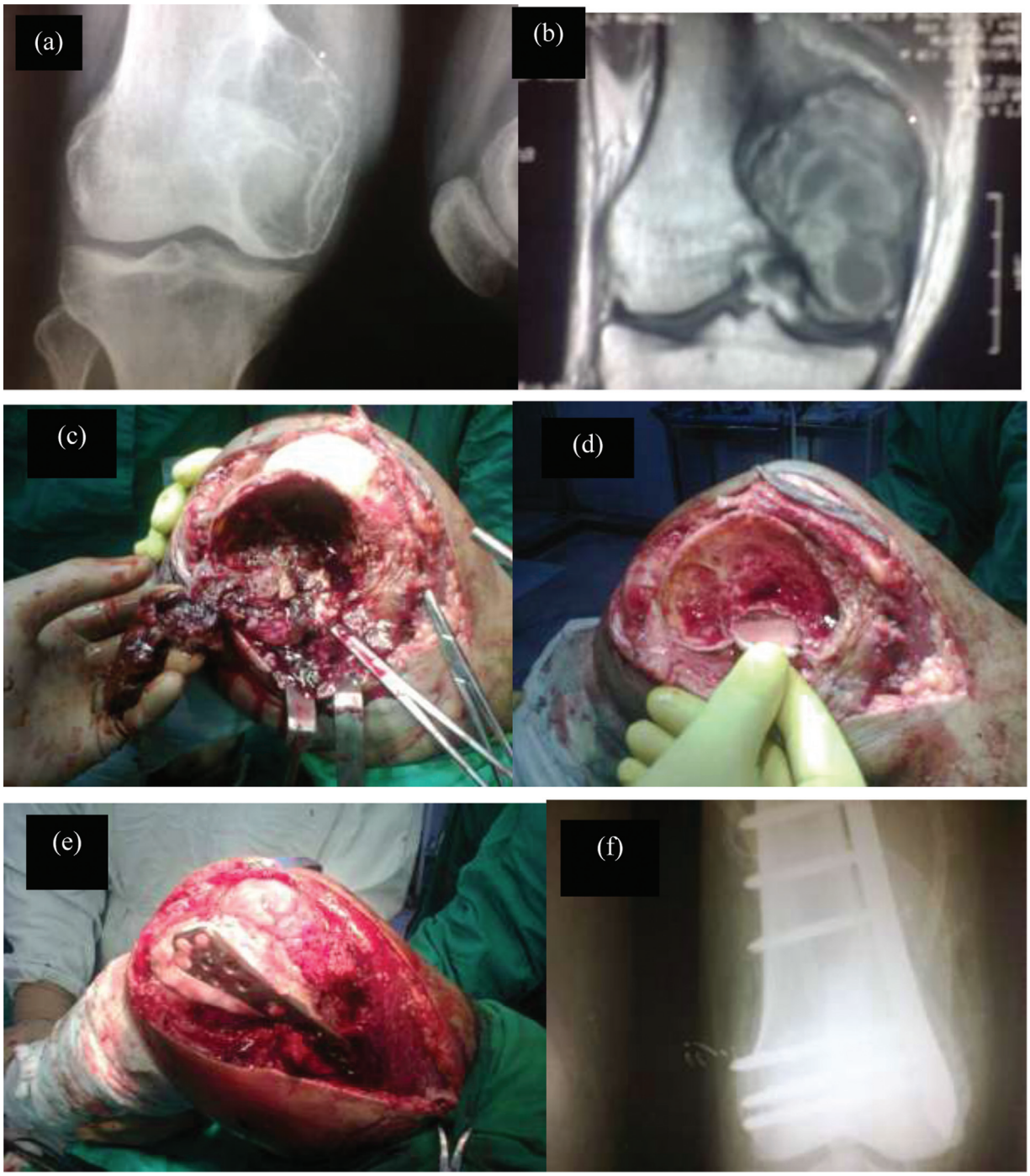

Fig. 1 Surgical technique for extended curettage of GCT of the distal femur showing (a) preoperative X-ray (b) preoperative MRI (c) creation of cortical bone window and curettage of contents (d) after burring and washing with hydrogen peroxide and saline (e) filling the cavity with bone allograft, bone cement, and fixing with LCP (f) postoperative X-ray.

excluded grade I and III GCTs as they may create bias in the results due to smaller and larger curettage windows, respectively, and may also decrease the reproducibility of the results. To overcome the statistical difficulty for a limited sample study, we used the Fisher exact test and the Student t-test, which works well on smaller samples.[11] Moreover, the study cohorts are nearly identical based on the baseline characteristics of the cohorts.

The results of our trial have shown no difference in Revised Musculoskeletal Tumor Society Scores between both cohorts. Excellent postoperative outcomes of limb function have been achieved in both groups. The results of our study have shown similar results as those of Greenberg et al.[12] and Yu et al.[13] where they used bisphosphonate-loaded bone cement for filling after curettage and oral bisphosphonates, respectively. Similarly, curettage with bone cement has been proven to be successful in many other studies as well.[14,15] During our literature review, we also found some studies where bone grafting was used along with bone cement for GCT with excellent postoperative

 © 2022. Sociedade Brasileira de Ortopedia e Traumatologia. All rights reserved.

functions.[16,17] However, these studies related to bone cement and bone grafts are not specific for GCT around the knee joint and included grades I and III GCTs as well, such as Song et al.[18] who performed extended curettage with bone cement for GCT around the knee joint but included grade III GCTs only, while Saibaba et al.[9] included grades I, II, and III GCT candidates. Another study by Gupta et al.[19] included pathological fractures with GCT as the study population, but the results remained excellent. Hence, there is a lack of data regarding the use of allograft and/or cement around the knee joint for grade II GCT.

Table 2 Postoperative comparison of outcomes between the allograft with the non-allograft group

Outcomes	Bone Allograft	Non-Bone Allograft	*p-value*
Revised Musculoskeletal tumor society score**	26.25 (2.17)	26.15 (2.48)	0.92
Knee Society Score**	78.67 (6.02)	81.46 (7.67)	0.33
Recurrence*	0 (0%)	0 (0%)	1
Complications			
Wound infections*	3 (25%)	1 (7.69%)	0.21
Deep infections*	0 (0%)	0 (0%)	1
Early osteoarthritis*	0 (0%)	0 (0%)	1

**Mean (standard deviation)
*Frequency (percentage)

The knee score of the Knee Society Score was also used in our trial as a method of calculating structural and functional outcomes in a comprehensive manner. The knee scores of both groups did not show any statistically significant difference. However, the results were showing slightly better results in the non-bone allograft group due to less contracture formations. The association of contracture with delayed rehabilitation has been well-established.[20] Patients treated with bone cement developed early postoperative recovery which reduces the incidence of contractures.[21] During our surgery, we did not manipulate the articular surfaces, so mediolateral or anteroposterior instability was not observed in any candidate in any group. Due to pain, muscle damage, and contracture development, a few patients in both groups reported some extension lag which was mild and managed conservatively. To the best of our knowledge, none of the previous studies have reported postoperative functions in terms of the knee score of the Knee Society Score. The score has been originally designed for sports surgeries, but it may

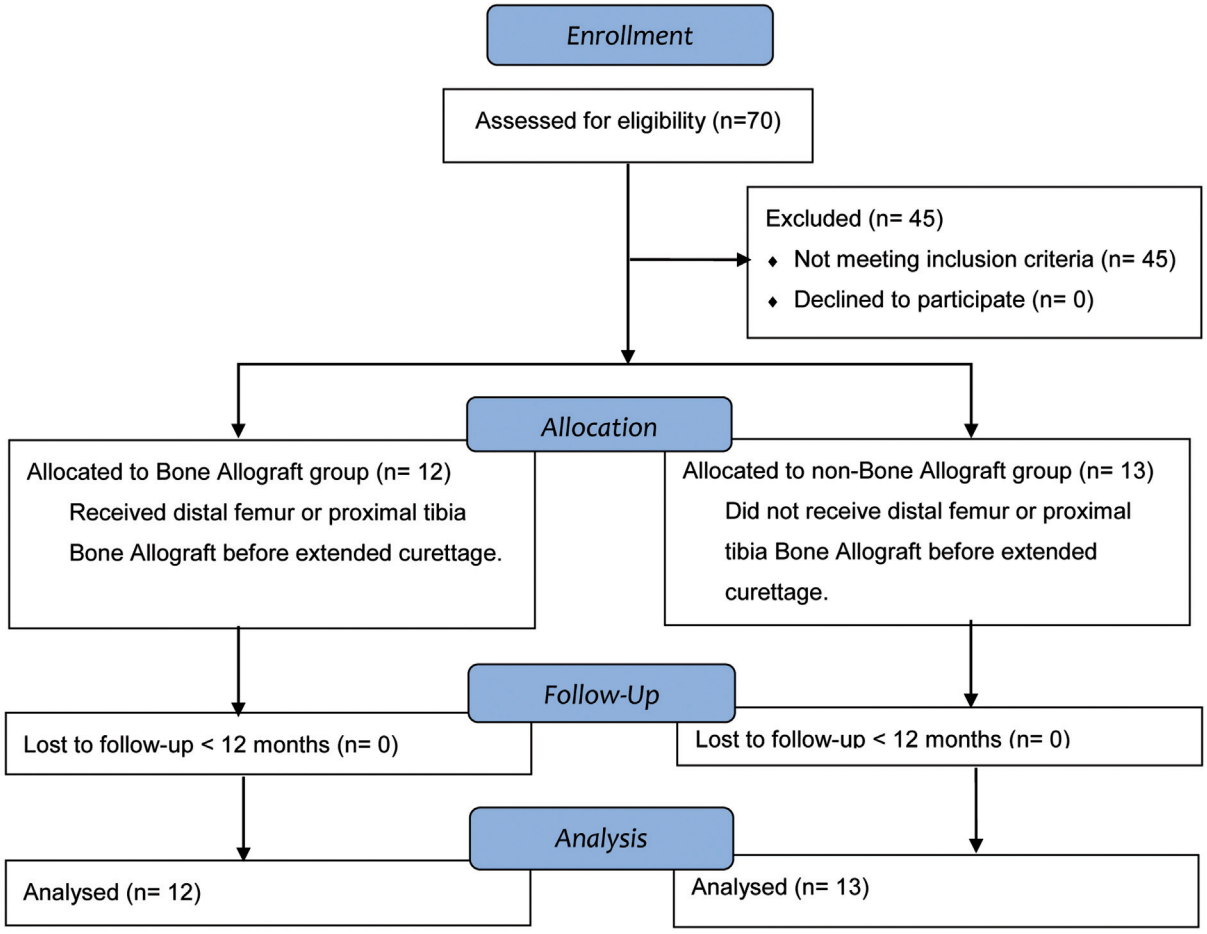

Fig. 2 Flowchart for inclusion/exclusion of patients.

 © 2022. Sociedade Brasileira de Ortopedia e Traumatologia. All rights reserved.

play a pivotal role in the assessment of knee functions after other reconstructive knee surgeries as well, since this scoring system is based on a reliable clinical assessment by trained personnel only without any clinician-oriented or patient-oriented prejudice.[22] We may postulate that the assessment of knee functions should be carried out using the knee score of the Knee Society Score in future studies to increase the reproducibility of the results for GCT around the knee.

With an excellent functional status, we followed-up patients for at least 1 year and did not find recurrence in any of the groups. The results of our study contradict the previous articles in which a high number of recurrences have been reported. Moreover, Vaishya et al.[23] reported more recurrences in bone graft than in bone cement in their systematic review. Many studies have mentioned phenolization as a necessary adjunct to decrease recurrence.[24,25] However, we only used hydrogen peroxide for chemical cauterization with bone cement in both groups to decrease the risk of recurrence. Studies have mentioned curettage as a potential risk factor for high recurrence.[8,26] Most of these studies used only curettage with bone graft or bone cement without phenolization or hydrogen peroxide. Our results have shown that chemical cauterization with hydrogen peroxide along with extended curettage may be enough to reduce recurrences in GCT. The recurrence rate of our study also shows that extended curettage with chemical cauterization is superior to wide-margin resection for Grade II GCT, which goes against the previously published articles.[26,27]

Our study reports superficial infections among candidates in both groups. However, more infections were reported in the bone allograft group than in the non-bone allograft group. All the participants were infected with staphylococcus aureus and were subsequently treated by dressings and antibiotic. However, in one candidate, the infection penetrated deep, requiring removal of bone cement, copious washing, and reloading of bone cement. We did not report any postoperative fractures in our study. This indicates that appropriate filling of the bone defect is necessary to prevent fractures. One of the most discussed complications of periarticular curettage is the development of early osteoarthritis, with mixed results having been reported in different studies.[28,29] Xu et al.[30] showed that subchondral bone grafting may decrease osteoarthritic changes, but our study has proven equivocal results with bone grafting and/or cementing. Araki et al. conducted the longest follow-up study to evaluate the development of osteoarthritis and reported osteoarthritis in 26% of the participants after curettage and cementation.[29]

In conclusion, extended curettage with or without bone allograft have similar functional outcomes for the knee without any major difference in the incidence of recurrence and complications for Grade II GCT. Under these circumstances, intraoperative duration, surgical convenience, and cost-effectiveness favor the use of bone cement without bone allografts for reconstructing the defect after extended curettage. However, bone allograft provides a sandwiching material between the cartilage and the bone cement that may prevent cartilage degeneration and osteoarthritis in long-term follow-ups, which requires further investigation.

Ethics Approval

The study was approved by Human Subject Review Board.

Contributions of the Authors

Sahito B. and Ali S. M. E. conceived the study and performed data collection and critical revision. Majid B., Katto S. A., Jatoi A. and Jahanzeb S. performed designing, data interpretation and drafting. All the authors approved the final draft and stand accountable for the validity of the data.

Financial Support

There was no financial support from any public, commercial, or non-profit sources.

Conflict of Interests

The authors have no conflict of interests to declare.

References

1 Muheremu A, Niu X. Pulmonary metastasis of giant cell tumor of bones. World J Surg Oncol 2014;12:261
2 Puri A, Agarwal M. Treatment of giant cell tumor of bone: Current concepts. Indian J Orthop 2007;41(02):101–108
3 Campanacci M, Baldini N, Boriani S, Sudanese A. Giant-cell tumor of bone. J Bone Joint Surg Am 1987;69(01):106–114
4 Sahito B, Ali SME, Kumar D, Kumar J, Hussain N, Lakho T. Role of denosumab before resection and reconstruction in giant cell tumors of bone: a single-centered retrospective cohort study [published online ahead of print, 2021 May 29]. Eur J Orthop Surg Traumatol 2021;10.1007/s00590-021-03012-1
5 Sobti A, Agrawal P, Agarwala S, Agarwal M. Giant Cell Tumor of Bone - An Overview. Arch Bone Jt Surg 2016;4(01):2–9
6 Hasan O, Ali M, Mustafa M, Ali A, Umer M. Treatment and recurrence of giant cell tumors of bone - A retrospective cohort from a developing country. Ann Med Surg (Lond) 2019;48:29–34
7 Bernardes M, Santos F, Frias M, Sá D, Duarte G, Lemos R. Giant Cell Tumor with Fracture of the Proximal Radius - Reconstructive Surgery with Radius Allograft. J Orthop Case Rep 2020;10(03): 32–35
8 Errani C, Tsukamoto S, Leone G, et al. Higher local recurrence rates after intralesional surgery for giant cell tumor of the proximal femur compared to other sites. Eur J Orthop Surg Traumatol 2017; 27(06):813–819
9 Saibaba B, Chouhan DK, Kumar V, Dhillon MS, Rajoli SR. Curettage and reconstruction by the sandwich technique for giant cell tumours around the knee. J Orthop Surg (Hong Kong) 2014;22 (03):351–355
10 Datta NK, Das KP, Mia MM, Aish PK. Limb Salvage by Resection Arthrodesis with the use of Osteoarticular Allograft in the Treatment of Aggressive Giant Cell Tumour around the Knee. Mymensingh Med J 2020;29(02):317–324
11 Jung SH. Stratified Fisher's exact test and its sample size calculation. Biom J 2014;56(01):129–140
12 Greenberg DD, Lee FY. Bisphosphonate-loaded Bone Cement as a Local Adjuvant Therapy for Giant Cell Tumor of Bone: A 1 to 12-Year Follow-up Study. Am J Clin Oncol 2019;42(03):231–237
13 Yu X, Xu M, Xu S, Su Q. Clinical outcomes of giant cell tumor of bone treated with bone cement filling and internal fixation, and oral bisphosphonates. Oncol Lett 2013;5(02):447–451

 © 2022. Sociedade Brasileira de Ortopedia e Traumatologia. All rights reserved.

14 Takeuchi A, Suwanpramote P, Yamamoto N, et al. Mid- to long-term clinical outcome of giant cell tumor of bone treated with calcium phosphate cement following thorough curettage and phenolization. J Surg Oncol 2018;117(06):1232–1238
15 Chen KH, Wu PK, Chen CF, Chen WM. Zoledronic acid-loaded bone cement as a local adjuvant therapy for giant cell tumor of the sacrum after intralesional curettage. Eur Spine J 2015;24(10): 2182–2188
16 Kundu ZS, Gogna P, Singla R, Sangwan SS, Kamboj P, Goyal S. Joint salvage using sandwich technique for giant cell tumors around knee. J Knee Surg 2015;28(02):157–164
17 Wu M, Yao S, Xie Y, et al. A novel subchondral bone-grafting procedure for the treatment of giant-cell tumor around the knee: A retrospective study of 27 cases. Medicine (Baltimore) 2018;97 (45):e13154
18 Song Y, Li CF, Shi XT, Cheng YQ, Suo HQ, Liu JG. [Expanded curettage and bone cement filling combined with internal fixation for the treatment of Campanacci III giant cell tumour of knee joint]. Zhongguo Gu Shang 2019;32(04):372–376
19 Gupta SP, Garg G. Curettage with cement augmentation of large bone defects in giant cell tumors with pathological fractures in lower-extremity long bones. J Orthop Traumatol 2016;17(03): 239–247
20 Skalsky AJ, McDonald CM. Prevention and management of limb contractures in neuromuscular diseases. Phys Med Rehabil Clin N Am 2012;23(03):675–687
21 Sas A, Van Camp D, Lauwers B, Sermon A, van Lenthe GH. Cement augmentation of metastatic lesions in the proximal femur can improve bone strength. J Mech Behav Biomed Mater 2020;104:103648
22 Martimbianco AL, Calabrese FR, Iha LA, Petrilli M, Lira Neto O, Carneiro Filho M. Reliability of the "American Knee Society Score" (AKSS). Acta Ortop Bras 2012;20(01):34–38
23 Vaishya R, Pokhrel A, Agarwal AK, Vijay V. Current status of bone cementing and bone grafting for giant cell tumour of bone: a systemic review. Ann R Coll Surg Engl 2019;101(02): 79–85
24 Pietschmann MF, Dietz RA, Utzschneider S, Baur-Melnyk A, Jansson V, Dürr HR. The influence of adjuvants on local recurrence rate in giant cell tumour of the bone. Acta Chir Belg 2010;110(06): 584–589
25 Dürr HR, Maier M, Jansson V, Baur A, Refior HJ. Phenol as an adjuvant for local control in the treatment of giant cell tumour of the bone. Eur J Surg Oncol 1999;25(06):610–618
26 Abuhejleh H, Wunder JS, Ferguson PC, et al. Extended intralesional curettage preferred over resection-arthrodesis for giant cell tumour of the distal radius. Eur J Orthop Surg Traumatol 2020; 30(01):11–17
27 Pazionis TJ, Alradwan H, Deheshi BM, Turcotte R, Farrokhyar F, Ghert M. A Systematic Review and Meta-Analysis of En-Bloc vs Intralesional Resection for Giant Cell Tumor of Bone of the Distal Radius. Open Orthop J 2013;7:103–108
28 Farfalli GL, Slullitel PA, Muscolo DL, Ayerza MA, Aponte-Tinao LA. What Happens to the Articular Surface After Curettage for Epiphyseal Chondroblastoma? A Report on Functional Results, Arthritis, and Arthroplasty. Clin Orthop Relat Res 2017;475(03): 760–766
29 Araki Y, Yamamoto N, Hayashi K, et al. Secondary Osteoarthritis After Curettage and Calcium Phosphate Cementing for Giant-Cell Tumor of Bone Around the Knee Joint: Long-Term Follow-up. JB JS Open Access 2020;5(03):e19.00068
30 Xu HR, Niu XH, Zhang Q, Hao L, Ding Y, Li Y. Subchondral bone grafting reduces degenerative change of knee joint in patients of giant cell tumor of bone. Chin Med J (Engl) 2013;126(16): 3053–3056

 © 2022. Sociedade Brasileira de Ortopedia e Traumatologia. All rights reserved.