



Primary Extraskelatal Ewing Sarcoma of the Thoracolumbar Epidural Space: Rare Case Report in a Child

Sarcoma de Ewing extraesquelético primário no espaço epidural toracolombar: Raro relato de caso em criança

Aldo José Ferreira da Silva^{1,2} Ana Carolina de Carvalho Ruela Pires³
 Auxiliadora Damianne Pereira Vieira da Costa³ Fabiana Lopes Amaral³ Rodrigo C. Bomfim⁴
 Ângelo M. S. Bomfim Filho⁴ Alessandra Lamenha Feitosa⁵ Igor Lima Buarque⁶

¹ Division of Pediatric Neurosurgery, Hospital Geral do Estado, Maceió, Brazil

² Pediatric Neurosurgery Division, Santa Monica Teaching Maternity, Universidade Estadual de Ciências da Saúde de Alagoas, Maceió, Brazil

³ Division of Pediatric, Hospital Geral do Estado, Maceió, Brazil

⁴ Intervention and Diagnostic Imaging Service (Angioneuro), Hospital Veredas, Maceió, Brazil

⁵ Department of Pediatric Oncology, Santa Casa de Misericórdia de Maceió, Maceió, Brazil

⁶ CESMAC University Center, Maceió, Brazil

Address for correspondence Aldo José Ferreira da Silva, MD, Hospital Geral do Estado/Maternidade Escola Santa Mônica, Universidade Estadual de Ciências da Saúde de Alagoas, R. Barão José Miguel 151, 57055-160 Maceió, AL, Brazil (e-mail: neuroajfs@yahoo.com.br).

Arq Bras Neurocir 2022;41(2):e183–e186.

Abstract

Introduction Ewing sarcomas are a family of tumors that can be of skeletal or extraskelatal origin. We report a rare case of a child with extraskelatal Ewing sarcoma in the thoracolumbar epidural space.

Case Report The patient was a 1-year-old female child with sphincter alteration, flaccid paraplegia, and areflexia. A magnetic resonance imaging (MRI) scan showed a large extensive epidural lesion with compression of the dural sac in the D6–L2 segment, and a left paravertebral extension through the L1–L2 foramen. Laminotomy was performed, with subtotal resection of the lesion. The histopathological and immunohistochemical analyses indicated Ewing sarcoma. Due to the child's age, radiotherapy was not performed, only chemotherapy, due to the aggressiveness of the neoplasm. The patient showed rapid tumor recurrence and ended up dying.

Discussion Extraskelatal Ewing sarcoma can appear in different locations in the body. They are aggressive tumors with local recurrence and distant metastases. In our case, a combination of MRI and positron-emission tomography–computed tomography scan presented a clearer result, especially in the presence of metastasis. In the histopathological analysis, small blue cells with a clear cytoplasm and indistinct nucleoli were observed. In the immunohistochemical analysis, CD99 (MIC2) expression is

Keywords

- Ewing sarcoma
- thoracolumbar
- epidural
- radiotherapy
- chemotherapy

received

February 6, 2021

accepted

December 20, 2021

published online

April 4, 2022

DOI <https://doi.org/10.1055/s-0042-1742710>

ISSN 0103-5355.

© 2022. Sociedade Brasileira de Neurocirurgia. All rights reserved.

This is an open access article published by Thieme under the terms of the Creative Commons Attribution-NonDerivative-NonCommercial-License, permitting copying and reproduction so long as the original work is given appropriate credit. Contents may not be used for commercial purposes, or adapted, remixed, transformed or built upon. (<https://creativecommons.org/licenses/by-nc-nd/4.0/>)

Thieme Revinter Publicações Ltda., Rua do Matoso 170, Rio de Janeiro, RJ, CEP 20270-135, Brazil

highlighted. The best treatment outcome would have been surgical resection with chemotherapy and radiotherapy.

Conclusion We reported a rare case of thoracolumbar epidural Ewing sarcoma in which, despite surgery and chemotherapy, the tumor behaved very aggressively, leading to an unfavorable prognosis.

Resumo

Introdução Os sarcomas de Ewing constituem uma família de tumores que podem ser de origem óssea ou extraesquelética. O caso aqui relatado é o de uma criança com raro sarcoma de Ewing extraesquelético no espaço epidural toracolombar.

Relato de caso Criança do sexo feminino, de 1 ano de idade, com quadro de alteração de esfíncter, paraplegia flácida, e arreflexia. O exame de ressonância magnética (RM) revelou volumosa lesão expansiva epidural com compressão do saco dural no segmento de D6-L2, e extensão paravertebral esquerda através do forame L1-L2. Realizou-se laminotomia, com ressecção subtotal da lesão. O exame histopatológico e a imunohistoquímica indicavam sarcoma de Ewing. Por conta da idade da criança, ela não foi submetida a radioterapia, apenas a quimioterapia, e, devido à agressividade da neoplasia, a paciente evoluiu com rápida recidiva tumoral e terminou falecendo.

Discussão O sarcoma de Ewing extraesquelético pode aparecer em diferentes locais do corpo. São tumores agressivos com recorrência local e metástase à distância. Na investigação, a combinação de RM e tomografia por emissão de pósitrons–tomografia computadorizada apresenta melhor resultado, principalmente na presença de metástase. No exame histopatológico, observaram-se pequenas células azuis com citoplasma claro e nucléolos indistintos. Na imunohistoquímica, se destaca a expressão principalmente do CD99 (*MIC2*). A conduta com melhor resultado no tratamento seria ressecção cirúrgica, com quimioterapia e radioterapia.

Conclusão Relatamos um caso raro de uma criança com sarcoma de Ewing epidural na coluna, e apesar da realização da cirurgia e de quimioterapia, o tumor se comportou de modo extremamente agressivo, o que levou a um prognóstico desfavorável.

Palavras-chave

- sarcoma de Ewing
- toracolombar
- epidural
- radioterapia
- quimioterapia

Introduction

Ewing sarcoma is a rare malignant neoplasm that was first described by James Ewing in 1921. He described it as a small-blue-round-cell tumor. Initially, Ewing sarcoma was believed to originate in the undifferentiated endothelial and mesenchymal cells of the bone marrow, but, with the advent of immunohistochemistry and cytogenetic tests, its neuroectodermal origin was discovered.^{1–3} It is the second most common bone tumor in children and adolescents.⁴

The Ewing sarcoma family of tumors (ESFT) includes peripheral primitive neuroectodermal tumors (pPNETs) and Askin tumors. They are morphologically similar in terms of malignancy, and they can be of skeletal or extraskelatal origin. Extraskelatal Ewing sarcomas account for 6% to 47% of all tumors in the ESFT.^{5,6}

The patient in the case herein reported was a child with a rare extraskelatal Ewing sarcoma of the thoracolumbar epidural space.

Case Report

A 1-year-old female child presented to the hospital with difficulty in walking, with motor deficit progressively wors-

ening and dorsalgia for 30 days. Upon physical examination, she presented with intestinal constipation, bladder dysfunction (neurogenic bladder), flaccid paraplegia, and areflexia. Up to one year of age, the developmental milestones were normal, and during pregnancy the obstetric ultrasound was also normal. Regarding the imaging studies, a computed tomography (CT) scan of the thoracolumbar spine showed a massive heterogeneous lesion (D8–L2) in the vertebral canal. A magnetic resonance imaging (MRI) scan of the thoracolumbar spine showed a large extensive epidural lesion with compression of the dural sac in the D8–L2 segment, and a left paravertebral extension through the L1–L2 foramen (►Fig. 1). The chest CT scan and the ultrasound examination of the abdomen were normal. Laminotomy was performed from D7 to L3, with subtotal resection of the lesion (►Fig. 2a and b). In the postoperative period, the areflexia and paraplegia persisted, and only improvement in terms of pain were observed. The histopathological results indicated undifferentiated malignant blue-round-cell neoplasm (►Fig. 2c). The immunohistochemical analysis suggested Ewing sarcoma/PNET with Ki67 (85% positive)/epithelial membrane antigen (EMA) positive/CD56

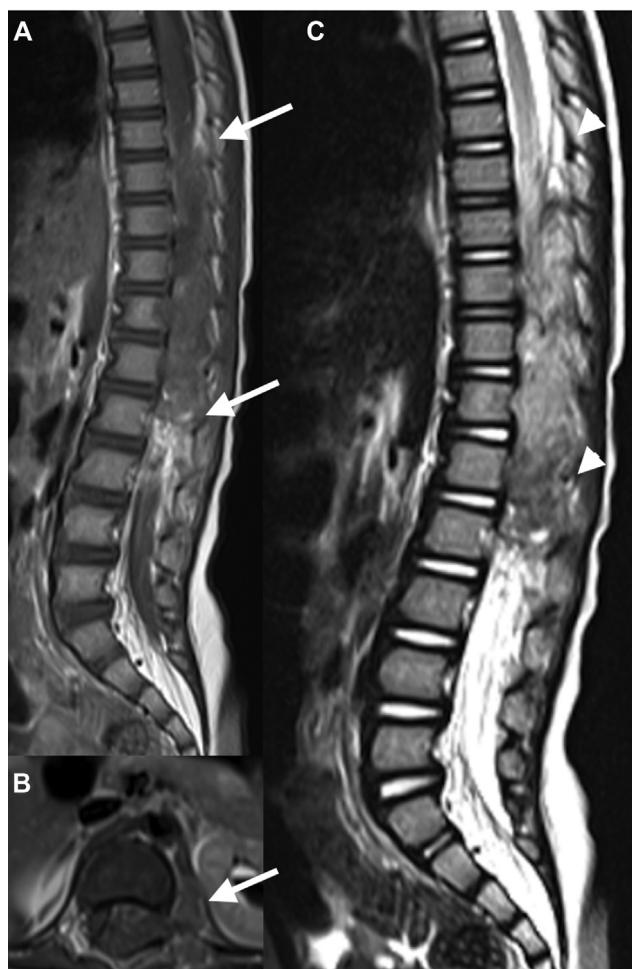

Fig. 1 (A) Sagittal T1-weighted MRI scan with contrast showing a heterogeneously-enhancing epidural mass at T8-L2 (arrows); (B) axial T1-weighted MRI scan with contrast showing an extension to the left intervertebral foramen (L1 / L2) with a paravertebral mass and homogeneous enhancement (arrow); (C) sagittal T2-weighted MRI scan showing a heterogeneously-enhancing epidural mass at T8-L2 (arrowheads).

positive/pan-cytokeratin positive/CD99 positive/friend leukemia integration-1 (FLI-1) positive.

Due to the patient's age, radiotherapy was not performed, only chemotherapy. The patient then presented with rapid lesion recurrence (► **Fig. 3**), with tumor lysis, septic shock and, after several days in the intensive care unit (ICU), she died.

Discussion

In 1969, Tefft et al.⁷ first described four patients with paravertebral soft-tissue tumors that were histologically similar to Ewing sarcoma. In 1975, Angervall and Enzinger⁸ reviewed 39 patients with paravertebral malignant soft-tissue tumors that did not originate in the bone, but were morphologically similar to skeletal Ewing sarcoma.

Extraskelletal Ewing sarcoma is a part of the ESFT. This group of tumors affects bones and soft tissues. The peak incidence is between 10 and 15 years of age, with a specific translocation $t(11; 22)(q24; q12)$ in > 90% of the cases.^{2,9,10}

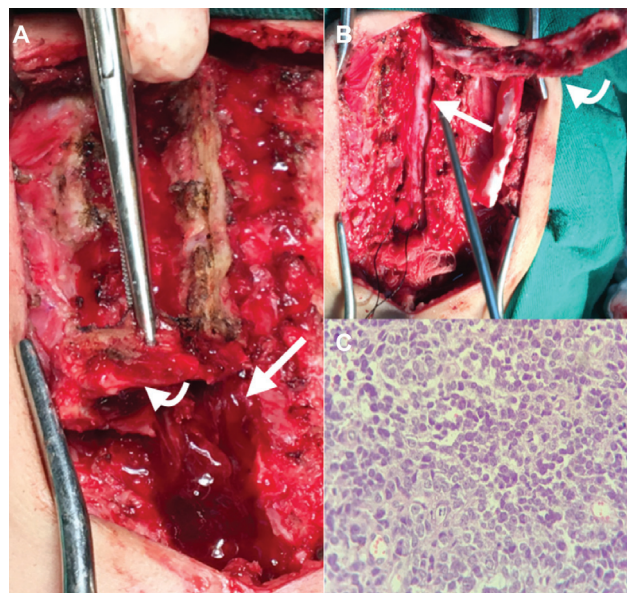


Fig. 2 (A) Laminotomy (curved arrow) with epidural mass (arrow); (B) D7-L3 laminotomy (curved arrow) and dural sac after tumor resection (arrow); (C) the tumor shows the a small-round-blue-cell appearance and scanty cytoplasm with mitotic figures (hematoxylin-eosin stain, x 400).

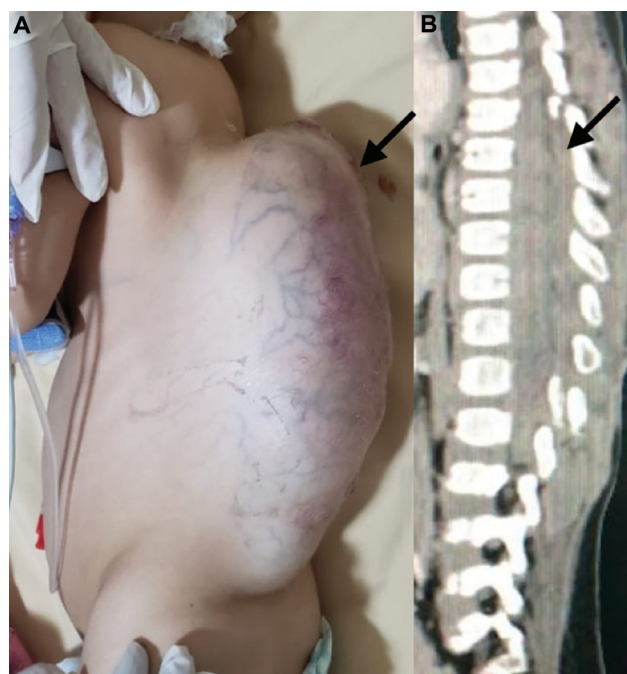


Fig. 3 (A,B) Massive recurrence in the thoracolumbar epidural space (arrows).

Extraskelletal Ewing sarcoma can appear in different locations of the body, such as the central nervous system, the chest wall, the retroperitoneum, the skin, the kidneys, the small intestine, the pelvis, the rectum, the vagina, the fingers, the arms, the scalp, the lips, the nasal passages, the paravertebral region, and the perineum.¹ They are aggressive tumors with a high incidence of local recurrence and distant metastasis, mainly to the lungs, spine, and brain. These

tumors have worse prognosis compared with that of other bone tumors of the ESFT.^{2,6}

Extradural tumors account for 30% of all spinal-cord tumors in children. Therefore, the differential diagnoses may be: benign bone tumors (such as osteoid osteoma, osteochondroma, giant-cell tumor, aneurysmal bone cyst, and hemangioma), Langerhans cell histiocytosis, and fibrous dysplasia; and malignant tumors, such as sarcomas, teratomas, chordomas, and metastatic lesions.¹¹

For the diagnosis, imaging techniques like CT be used to look for heterogeneous masses, and the MRI, for hypo- or isointense signals in T1-weighted images and hyperintense signals in T2-weighted images. Fluorodeoxyglucose positron emission tomography has not shown good results in the diagnosis and staging of soft-tissue sarcomas.^{2,12}

A combination of MRI and positron-emission tomography-computed tomography (PET-CT) has been shown to yield satisfactory results, mainly in the identification of metastasis.^{2,12}

As clinical findings are inaccurate and the diagnosis of extraskelatal Ewing sarcomas by imaging is nonspecific, the histopathological analysis becomes vital, and, on it, uniform proliferation of small blue round cells with a clear cytoplasm and indistinct nucleoli is observed. The immunohistochemical markers traditionally used in the differential diagnosis of ESFT are CD99 (MIC2), FLI-1, and human natural killer-1 (HNK-1). Other more specific markers are also used, such as enolase, S-100, CD56, chromogranin A, synaptophysin, cytokeratin, and EMA. The expression of Ki67 also represents an indicator of poor prognosis in ESFT.^{2,9,13}

In terms of treatment, patients with extraskelatal Ewing sarcoma who underwent surgical resection (partial or total), chemotherapy, and radiotherapy had a 1-year survival rate compared with those who underwent surgery, chemotherapy, or radiotherapy.¹⁴ Patients with metastasis had an even worse prognosis.⁶

In the present article, we reported a rare case of thoracolumbar epidural Ewing sarcoma, and due to the atypical age group (1 year of age) for the pathological condition, in which radiotherapy is not recommended, the tumor proved to be extremely aggressive. Despite surgery and chemotherapy, the tumor presented a rapid degree of recurrence, leading to an unfavorable outcome.

Conflict of Interests

The authors have no conflict of interests to declare.

References

- 1 Ali SA, Muhammad AT, Soomro AG, Siddiqui AJ. Extra osseous primary Ewing's sarcoma. *J Ayub Med Coll Abbottabad* 2010;22(03):228–229
- 2 Bustoros M, Thomas C, Frenster J, et al. Adult primary spinal epidural extraosseous ewing's sarcoma: a case report and review of the literature. *Case Rep Neurol Med* 2016; 2016:1217428
- 3 Murphey MD, Senchak LT, Mambalam PK, Logie CI, Klassen-Fischer MK, Kransdorf MJ. From the radiologic pathology archives: ewing sarcoma family of tumors: radiologic-pathologic correlation. *Radiographics* 2013;33(03):803–831
- 4 Eddaoualline H, Mazouz K, Rafiq B, et al. Ewing sarcoma of the adrenal gland: a case report and review of the literature. *J Med Case Reports* 2018;12(01):69
- 5 Jiang S, Wang G, Chen J, Dong Y. Comparison of clinical features and outcomes in patients with extraskelatal vs skeletal Ewing sarcoma: an SEER database analysis of 3,178 cases. *Cancer Manag Res* 2018;10:6227–6236
- 6 Tural D, Molinas Mandel N, Dervisoglu S, et al. Extraskelatal Ewing's sarcoma family of tumors in adults: prognostic factors and clinical outcome. *Jpn J Clin Oncol* 2012;42(05):420–426
- 7 Tefft M, Vawter GF, Mitus A. Paravertebral "round cell" tumors in children. *Radiology* 1969;92(07):1501–1509
- 8 Angervall L, Enzinger FM. Extraskelatal neoplasm resembling Ewing's sarcoma. *Cancer* 1975;36(01):240–251
- 9 Halefoglu AM. Extraskelatal Ewing's sarcoma presenting as a posterior mediastinal mass. *Arch Bronconeumol* 2013;49(02): 82–84
- 10 Fizazi K, Dohollou N, Blay JY, et al. Ewing's family of tumors in adults: multivariate analysis of survival and long-term results of multimodality therapy in 182 patients. *J Clin Oncol* 1998;16(12): 3736–3743
- 11 Quon JL, Grant RA, Huttner AJ, Duncan CC. Thoracic epidural teratoma: case report and review of the literature. *Clin Med Insights Pathol* 2014;7:15–20
- 12 Srivastava S, Arora J, Parakh A, Goel RK. Primary extraskelatal Ewing's sarcoma/primitive neuroectodermal tumor of breast. *Indian J Radiol Imaging* 2016;26(02):226–230
- 13 Machado I, Lopez-Guerrero JA, Llombart-Bosch A. Biomarkers in the Ewing's sarcoma family of tumors. *Curr Biomark Find* 2014; 4:81–92
- 14 Saeedinia S, Nouri M, Alimohammadi M, Moradi H, Amirjamshidi A. Primary spinal extradural Ewing's sarcoma (primitive neuroectodermal tumor): Report of a case and meta-analysis of the reported cases in the literature. *Surg Neurol Int* 2012;3:55