Article published online: 2022-06-08

Study of Surrogate Immunohistochemical Markers IDH1, ATRX, BRAF V600E, and p53 Mutation in Astrocytic and Oligodendroglial Tumors

Santosh Sharma[1] Kusum Mathur[1] Alka Mittal[1] Meel Mukta[1] Arpita Jindal[1] Mukesh Kumar[1]

[1] SMS Medical College and Attached Hospital, Jaipur, Rajasthan, India

Indian J Neurosurg 2023;12:137–146.

Address for correspondence Mukta Meel, MBBS, MD, Department of Pathology, SMS Medical College, Jaipur 332004 Rajasthan, India (e-mail: drmuktab@yahoo.com).

Abstract

Introduction In consonance with current the World Health Organization (WHO) classification of the central nervous system (CNS) tumors (2016), histological diagnosis of gliomas should be reinforced by molecular information. This study was performed to determine the frequency of isocitrate dehydrogenase 1 (IDH1), α thalassemia/intellectual disability syndrome X-linked (ATRX), p53, and BRAF V600E mutations in different grade astrocytomas and oligodendrogliomas.

Methods Seventy-seven cases of astrocytoma and oligodendroglioma (7 pilocytic astrocytomas, 15 diffuse astrocytomas [DA], 4 anaplastic astrocytomas [AA], 29 glioblastomas [GBM], and 22 oligodendrogliomas) were analyzed using immunohistochemistry for IDH1 mutant protein, ATRX, p53, and BRAF as well as their clinicopathological features assessed.

Results All pilocytic astrocytoma and primary glioblastoma cases were negative for an *IDH1* mutation. *IDH1* mutation was detected in 66.7% (10/15) of DA, 50% (2/4) of AA, 20.7% (6/29) of glioblastomas, and 81.8% (18/22) of oligodendroglioma cases. Loss of nuclear ATRX expression was found in 86.7% (13/15), 75% (3/4), and 34.5% (10/29) of DA, AA, and GBM cases, respectively. All oligodendroglioma cases showed retained ATRX expression. Both markers were found statistically significant in the above tumors ($p < 0.05$). *BRAF V600E* mutation was detected in a single case of pilocytic astrocytoma and pleomorphic xanthoastrocytoma as well as both cases of epithelioid glioblastoma.

Conclusions *IDH1* and *ATRX* mutations are very common in diffuse astrocytoma and anaplastic astrocytoma, while they are rare in pilocytic astrocytoma and glioblastoma. Immunohistochemistry for *IDH1* and *ATRX* can successfully characterize the diffuse gliomas into molecularly defined groups in the majority of the cases. *BRAF V600E* mutation is rare in astrocytic tumors in the Indian population.

Keywords
- astrocytoma
- oligodendroglioma
- glioblastoma
- isocitrate
- dehydrogenase

Introduction

Brain tumor, which is one of the most important cancers causing death, represents the 17th most common cancer worldwide and constitutes 1 to 2% of all tumors.[1,2] In India, the incidence of central nervous system (CNS) tumors ranges from 5 to 10 per 1,00,000 population with a rising trend. Due to a noteworthy increase in the incidence of, and death rates from, brain tumors in many

article published online
June 8, 2022

DOI https://doi.org/10.1055/s-0042-1743265.
ISSN 2277-954X.

developed countries, this type of tumor has distinctive value.[3]

In the World Health Organization (WHO) 2007 classification of CNS tumors, glial tumors were classified based on morphology as molecular features of gliomas were relatively less known in this classification.[4]

The importance of integrated diagnosis of brain tumors was highlighted by the fourth revised WHO classification of tumors of the CNS.[5] Hence, for accurate diagnosis, as well as patient management in neuro-oncological aspects, in addition to histological features, molecular signatures are now obligatory because molecularly different tumors could have different biological behaviors and treatment responses to therapeutic agents. The 2016 update of WHO classification suggests well-established molecular parameters in diagnostic algorithms of diffuse gliomas. Although the modification included in the 2016 update of the WHO classification of CNS tumors was extensively accepted, it has brought challenges as to the practical applicability of the new guidelines, especially in a resource-limited setting such as India as molecular analysis cannot be performed in many centers of India or sometimes molecular results may not be conclusive. As many of the genetic parameters included in 2016 WHO classification can be assessed using immunohistochemistry, immunohistochemistry offers an affordable, powerful, and easily available means to detect oncogenic genetic alterations in tissues. In the current study, an immunohistochemistry study was done to detect *IDH1R132H* mutation, *ATRX* expression, *p53* mutation, *BRAFV600E* mutation, and Ki-67 to refine tumor diagnosis and molecular classification, as well as to predict prognosis and determine individual therapeutic strategies.

In India, limited data are available on frequencies of *IDH1*, *BRAF*, and *ATRX* mutations in glial tumors so far, and most of the information regarding molecular alterations in gliomas is available from the western literature.[6–8]

Thus, the purpose of this study was to evaluate the frequency of these molecular alterations in different grades of astrocytic and oligodendroglial tumors by immunohistochemistry as these are important diagnostic and prognostic markers and the WHO 2016 classification based on this genetic information.

Objectives

Primary objectives: (1) Histomorphological grading of astrocytic and oligodendroglial tumors. (2) Immunohistochemical study of *IDH1*, *ATRX*, *BRAFV600E*, and *p53* mutations in different types of astrocytic and oligodendroglial tumors.

Secondary objective: Clinicopathological correlation of these markers in different types of astrocytic and oligodendroglial tumors.

Materials and Methods

Study design: Cross-sectional descriptive type of observational study.

Study period: After approval from the institutional ethics committee until the sample size was attained (~2 years).

Study universe: All neurosurgical biopsy specimens were received at the Department of Pathology.

Inclusion criteria: Cases of astrocytoma and oligodendroglioma were reported during the study period with complete clinical and radiological history.

Exclusion criteria: Other neuroepithelial tumors, non-neoplastic lesions of the CNS, cases with incomplete history and radiological details, and poorly preserved biopsy.

In this prospective study, all patients (no age limit) with a histologically proven astrocytoma and oligodendroglioma were included and variables such as age, sex, chief complaints, and relevant clinical as well as radiological details were recorded. All cases were classified and graded according to the existing 2016 WHO criteria.

IHC was performed at least on one representative block in all cases and performed using primary antibody against the following antigens: IDH1 R132H, ATRX, p53, Ki-67, and BRAF (V600E).

Statistical Analysis

The findings were tabulated in a Microsoft Excel Worksheet and analyzed using the Standard Statistical Package for the Social Sciences (SPSS) version 20.0 for Windows.

Outcome Variables

1. Proportion of various grades of astrocytic and oligodendroglial tumors assessed by histomorphology.
2. Presence of *IDH1*, *ATRX*, *BRAFV600E*, and *p53* mutations in different grades of astrocytic and oligodendroglial tumors.

Outcome Analysis

a. Qualitative data were expressed in the form of percentages and proportions.
b. Significance of difference in the proportion was calculated by chi-square and $p < 0.05$ was taken as significant.

Results

During the period of 18 months from May 2019 until the completion of the study, i.e., October 2020, 490 neurosurgical biopsies were received for histopathological examination in the department of pathology, out of which 77 cases of astrocytic and oligodendroglial tumors with complete clinical history and radiological findings were studied for histomorphology and immunohistochemical analysis of *IDH1* mutation, *ATRX* expression, *p53* mutation, *Ki-67*, and *BRAF V600E* mutations.

Clinical Data

Age- and Gender-Wise Distribution

Out of 77 cases, 47 (61.03%) were males and 30 (38.96%) were females with male:female ratio of 1.5:1. The age range of study subjects was 4 to 71 years with a mean age of 39.84 ± 15.84 years. The highest number of cases were in

the age group 21 to 40 years (29 cases), which constituted 37.66% of total cases, followed by 41 to 60 years (27) cases (35.5%). The least number of cases were in the age group > 60 years old (11.8%).

Distribution Based on Site and Clinical Features

In our cohort, the most common site for glial tumors was the frontal lobe (23.4%), followed by temporal, parietal, and frontoparietal (10.4%) each. Forty-eight (62.3%) patients presented with the headache, and 22 (28.9%) patients presented with seizures. Fifteen (19.7%) patients presented with clinical features, suggesting focal neurological deficits, raised ICT, and behavioral/neurocognitive changes. Twelve (15.6%) patients presented with altered sensorium and the remaining 8 (10.5%) of patients presented with other features as vertigo, vision defect, and tinnitus.

Histological Distribution of Tumors and WHO Grade

In the current study, the most common glial tumor was glioblastoma (GBM) (29 cases, 37.7%), followed by diffuse astrocytoma (18.2%) and anaplastic oligodendroglioma (15.6%). Together, these three tumor types constituted more than 70% of all tumors (►**Fig. 1**). Overall, 9.1% of tumors in the cohort were classified as WHO Grade I, 32.4% as Grade II, 20.8% as Grade III, and 37.7% as Grade IV tumors. Grade I glial tumors included pilocytic astrocytoma (PA, 9.1%). Grade II tumors included were diffuse astrocytoma (DA, 18.2%), oligodendroglioma (ODG, 13%), and pleomorphic xanthoastrocytoma (PXA, 1.3%). Grade III tumors were anaplastic astrocytoma (AA, 5.2%) and anaplastic oligodendroglioma (15.6%). In GBM (WHO Grade IV), 22 cases were of glioblastoma multiformae, not otherwise specified (28.6%), 2 cases were each of giant cell GBM, gliosarcoma and epithelioid GBM, and 1 case of GBM with a primitive neuronal component. There were seven cases of pilocytic astrocytoma; out of which five cases (71.4%) were infratentorial and two cases (29.6%) were supratentorial, while in other glial tumors, 68 cases (97.1%) were supratentorial and 2 cases (2.7%) were infratentorial.

Histopathology Data

In all cases, histomorphological features such as cytological atypia, mitosis, microvascular proliferation, and necrosis were studied and the WHO grading was done. [►**Table 1**]

However, based on histomorphological findings, all astrocytic and oligodendroglial tumors were placed in not otherwise specified (nos) category with respect to the WHO grade, according to the updated WHO 2016 classification.

Immunohistochemistry Data

In pilocytic astrocytoma, only a single case showed *BRAFV600E* mutation (14.3%), while *IDH1*, *ATRX*, and *p53* mutations were not detected in any of the cases (►**Fig. 2**). Out of 15 cases of

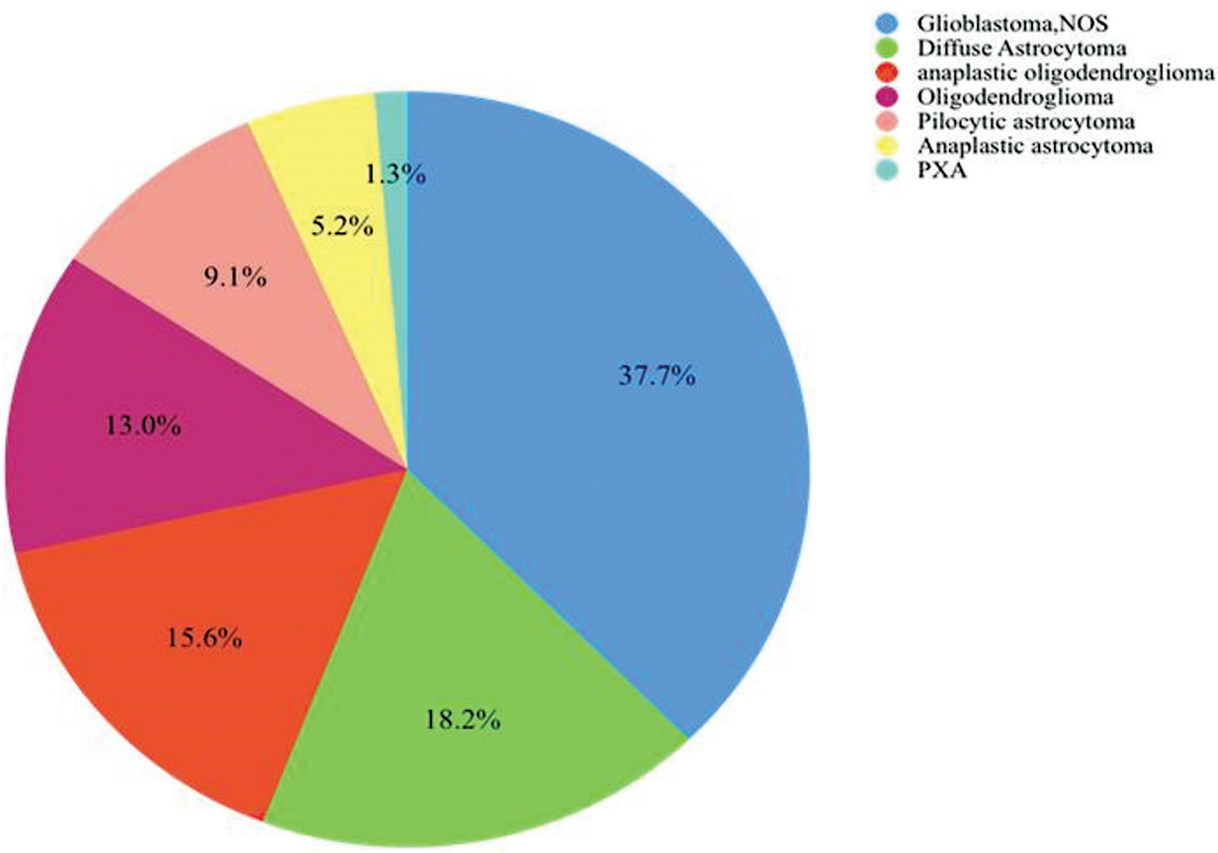

Fig. 1 Histomorphological distribution of tumors.

Table 1 Microscopic findings in astrocytic and oligodendroglial tumors

Microscopic findings		Astrocytic tumors (55)				Microscopic findings		Oligodendroglial tumors (22)	
		Grade I ($n=7$)	Grade II ($n=15$)	Grade III ($n=4$)	Grade IV ($n=29$)			Grade II ($n=10$)	Grade III ($n=12$)
Cytological atypia		2 (28.6%)	15 (100.0%)	4 (100.0%)	29 (100.0%)	Cytological atypia		10 (100.0%)	12 (100.0%)
Mitosis	Absent	5 (71.4%)	11 (73.3%)	0		Mitosis	Absent	1 (10%)	0
	Low (<4/ 10 hpf)	2 (28.6%)	4 (26.7%				low ≤5/10 hpf	9 (90%)	2 (16.7%)
	High (≥5/ 10 hpf)	0	0	4 (100.0%)	29 (100.0%)		High (>6/10 hpf)	0	10 (83.3%)
Microvascular proliferation		4 (57.1%)	0	0	29 (100.0%)	Microvascular proliferation		1 (10.0%)	9 (75.0%)
Necrosis		0	0	0	29 (100.0%)	Necrosis		0	6 (50.0%)

WHO grade II tumors (diffuse astrocytoma, nos, and PXA), 10 cases showed *IDH1* mutation (66.7%), 13 cases showed loss of *ATRX* expression (86.7%), and 7 cases showed *p53* mutation (46.7%). In four cases of anaplastic astrocytoma; nos, WHO grade III, two cases showed *IDH1* mutation (50%), three cases showed loss of *ATRX* expression (75%), and three cases showed *p53* mutation (75%) (►**Fig. 3**). Out of 29 cases of WHO grade IV tumors (GBM and its variants), 6 cases showed *IDH1* mutation (20.7%), 10 cases showed loss of *ATRX* expression (34.4%), 25 cases showed *p53* mutation (86.2%), and 2 cases of epithelioid glioblastoma showed *BRAFV600E* mutation (►**Figs. 4** and **5**). A statistically significant association was found in astrocytomas for *IDH1* mutation, *ATRX* loss, and *p53* mutation ($p < 0.05$; Chi-square test).

Among 22 oligodendroglioma tumors, 10 cases had WHO grade II oligodendrogliomas, 8 cases showed *IDH1* mutation (80%), and one case showed *p53* mutation (10%), while 12 had WHO grade III tumors (anaplastic oligodendroglioma), of which 10 cases showed *IDH1* mutation (83.3%). *ATRX* expression was retained in all cases(►**Fig. 6**) (►**Table 2**). A statistically significant association was found in oligodendrogliomas for *IDH1* mutation and retained *ATRX* expression ($p < 0.05$, Chi-square test).

In the current study, we tried to correlate *IDH1* mutation and *p53* mutation with age in all diffusely infiltrating glial tumors (►**Tableas 3** and **4**).

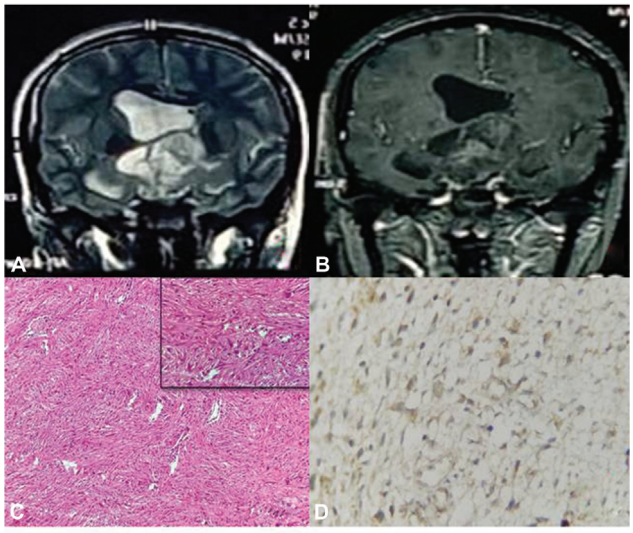

Fig. 2 (**A**, **B**) MRI showing heterogeneously enhancing solid cystic mass lesion in the suprasellar region compressing and splaying the optic nerve and optic chiasma with no obvious extension into the sella, reported as suggestive of the likelihood of craniopharyngioma. (**C**) Microphotograph showing a piloid pattern (Rosenthal fibers and eosinophilic granular bodies in the inset), (**D**) as well as showing cytoplasmic immunoreactivity BRAF V600E, and diagnosed as pilocytic astrocytoma (H&E stain, ×100 and ×400).

Radiological Findings versus Histopathology Diagnosis

In the current cohort of 77 cases, radiology diagnosis was similar in 64 cases with histopathology, while in 13 cases (16.9%) there was radiological pathological discordance. Out of these 13 cases, five cases were of glioblastoma on histomorphology, which were misdiagnosed as tuberculomas (2 cases), hematoma, metastasis, and meningioma on radiology. Glioblastoma, tuberculoma, and metastasis had extensive central necrosis, appeared as hypointense on diffusion-weighted sequence with surrounding edema and ring-like contrast enhancement on imaging, so it can be misdiagnosed. Sometimes, glioblastoma can cause extensive intracranial hemorrhage that can be diagnosed as a hematoma. Similarly, superficially cortically located glioblastoma can elicit extensive meningeal reaction on imaging and confused with meningioma (►**Fig. 5A**, **B**). Five cases diagnosed as pilocytic astrocytoma on histomorphology were misdiagnosed as ependymoma (2 cases), benign cyst and cystic craniopharyngioma (2 cases) on radiology. This could be due to as in CT scan pilocytic astrocytoma as well as these lesions appear as cystic lobulated mass with a solid nodule as well as in MRI both are T1 hypointense and T2 hyperintense lesion (►**Fig. 2A**, **B**). Three cases of anaplastic oligodendroglioma were misdiagnosed as pilocytic astrocytoma, metastasis, and neurocytoma as these lesions appear as solid cystic space-occupying mass with calcification in neuroimaging and misinterpretation can occur. Hence, radiopathological correlation is of the greatest importance in relation to patient care and to reduce false rates but histomorphology is

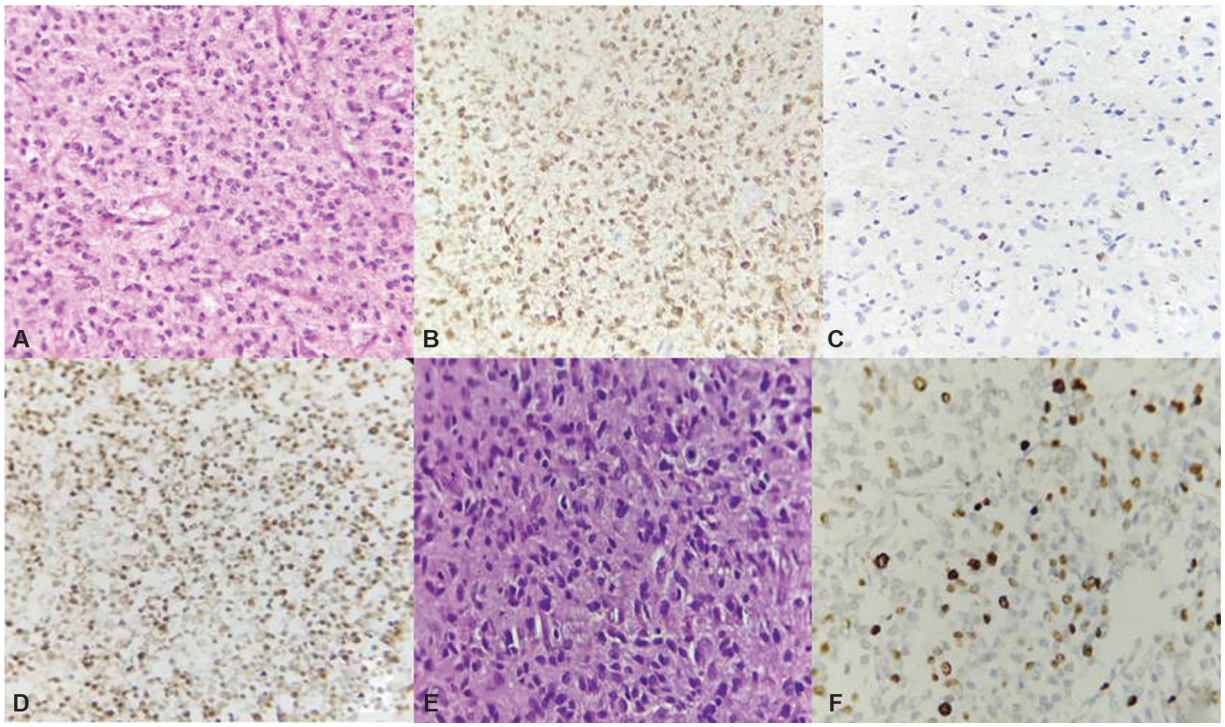

Fig. 3 (**A**) Diffuse astrocytoma showing fibrillary astrocytes dispersed in the neurofibrillary matrix with moderate cytological atypia (H&E, X100). (**B–D**) Microphotograph showing cytoplasmic immunoreactivity with IDH1R132H, loss of ATRX expression, nuclear immunoreactivity with p53 (×100). (**E, F**) Anaplastic astrocytoma showing anaplasia and mitosis as well as high MIB-1 labeling index (H/E stain, ×400, ×100).

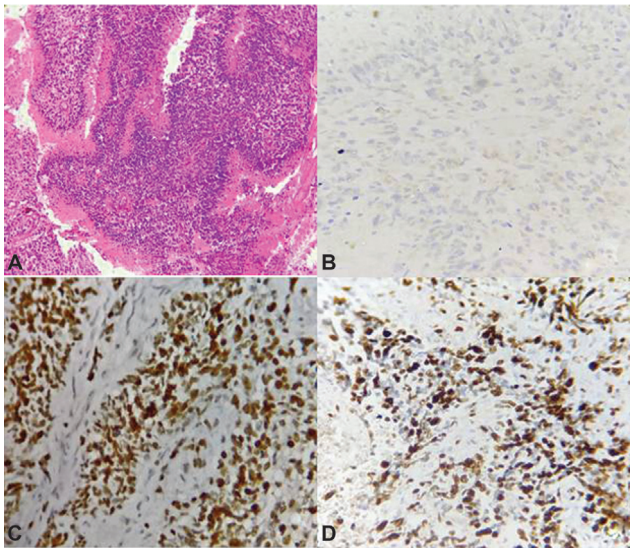

Fig. 4 (**A**) Glioblastoma multiformae showing palisading necrosis (H&E stain; x100). (**B–D**) Microphotograph showing immunonegativity with IDH1 R132H, nuclear immunoreactivity with p53, and a high MIB score (x100, x400).

considered the gold standard for diagnosis and subsequent patient treatment.

Follow-Up

Seventy-seven patients were done craniotomies; no intraoperative death was reported. After surgical intervention; 11 patients (14.4%) had residual neurological deficits and 17 patients (22.1%) had deteriorating neurological status. Postoperative infection (wound sepsis and pneumonia) occurred in seven patients (9.1%) during the follow-up period. In a follow-up period of 3 months, 6 patients with glioblastoma and 2 patients with diffuse astrocytoma died.

Classification of Adult Diffuse Gliomas and Glioblastomas using the Indian Society of Neuro-oncology (ISNO) Guidelines

The Indian Society of Neuro-oncology (ISNO) recommended a more empirical and strategic approach of using ATRX and IHC in addition to *IDH* mutation for the classification of adult diffuse gliomas and glioblastomas in a resource-limited setting. They recommended that the beginning screen is a histological review, where the diffuse infiltrative growth pattern should be established, and only then the further steps can be followed. Once this is confirmed, the phenotype of the tumor should be recognized, i.e., astrocytoma, oligodendroglioma, oligoastrocytoma (ambiguous morphological pattern), and GBM. These tumors are then graded (as II or III) based on the traditional histological criteria of cellularity and mitosis. After histology, IHC should be performed.

Out of 29 cases of glioblastomas, in > 55 years of age group, there were 11 cases and all were IDH1 negative and put into the category of wild-type GBM, whereas the remaining cases ($n = 18$) were in the < 55 year age group, and IDH1 positivity was seen in 6 cases with ATRX loss only in 3 cases and categorized as GBM, *IDH1* mutant (i.e., secondary GBM, $n = 3$). IDH1 negativity was seen in

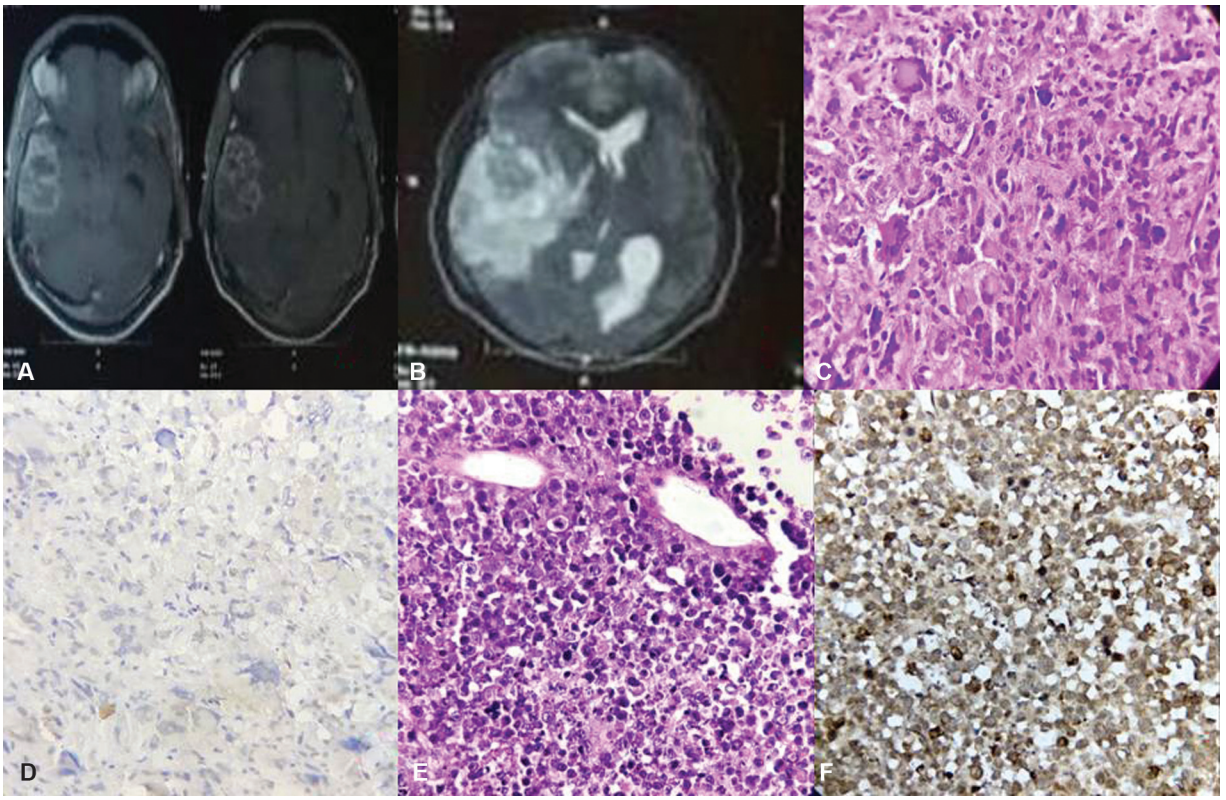

Fig. 5 (**A, B**) MRI showing a relatively large well-defined predominantly extra-axial mass lesion in the right temporal convexity, appearing heterogeneously hyperintense on T2WI, with cystic areas of necrosis, intense heterogeneous enhancement, and lobulated margins; reported as atypical meningioma. (**C, D**) Later it was diagnosed as a giant cell glioblastoma and microphotograph showing giant and pleomorphic cells as well as immunonegativity for IDH1 R132H (H&E, x400). (**E, F**) Epithelioid GBM showing pleomorphic round to polygonal cells with vesicular nuclei and prominent nucleoli as well as cytoplasmic immunoreactivity for BRAF V600E (H&E stain, x400).

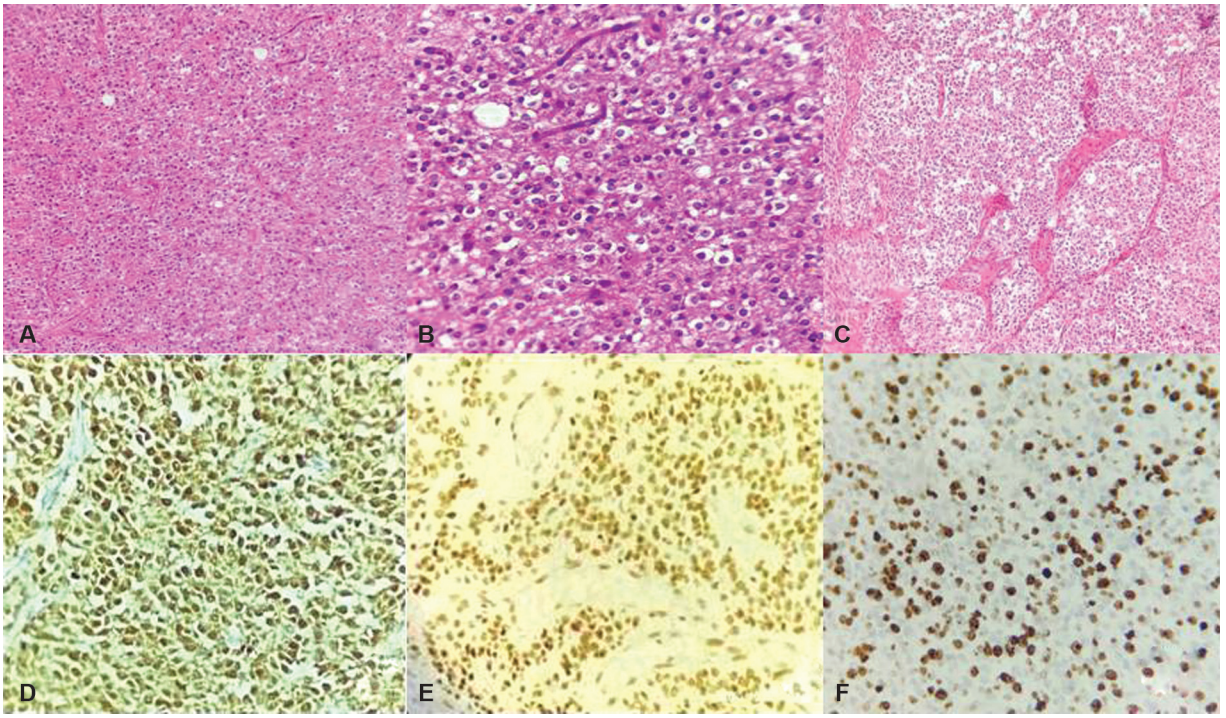

Fig. 6 (**A, B**) Oligodendroglioma showing monomorphic cells with thin plexiform vasculature as well as fried egg appearance of cells and chicken wire blood vessels (H&E stain; x100, x400). (**C–F**) Anaplastic oligodendroglioma showing increased cellularity and microvascular proliferation, immunoreactivity with IDH1 R132H, ATRX nuclear protein, and a high MIB-1 score (H&E; x100, x400).

Table 2 Immunohistochemical findings in astrocytic and oligodendroglial tumors

IHC markers	Astrocytic tumors ($n = 55$)				P value (Chi- square test)	IHC markers	Oligodendroglial tumors ($n = 22$)		p-value (Chi-square test)
	Grade I ($n = 7$)	Grade II ($n = 15$)	Grade III ($n = 4$)	Grade IV ($n = 29$)			Grade II ($n = 10$)	Grade III ($n = 12$)	
IDH1 mutation	0	10 (66.7%)	2 (50.0%)	6 (20.7%)	0.01	IDH1 mutation	8 (80.0%)	10 (83.3%)	<0.01
ATRX loss	0	13 (86.7%)	3 (75.0%)	10 (34.4%)	<0.01	ATRX retained	10 (100%)	12 (100%)	<0.01
p53 overexpression	0	7 (46.7%)	3 (75.0%)	25 (86.2%)	0.01	p53 overexpression	1 (10.0%)	0	–
BRAFV600E mutation	1 (14.3%)	–	–	2 (6.9%)		*BRAFV600E* mutation	–	–	–

Table 3 Correlation of *IDH1* mutation with age in diffusely infiltrative glial tumors

IDH1 mutation	Age group		p-Value
	up to 40 years	>40 years	Chi-square test
Positive	18 (51.5%)	14 (40%)	0.33
Negative	17 (48.5%)	21 (60%)	

[a]DH1 mutation age group *p*-value.
[b]Up to 40 years > 40 years Chi-square test.
[c]Positive 18 (51.5%) 14 (40%) 0.33.
[d]Negative 17 (48.5%) 21 (60%).

Table 4 Correlation of p53 mutation with age in diffusely infiltrative glial tumors

p53 mutation	Age group		p-Value
	Up to 40 years	>40 years	Chi-square test
Positive	15 (42.9%)	21 (60%)	0.15
Negative	20 (57.1%)	14 (40%)	

12 cases. Out of 12 *IDH1*-negative cases, 5 cases showed ATRX loss and 7 cases showed ATRX expression retention (►**Table 5**).

Discussion

The understanding of the pathogenesis and biology of gliomas has gone through mutinous changes recently. The updated 2016 WHO classification of CNS tumors has included well-established molecular parameters into the classification of diffuse gliomas.[5] For higher diagnostic accuracy, categorization of glial tumors into different prognostic groups as well as optimal individualization of treatment, and incorporation of molecular information have become mandatory.[9] In the light of the ISNO consensus, the standard approach to all diffuse astrocytic and oligodendroglial gliomas begins with performing IHC for *ATRX* and *IDH1-R132H* expression.[10] In the current study, we used immunohistochemistry to reveal *IDH1-R132H* and *ATRX* status instead of sequencing, aiming to dispense a mature and straightforward tool for clinical practice. So, our results also revealed that the IDH1-R132H and (or) ATRX loss status could be necessary to provide the basic molecular information for the "integrated diagnosis" of gliomas. Besides these two markers, *p53* mutation, *BRAFV600E* mutation, and Ki-67 were used for an integrated diagnosis.

In the current cohort, 77 cases of astrocytomas and oligodendrogliomas were evaluated under a light microscope for histomorphology and were subjected to immunohistochemical study.

In the present study, males (61%) were affected more than females with a male to female ratio of 1.5:1 and this was in coherence with other studies.[11–13] The ages ranged from 4 to

Table 5 ISNO algorithm for classification of GBM

Histologically GBM, Age >55 years ($n=11$)		Histologically GBM, Age <55 year ($n=18$)			
IDH1 positive (GBM IDH mutant)	IDH1 negative (GBM, wild-type)	IDH positive (GBM IDH mutant)		IDH negative (GBM,NOS)	
N = 0	N = 11	ATRX loss (characteristic)	ATRX retained, advised FISH for 1p/19q co deletion	ATRX loss, advised DNA sequencing for rare IDH mutation	ATRX retained, FISH advised for 1p/19q co deletion
		$N=3$	$N=3$	$N=5$	$N=7$

71 years, with a mean age of 39.84 ± 15.84 years, which was comparable to the study done by Chatterjee et al, where the age range was 11 to 68 years and the mean age was 46.4 years.[13] Diffuse gliomas and glioblastomas were found more commonly in the third and fourth decades of life, a finding similar to that of a study done by Sumathi et al.[14] In our study, the frontal lobe was the most common site (23.4%) of involvement by glial tumors and most common presenting complain was headache (62.3%), followed by seizure (28.9%) and a similar observation was also made by Hamdani et al, where the most common site was frontal lobe (23.2%) and the headache was the most common symptom (68.2%), followed by seizure (34%).[15]

After the implementation of the updated WHO 2016 classification on morphological assessment, in the current series most common glial tumor was glioblastoma (GBM) (29 cases, 37.7%) and it was similar to study done by Dhar et al and Ganghoria et al, where they studied the spectrum of intracranial tumors and found that glioblastomas were most common in all tumors as well as in astrocytic tumors.[16,17] Following glioblastoma, diffuse astrocytoma (18.2%) and anaplastic oligodendroglioma (15.6%) were common. Together, these three tumor types constituted more than 70% of all tumors. A study performed by Thota et al only on diffusely infiltrating astrocytomas, 74 cases were of GBM (64.9%), followed by anaplastic astrocytomas (18.9%) and diffuse astrocytoma (16.2%). Hence, glioblastomas were the most common tumor, followed by anaplastic astrocytomas. Here, the variation in the frequency may be due to the noninclusion of circumscribed tumors as PA, PXA, and oligodendroglioma as done in our study.[8]

In different grades of astrocytic tumors, the WHO Grade IV, glioblastoma were the most common (52.7%), which was in corroboration to other studies done by Hamdani et al (51.2%) and Ahmed et al (61.04%).[15,18] Pilocytic astrocytomas were predominantly in the infratentorial compartment (71.4%), while other glial tumors were predominantly in the supratentorial compartment (97.1%). It is now scrutinized that diffuse astrocytoma and anaplastic astrocytoma share identical genetic profiles and are characterized by *IDH* and *ATRX* mutations. Isocitrate dehydrogenase (IDH) is one of the most well-acknowledged and widely narrated molecular markers in glial tumors, both with astrocytic and oligodendroglial differentiation. The frequency of IDH mutation in diffuse glioma is variable, ranging from 54% to 90%.[19–21] IDH mutation is rare in pilocytic astrocytoma and primary glioblastoma (<10%).[20] *ATRX* mutation is also a peculiarity of astrocytic tumors, which on IHC can be detected by loss of nuclear expression by tumor cells. In our observation, none of the pilocytic tumors showed *IDH1* mutation, whereas it was 66.7% in diffuse astrocytoma, and 50% in anaplastic astrocytoma, which was comparable to the study by Cai et al and Watanabe et al.[20,22] Therefore, *IDH1* mutation was found more common in DA as compared with AA, which was also equitable to other studies.[13,22] In the current study, the frequency of *IDH1* mutation in Grade II oligodendroglial tumors was 80% and in anaplastic oligodendroglial tumors it was (83.3%), which was in coherence with other studies.[22] *IDH1* mutation was found statistically significant in both astrocytic tumors and oligodendroglial tumors ($p < 0.05$, Chi-square test).

ATRX mutation was found in 86.7% of DA, 75% of AA, and 34.4% of GBM, while it was retained in pilocytic astrocytoma and oligodendroglioma. It was also statistically significant ($p < 0.05$); the frequency of *ATRX* mutation in our cohort corroborated with other studies.[13,22,23] Jiao et al and Wiestler et al studied that *ATRX* mutation occurs predominantly in DA (60–70%) and AA (70–80%) and is very rare in primary GBM (4–6%) and oligodendroglial tumors, as seen here.[24,25]

TP53 is an essential regulator of the cell cycle and forms a part of the tumor suppressor gene family. *TP53* mutations are established to be almost mutually exclusive with 1p/19q codeletion in gliomas and correlate strongly with astrocytic tumor morphology.[26] The frequency of *p53* mutation was detected statistically significant in astrocytic tumors ($p < 0.05$), comparable to the study done by Chatterjee et al and it was 14.3% in PA, 46.3% in DA, 75% in AA, and 86.2% in GBM in our cohort.[13]

In the current study, *IDH1* mutation was found more common (51.5%) in the younger age group (up to 40 years) as compared with > 40 years (48.5%), but results were not found statistically significant ($p = 0.33$). A study performed by Thota et al also found that *IDH1* mutation was more common in younger patients ($p < 0.001$).[8] *p53* mutation was found more common in individuals > 40 years (60% patients) as compared with those up to 40 years (42.9%) of age. However, the results were not statistically significant ($p = 0.15$). A study performed by Gillet et al showed *p53*

mutation more common in the young age of low-grade glioma.[26] This could be due to different sample sizes and the exclusion of high-grade glioma in their study.

BRAFV600E mutation has been described frequently in circumscribed gliomas such as pleomorphic xanthoastrocytoma (PXA), less often in diffuse adult gliomas, and approximately 50% of cases of epithelioid glioblastoma harbor this mutation.[27,28] The presence of *BRAFV600E* mutations may help in identifying the above tumor types from their mimics, predict tumor behavior, and/or indicate an opportunity for targeted therapy. Out of seven cases of pilocytic astrocytoma, only one case (14.3%) showed positivity for *BRAFV600E* comparable to Myung et al as well as both cases of epithelioid glioblastoma and a single case of pleomorphic xanthoastrocytoma (100%) in our study showed immunoreactivity for BRAF V600E.[29]

Establishing an accurate working diagnosis for glial tumors, the pathology is critical in formulating appropriate surgical goals, predicting the likelihood of lesion recurrence, and guiding postoperative adjunctive management.

In a resource-constrained setting, the ISNO has recommended the guidelines for practical adaptation of the current WHO 2016 classification. In glioblastoma >55 years of age group, all cases (11) were IDH1 negative so classified as GBM; IDH1 wild-type. In < 55 year age group, there were 18 cases of GBM, out of which 6 cases were categorized as GBM, IDH1 mutant type due to immunoreactivity for IDH1 and 12 cases as GBM, nos due to IDH1 negativity. To our knowledge, this is the first study in north India that used the ISNO guidelines for molecular subgrouping of diffuse gliomas and oligodendrogliomas.

Conclusion

According to the current updated WHO 2016 classification, histomorphological features along with IDH1, ATRX, and p53 status, can be used for the classification of diffuse astrocytoma WHO grade II/III and GBM into molecular subgroups. Diffuse gliomas and oligodendroglial tumors are characterized by *IDH1* mutation, which can be straightforwardly detected by IHC using an antibody against the mutant protein (IDH1R132H). *IDH1* mutation along with loss of nuclear expression of ATRX is a vital feature of DA and AA ($p < 0.01$) and accurately diagnosed by IHC; thus we can avoid the need for expensive investigations such as DNA sequencing and FISH. *IDH1* mutation was not present in any case of pilocytic astrocytoma and *ATRX* mutation was not found in any oligodendroglioma. Therefore, the use of these two markers can confirm the molecular nature of glial tumors. p53 can act as a surrogate marker for astrocytic differentiation. *BRAF V600E* mutation was found in PXA, one case of a pilocytic tumor, and both cases of epithelioid GBM. Hence, *BRAFV600E* mutation helped in the definitive diagnosis of PXA and epithelioid GBM along with histomorphological features. In pilocytic astrocytoma, *BRAFV600E* mutation was less common.

Ethical Approval Statement

Ethical approval had been taken from Institutional Ethics Committee with IEC no. 299/MC/EC/2020; dated 06/06/20.

Authors' Contribution

All the authors have read & approved the manuscript.

Conflict of Interest

None declared.

References

1 McNeill KA. Epidemiology of brain tumors. Neurol Clin 2016;34 (04):981–998
2 Ostrom QT, Gittleman H, Xu J, et al. CBTRUS statistical report: primary brain and other central nervous system tumors diagnosed in the United States in 2009–2013. Neuro-oncol 2016;18(suppl_5):v1–v75
3 McGuire S. World Cancer Report 2014. Geneva, Switzerland: World Health Organization, International Agency for Research on Cancer, WHO Press, 2015. Adv Nutr 2016;7(02):418–419
4 Louis DN, Ohgaki H, Wiestler OD, et al; International Agency for Research on Cancer (IARC) The 2007 WHO classification of tumours of the central nervous system. Acta Neuropathol 2007; 114(02):97–109
5 Louis DN, Ohgaki H, Wiestler OD, Cavenee WK. WHO classification of tumours of the central nervous system. 4th rev. ed. Lyon: IARC Press; 2016
6 Jha P, Suri V, Sharma V, et al. IDH1 mutations in gliomas: first series from a tertiary care centre in India with comprehensive review of literature. Exp Mol Pathol 2011;91(01):385–393
7 Rajeswarie RT, Rao S, Nandeesh BN, Yasha TC, Santosh V. A simple algorithmic approach using histology and immunohistochemistry for the current classification of adult diffuse glioma in a resource-limited set-up. J Clin Pathol 2017;71(01):323–329
8 Thota B, Shukla SK, Srividya MR, et al. IDH1 mutations in diffusely infiltrating astrocytomas: grade specificity, association with protein expression, and clinical relevance. Am J Clin Pathol 2012;138(02):177–184
9 Li QJ, Cai JQ, Liu CY. Evolving molecular genetics of glioblastoma. Chin Med J (Engl) 2016;129(04):464–471
10 Santosh V, Sravya P, Gupta T, et al. ISNO consensus guidelines for practical adaptation of the WHO 2016 classification of adult diffuse gliomas. Neurol India 2019;67(01):173–182
11 Parkin DM. Global cancer statistics in the year 2000. Lancet Oncol 2001;2(09):533–543
12 Jazayeri SB, Rahimi-Movaghar V, Shokraneh F, Saadat S, Ramezani R. Epidemiology of primary CNS tumors in Iran: a systematic review. Asian Pac J Cancer Prev 2013;14(06):3979–3985
13 Chatterjee D, Radotra BD, Kumar N, Vasishta RK, Gupta SK. *IDH1*, *ATRX*, and *BRAF*V600E mutation in astrocytic tumors and their significance in patient outcome in north Indian population. Surg Neurol Int 2018;9:29
14 Sumathi V, Balakrishnan K, Krishna MSS, Maheshwari KU. Histopathological spectrum and grading of CNS tumours in tertiary centre: Case study of 83 cases. J Evid Based Med Healthcare 2016;3:2240–2243
15 Hamdani SM, Dar NQ, Reshi R. Histopathological spectrum of brain tumors: a 4-year retrospective study from a single tertiary care facility. Int J Med Sci Public Health 2019;8:673–676
16 Dhar A, Bhat AR, Nizami FA, et al. Analysis of brain tumors in Kashmir Valley - A 10 year study. Bangladesh J Med Sci 2014;13:268–277
17 Ghanghoria S, Mehar R, Kulkarni CV, Mittal M, Yadav A, Patidar H. Retrospective histological analysis of CNS tumors – A 5 year study. Int J Med Sci Public Health 2014;3:1205–1207

18 Ahmed Z, Muzaffar S, Kayani N, Pervez S, Husainy AS, Hasan SH. Histological pattern of central nervous system neoplasms. J Pak Med Assoc 2001;51(04):154–157
19 Ichimura K, Pearson DM, Kocialkowski S, et al. IDH1 mutations are present in the majority of common adult gliomas but rare in primary glioblastomas. Neuro-oncol 2009;11(04): 341–347
20 Watanabe T, Nobusawa S, Kleihues P, Ohgaki H. IDH1 mutations are early events in the development of astrocytomas and oligodendrogliomas. Am J Pathol 2009;174(04): 1149–1153
21 Zou P, Xu H, Chen P, et al. IDH1/IDH2 mutations define the prognosis and molecular profiles of patients with gliomas: a meta-analysis. PLoS One 2013;8(07):e68782
22 Cai J, Zhu P, Zhang C, et al. Detection of ATRX and IDH1-R132H immunohistochemistry in the progression of 211 paired gliomas. Oncotarget 2016;7(13):16384–16395
23 Cai J, Zhang C, Zhang W, et al. ATRX, IDH1-R132H and Ki-67 immunohistochemistry as a classification scheme for astrocytic tumors. Oncoscience 2016;3(7-8):258–265
24 Jiao Y, Killela PJ, Reitman ZJ, et al. Frequent ATRX, CIC, FUBP1 and IDH1 mutations refine the classification of malignant gliomas. Oncotarget 2012;3(07):709–722
25 Wiestler B, Capper D, Holland-Letz T, et al. ATRX loss refines the classification of anaplastic gliomas and identifies a subgroup of IDH mutant astrocytic tumors with better prognosis. Acta Neuropathol 2013;126(03):443–451
26 Gillet E, Alentorn A, Doukouré B, et al. TP53 and p53 statuses and their clinical impact in diffuse low grade gliomas. J Neurooncol 2014;118(01):131–139
27 Appin CL, Brat DJ. Molecular genetics of gliomas. Cancer J 2014;20 (01):66–72
28 Ellison D, Kleinschmidt-DeMasters B, Park SH. Epithelioid glioblastoma. In: Louis DN, Ohgaki H, Wiestler OD, Cavenee WK, eds. WHO Classification of Tumors of the Central Nervous System, Revised 4t. France: International Agency for Research on Cancer (IARC); 2016 50,51
29 Myung JK, Cho H, Park CK, Kim SK, Lee SH, Park SH. Analysis of the BRAF(V600E) mutation in central nervous system tumors. Transl Oncol 2012;5(06):430–436