







# Reconstruction of the Long Process of the Incus by Use of Glass Ionomer Cement: Our Experience

Khaled Abd El Rahman Ali<sup>1</sup>  Maha Ahmed Ibrahim<sup>2</sup>  Mohammed Ahmed Hussien<sup>3</sup>   
Khaled Gamal Dahy<sup>1</sup> 

<sup>1</sup> Department of Otolaryngology-Head and Neck Surgery, Sohag University, Sohag, Egypt

<sup>2</sup> Department of Otolaryngology-Head and Neck Surgery, Audiology Unit, Sohag University, Sohag, Egypt

<sup>3</sup> Department of Otolaryngology-Head and Neck Surgery, Assiut Al-Azhar University Hospital, Assiut, Egypt

Address for correspondence Khaled Gamal Dahy, MD, Department of Otolaryngology-Head and Neck Surgery, Sohag University, Sohag, Egypt (e-mail: khgamal272@gmail.com).

Int Arch Otorhinolaryngol 2022;26(4):e697–e700.

## Abstract

**Introduction** Chronic suppurative otitis media is one of the most common causes of reversible conductive hearing loss which can lead to necrosis of the ossicles. The incus, especially its long process, is the most common ossicle affected.

**Objectives** The present study aims to assess the use of glass ionomer cement for the reconstruction of the long process of the incus.

**Methods** The present study was conducted on 27 patients with chronic suppurative otitis media with central perforation with dry and quiescent ears with an eroded long process of the incus submitted to tympanoplasty. The audiological evaluations were done on all patients, including preoperative and postoperative evaluation of the air-bone gap; the average pure tone threshold was done 6 months postoperatively.

**Results** The average air pure tone threshold was 42.8 dB preoperatively and 22.5 dB postoperatively. The postoperative air pure tone thresholds were significantly smaller than the preoperative values ( $p < 0.01$ ). The air-bone gap was 30.5 dB at 500 Hz, 31.6 dB at 1 KHz, and 24.1 dB at 2 KHz preoperatively, and 7.7 dB at 500 Hz, 7.2 dB at 1 KHz, and 7.1 dB at 2 KHz postoperatively at the end of 6 months of follow-up. There were significant hearing gains in the air-bone gap ( $p < 0.001$ ).

**Conclusion** Glass ionomer cement is a useful and effective material for bridging the defect of the long process of the incus.

## Keywords

- ▶ glass ionomer cement
- ▶ hearing loss
- ▶ ossiculoplasty
- ▶ audiometry

## Introduction

Chronic suppurative otitis media is one of the most common causes of reversible conductive hearing loss in the world, especially in developing countries because of poor socio-economic status, poor nutrition, poor hygiene, and lack of health education. Both genders can be affected, and every age group is vulnerable. The natural ossicular chain plays an important role in transporting sound efficiently from the environment to the oval window.<sup>1</sup> Diseases of the middle ear, especially chronic

otitis media, can interrupt this transfer. The incus, especially its long process, is the most common ossicle affected.<sup>2,3</sup> Other problems of the ossicular chain include a defective stapes superstructure with or without a defective incus, and defective malleus.<sup>4</sup>

The surgical solution for chronic suppurative otitis media is tympanoplasty. Eradication of inflammation by reconstruction of the sound conduction system between the eardrum and inner ear with a well-aerated tympanic cavity

received

June 18, 2021

accepted after revision

December 1, 2021

published online

June 14, 2022

DOI <https://doi.org/>

10.1055/s-0042-1743276.

ISSN 1809-9777.

© 2022. Fundação Otorrinolaringologia. All rights reserved.

This is an open access article published by Thieme under the terms of the

Creative Commons Attribution-NonDerivative-NonCommercial-License,

permitting copying and reproduction so long as the original work is given

appropriate credit. Contents may not be used for commercial purposes, or

adapted, remixed, transformed or built upon. (<https://creativecommons.org/licenses/by-nc-nd/4.0/>)

Thieme Revinter Publicações Ltda., Rua do Matoso 170, Rio de Janeiro, RJ, CEP 20270-135, Brazil

were the main goals of successful tympanoplasty operations.<sup>5</sup> The main goal of ossiculoplasty is to establish ossicular continuity to improve the sound conduction and impedance matching system with an intact tympanic membrane. There has been growing research interest in the restoration of ossicular defects in chronic otitis media surgery for > 50 years. Ossiculoplasty can be accomplished via various replacement prostheses: autograft, homograft, and allograft.<sup>6</sup>

Glass ionomer cement (GIC) has been widely used in dentistry for many years. For the last 2 decades, GICs have been used as a treatment option for ossiculoplasty. Helms et al. first reported its use in middle ear surgery in the 1990s.<sup>7</sup> It is now used in ear surgery for various indications, such as ossicular reconstruction, bony external ear canal repair, stabilization of cochlear implants, repair of dural defects, and reconnecting of gaps created by incudostapedial necrosis.<sup>8</sup> Several studies have shown that there was a considerable increase in the hearing quality of patients when the ossicular chain was rebuilt with GIC.<sup>9–12</sup> The ideal bone cement utilized for this objective ought to be moldable, effectively applied, quickly setting, nonpoisonous, fluid-resistant, fit for osteointegration, and ready to affect insignificant inflammation.<sup>13</sup>

The present study aims to assess the use of GIC for the reconstruction of the long process of the incus.

## Materials and methods

A prospective study was done. Tympanoplasty was performed with ossiculoplasty in patients with chronic suppurative otitis media between 2016 and 2018. Ethical clearance was obtained from the institutional ethical board with ethics committee No. Soh-Med-2102–45. Informed consent was obtained from the patients before the start of the study.

Chronic otitis media with central perforation were selected, based on the following inclusion and exclusion criteria. Only patients with dry and quiescent ears with an eroded long process of the incus were included in the present study. Chronic otitis media squamous type, traumatic perforations, and previous ear surgeries were excluded.

After proper selection and evaluation, all the cases underwent the standardized procedure of tympanoplasty under general anesthesia, and the postaural approach was used. Then, the middle ear was exposed and inspected for the disease process, such as polypoidal mucosa, granulation tissue, fibrous tissue, and glue. The ossicles were exposed and GICs were used for bridging the defect of the long process of the incus to the head of stapes. Glass ionomer cements are formed of a sterile powder and a liquid, later on during operation; the component was mixed for 7 seconds, and the mixture must be used from 1 to 3 minutes. Precautions should be kept in mind before, during, and after the application of GIC: it is important to remove the mucosal membrane and all other soft tissues from the surface of the actual bone area since GIC does not adhere to soft tissue, the middle ear cavity should be dry before the application of GIC, and any bleeding in the middle ear should be controlled first. Application of GIC should be done under high magnification; we use a straight or slightly curved needle to apply GIC with great precaution not to allow the attachment between the GIC

and normal structures like the tympanomeatal flap, the malleus, the footplate, and the middle ear mucosa to avoid undesirable reactions with soft tissues or ossicular fixation; therefore, a small piece of gelfoam can be used over critical structures such as the facial nerve and the stapes footplate for their protection. A fine suction cannula was used for modifying the shape of the GIC to reach the nearest shape of a normal incudostapedial joint. Usually, the defect is < 2mm, but if it is larger, gap serial applications can be used with enough time between each application to allow the previous one to harden, then we build on it to reach the desirable reconstruction, as shown in **Fig. 1**. The GIC hardened 7 minutes after its application, and the movement of the ossicles was checked to ensure their continuity and mobility. Temporalis fascia graft was placed by the underlay technique for the repair of the tympanic membrane perforation in all patients.

All patients were discharged on the 2<sup>nd</sup> postoperative day. The patients were started on systemic antibiotics, analgesics, and antihistamines for 1 week. Postoperatively, all patients were followed-up for a total of 6 months with regular intervals at the 1<sup>st</sup>, 3<sup>rd</sup>, and 6<sup>th</sup> months.

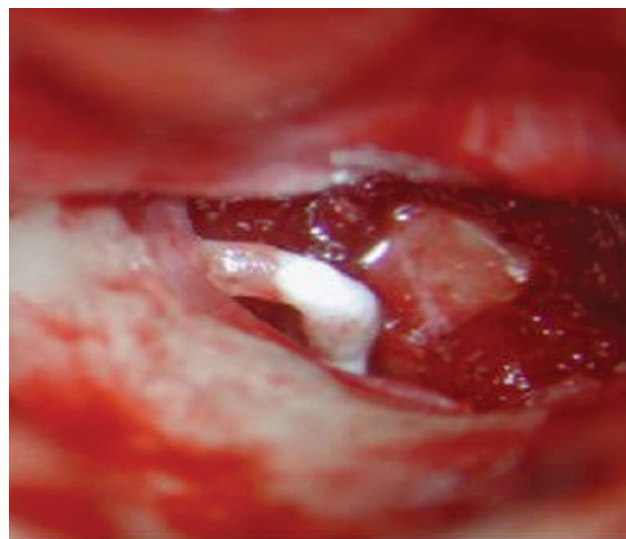
Audiological evaluations were done on all patients, including preoperative and postoperative evaluation of the air-bone gap; the average pure tone threshold was performed 6 months postoperatively to assess the level of hearing improvement.

## Statistical analysis

All collected cases were revised for completeness and consistency. Recorded data were entered on a computer using Microsoft Excel 2010 for windows (Microsoft Corporation, Redmond, WA, USA). A paired *t*-test was used to compare preoperative and postoperative results. A *p*-value < 0.05 was considered statistically significant.

## Results

The present study was conducted on 27 patients with ages ranging from 13 to 55 years old; 15 of them were female and



**Fig. 1** Glass ionomer cement reconstruction of the right incudostapedial joint

**Table 1** Characteristics of the patients

Variable	Mean $\pm$ SD
Age	34 $\pm$ 6.7
Gender	
Male	12 (44.4%)
Female	15 (55.6%)
Side	
Right	15 (55.6%)
Left	12 (44.4%)
Size of perforation	
Small-sized	15 (55.6%)
Moderate-sized	10 (37%)
Subtotal perforation	2 (7.4%)

Abbreviation: SD, standard deviation.

12 were males, with a history of otitis media ranging from 6 to 9 years, as shown in ►Table 1. The average air pure tone threshold was 42.8 dB preoperatively and 22.5 dB postoperatively. The postoperative air pure tone thresholds were significantly smaller than the preoperative values ( $p < 0.01$ ). The air-bone gap was 30.5 dB at 500 Hz, 31.6 dB at 1 KHz, and 24.1 dB at 2 kHz preoperatively, and 7.7 dB at 500 Hz, 7.2 dB at 1 KHz, and 7.1 dB at 2 kHz postoperatively at the end of 6 months of follow-up. There were significant hearing gains in the air-bone gap ( $p < 0.001$ ), as shown in ►Fig. 2.

## Discussion

Chronic suppurative otitis media owing to poor socio-economic status and poor environmental conditions account for morbidity in ~ 5% of the total population. Sound transmission from the tympanic membrane to cochlear fluids needs a normal ossicular chain. The incus is the most frequently affected ossicle by pathological disease (chronic suppurative

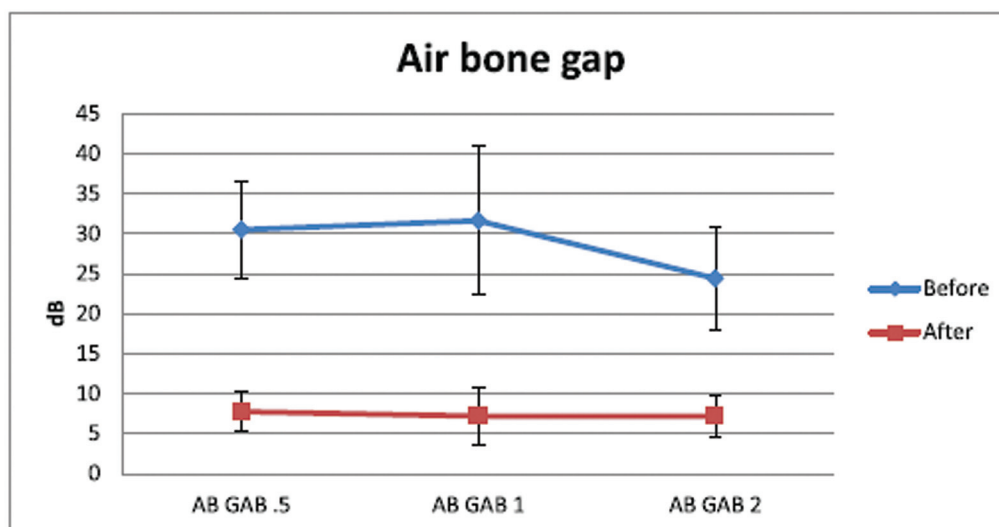
otitis media), especially its long process and lenticular process, which is due to its anatomical position and blood supply. The defect of the long process or of the lenticular process of incus results in conductive hearing loss.<sup>14</sup>

In the present study, we have evaluated the results of using glass ionomer bone cement to reconstruct the long process of the incus in patients with chronic otitis media with central perforation, dry and quiescent type, with a large air-bone gap, while patients with chronic otitis media squamous type were excluded because it is a destructive pathology and usually more than one ossicle will be affected.

Glass ionomer cement has been widely used in dentistry since the 1960s as a luting and filling restorative material due to its adhesive and other advantageous properties. Glass ionomer cements took place in otology practice, especially in ossiculoplasty operations, since the 1990s.<sup>10</sup> Glass ionomer cements are one of the most used allograft processes. They are used to fill the defect between the long process of the incus and the stapes. Glass ionomer cements provide physiological results close to the function of the natural ossicular chain.

Glass ionomer cement is utilized not only for the rebuilding of the ossicular chain but also for the stabilization of other prostheses, such as Teflon piston, in otosclerosis surgery.<sup>15</sup> According to many authors, GIC reduces surgical revision rates by stabilizing the prosthesis and preventing erosion of the long process of the incus. In the present study, we did not use prostheses to reconstruct the defect; we used GIC only.

O'Reilly et al.<sup>16</sup> reported that there were problems in the stabilization of the interposed incus depending on the anatomy of the middle ear, so it is better to use a prosthesis. Babu et al.<sup>17</sup> reconstructed the defects of the long process of the incus with bone in 18 patients and the reported average pure tone threshold was 51 dB and the postoperative one was 26 dB. The preoperative air-bone gap was 33 dB, while the postoperative value was 10 dB. Kjeldsen et al.<sup>18</sup> performed bone cement ossiculoplasty in 12 patients and reported a postoperative gain  $\geq 10$  dB at average pure tone thresholds in 7 patients and no change in 3 patients.



**Fig. 2** The preoperative and postoperative air-bone gap at 500Hz, 1kHz, 2kHz

Wegner et al. conducted a systematic review and found that no infection or extrusion was observed in patients who underwent ossiculoplasty with GIC.<sup>8,19,20</sup> In a previous study by Celenk et al., there was only 1 occurrence of granulation over the ossicles (2%) and 1 case of extrusion (2%).<sup>21</sup> Ráth et al. found 1 incidence of disintegrating GIC that required revision surgery (3%).<sup>19</sup> We did not find any such complication in our series except in two cases.

Glass ionomer cement has been shown by Driscoll et al. to have adverse effects on soft tissues.<sup>22</sup> According to Yazıcı et al.,<sup>11</sup> the GIC group had an intact graft rate of 78.6%. In our study, we had a 92.6% graft success rate with 2 cases that presented with granular myringitis, which improved with medical treatment later on. To avoid the undesirable effects of GIC, soft tissues should be avoided, the middle ear cavity should be kept dry, and enough time should be given for the GIC to harden.

Celik et al.<sup>23</sup> compared the use of glass ionomer with that of cortical bone for ossiculoplasty and found that closure of the air-bone gap was 16.8 dB in the glass ionomer group and 18 dB in the cortical bone group. Dere et al.<sup>14</sup> did a comparative study between the use of GIC and incus interposition in the reconstruction of long process defects and found that the average pure tone threshold was 42.8 dB, while this value was 35.2 postoperatively in the GIC group. The preoperative air-bone gap was 27 dB and the postoperative value was 20.7 dB. In the incus interposition group, the average preoperative and postoperative air pure tone thresholds were 42.9 and 34.5 dB, respectively, and the postoperative air-bone gaps were 28.7 and 20.2 dB, respectively. In our study, the preoperative air-bone gap was 30.5 dB at 500 Hz, 31.6 dB at 1 KHz, and 24.1 dB at 2 kHz, and 7.7 dB at 500 Hz, 7.2 dB at 1 KHz, and 7.1 dB at 2 kHz postoperatively at the end of 6 months of follow-up. There were significant hearing gains in the air-bone gap ( $p < 0.001$ ).

We believe that this may be proof of the high success rate of GIC, but an increase in the number of cases and in the period of follow-up is necessary.

## Conclusion

Glass ionomer cement is a useful and effective material for bridging the defect of the long process of the incus.

### Funding

The present research did not receive any specific grant from funding agencies in the public, commercial, or not-for-profit sectors.

### Conflict of interests

The authors have no conflict of interests to declare.

## References

- Verhoeff M, van der Veen EL, Rovers MM, Sanders EA, Schilder AG. Chronic suppurative otitis media: a review. *Int J Pediatr Otorhinolaryngol* 2006;70(01):1–12
- Haidar H, Sheikh R, Larem A, et al. Ossicular chain erosion in chronic suppurative otitis media. *Otolaryngol (Sunnyvale)* 2015;5(203):2
- Varshney S, Nangia A, Bist SS, Singh RK, Gupta N, Bhagat S. Ossicular chain status in chronic suppurative otitis media in adults. *Indian J Otolaryngol Head Neck Surg* 2010;62(04):421–426
- Dubey SP, Larawin V. Complications of chronic suppurative otitis media and their management. *Laryngoscope* 2007;117(02):264–267
- Albu S, Babighian G, Trabalzini F. Prognostic factors in tympanoplasty. *Am J Otol* 1998;19(02):136–140
- Yung M. Long-term results of ossiculoplasty: reasons for surgical failure. *Otol Neurotol* 2006;27(01):20–26
- Helms J, Geyer G, Wanek E, Zollner W, Gasser O. Bone replacement part made of glass ionomer cement. *Google Patents*; 1994
- Babighian G. Use of a glass ionomer cement in otological surgery. A preliminary report. *J Laryngol Otol* 1992;106(11):954–959
- Galy-Bernadov C, Akkari M, Mathiolon C, Mondain M, Uziel A, Venail F. Comparison of early hearing outcomes of type 2 ossiculoplasty using hydroxyapatite bone cement versus other materials. *Eur Ann Otorhinolaryngol Head Neck Dis* 2014;131(05):289–292
- Kalcioğlu MT, Uzun İH, Yalçın M, Malkoç MA, Öğreten AT, Hanege FM. Evaluation on shear bond strength of different glass ionomer and hydroxy apatite cements used in ossiculoplasty. *Balkan Med J* 2015;32(01):23–29
- Yazıcı H, Uzunkulaoglu H, Emir HK, Kızılkaya Z, Doğan S, Samim E. Comparison of incus interpositioning technique versus glass ionomer cement application in type 2 tympanoplasty. *Eur Arch Otorhinolaryngol* 2013;270(05):1593–1596
- Watson GJ, Narayan S. Bone cement: how effective is it at restoring hearing in isolated incudostapedial erosion? *J Laryngol Otol* 2014;128(08):690–693
- Brask T. Reconstruction of the ossicular chain in the middle ear with glass ionomer cement. *Laryngoscope* 1999;109(04):573–576
- Dere H, Ozdogan F, Ozcan KM, Selcuk A, Ozcan I, Gokturk G. Comparison of glass ionomer cement and incus interposition in reconstruction of incus long process defects. *Eur Arch Otorhinolaryngol* 2011;268(11):1565–1568
- Tysome JR, Harcourt J. How we do it: ionomeric cement to attach the stapes prosthesis to the long process of the incus. *Clin Otolaryngol* 2005;30(05):458–460
- O'Reilly RC, Cass SP, Hirsch BE, Kamerer DB, Bernat RA, Poznanovic SP. Ossiculoplasty using incus interposition: hearing results and analysis of the middle ear risk index. *Otol Neurotol* 2005;26(05):853–858
- Babu S, Seidman MD. Ossicular reconstruction using bone cement. *Otol Neurotol* 2004;25(02):98–101
- Kjeldsen AD, Grøntved AM. Tympanoplasty with ionomeric cement. *Acta Otolaryngol Suppl* 2000;543(543):130–131
- Wegner I, van den Berg JW, Smit AL, Grolman W. Systematic review of the use of bone cement in ossicular chain reconstruction and revision stapes surgery. *The Laryngoscope* 2015 Jan;125(01):227–233
- Somers T, Van Rompaey V, Claes G, et al. Ossicular reconstruction: hydroxyapatite bone cement versus incus remodelling: how to manage incudostapedial discontinuity. *Eur Arch Otorhinolaryngol* 2012;269(04):1095–1101
- Celenk F, Baglam T, Baysal E, et al. Management of incus long process defects: incus interposition versus incudostapedial rebridging with bone cement. *J Laryngol Otol* 2013;127(09):842–847
- Driscoll CL, Green JD, Beatty CW, McCaffrey TV, Marrs CD. In vitro characteristics of a glass ionomer cement. *Skull Base Surg* 1998;8(04):175–180
- Celik H, Aslan Felek S, Islam A, Demirci M, Samim E, Oztuna D. The impact of fixated glass ionomer cement and springy cortical bone incudostapedial joint reconstruction on hearing results. *Acta Otolaryngol* 2009;129(12):1368–1373