



Lumbar Discal Cyst: Is it a Rare Consequence in Lumbar Disc Disease Spectrum? Short Case Series with Review of Literature and Hypothesis Regarding Etiopathogenesis

Usha Kota Narayana Pai¹ Devaprasad Sathyannarayanan² Harsha Manjarambath Haridas²

¹Department of Pathology, Jubilee Mission Medical College and Research Institute, Thrissur, Kerala, India

²Department of Neurosurgery, Sun Medical and Research Centre, Thrissur, Kerala, India

Address for correspondence Usha Kota Narayana Pai, MD, DCP, DNB, Department of Pathology, Jubilee Mission Medical College and Research Institute, Thrissur 680005, Kerala, India (e-mail: ushapaikn66@gmail.com).

Indian J Neurosurg 2025;14:213–218.

Abstract

Background Lumbar discal cysts are rare intraspinal extradural lesions presenting as lumbar radiculopathy. The rarity of the lesion is sufficient to evoke interest in its diagnosis. The hitherto unsolved etiopathogenesis prompted us to look into these areas in this study.

Objectives 1) To review the literature and summarize the clinicoradiological and histopathological features of the discal cyst. 2) To investigate possible mechanisms in the etiopathogenesis of discal cysts.

Materials and Methods Three patients presented with features suggestive of lumbar disc prolapse and were diagnosed with discal cyst over 1.5 years and were included in this study. All patients underwent lumbar spine magnetic resonance imaging (MRI) and were subsequently treated by cyst excision. The final diagnosis of the discal cyst was based on histopathological features.

Results Out of three patients, two had a discal cyst with disc prolapse, and one had a discal cyst alone. Discal cyst patient underwent excision of cyst alone. Discal cyst patients with disc prolapse underwent discectomy in addition to excision of the discal cyst. One patient had an L2–L3 level discal cyst with disc prolapse, which is uncommon.

Conclusion Lumbar discal cysts, although rare, form an important differential diagnosis in patients with lumbar radiculopathy. They have a distinctive MRI appearance, and because discal cyst and disc prolapse shared similar etiopathological features, we hypothesize that discal cyst is a part of the degenerative disc disease spectrum. We also conclude that discal cyst excision should be coupled with discectomy when LDC is associated with disc prolapse.

Keywords

- ▶ discal cyst
- ▶ lumbar disc prolapse
- ▶ magnetic resonance imaging

Introduction

Low back pain with sciatica could be due to numerous causes. It includes intervertebral disc prolapse and related pathologies, spondylolisthesis, spinal tumors (benign and malignant), and spinal infections. Spinal extradural cysts form an important differential diagnosis for back pain and sciatica. Extradural cysts include discal cysts, arachnoid cysts, synovial cysts, ligamentum flavum cysts, and ganglion cysts. In most of these cases, the histological diagnosis is clear. However, in certain intraspinal extradural cystic lesions, pathology varies and often needs to be correlated with radiological and operative findings. There is considerable overlap in the nomenclature of these cysts. Only a careful perusal of the historical evolution of their nomenclature will give clarity on the exact nature of their pathologies. A case in point is juxta-facet cysts. In various articles, these cysts have meant synovial cysts, while in others, these have meant ganglion cysts. Unless a pathologist is conversant with the myriad of pathologies that constitute spinal extradural cysts, it will continue to remain an enigma.

The lumbar discal cyst is a rare clinical entity that commonly presents as radiculopathy involving compression of single nerve root mimicking intervertebral disc prolapse, usually seen in young patients. So far, most cases have been reported from the Asian continent.¹⁻⁵ A few cases have been reported in the pediatric age group.⁶ Bilateral occurrence of discal cyst has also been reported.⁷ Common sites of lumbar discal cysts are intervertebral spaces L4-L5, L3-L4, and rarely L2-L3.⁸ Among the radiological investigations, MRI plays a pivotal role in the preoperative diagnosis of the discal cyst. MRI shows characteristic isointense T1 and hyperintense T2 lesions with a rim of contrast enhancement.³ Histologically, discal cyst contains fibrous connective tissue without specific epithelial lining cells, and sometimes, hemosiderin deposits are seen due to old hemorrhage.^{1,2} The correlation of clinical features, MRI findings, operative details, and histological characteristics help exclude other differential diagnoses of spinal extradural cysts such as arachnoid cysts, synovial cysts, ligamentum flavum cysts, and ganglion cysts.⁹⁻¹² Concerning management, if conservative treatment fails, controversy hinges on whether surgical cyst excision should be combined with or without discectomy. Here, we present three cases of the discal cyst and review pertinent literature, thereby suggesting a hypothesis about its genesis, which would help us offer a suitable therapeutic option.

Subjects and Methods

Case 1

A 28-year-old man presented with 2 months history of back pain radiating to the left leg. The left leg straight-leg raising (SLR) test was positive. He had no other neurological deficit. MRI showed isointense T1WI and hyperintense T2WI lesion behind and below L4-L5 disc space, ventrolateral to the dural sac, pushing the left L5 root, with peripheral contrast enhancement. There was no evidence of significant disc prolapse. Preoperatively, the diagnosis was not apparent to

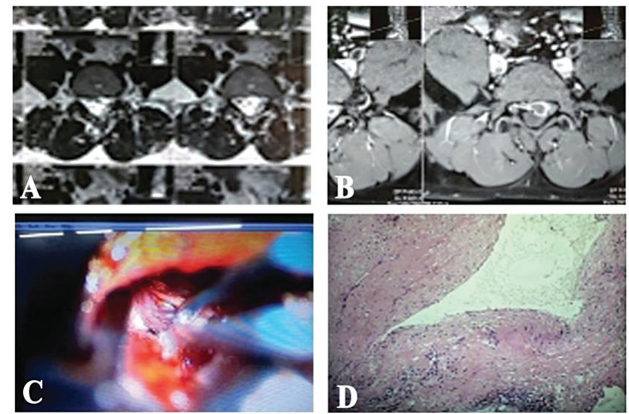


Fig. 1 (A) MRI-T2-weighted image showing hyperintense lesion anterior to the dural sac on the left side and (B) MRI-peripheral rim of enhancement on contrast T1 images anterior and left of the dural sac. (C) Per-operative discal cyst (black arrow) under the nerve root (white arrow). (D) Photomicrograph showing a thick fibrocollagenous cyst wall with hemosiderin pigment deposits and scanty lymphocytes (H&E, $\times 100$ magnification).

the operating surgeon. As the patient failed conservative measures, he was offered surgery. Microsurgical fenestration of left L4-L5 inter-laminar space was done to expose a stretched left L5 root by a greenish cystic lesion. Upon opening the cyst, dirty green fluid escaped suggesting old hemorrhage. Extirpation of the cyst wall was done, and there was no communication with the disc or dura per-operatively. The cyst capsule was excised. Histopathology showed a cyst wall with thick fibrocollagenous tissue without lining epithelial cells, focal deposits of hemosiderin pigment, and a few mononuclear inflammatory cells such as lymphocytes and macrophages (– Fig. 1). Disc material was not seen in the cyst. Postoperatively and at 2 years of follow-up, the patient was symptom-free.

Case 2

A 51-year-old lady presented with 2 weeks' duration of back pain radiating to the left leg with neurogenic claudication. She was obese and hypertensive. She had a positive SLR test, left extensor hallucis longus weakness, and an absent ankle jerk on the left side. Non-contrast MRI done at another center revealed lumbar canal stenosis (LCS) from L3 to S1 levels with a ventrolateral cyst at L5-S1 level on the left side with significant disc prolapse. Contrast MRI was not performed as the patient did not consent. Radiology opinion was obtained that suggested "degenerative cyst." Clinically, two roots were involved, and she had neurogenic claudication, as seen in LCS. After an unsuccessful trial of conservative treatment at another center, she was offered surgery. It was decided to expose as for LCS. At surgery, L3 to S1 spines were exposed. Microsurgically, however, only the left L5-S1 interlaminar space was fenestrated to expose the S1 root. It was found to be stretched by a tense cyst. The cyst wall was ruptured to release xanthochromic fluid. The cyst wall was excised, and it had communication with the disc wall at that level. L5-S1 discectomy was done. Histopathology showed hyalinized and loose fibrocollagenous tissue with hemorrhage, scattered

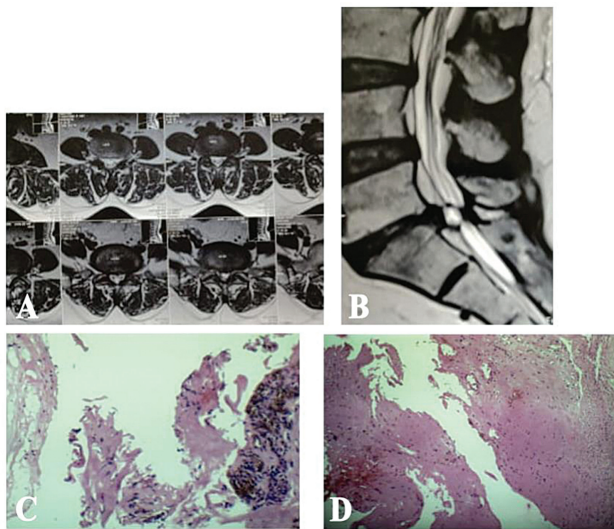


Fig. 2 (A) MRI-T2 image showing discal cyst ventrolateral to the dural sac left side and (B) MRI-T2 sagittal image showing discal cyst L5-S1 level. (C and D) Photomicrographs showing a fibrocollagenous cyst wall with hemorrhage and deposits of hemosiderin (H&E, $\times 100$ magnification).

lymphocytes, and macrophages with focal hemosiderin pigment deposits (\rightarrow Fig. 2). Postoperatively, the patient had an uneventful recovery. On follow-up at 1 year, the patient had no symptoms.

Case 3

A young man aged 27 years presented with severe left sciatica up to the left knee of 2 months' duration. SLR was positive on the left side, and left quadriceps were weak, and the knee jerk was absent. Plain MRI showed T1WI isointense, T2WI hyperintense lesion ventrolateral to the dural sac on the left side at the L2-L3 level with significant disc prolapse. The patient did not consent to a contrast MRI. Conservative treatment failed, and the patient opted for surgery. He underwent excision of the discal cyst and microlumbar discectomy. Histology showed a cyst wall formed by fibrocollagenous tissue without lining cells, lymphocytes, and macrophages with focal areas of hemorrhage (\rightarrow Fig. 3). Postoperatively, the patient had pain relief immediately and maintained so at 6 months' follow-up.

Discussion

In an era where a sedentary lifestyle is giving rise to lumbago sciatica syndrome with greater regularity, along with disc disorders, discal cysts are likely to be diagnosed more often. Discal cysts are among the numerous extradural spinal cysts that include arachnoid cysts, synovial cysts, ligamentum flavum cysts, ganglion cysts, and Tarlov cysts.

Juxta-facet cysts include synovial cysts and ganglion cysts. Some authors have used these two lesions as synonymous. Synovial cyst of the lumbar spine originates from the apophyseal joint capsule and is commonly related to degenerated or unsteady facet joints. On the contrary, the ganglion cyst of the lumbar spine is an accessible lying well-

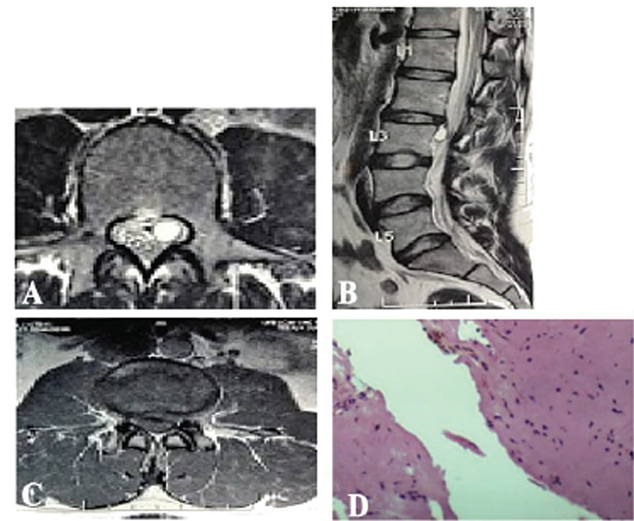


Fig. 3 (A) MRI-T2 hyperintense cystic lesion left side ventral to the dural sac (B) MRI-sagittal T2 image showing cyst just inferior to the level of L2-L3 disc space and (C) MRI-T1 axial image showing disc prolapse at the disc level. (D) Photomicrograph showing thick fibrocollagenous tissue without lining cells and areas of hemorrhage (H&E, $\times 100$ magnification).

delineated cystic lesion without any attachment to the apophyseal joint. On MRI, both these cysts are visible as a hypointense signal on T1 and a hyperintense signal on T2. They lack contrast enhancement with gadolinium. They are preferably treated by surgical excision. Grossly, the synovial cyst is filled with clear or yellowish fluid, and microscopy shows synovial cells lining the cyst with focal deposits of hemosiderin due to recurrent hemorrhage into the cyst cavity. Grossly ganglion cyst appears as delimited, thin-walled cyst filled with mucoid or gelatinous material. Histologically, it is characterized by a thick collagenous capsule adjoining a glutinous matter.

Ligamentum flavum cyst is a differential diagnosis for intraspinal extradural cysts presenting as lumbago-sciatica. It is a type of pseudocyst seen chiefly in elderly patients. On MRI, it manifests as a heterogeneous intensity on T1/T2 images. Treatment is the excision of the cyst. It does not have an attachment to the facet joint cavity. Histology helps to distinguish it from other similar cystic lesions. The cyst wall contains loose fibromyxoid tissue and lacks synovial cells.

The lumbar spine is an uncommon site for an arachnoid cyst. It is encountered more in the pediatric age group, commonly involving the dorsal spine. Rarely, it can present as an extradural lesion that can go unnoticed unless there is a mass effect on the spinal cord. On MRI, it is visualized as isointense on T1 and hyperintense on T2. Grossly, the cyst has a thin translucent wall containing clear fluid in the lumen. Histopathology was characterized by a cyst wall having flattened meningeal cells.

Tarlov (perineural) cyst is detected incidentally or symptomatic due to lumbosacral radiculopathy mimicking disc-related disorders. It affects posterior nerve roots with the encasing of nerve fibers. Due to its CSF content, it is cited as a low-intensity signal on T1 and a high-intensity signal on T2 MRI. Surgical treatment is to alleviate the neurological

Table 1 Summary of radiological and histopathological features of spinal extradural cysts

Spinal extradural cysts	MRI features	Pathology
Discal cysts	Ventrolateral to dural sac T1 isointense T2 Hyperintense Peripheral rim of contrast enhancement	Fibrous connective tissue without any lining, sometimes hemosiderin, rarely disc cartilage
Synovial cysts	Close proximity to facet joints Hypointense on T1 Hyperintense on T2 No contrast enhancement	Cyst wall lined by synovial cells with hemosiderin deposits
Ganglion cysts	Close proximity to facet joints Hypointense on T1 Hyperintense on T2 No contrast enhancement	Thick collagenous capsule with glutinous contents, no lining cells
Ligamentum flavum cyst	Posterior to dural sac, heterogeneous MRI signals on T1-hyperintense T2 images. The contrast shows peripheral enhancement	Fibrous tissue without lining cells with or without degeneration. Elastic fibers of the ligament is not seen in the cyst wall
Tarlov (perineural) cysts	Hypointense on T1 and hyperintense on T2 with nerve elements in the wall demonstrated by MR neurography	Histologic examination reveals an outer wall composed of vascular connective tissue and an inner wall lined with flattened arachnoid. Part of the lining contains nerve fibers and occasionally ganglion cells

symptoms and halt further damage to the nerve root. Histologically, the cyst wall comprises thin membranous tissue with nerve fibers and, sometimes, ganglion cells (→Table 1).

Discal cyst was described only in 1997 by Toyama in the Japanese literature⁴ and in 1999 by Kono et al. in the English literature.¹³ In 2001, Chiba et al. enumerated their clinical and radiological features with microscopic findings.⁸ In the present study, we describe a series of three patients where we observed lumbar radiculopathy as a clinical feature as also reported by other authors.⁴

The site of the discal cyst in Cases 1 and 2 was the lower lumbar region. However, in Case 3, we observed a cyst at the L2–L3 level, a rare location. So far, only six cases have been reported at this level.^{8,14}

The diagnostic tools employed to diagnose discal cysts include MRI and CT discography.^{1,13} MRI is a non-invasive tool to differentiate a discal cyst from other intraspinal cysts. Discal cyst shows characteristic isointense T1 and hyperintense T2 images with peripheral rim enhancement on contrast images. In Cases 2 and 3, preoperatively, the diagnosis of the discal cyst was not evident, probably due to lack of contrast MRI. Hence, in patients with T1 isointense and T2 hyperintense lesions ventrolateral to the dural sac, contrast MRI should be insisted upon to add specificity to the diagnosis of the discal cyst. In all three cases of this series, discal cysts were ventrolaterally located on MRI, as seen in most previously reported cases.^{13–15} Communication of discal cyst with corresponding intervertebral disc, as reported by Chiba et al., was noted only in Case 2 of this series.⁸

CT discography involves injecting contrast into disc space. It is an invasive procedure. Contrast injected into the disc space will delineate the herniated disc prolapse. Regarding

discal cysts, contrast injected into disc space during discography will find its way into the discal cyst, thereby establishing the diagnosis. In a patient with multiple spinal pathologies coexisting, as seen in Case 2 of this series, retrospectively, if discography had been performed, it would have invoked sciatic pain in the patient, thereby establishing that patient was symptomatic for discal cyst and disc prolapse and not LCS. This could have resulted in a much smaller incision and more comfort for the patient in the postoperative period. However, the fact that discography is an invasive procedure offsets its advantage.

The definite pathogenesis of discal cyst is yet uncertain. On histology, all three cases showed a cyst without any specific lining cells. This suggests that discal cyst is a type of pseudocyst that is probably formed due to the escape of fluid from the annulus fibrosus of the intervertebral disc, leading to fluid accumulation in the extradural space subsequently gets walled off. A similar mechanism has been proposed by Tokunaga et al.¹⁶ In all three cases of this series, inflammatory cells were noted in the cyst wall. Hence, we propose an alternate hypothesis that disc herniation induces inflammatory cell response, causing infiltration by macrophages and lymphocytes, which helps resorption herniated disc material. The findings of an ultrastructural study on discal cyst by Kobayashi et al. support this hypothesis.¹⁷

Incomplete resorption of a herniated disc may present as a discal cyst associated with disc prolapse, as seen in Cases 2 and 3. However, in Case 1, there was only a discal cyst without associated disc prolapse. This probably indicates that inflammatory response has led to complete resorption of the disc leaving behind only a remnant discal cyst. A similar inflammatory response is noted in patients with disc prolapse. Haro et al described inflammatory response in

herniated nucleus pulposus, which was more pronounced in the extruded disc than in the protruded type.¹⁸ Cases 2 and 3 in this series had concomitant significant disc herniation as evident on MRI images, which necessitated discectomy along with discal cyst excision. Hence, we hypothesize that discal cyst is an occasional byproduct in the disc degeneration syndrome, formed during the natural history of the course of disc herniation and resorption. If the annular rent allows only fluid egress through the annulus, it elicits an inflammatory response giving rise to a sequence of events, leading to discal cyst formation. If, however, the rent in the annulus is large enough to permit herniation of nucleus pulposus, it leads to disc prolapse of varying degrees. This could explain discal cyst and disc prolapse occurring together in Cases 2 and 3 of this series.

Treatment of discal cysts has included medical therapies, including epidural steroid injection. Surgical options have been reserved for those cases failing the trial of medical management. This has included CT-guided cyst aspiration, endoscopic transforaminal and interlaminar approach, microsurgical inter-laminar fenestration and discal cyst excision, partial hemilaminectomy, and discal cyst excision.⁵

We propose an algorithm for optimal management of patients with the discal cyst. In patients who are symptomatic after a trial of conservative treatment, if they have a discal cyst alone on MRI without herniated disc, and if they are in a stage of complete resolution of disc material leaving a residual discal cyst alone, surgery should address excision of discal cyst alone. However, if a patient presents at a stage where the discal cyst coexists with incompletely resorbed disc herniation, excision of the discal cyst should be coupled with discectomy. The procedure could be either microsurgical or endoscopic, as described in various articles available from different centers (►Fig. 4). There are rare case reports of spontaneous regression of discal cyst with conservative treatment.^{19,20}

Conclusion

To summarize, the discal cyst is a rare clinicopathological entity reported in the recent past, clinically, mimicking disc prolapse. Lack of recognition of discal cyst by treating clinicians and diagnosing pathologists could be overcome by pre-surgical clinicroadiological correlation with support

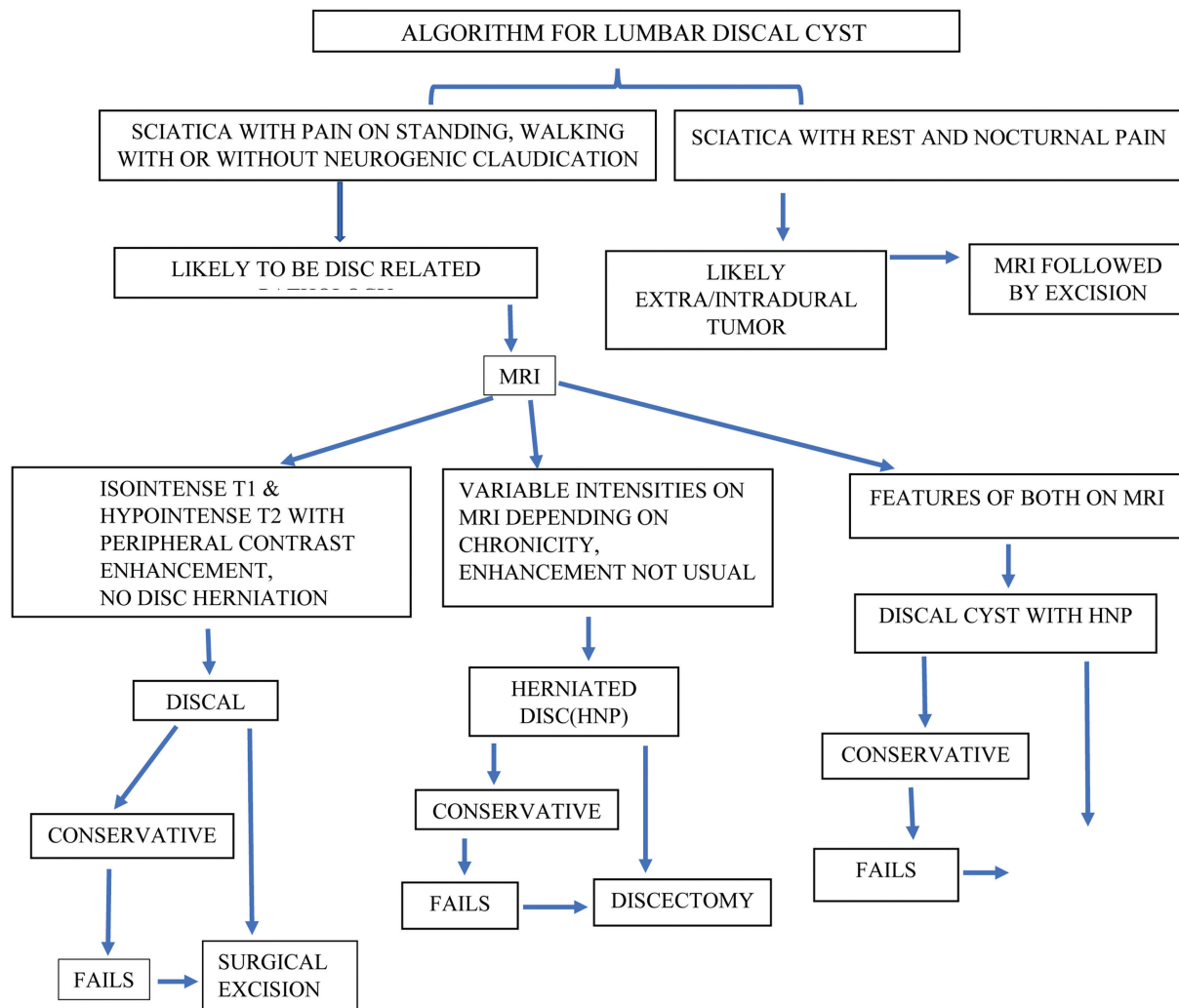


Fig. 4 Proposed algorithm for lumbar discal cyst management.

from pathologists. In the future, reporting more cases of the discal cyst may help to support the hypothesis regarding its etiopathogenesis as a part of the disc disease spectrum, offering prophylactic options and more minimally invasive treatment. Symptomatic patients who fail conservative treatment should undergo excision of cyst alone if MRI shows discal cyst without disc degeneration. If, however, there is concomitant disc prolapse, additional discectomy should be done.

Conflict of Interest

None declared.

Acknowledgment

The authors acknowledge Dr. Suresh Kumar R, Scientist, Jubilee Centre for Medical Research, for his valuable suggestions throughout the completion of this study.

References

- Aljuboori Z, Altstadt T. Symptomatic lumbar discal cyst: a rare entity that can mimic other lumbar cystic lesions. *Cureus* 2019;11(08):e5453
- Hwang JH, Park IS, Kang DH, Jung JM. Discal cyst of the lumbar spine. *J Korean Neurosurg Soc* 2008;44(04):262–264
- Nabeta M, Yoshimoto H, Sato S, Hyakumachi T, Yanagibashi Y, Masuda T. Discal cysts of the lumbar spine. Report of five cases. *J Neurosurg Spine* 2007;6(01):85–89
- Jeong GK, Bendo JA. Lumbar intervertebral disc cyst as a cause of radiculopathy. *Spine J* 2003;3(03):242–246
- Aydin S, Abuzayed B, Yildirim H, Bozkus H, Vural M. Discal cysts of the lumbar spine: report of five cases and review of the literature. *Eur Spine J* 2010;19(10):1621–1626
- Khalatbari MR, Moharamzad Y. Discal cyst in pediatric patients: case report and review of the literature. *Neuropediatrics* 2012;43(05):289–292
- Shibata S, Hanakita J, Takahashi T, Minami M, Kuraishi K, Watanabe M. Bilateral discal cysts managed by partial hemilaminectomy and microscopic resection of hemilateral cyst. *Spine* 2011;36(25):E1655–E1658
- Chiba K, Toyama Y, Matsumoto M, Maruiwa H, Watanabe M, Nishizawa T. Intraspinous cyst communicating with the intervertebral disc in the lumbar spine: discal cyst. *Spine* 2001;26(19):2112–2118
- Fam MD, Woodroffe RW, Helland L, et al. Spinal arachnoid cysts in adults: diagnosis and management. A single-center experience. *J Neurosurg Spine* 2018;29(06):711–719
- Onofrio BM, Mih AD. Synovial cysts of the spine. *Neurosurgery* 1988;22(04):642–647
- Taha H, Bareksei Y, Albanna W, Schirmer M. Ligamentum flavum cyst in the lumbar spine: a case report and review of the literature. *J Orthop Traumatol* 2010;11(02):117–122
- Domenicucci M, Ramieri A, Marruzzo D, et al. Lumbar ganglion cyst: nosology, surgical management and proposal of a new classification based on 34 personal cases and literature review. *World J Orthop* 2017;8(09):697–704
- Kono K, Nakamura H, Inoue Y, Okamura T, Shakudo M, Yamada R. Intraspinous extradural cysts communicating with adjacent herniated disks: imaging characteristics and possible pathogenesis. *Am J Neuroradiol* 1999;20(07):1373–1377
- Park JW, Lee BJ, Jeon SR, Rhim SC, Park JH, Roh SW. Surgical treatment of lumbar spinal discal cyst: is it enough to remove the cyst only without following discectomy? *Neurol Med Chir (Tokyo)* 2019;59(06):204–212
- Lee HK, Lee DH, Choi CG, et al. Discal cyst of the lumbar spine: MR imaging features. *Clin Imaging* 2006;30(05):326–330
- Tokunaga M, Aizawa T, Hyodo H, Sasaki H, Tanaka Y, Sato T. Lumbar discal cyst followed by intervertebral disc herniation: MRI findings of two cases. *J Orthop Sci* 2006;11(01):81–84
- Kobayashi S, Takeno K, Uchida K, et al. Pathogenesis of the discal cysts communicating with an adjacent herniated disc. Histological and ultrastructural studies of two cases. *Joint Bone Spine* 2010;77(02):184–186
- Haro H, Shinomiya K, Komori H, et al. Upregulated expression of chemokines in herniated nucleus pulposus resorption. *Spine* 1996;21(14):1647–1652
- Prasad G, Kabir SM, Saifuddin A, Casey AT. Spontaneous resolution of discal cyst around L5 nerve root: case report and review of literature. *Br J Neurosurg* 2011;25(06):761–763
- Chou D, Smith JS, Chin CT. Spontaneous regression of a discal cyst. Case report. *J Neurosurg Spine* 2007;6(01):81–84