

# A Rare Case of Cardiac Malignancy: Myxoid Liposarcoma

Sowmica Devabhaktuni<sup>1</sup> Ravichandran Ambalathandi<sup>1</sup> G.A. Vasugi<sup>2</sup>  
Manickavasagam Meenakshisundaram<sup>1</sup>

<sup>1</sup>Department of Medical Oncology, Sri Ramachandra Institute of Higher Education and Research, Porur, Chennai, Tamil Nadu, India

<sup>2</sup>Department of Pathology, Sri Ramachandra Institute of Higher Education and Research, Porur, Chennai, Tamil Nadu, India

**South Asian J Cancer 2022;11(3):276–278.**

## Address for correspondence

Ravichandran Ambalathandi, DM (Medical Oncology), Department of Medical Oncology, Sri Ramachandra Institute of Higher Education and Research, Porur, Chennai, Tamil Nadu, 600116, India (e-mail: raviambalathandi@gmail.com).



Ravichandran Ambalathandi

A 53-year-old female, who is a known hypertensive for 8 years, presented with difficulty in breathing for 1 week. Associated with orthopnea, the patient also complained of dry cough and fever. Fever was low grade, intermittent, and not associated with chills and rigors. No history of chest pain, palpitations, giddiness, syncopal attacks, or pedal edema was found.

On examination, patient was conscious, coherent, and oriented. Tachypnea and tachycardia were noted. Oxygen saturation was 98% at room air. JVP (jugular venous pulse) was elevated. No pallor, icterus, cyanosis, lymphadenopathy, or pedal edema was found. Cardiovascular examination revealed muffled heart sounds. Examination of other systems was unremarkable.

ECG (electrocardiogram) showed tachycardia, low voltage complexes, and nonspecific ST-T changes. Emergency echocardiogram was done, which showed massive pericardial effusion with homogenous mass attached to the right atrium with normal LV (left ventricular) function. Patient was taken up for emergency pericardiocentesis using a pig tail catheter, and 550 mL of hemorrhagic pericardial fluid was drained and sent for analysis.

Pericardial fluid was negative for malignant cells, AFB (acid-fast bacillus), and gene expert for MTB (mycobacterium tuberculosis). Protein was 5.7, sugar 91, ADA (adenosine deaminase) 61.1, LDH (lactate dehydrogenase) 3,069, and culture sensitivity showed no growth.

Once the patient was stabilized, a CECT (contrast-enhanced computed tomogram) Thorax was done for evaluating the cardiac mass. CECT showed minimally enhancing mass lesion in right atrial wall extending into pericardium.

(computed tomography) CT-guided biopsy was done from the right atrial mass.

Histopathology showed lesion predominantly composed of atypical adipocytes and lipoblasts exhibiting moderate pleomorphism. Numerous signet ring lipoblasts were also noted admixed with delicate thin-walled arborizing and curvilinear capillaries. Background showed a myxoid matrix, shown in **Fig. 1**. The lipoblasts were focally positive for S-100 and negative for cytokeratin, immunohistochemically. With H&E (Hematoxylin and Eosin) and IHC (immunohistochemistry) features, a diagnosis of myxoid liposarcoma was rendered.

PET-CT (positron emission tomography-computed tomography) was done to rule out metastasis. PET-CT showed mild FDG (fluorodeoxyglucose) avid hypodense lesion measuring 58 × 50 mm along the lateral wall of right atrium without any other significant lesions. Now, patient is planned for complete excision.

Primary cardiac tumors are a rare entity whose incidence, according to surgery and autopsy reports, is 0.3 to 0.7% of all cardiac tumors.<sup>1</sup> Metastasis to heart from other primary sites is more common. Of this rare group, 75% are benign with most common entity being myxoma.<sup>2</sup>

Liposarcomas are often asymptomatic. Symptoms may be due to compression or direct invasion of adjacent organs after attaining a considerable size, which may delay the diagnosis of liposarcomas.

Limited data are available for the management of cardiac sarcomas. The available data show that the prognosis is generally bleak. Complete resection is not of much benefit for malignant cardiac sarcomas.<sup>3</sup>

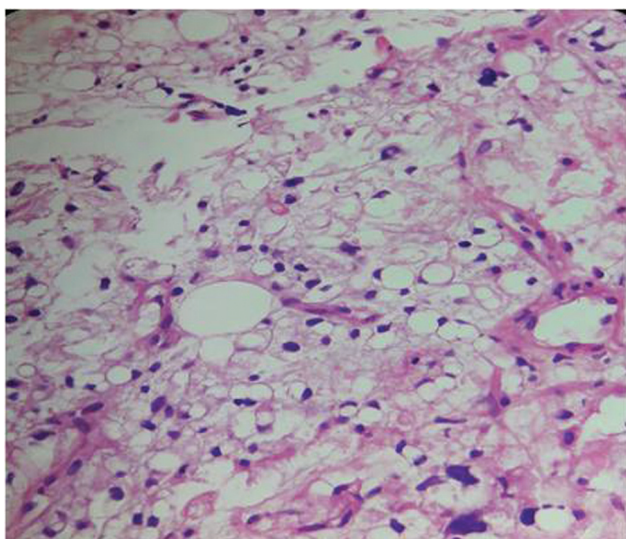
DOI <https://doi.org/10.1055/s-0042-1743424> ISSN 2278-330X

**How to cite this article:** Devabhaktuni S, Ambalathandi R, Vasugi GA et al. A Rare Case of Cardiac Malignancy: Myxoid Liposarcoma. *South Asian J Cancer* 2022;11(3):276–278.

© 2022. MedIntel Services Pvt Ltd. All rights reserved.

This is an open access article published by Thieme under the terms of the Creative Commons Attribution-NonDerivative-NonCommercial-License, permitting copying and reproduction so long as the original work is given appropriate credit. Contents may not be used for commercial purposes, or adapted, remixed, transformed or built upon. (<https://creativecommons.org/licenses/by-nc-nd/4.0/>)

Thieme Medical and Scientific Publishers Pvt. Ltd., A-12, 2nd Floor, Sector 2, Noida-201301 UP, India



**Fig. 1** CMLS (cardiac myxoid liposarcoma) histology.

Very few studies addressed the use of chemotherapy in cardiac sarcomas. Isambert et al found that chemotherapy improved survival, but only in patients who were not operated.<sup>4</sup> Abu Saleh et al studied the use of neoadjuvant chemotherapy. This study concluded that increased completed resection rates were seen in the neoadjuvant group, which translated into increased survival.<sup>5</sup> Most commonly employed chemotherapy regimens were doxorubicin and ifosfamide.

In conclusion, myxoid liposarcoma arising from heart is an extremely rare entity. Surgical resection combined with chemotherapy or radiotherapy remains the main treatment strategy to date. Novel treatment strategies for the treatment of cardiac sarcomas, such as molecular targeting therapy, need to be explored further.

#### Conflict of Interest

None.

#### Acknowledgment

We sincerely thank Dr. Arunan Murali, Professor, Department of Radiology, Sri Ramachandra Institute of Higher Education and Research, Chennai, Tamil Nadu, India.

#### References

- 1 Bisel HF, Wróblewski F, Ladue JS. Incidence and clinical manifestations of cardiac metastases. *J Am Med Assoc* 1953;153(08):712–715
- 2 Leja MJ, Shah DJ, Reardon MJ. Primary cardiac tumors. *Tex Heart Inst J* 2011;38(03):261–262
- 3 Ramlawi B, Leja MJ, Abu Saleh WK, et al. Surgical treatment of primary cardiac sarcomas: review of a single-institution experience. [published correction appears in *Ann Thorac Surg*. 2016 Dec;102(6):2139] *Ann Thorac Surg* 2016;101(02):698–702
- 4 Isambert N, Ray-Coquard I, Italiano A, et al. Primary cardiac sarcomas: a retrospective study of the French Sarcoma Group. *Eur J Cancer* 2014;50(01):128–136
- 5 Abu Saleh WK, Ramlawi B, Shapira OM, et al. Improved outcomes with the evolution of a neoadjuvant chemotherapy approach to right heart sarcoma. *Ann Thorac Surg* 2017;104(01):90–96

