



Closure of Transsplenic Access Tracts Using Tract Embolics: Success, Clinical Outcomes, and Complications in a Tertiary Center

David Rigual² Isaac Chen¹ Dustin L. Roberts² James Sayre² Ravi Srinivasa²

¹California Northstate University College of Medicine, Elk Grove, California, United States

²Division of Vascular and Interventional Radiology, UCLA, Ronald Reagan Medical Center, Los Angeles, California, United States

Address for correspondence Isaac Chen, BS, 23640 Falcons View Drive, Diamond Bar, California (e-mail: isaacchen0@gmail.com).

J Clin Interv Radiol ISVIR 2023;7:8–14.

Abstract

Purpose The aim of the study was to evaluate the safety and effectiveness of transsplenic venous access closure.

Materials and Methods Twenty patients (mean age: 51.8 years; range: 28–72), underwent 21 transsplenic venous access procedures over 4 years in this retrospective study. Comorbidities, active hemorrhage, anticoagulation, coagulation parameters, platelets, indications for transsplenic access, needle gauge, sheath size, variceal embolization method, tract embolization method, bleeding complications, and transfusion requirements and additional procedures to manage bleeding complications were recorded.

Results Preprocedure comorbidities included portal hypertension ($n = 18/20$, 90%), portal vein thrombosis ($n = 14/20$, 70%), hemorrhage ($n = 6/20$, 30%), splenic vein thrombosis ($n = 7/20$, 35%), anticoagulation ($n = 2/20$, 10%), and sinistral portal hypertension ($n = 2/20$, 10%). Mean baseline international normalized ratio was 1.3 (range: 1–1.9), platelets 122 (range: 18–492). Most common transsplenic access indications were gastric varices with nonpatent portosystemic shunt ($n = 11/21$, 52%) and portal vein targeting for transjugular intrahepatic portosystemic shunt ($n = 8$, 38%). Most common access sheath sizes were 4-French ($n = 5$, 24%) and 6-French ($n = 6$, 29%). Fifteen procedures (71%) involved variceal embolization. Transsplenic tracts were embolized with microfibrillar collagen alone ($n = 7$), coils and microfibrillar collagen ($n = 8$), or others ($n = 6$). Based on the Society of Interventional Radiology adverse event classification system, embolization complications included one major (splenic artery pseudoaneurysm and a splenic vein pseudoaneurysm) and three moderate (19%) adverse bleeding events, which required blood transfusion.

Keywords

- ▶ transsplenic access
- ▶ microfibrillar collagen
- ▶ hemostasis

Conclusion Transsplenic venous access tract embolization is a safe and moderately effective method to achieve tract hemostasis, with an overall clinical failure rate of 20%.

article published online
March 8, 2022

DOI <https://doi.org/10.1055/s-0042-1743499>.
ISSN 2457-0214.

© 2022. Indian Society of Vascular and Interventional Radiology. All rights reserved.

This is an open access article published by Thieme under the terms of the Creative Commons Attribution-NonDerivative-NonCommercial-License, permitting copying and reproduction so long as the original work is given appropriate credit. Contents may not be used for commercial purposes, or adapted, remixed, transformed or built upon. (<https://creativecommons.org/licenses/by-nc-nd/4.0/>)

Thieme Medical and Scientific Publishers Pvt. Ltd., A-12, 2nd Floor, Sector 2, Noida-201301 UP, India

Introduction

Percutaneous transsplenic venous access (PTSVA) is an effective and safe method to gain entry to the portal venous system when transjugular, transhepatic, and percutaneous transhepatic access routes are not optimal.¹⁻³ This approach has been used for diagnostic splenoportography, variceal embolization, portal vein recanalization, and to facilitate portal venous cannulation for transjugular intrahepatic portosystemic shunt (TIPS). Access site hemostasis is an important consideration of PTSVA.⁴ However, multiple prior studies have shown no difference between transsplenic and transhepatic access site hemorrhagic complications.^{5,6} Historically, rates of PTSVA tract hemorrhage were significantly higher without the use of embolic materials to plug the splenic tract.^{7,8} To date, splenic parenchymal tract closure has been reported successfully with a low complication rate utilizing a variety of embolics, including plugs, Gelfoam, and a combination of coils and glue.^{1,9} In this retrospective study, we aim to assess the efficacy of splenic parenchymal tract closure with microfibrillar collagen (Avitene microfibrillar collagen hemostat; Warwick, Rhode Island, United States) alone, and in conjunction with a variety of other embolics, for closure of transsplenic access tracts.

Materials and Methods

A single-center retrospective review of the electronic medical records was conducted of all patients who underwent PTSVA with tract embolization from August 2014 to August 2018 with the approval of the institutional review board. In all, 23 patients were considered for inclusion. One 18-month-old patient was excluded, one was excluded for insufficient data, and one excluded due to inability to establish secure transsplenic venous access. The analyzed cohort consisted of 21 PTSVA performed in 20 patients (11 male, 9 female; median age: 55), with one patient undergoing two procedures. All but one patient underwent cross-sectional imaging with computed tomographic (CT) or magnetic resonance imaging prior to intervention. All patients were followed for access site complications for a minimum of 45 days unless they died prior to this time ($n = 2$), except for one patient who was lost to follow-up at 2 weeks.

Technical success of PTSVA tract closure was defined by stability of the tract embolic between immediate and 1-minute delayed fluoroscopic imaging relative to PTSVA tract embolization. Clinical success was defined as the absence of high-density ascites (on CT), or perisplenic hematoma on post-procedural ultrasound or CT performed for the evaluation of postprocedural abdominal pain, hypotension or hemoglobin drop. Clinical failures were graded on the basis of the most recent Society of Interventional Radiology (SIR) adverse event classification system.¹⁰

Procedural Technique

An attending interventional radiologist saw each patient in the clinic or during inpatient consultation before the procedure. Procedures were performed with moderate sedation

with intravenous midazolam and fentanyl or general anesthesia administered by a certified registered nurse anesthetist or anesthesiologist. Patients were resuscitated for ongoing hemorrhage and coagulopathy by anesthesia staff throughout the procedure when necessary. Paracentesis was performed in cases with large volume ascites prior to performing PTSVA.

Available preprocedural cross-sectional imaging was reviewed to determine the optimal site for PTSVA. Access was preferentially targeted to inferior splenic vasculature when feasible to minimize the risk of pleural transgression. All patients were administered local analgesia percutaneously to the level of the splenic capsule with 1% lidocaine. Percutaneous access was performed with a 21 or 22-gauge Chiba needle (Cook Medical; Bloomington, Indiana, United States) under sonographic guidance. Angiography was then performed to confirm appropriate access. This was followed by splenic vein cannulation with a 0.018" wire except for one case (Patient #1) that was performed through the 22G access, which was sufficient for Gelfoam embolization of gastric varices. Transitional dilatation was performed in all other cases to sheath sizes ranging from 4 to 8 French. The most common procedures subsequently performed were TIPS with portal venous recanalization ($n = 8$), antegrade gastric variceal embolization ($n = 7$), and antegrade gastroesophageal embolization ($n = 5$), as previously described.^{11,12}

For access closure, transsplenic angiography was performed during retraction of the PTSVA sheath to identify the point of splenic venous entry. Tract embolization was then performed under continuous fluoroscopic imaging to the level of the splenic capsule. PTSVA tracts were embolized through the largest placed access sheath with one or a combination of embolics, including Gelfoam, microfibrillar collagen, coils, and *n*-butyl cyanoacrylate (NBCA). Gelfoam and microfibrillar collagen embolic suspensions were prepared as a slurry with iodinated contrast material. NBCA was mixed with lipiodol when utilized. Mixture ratios were determined by operator preference.

Statistical Analyses

Patient characteristics assessed for statistical significance with respect to PTSVA tract hemorrhage included age, international normalized ratio (INR), platelets, PTSVA sheath size (data not available for one patient, and one case was performed with PTSVA through a 22G Chiba needle), preprocedural active hemorrhage, and preprocedural or intraprocedural active anticoagulation (referred to as active anticoagulation). PTSVA tract embolic selection was also assessed for statistical significance with respect to hemorrhage in the following categories: microfibrillar collagen, microfibrillar collagen combined with other embolics, and single or multiple embolics other than microfibrillar collagen. Significance of hemorrhage could not be ascertained on the basis of pre- and postprocedural hemoglobin changes due to a lack of standardization of hemoglobin measurements related to procedural timing and transfusion requirements.

Table 1 Relationship between presence/absence of PTSVA tract bleeding and patient age, INR, platelets, and PTSVA sheath size

		Mean	Standard deviation	p-Value (Welch's t-test)
Age	PTSVA tract bleed	59.8 years	5.9	0.044
	No PTSVA tract bleed	49.9 years	13.3	
INR	PTSVA tract bleed	1.40	0.356	0.730
	No PTSVA tract bleed	1.33	0.278	
Platelets	PTSVA tract bleed	58.5 (1000 / mm ³)	36.7	0.032
	No PTSVA tract bleed	135 (1000 / mm ³)	110	
PTSVA sheath size	PTSVA tract bleed	5.5 French	1.73	0.814
	No PTSVA tract bleed	5.73 French	1.28	

Abbreviations: INR, international normalized ratio; PTSVA, percutaneous transsplenic venous access.

Table 2 Relationship between presence/absence of PTSVA tract bleeding and cases involving active hemorrhage, active anticoagulation, or PTSVA tract embolics

		PTSVA tract bleed		No PTSVA tract bleed		Pearson chi-square two-tailed p-value
		Number	Percent	Number	Percent	
Preprocedural active hemorrhage	Present	1	25	6	35.3	0.694
	Absent	3	75	11	64.7	
Active anticoagulation	Present	0	0	2	11.8	1 (Fisher's exact test)
	Absent	4	100	15	88.2	
PTSVA tract embolics	Microfibrillar collagen	1	25	6	75	0.921
	Microfibrillar collagen plus other embolic(s)	2	50	7	77.8	
	Embolic(s) other than microfibrillar collagen	1	25	4	80	

Abbreviation: PTSVA, percutaneous transsplenic venous access.

IBM SPSS Statistics for Windows, Version 24.0. (IBM Corporation, Armonk, New York, United States) was used to perform the statistical analysis. Means, standard deviations, Welch's t-tests, Fisher's exact test, and chi-squared analysis were performed for PTSVA tract bleed complications (► **Tables 1** and **2**). A 5% level of significance was used.

Descriptive statistics were performed for the following variables: procedural indications, procedures performed, indications for PTSVA, portal venous hypertension, variceal embolization methods, PTSVA tract embolics, postprocedural transfusion requirements, procedures required to treat PTSVA tract hemorrhage, and adverse bleeding event severity defined by SIR criteria.¹⁰

Results

Technical success of PTSVA tract embolization was achieved in 9 of 10 cases that were able to be assessed due to absent or insufficient imaging in the remaining 11 cases, rendering this component of the study as descriptive. ► **Fig. 1** demonstrates an example of a technically successful case. One technical failure—characterized by partial migration of tract embolic following PTSVA tract embolization—was not associated with

clinical failure. Clinical success was achieved in 17/21 cases (81%). Four cases were complicated by PTSVA access site hemorrhage in which three cases were moderate and one was severe as per SIR classification. Mean follow-up time was 9.3 months, (median being 5 months; range: 0.25–25.5 months). There were no postprocedural access site bleeds that developed beyond 30 days. Three of four perisplenic hemorrhages presented on the same day of the procedure or postprocedure day (PPD) 1 and were stabilized by PPD 1 or 2. One PTSVA tract hemorrhagic complication was found incidentally on PPD 2 and stabilized by PPD 31 (► **Fig. 2**).

Procedural indications, procedures performed, and indications for PTSVA are shown in ► **Table 3**. Patient age, INR, platelets, PTSVA sheath size, preprocedural active hemorrhage, presence or absence of active anticoagulation, and PTSVA tract embolics are also shown in ► **Table 3**. Portal venous hypertension was present in all patients. Portal venous thrombosis was present in 14 cases. Splenic vein thrombosis was present in 7 cases. Variceal embolization was performed in 15 cases with one, or a combination of Gelfoam, coils, NBCA, and/or vascular plug. Number of postprocedural packed red blood cell transfusion requirements, interventions required for management of PTSVA tract hemorrhage,

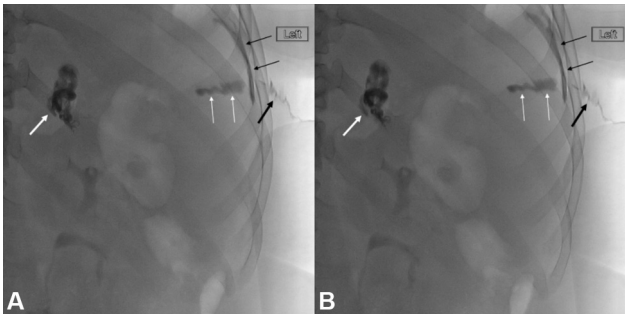


Fig. 1 A 37-year-old woman with a remote history of laparoscopic gastric banding complicated by ischemic bowel requiring small bowel resection. She presented 1 year later with hematemesis. Endoscopy revealed gastroesophageal varices and portal gastropathy. She underwent transjugular intrahepatic portosystemic shunt (TIPS) with portal venous recanalization assisted by PTSVA and embolization of a gastrorenal shunt. Percutaneous transsplenic venous access (PTSVA) tract embolization was technically successful at the conclusion of the procedure. (A) Immediate and (B) delayed post-PTSVA tract embolization fluoroscopic images demonstrate stability of the microfibrillar collagen-contrast slurry within the tract (white arrows), extending over the splenic capsule (black arrows), and within the subcutaneous tissues (thick black arrow). *n*-butyl cyanoacrylate is demonstrated within the gastrorenal shunt (thick white arrow). The patient experienced no clinical complication of the procedure.

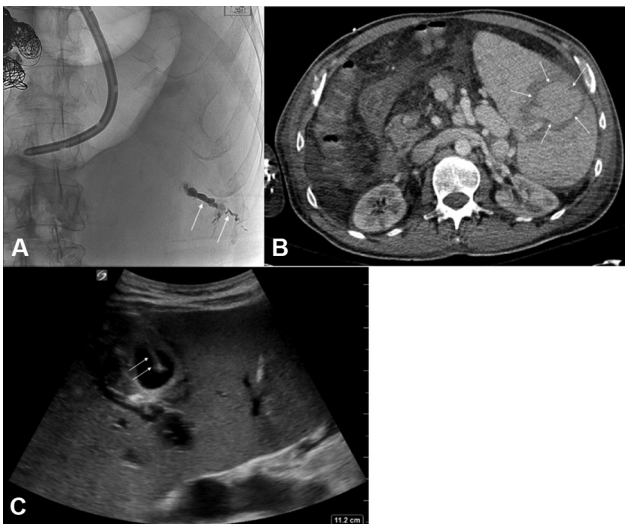


Fig. 2 A 62-year-old man with cirrhosis, multifocal hepatocellular carcinoma treated by ablation, portal vein thrombosis with portal venous cavernous transformation, and Sarin classification type II gastroesophageal varices. He presented to the emergency department with large volume hematemesis and hemochezia. Emergent endoscopy revealed bleeding esophageal varices. Percutaneous transsplenic venous access (PTSVA) was performed with placement of an 8-French vascular sheath. Esophageal varices were embolized to complete stasis with a combination of coils, Gelfoam, and *n*-butyl cyanoacrylate. (A) Post-PTSVA tract embolization spot fluoroscopic image demonstrates the PTSVA tract embolized with microfibrillar collagen-contrast slurry (arrows). (B) Computed tomography performed on postprocedure day 2 for staging of liver disease demonstrates a 5.6 cm splenic vein pseudoaneurysm (arrows). (C) Gray scale ultrasound image demonstrates 21-G Chiba needle access into the splenic vein pseudoaneurysm (arrows).

Table 3 Patients studied, with their ages, procedural indications, procedure types, relevant lab values, presence/absence of preprocedural active hemorrhage, presence/absence of active anticoagulation, and embolic types.

Patient	Age	Sex	Procedural indication	Indication for PTSVA	INR	Preprocedural active hemorrhage	Active anticoagulation	Procedure	PTSVA tract embolics
1	57	M	Bleeding GV	Varices not accessible through a PSS	1.2	Present	No	Antegrade GV embolization	Coils and NBCA
2	30	M	Bleeding GV, Spl VT	Varices not accessible through a PSS	1	Absent	No	Antegrade GV embolization	Coils, Gelfoam and microfibrillar collagen
2	30	M	Bleeding GV, Spl VT	Varices not accessible through a PSS	1.1	Absent	No	Antegrade GV embolization	Microfibrillar collagen
3	64	M	Bleeding GOV, TIPS not desired	Varices not accessible through a PSS	1.7	Absent	No	Antegrade GOV embolization	Coils and microfibrillar collagen
4	45	M	Bleeding EV	Recanalization of PVT for TIPS targeting	1.4	Present	No	TIPS with PVR, antegrade GOV embolization	Coils and microfibrillar collagen
5	55	F	Ascites refractory to medical therapy	Recanalization of PVT for TIPS targeting	1.1	Absent	No	TIPS with PVR, paracentesis	Coils and microfibrillar collagen
6	72	F	Acute PVT		1.3	Absent			Coils and NBCA

(Continued)

Table 3 (Continued)

Patient	Age	Sex	Procedural indication	Indication for PTSVA	INR	Preprocedural active hemorrhage	Active anticoagulation	Procedure	PTSVA tract embolics
7	67	F	Bleeding sigmoid colostomy PsV	Recanalization of PVT for TIPS targeting Varices not accessible through a PSS	1.4	Absent	No	TIPS with PVR, SPM pharmaco-mechanical lysis Retrograde PsV embolization	Coils and NBCA
8	37	F	Bleeding GOV	Recanalization of PVT for TIPS targeting	1.2	Absent	No	TIPS with PVR, antegrade GOV embolization	Microfibrillar collagen
9	65	M	Ascites refractory to medical therapy	Recanalization of PVT for TIPS targeting	1.9	Absent	Warfarin	TIPS with PVR, paracentesis	Microfibrillar collagen
10	50	M	Bleeding GV	Varices not accessible through a PSS	1.3	Present	No	Antegrade GV embolization	Microfibrillar collagen
11	46	F	Bleeding GOV	Portal venography and pressure measurements	1.8	Present	No	PV and pressure measurements	Microfibrillar collagen
12	58	M	Bleeding RV	Varices not accessible through a PSS	1.6	Present	No	RV embolization	Coils and microfibrillar collagen
13	55	F	Bleeding GOV	Varices not accessible through a previously embolized PSS	1.2	Absent	No	Antegrade GOV embolization	Coils and microfibrillar collagen
14	28	M	Bleeding MV	Recanalization of PVT for TIPS targeting	1.1	Present	No	TIPS with PVR, SPM venoplasty	Coils and NBCA
15	59	F	Ascites refractory to medical therapy	Recanalization of PVT for TIPS targeting	1.2	Absent	No	TIPS with PVR, antegrade GOV embolization	Coils and microfibrillar collagen
16	59	M	HE, GV	Varices not accessible through a previously embolized PSS	1.5	Absent	No	Antegrade GV embolization	Coils and NBCA
17	51	F	Bleeding GV	Portal venous access	1	Absent	No	PV and pressure measurements, Ts LB	Microfibrillar collagen
18	57	F	Ascites refractory to medical therapy	Recanalization of PVT for TIPS targeting	1.2	Absent	No	TIPS with PVR, paracentesis	Coils and microfibrillar collagen
19	40	M	Bleeding GV	Varices not accessible through a PSS	1.1		No	Antegrade GV embolization	Coils and microfibrillar collagen
20	62	M	Bleeding EV with chronic PVT	Varices not accessible through a PSS, unable to place TIPS	1.9		No	Antegrade EV embolization	Microfibrillar collagen

Abbreviations: EV, esophageal varices/variceal; GOV, gastroesophageal varices/variceal; GV, gastric varices/variceal; HE, hepatic encephalopathy; MV, mesenteric varices; NBCA, n-butyl cyanoacrylate; PSS, portosystemic shunt; PsV, peristomal varices/variceal; PTSVA, percutaneous transsplenic venous access; PVR, portal venous recanalization; PVT, portal vein thrombosis; PV, portal venography; RV, rectal varices/variceal; Spl VT, splenic venous thrombosis; SPM, spleno-porto-mesenteric; TIPS, transjugular intrahepatic portosystemic shunt; Ts LB, transsplenic liver biopsy.

Table 4

Patient number	Postprocedural PRBC transfusion requirement	Additional interventions	AE category by SIR criteria
5	2	None	Moderate AE
7	2	None	Moderate AE
13	2	None	Moderate AE
20	2	Splenic venous pseudoaneurysm thrombin injection on PPD 12. Splenic arterial pseudoaneurysm embolization on PPD 21. Laparotomy and washout on PPD 31	Severe AE

Abbreviations: AE, adverse event; PRBC, packed red blood cell; PPD, postprocedure day; SIR, Society of Interventional Radiology.

and adverse event category by SIR criteria are listed for all cases complicated by PTSVA tract hemorrhages in **Table 4**.

Means, standard deviations, and *p*-values with respect to the distribution of patient age and INR, platelets, and PTSVA sheath size with respect to presence or absence of PTSVA tract bleeding complications are shown in **Table 1**. Distribution of cases involving active hemorrhage, active anticoagulation, and PTSVA tract embolics with respect to the presence or absence of PTSVA tract bleeding complications and associated *p*-values is shown in **Table 2**. Mean platelet values for patients who did and did not suffer PTSVA tract hemorrhage were 58.5 and 135 (1000/mm³), respectively, which were statistically significant (*p* = 0.032). Mean ages for patients who did and did not suffer PTSVA tract hemorrhage were 59.8 and 49.8 (years), respectively, which were also significantly different (*p* = 0.044). There was no statistically significant difference between risk of PTSVA tract hemorrhage corresponding to INR (*p* = 0.730), active anticoagulation (*p* = 1), active hemorrhage (*p* = 0.694), PTSVA sheath size (*p* = 0.814), or PTSVA tract embolics (*p* = 0.921).

Discussion

PTSVA is a valuable technique to gain antegrade access to the portal venous system in a minority of portal venous interventions. The technique has been shown to be useful in the setting of portal venous thrombosis requiring main portal venous recanalization, variceal embolization, accurate measurements of extrahepatic portal hypertension, and antegrade portography to visualize portal venous collateral pathways.^{9,13,14} PTSVA is also useful to access bleeding gastric varices that are not associated with a patent gastrosplenic shunt.^{12,15} This study also finds PTSVA to be useful in circumstances similar to those reported in the literature (**Table 3**).

Haddad et al validated the safety of transsplenic access in 2018 by comparison of patient cohorts undergoing transsplenic and transhepatic accesses from 2000 to 2017 at their institution. They report 3 bleeding complications out of 24 transsplenic accesses (12.5%), and 10 bleeding complications out of 124 transhepatic accesses (8.1%), which were not significantly different when stratified to overall and major bleeding complications.⁵ Multiple authors have demonstrated a similar rate of bleeding complications. Liang et al reported 2 bleeding complications out of 17 cases of transsplenic access (12.5%).³ Zhu et al reported 3 major and 6 minor bleeding

complications out of 44 transsplenic accesses (6.5 and 13%, respectively).¹³ Monroe et al reported 2 bleeding complications out of 26 cases (7.7%).⁹ As such, the bleeding complication rate in this study is comparable to the reported literature for transsplenic access. We report a 19% complication rate with respect to bleeding following PTSVA tract embolization (4 bleeding events). Three patients adequately responded to transfusions of two units of packed red blood cells qualifying the severity of their complications as moderate adverse events by SIR criteria (14.3%). One patient experienced a major adverse event related to bleeding (4.8%). He required two procedures to treat splenic venous and arterial pseudoaneurysms, respectively, and an operation to evacuate a painful intraperitoneal hematoma (**Fig. 2**).

Transsplenic access tract embolization is a commonly reported technique to lower the risk of tract hemorrhage.^{3,5,9,13} Commonly reported embolics, including Gelfoam, coils, coils and glue, and vascular plugs, have demonstrated acceptable performance in this regard.^{1,2,12,15,16} This study demonstrates that low-cost microfibrillar collagen confers no greater risk of PTSVA tract hemorrhage compared to Gelfoam, NBCA or coils when used alone or in combination with one of these agents (*p* = 0.977). Pimpalwar et al demonstrated a relatively higher rate of transsplenic access tract hemorrhage of 27% in a pediatric cohort embolized with Gelfoam pledgets or microfibrillar collagen, but this study did not make a comparison of different embolic agents with respect to tract hemorrhage. Interestingly, the authors of that study report limited success with microfibrillar collagen, which they discontinued early in the course of their work due to clogging of microfibrillar collagen-contrast slurry in the 4 French dilators they used to deploy the embolic.¹⁴ In this study, PTSVA tract embolization was performed in 17 cases without experiencing delivery system occlusion. At the authors' institution, microfibrillar collagen is routinely used for closure of both transhepatic and transsplenic access tracts. Benefits of this agent include the low cost, ease of use, and lack of permanent artifact on future CT imaging associated with coils and NBCA tract closure.

We detected a significant difference in preprocedural mean platelet levels between patients who did and did not experience a PTSVA tract hemorrhage following tract embolization (**Table 4**). The cohort of patients who experienced PTSVA tract hemorrhage demonstrated a mean platelet level of 58,000 plt/mm³, which is higher than the cutoff of 50,000 plt/mm³ recommended by the SIR anticoagulation

guidelines for procedures with significant bleeding risk.¹⁷ The increased rate of bleeding may have been due to concomitant bleeding risk factors that were not independently associated with higher PTSVA tract bleeding in our study, likely due to our small patient population. Zhu et al reported a higher prevalence of transsplenic access hemorrhage in a 46-patient series among patients with moderately elevated INR in the range of 1.51 to 1.64.¹³ However, we did not detect INR to be a significant risk factor for PTSVA tract bleeding, possibly also due to the small size of our population.

Additionally, we found age to be a significant risk factor for prediction of PTSVA tract hemorrhage in our cohort, which has not been previously reported in the literature. The loss of physiologic reserve associated with advancing age may correlate with multiple risk factors for tract bleeding.

This study is limited by its retrospective uncontrolled design. No differences were detected in clinical outcomes on the basis of chosen PTSVA tract embolic; however, a lack of post-procedural imaging in many cases may have resulted in underreporting of clinically insignificant mild adverse events with respect to PTSVA tract bleeding. Furthermore, a lack of standardized ratios of Gelfoam and microfibrillar mixture with iodinated contrast material, and NBCA mixture with ethiodized oil limited our development of a given protocol by which liquid embolics may be used with equal efficacy for PTSVA tract embolization. Furthermore, our small population size imposed several limits to our statistical analysis. The technical success of PTSVA tract embolization was observed in 9/10 cases that could be assessed, with the other 11 having absent/insufficient imaging, making that part of the study descriptive. This, in addition to a lack of a controlled design, accounts for the confinement of our studied tract embolics to broad categories apart from microfibrillar collagen. Our small patient sample size may also explain why we were unable to identify expected risk factors as significantly predictive of PTSVA tract hemorrhages.

Conclusion

PTSVA is an important adjunctive technique for common portal venous interventions, particularly those complicated by portal venous occlusion. Within the limitations of our study, we have demonstrated that embolization of transsplenic venous access tract is safe and effective.

Ethical approval

The article was exempted from an ethical committee approval.

Conflict of Interest

None declared.

References

- 1 Chu HH, Kim HC, Jae HJ, et al. Percutaneous transsplenic access to the portal vein for management of vascular complication in patients with chronic liver disease. *Cardiovasc Intervent Radiol* 2012;35(06):1388–1395
- 2 Habib A, Desai K, Hickey R, et al. Portal vein recanalization-transjugular intrahepatic portosystemic shunt using the transsplenic approach to achieve transplant candidacy in patients with chronic portal vein thrombosis. *J Vasc Interv Radiol* 2015;26(04):499–506
- 3 Liang HL, Yang CF, Pan HB, Chen CK, Chang JM. Percutaneous transsplenic catheterization of the portal venous system. *Acta Radiol* 1997;38(02):292–295
- 4 Quinn SF, vanSonnenberg E, Casola G, Wittich GR, Neff CC. Interventional radiology in the spleen. *Radiology* 1986;161(02):289–291
- 5 Haddad MM, Fleming CJ, Thompson SM, et al. Comparison of bleeding complications between transsplenic versus transhepatic access of the portal venous system. *J Vasc Interv Radiol* 2018;29(10):1383–1391
- 6 Ohm J-Y, Ko G-Y, Sung K-B, Gwon D-I, Ko HK. Safety and efficacy of transhepatic and transsplenic access for endovascular management of portal vein complications after liver transplantation. *Liver Transpl* 2017;23(09):1133–1142
- 7 Brazzini A, Hunter DW, Darcy MD, et al. Safe splenoportography. *Radiology* 1987;162(03):607–609
- 8 Probst P, Rysavy JA, Amplatz K. Improved safety of splenoportography by plugging of the needle tract. *AJR Am J Roentgenol* 1978;131(03):445–449
- 9 Monroe EJ, Speir EJ, Hawkins CM, Shivaram G, Koo KSH, Gill AE. Transsplenic splenoportography and portal venous interventions in pediatric patients. *Pediatr Radiol* 2018;48(10):1441–1450
- 10 Khalilzadeh O, Baerlocher MO, Shyn PB, et al. Proposal of a new adverse event classification by the Society of Interventional Radiology Standards of Practice Committee. *J Vasc Interv Radiol* 2017;28(10):1432–1437.e3
- 11 Thornburg B, Desai K, Hickey R, et al. Portal vein recanalization and transjugular intrahepatic portosystemic shunt creation for chronic portal vein thrombosis: technical considerations. *Tech Vasc Interv Radiol* 2016;19(01):52–60
- 12 Gong GQ, Wang XL, Wang JH, et al. Percutaneous transsplenic embolization of esophageal and gastro-fundal varices in 18 patients. *World J Gastroenterol* 2001;7(06):880–883
- 13 Zhu K, Meng X, Zhou B, et al. Percutaneous transsplenic portal vein catheterization: technical procedures, safety, and clinical applications. *J Vasc Interv Radiol* 2013;24(04):518–527
- 14 Pimpalwar S, Chinnadurai P, Hernandez A, Kukreja K, Siddiqui S, Justino H. Trans-splenic access for portal venous interventions in children: do benefits outweigh risks? *Cardiovasc Intervent Radiol* 2018;41(01):87–95
- 15 Grosse U, Brechtel K, Ketelsen D, et al. Portal vein recanalization and embolization of the transsplenic puncture tract using an Amplatzer® vascular plug: a case report. *BMC Res Notes* 2015;8:193
- 16 Ullmer W, Müller-Wille R, Grothues D, et al. Gelfoam for closure of large percutaneous transhepatic and transsplenic puncture tracts in pediatric patients. *Röfo Fortschr Geb Röntgenstr Nuklearmed* 2014;186(07):693–697
- 17 Patel IJ, Rahim S, Davidson JC, et al. Society of Interventional Radiology Consensus Guidelines for the Periprocedural Management of Thrombotic and Bleeding Risk in Patients Undergoing Percutaneous Image-Guided Interventions-Part II: Recommendations: Endorsed by the Canadian Association for Interventional Radiology and the Cardiovascular and Interventional Radiological Society of Europe. *J Vasc Interv Radiol* 2019;30(08):1168–1184.e1