



Is Non-Restorative Cavity Treatment a Practical Choice in Primary Teeth?

Amarshree A. Shetty¹ Aditi Acharya¹ Manju R.²

¹Department of Paediatric and Preventive Dentistry, AB Shetty Memorial Institute of Dental Sciences, Deralakatte, Mangalore, Karnataka, India

²Department of Pediatric Dentistry, AB Shetty Memorial Institute of Dental Sciences, Deralakatte, Mangalore, Karnataka, India

Address for correspondence Aditi Acharya, Post Graduate, Department of Paediatric and Preventive Dentistry, AB Shetty Memorial Institute of Dental Sciences, Deralakatte, Mangalore 575018, Karnataka, India (e-mail: draditiacharya94@gmail.com).

J Health Allied Sci^{NU} 2022;12:361–368.

Abstract

For years, “extension for prevention” was considered as the standard protocol for the restoration of caries. With advances in the field of cariology regarding the biofilm and improvement in materials, this perspective is being challenged. This is being challenged by more biological and less-invasive approaches, where the emphasis is on biofilm alteration to arrest carious lesions. This minimally invasive intervention is based on the concept that biofilm overlying the carious lesion is a driving force for the carious process and not the bacteria present in the infected dentin. Hence, daily removal or disruption of this biofilm will slow down the carious process or bring it to halt.

One such approach is non-restorative cavity treatment, where no caries is removed but lesions are made self-cleansable that allows it to be brushed by the parent or the child. This wholesome approach targets the disease at a causal level.

This review of literature describes the various advantages and limitations of this technique and the practicability of its use in pediatric patients during the pandemic COVID-19.

Keywords

- ▶ biological caries management
- ▶ NRCC
- ▶ NRCT

Introduction

Complete removal of all traces of carious tooth tissue within a carious lesion was considered the gold standard technique with “extension for prevention” concept being invoked to ensure that restoration margins were placed on areas of the tooth that are less vulnerable to caries. Advances in the field of cariology regarding the biofilm, with availability of advanced materials, have challenged this perspective.¹ This is being challenged by more biological and less-invasive approaches, where the emphasis is on biofilm alteration^{2,3}. This paradigm shift from conventional restorative or surgical approaches to caries^{5,6} is a minimally invasive intervention

based on the concept that biofilm overlying the carious lesion is a driving force for the carious process and not the bacteria present in the infected dentin. Hence, daily removal or disruption of this biofilm will slow down the carious process or bring it to halt.⁴

One such approach is non-restorative cavity treatment, where no caries is removed but lesions are made self-cleansable which allows it to be brushed by the parent or the child. This wholesome approach targets the disease at a causal level.

However, there are not enough reliable clinical trials and consensus about the protocol to apply in patients while performing non-restorative cavity treatment. Issues such as how to rely on clinical judgment to determine the extent

published online
March 8, 2022

DOI <https://doi.org/10.1055/s-0042-1743530>.
ISSN 2582-4287.

© 2022. Nitte (Deemed to be University). All rights reserved.
This is an open access article published by Thieme under the terms of the Creative Commons Attribution-NonDerivative-NonCommercial-License, permitting copying and reproduction so long as the original work is given appropriate credit. Contents may not be used for commercial purposes, or adapted, remixed, transformed or built upon. (<https://creativecommons.org/licenses/by-nc-nd/4.0/>)
Thieme Medical and Scientific Publishers Pvt. Ltd., A-12, 2nd Floor, Sector 2, Noida-201301 UP, India

of carious lesion, its indications and contraindications have not been summarized adequately. Hence, the objective of this review of literature is to address all these concerns and summarize them through the literature available for the optimal management of patients in a dental operator, keeping in mind the current concept of prevention and minimal invasion.

History

G.V. Black proposed the concept of removal of all cariogenic bacteria from the infected dental hard tissues with subsequent placement of a plastic restoration. Thus, one historic aim of carious tissue removal was to remove all the bacteria.⁷

This concept no longer aligns with the current understanding of caries. Now caries is believed to be caused due to the result of an ecological imbalance, triggered by an abundant intake of fermentable carbohydrates, leading to an imbalance in the biofilm composition and activity, and a net mineral loss caused by the bacteria due to an increased amount of acid production while metabolizing carbohydrates.⁸ Hence, this gives us an understanding that not all bacteria need to be removed; depriving the bacteria of their nutrients (fermentable carbohydrates) by sealing off them under restorations will serve the purpose, eventually leading to their inactivation.⁹ Most of the bacteria are unable to withstand starvation and eventually only a negligible amount perish. With introduction of newer adhesive systems for restorations, it is not necessary to provide macro-retentive properties such as in amalgam restorations to provide mechanical support.

The main aim of removal of all carious tissue that applies today is to provide a restoration having good longevity; however, the historic belief is that demineralized dentin may not be able to provide as much support as sound dentin would to the restorative material; hence, the removal of soft dentin was considered necessary to improve its longevity. Moreover, demineralized dentin retains the collagen backbone as long as the dentine is not completely contaminated by bacteria; in such cases remineralization and functional "healing" are possible, which is the concept of minimally invasive treatments.

Is It Necessary to Restore the Teeth?

We often fail to question ourselves as to what could happen if the teeth were left unrestored without any intervention.

We work with a presumption that the lesion will definitely progress if left unrestored. But we fail to understand that the actual prognosis of the disease in itself determines the choice of treatment. What this means is that watching the progression of the lesion and then deciding what treatment is to be offered will serve as benefit rather than conclusively going ahead with conservative treatments.

Levine et al conducted a study under two general dental practices that were established in 1975. Both the prevalence and pressure on available resources were much higher than

these are today. Asymptomatic deciduous caries teeth was frequently seen but usually left unrestored and this policy continued. Hence, in this study, the management consisted of regular reinforcement of simple dietary and tooth brushing advice. The clinical records of over 20 years was used in this study and it was seen that out of 1,587 non-treated cavitated primary teeth in 481 children, only 16% of the untreated teeth went on to cause pain and had to be restored or extracted with a mean survival time of 740 days. While the remaining 84% teeth studied remained pain free until being naturally shed after a mean interval of 1,241 days from diagnosis. The results of the study provide an evidence to aid the treatment planning of carious teeth in children receiving regular preventive dental care.¹⁰

We have come to an understanding that not all the lesions progress, which brings us to the current concept of non-restorative cavity treatment. It must be emphasized that non-restorative is not the same as lack of management.

Current Concept

In primary teeth, long-lasting restoration is not the primary aim. The main aim is to ensure that it remains in a disease-free and functional state until exfoliation.

Unlike permanent teeth, the disease progresses at a faster pace due to the morphology and composition of the teeth; hence, conservative management could lead to pulpal exposure, necessitating to either extract or perform pulp therapy. The feasibility and success of these conservative techniques may vary depending upon the age of the child, the level of cooperation of the child, and the parental financial status. Despite that the prognosis of these treatments are often questionable. In areas where awareness, accessibility to healthcare systems and income is low, preventive strategies can play a major role in curbing the disease process until definitive treatment strategies can be employed.

Non-restorative cavity treatment is one such method that works by making the cavity self-cleansable but does not help in restoring the surface integrity. Although it has a sound logical and pathological basis, its application is limited to primary teeth or root surface caries; for example, in children with special healthcare needs, high-risk children with limited compliance in a stabilization phase or immobile geriatric patients.^{11,12}

Non-Restorative Cavity Control

Non-restorative cavity treatment¹³ (NRCT) is a non-restorative method of controlling dentin lesions. It sits alongside Non-Operative Caries Treatment Program (NOCTP), a method of controlling enamel lesions. Taken together, this non-restorative management of enamel and dentine lesions is called non-restorative cavity control (NRCC).

It is a three-part treatment option for dentin cavities in primary dentition, root carious lesions, and cavitated coronal smooth surface lesions. The first part aims at improving the patients oral hygiene, the second part targets at making the cavity self-cleansable by removing the overhanging enamel

such as in proximal lesions, slicing of the enamel in the proximal surface enables the cavity to be accessible while tooth brushing with a fluoridated tooth paste, and the third part involves supporting the treatment with a 38% silver diamine fluoride or 5% NaF application based on the diagnosis of caries lesion activity whether it is cavitated or non-cavitated.⁴

Goals of Non-Restorative Cavity Control in Primary Teeth

1. Preserve the functionality of teeth until exfoliation without causing pain or inflammation.
2. Child friendly.
3. Reduce dental fear and anxiety toward oral health and increase confidence in the dental professional.
4. Daily and consistent improvement in oral hygiene measure by both the child and the parent/caregivers.
5. Erupting permanent teeth should remain healthy.

Advantages

- It has an advantage over the traditional restorative approach that it avoids the use of drills; hence, this could eliminate fear and anxiety to a considerable amount.
- Cavitated lesions can be managed without having to place a restoration and also avoiding restorative care under general anesthesia.⁴
- In case of primary teeth, restorative treatment can be postponed or avoided completely if the tooth remains in a disease-free functional state until exfoliation.
- It avoids futile or detrimental repeat restorative cycle, where cavities outline has to be redesigned.⁴
- Makes patients and parents aware about their responsibilities toward maintaining their oral health and quality of oral hygiene procedures.⁴
- It is cost-effective as the number of clinical visits is reduced and also helpful in the population who have difficulty in accessing healthcare facilities.
- The disease process can be studied over a period of time and in case of an uncooperative child, this further helps in behavior shaping.⁴
- Success or failure can be observed in time and discussed with the child and the caregiver.
- It can buy time for the child until the child develops the cognition to understand and cope with more invasive treatment, should it be necessary.⁴
- This form of treatment is more acceptable in children of the pre-cooperative age group.
- Allows children to get more acclimatized with the environment of the dental clinic.
- Considering the current pandemic situation, this treatment can be performed with minimum armamentarium, and aerosol generation can be avoided to a minimum.
- Can be an alternative for invasive treatments under general anesthesia.

Indications

NRCC should be the first line of choice under the following situations¹⁴:

1. Young children (4 years or younger): non-invasive treatments can prevent or at least postpone the need to conduct invasive therapies to an older age until the child is old enough to cope with these.
2. Children with dental anxiety toward invasive treatments, with this treatment, need for invasive therapy can be postponed.
3. In children (8–9 years and older) with many active carious lesions in primary teeth, this treatment can eliminate the need for invasive therapy until the teeth exfoliate. In case of pain, extraction is the choice of treatment.
4. In children of pre-cooperative age group and children with special healthcare needs where general anesthesia is contraindicated and gaining cooperation is difficult, this can slow down the disease process.

Contraindications

1. It should not be used when immediate invasive action is required such as during pain, infection, or sepsis.⁴
2. When patients or parents/caregivers show no readiness to change the behavior that has led to the development of the disease.⁴
3. Achieving a long-term follow-up may not be possible.

Treatment Protocol

NRCC is indicated in young children with active, cavitated, caries lesions in the primary dentition and/or with dental anxiety. The emphasis of this is to treat the cause of caries over time, decreasing discomfort to the child, and promoting oral health. Restoration of teeth is of secondary importance.¹⁵

The success of this type of caries management strategy mainly depends on the patient and parent who are ready to accept their responsibility for the disease and commit to remedial action, including dietary modification and regular and frequent tooth brushing with fluoridated tooth paste.⁴ Hence, it is advisable for the clinician to obtain an informed consent from the patient and parents/caregivers prior to the commencement of the treatment. The consent should clearly mention the goals of treatment, the clinician's role, the parents and child's role required to make the treatment a success (→ Table 1).¹⁴ The technical protocol involves making the lesion self-cleansable by removing any overhanging enamel, and in case of proximal lesions, slicing the proximal enamel with a hatchet, enamel access cutter, or diamond burr. Care has to be taken to prevent any food impaction and loss of space in regions where proximal slicing of enamel has been done.

For this, the parents or caregivers have to be motivated to brush their child's teeth twice daily with an age-appropriate amount of fluoridated toothpaste as advised. Correct method of tooth brushing must be taught with special consideration

Table 1 Treatment protocol of NRCC consists of several steps (adapted from Gruthuysen¹⁴)

Administrative	Contract involving the informed consent, clarifying the purpose of the treatment and the role of the dental professional and patient, parents/caregiver to make the treatment successful
Technical	Make the cavity accessible for (professional) home care cleaning; using a hatchet or diamond burr overhanging enamel can be removed; in the case of an approximal cavity, slicing (in a V-form shape without losing contact with the neighboring tooth) will enhance accessibility. Teach and check the skills of the patient, parents/caregiver how to clean the cavity adequately with the preferred toothbrush
Behavioral	Use appropriate behavioral change techniques such as motivational interviewing; this includes a step of checking that the information has been understood; make voice recordings of the sessions for educational purposes for yourself
Safety net	Apply fluoride varnish (every 3 months), SDF (once/twice a year), or a remineralization promoting liner (glass-ionomer) until the dentine has rehardened.
Periodic evaluation	Tailor periodic evaluation to the alleged success for the next period; at most a 3-month period, unless a longer period argued for; use light photographs and/or a notation system such as Ekstrand, Nyvad or ICDAS to monitor caries/lesion activity/size; decide whether the treatment is still justified; reinforce of the self-care strategy

toward the cleaning of proximal surfaces.¹⁶ Dutch guidelines,¹⁷ based on 5 years of experience, suggest that NRCC is explicitly indicated in young children with active caries lesions and children with dental anxiety where restorative treatments are not accepted. The dentist and the parents must maintain a good rapport as communication is the key to success, and a considerable amount of time has to be spent by the dentist in motivating the child or parents/caregivers in explaining the importance of home hygiene methods and it can in turn make a difference in the management strategy. Reinforcement of knowledge by sending voice memos and video clippings to the parents or caregivers can be motivating and help reform behavior. Supplementing this with a safety net support such as by either the use of 5% NaF varnish every 3 months, or annual/biannual application of 38% SDF or a remineralization promoting liner such as glass ionomer cement. Caries activity and lesions size can be monitored through colored photographs. There has been no definitive protocol for recall management but this can be scheduled after assessing the individual's caries risk. For example, the patient could be called every month; on encountering any improvement in performance, these recall visits can be further extended to a once in a 3-month period. Santamaria et al in their study compared three different types of biological caries management techniques used a period of 3 months recall period for the non-restorative cavity control group.¹⁸ Case selection plays a crucial role in success; assessing the progression of the lesion has to be done appropriately. This can be done using clinical assessment criteria given by various researchers such as Ekstrand, Frejeskov, and Nyvad or ICDAS that guides in visual assessment of the extent of the lesion, its size and color whether it is active or inactive. Based on this, further decision can be made on the intervention required to be performed. In 2018, the American Dental Association in their evidence-based clinical recommendations for the arrest or reversal of non-cavitated and cavitated dental caries using non-restorative treatments in children and adults has suggested a clinical pathway for the non-restorative treatment of non-cavitated and cavitated lesions

in primary teeth which can be used by practitioners in making a clinical decision (→ Fig. 1).¹⁹

Scientific Evidence Indicating Success of NRCC in Primary Teeth

On contrary to what we know GV Black in his textbook of 1908¹ wrote: "All buccal and labial cavities in which decay is burrowing should be fully opened by clipping away all the overhanging enamel and left as wide open as possible in order to admit free washing, both in artificial cleaning and in fresh clean saliva." This advice concurs with the observation from Anderson in 1938,²⁰ who showed that carious lesion progression within a cavity was arrested in primary teeth after making the occlusal cavitated lesion accessible for cleaning. This observation was made in the pre-fluoride era.

In another observational study,²¹⁻²³ NRCC showed success where it was deployed in 30 toddlers who suffered from early childhood caries. Active caries in the proximal surfaces were made accessible by slicing of the overhanging enamel. The children received fluoride gel (2% sodium fluoride) applications every 2 months. The caregivers were taught how to clean and the lesions and were instructed regarding cariogenic diet and oral health. After 1 year, 90% of these anterior lesions became inactive and did not show any pain or inflammation.

Mijan et al^{24,25} conducted a study to test the hypothesis that there is no difference in the survival rates of molars treated according to the conventional restorative treatment using amalgam, atraumatic restorative treatment (ART), and ultraconservative treatment (UCT) protocol after 3.5 years in children 6 to 7 years of age. In the UCT, small dentine carious cavities were treated according to the ART protocol. Medium-sized dentine carious cavities in primary molars were not restored but enlarged with a hatchet to facilitate plaque removal with a toothbrush and fluoridated toothpaste (1,000 ppm). Large dentine carious cavities in primary molars were also left unrestored and cleaned as described for medium-sized cavities. The criterion for enlarging

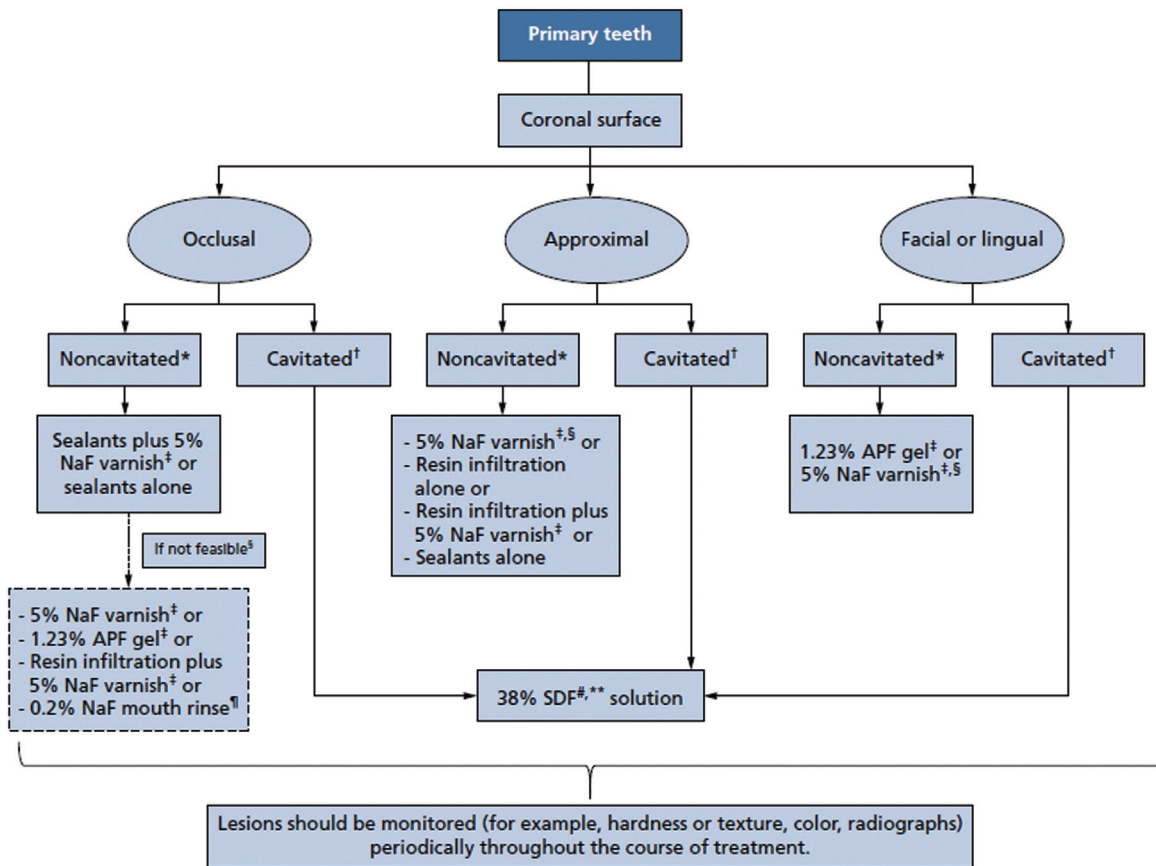


Fig. 1 Clinical pathway for non-restorative treatment of non-cavitated and cavitated carious lesions on primary teeth (adapted from ADA evidence-based practice guidelines 2018¹⁹).

multiple surfaces cavities was to create free access for the bristles of the toothbrush in bucco-lingual direction, allowing the cavities to be cleaned. It was observed after 3.5 years that no difference was found in the cumulative survival rates of primary molars treated according to the CRT, ART, and UCT protocols.

Santamaria et al²⁶ compared three treatment protocols, i.e., Halls technique, NRCC, and conventional restoration in children with high caries risk. In the NRCC group, accessibility of the cavity was enhanced and 5% sodium fluoride varnish was applied. The patients were recalled every 3 months for recall and the varnish application was re-done, if need be. The caregivers of the children aged 3 to 8 years were taught to brush the teeth in the bucco-lingual direction. After 2.5 years, 142 children could be included in the evaluation out of 168. The results showed that Halls technique (2.5% major failures) was superior in comparison to conventional restoration (9.0% major failures) and NRCC (9.0% major failures). Within the NRCC group, major failures were due to failure in adhering to the 3-month recall and also because the lesions selected belonged to ICDAS 5–6 and also could be due to the use of sodium fluoride varnish in cavitated lesions.²⁷ However, children's behavior was cooperative in both Halls technique and NRCC compared with conservative treatment.

An evidence-based dentistry update on silver diamine fluoride confirmed that SDF is effective for caries arrest on

cavitated lesions in primary teeth. It may also prevent new lesions.²⁸ Application is easy, non-invasive, affordable, and safe. Although it stains the lesions dark as it arrests them, it provides clinicians with an additional tool for caries management.²⁹ A systematic review showed that SDF reduces the growth of cariogenic bacteria by inhibiting demineralization and promoting remineralization of demineralized enamel and dentine.³⁰ Moreover, it is seen to hamper the degradation of the dentine collagen.³¹ In another systematic review, it was concluded that SDF in a concentration of 30% and 38% showed potential as an alternative treatment for caries arrest in the primary dentition and permanent first molars.^{32,33} Considering this supplementing the cavities with SDF will be a good option in further prolonging the life of teeth with carious lesions.

There are various studies that have suggested supplementing glass ionomer cement as a liner with both chemomechanical preparation (Carisolv) and atraumatic restorative treatment. The clinical success rates of longevity of glass ionomer cement with both these techniques have remained comparable with none being superior statistically.^{34,35} However, there are no clinical studies that have tested the use of glass ionomer cement in NRCC. Once the caries process is arrested, there is no harm in supplementing the cavity with a glass ionomer cement as this forms a barrier between the exposed dentin and the bacteria present in the

saliva. Glass ionomer has fluoride releasing and recharging property that could future be beneficial in arresting the caries and striking a balance between the de and remineralization process. This opens opportunities for researchers to conduct more studies in this area.

In a recent study done by Eden et al done to provide evidence-based management for dental caries that eliminates or reduces the generation of aerosols and aids personalized care planning based around aerosol-generating procedure reduction have stated that NRCC has a less robust evidence base than the other treatment options, with most of the reports of success being related to particular situations and performed by dentists who support this technique.³⁶

Through all the above studies it is evident that NRCC is not a new concept, this type of caries management has been practiced because the pre-fluoridated era however no particular guidelines were used for the same. Since the introduction of the term NRCC, along with that came the protocols where this technique could possibly be used. However, despite various studies being done, the clinical applicability still remains questionable as no long-term studies have been done for the same. The criteria for case selection for NRCC in all the above studies have not been elaborated, which is the main key factor that determines the success for this type of caries management.

NRCC during the Pandemic COVID-19

The COVID-19 pandemic originated in China in December 2019; ever since then, it has exposed 7 billion human on our planet to one of the worst and most rapidly expanding pandemics known to the global population since the Spanish flu.³⁷

Although in the pediatric population, the infection is reported to be relatively mild and has shown to have better prognosis.^{38,39} Mortality rates although lesser is worrisome when children with co-morbidities are concerned. The median period of viral spread is 9–15 days as measured from illness onset to discharge and in asymptomatic patients this period is shown to be relatively shorter.^{40,41} Therefore, it can be assumed that both the children and individuals are potentially infective (Royal College of Surgeons England [RCS], 2020)⁴² with the potential of cross-infection to health-care workers and general public.

As most dental work is invasive and aerosol-generating health authorities around the globe, ADA, Centres for Disease Control and Prevention (CDC), RCS, Scottish Dental Clinical Effectiveness Program (SDCEP), Australian Dental Association (AusDA), and the Ministry of Health and Dental Council New Zealand (NZMOH)] have recommended suspending these procedures.^{43–47}

Certain strata such as children with special healthcare needs who often have comorbidities such as increased bleeding due to medications, increased risk of infections, and children at risk of acquiring infective endocarditis.⁴⁸ Additionally, children with long-term respiratory diseases, including chronic lung disease of prematurity with oxygen dependency, severe asthma, cystic fibrosis with significant

respiratory problems are identified as being at a significantly increased risk from COVID-19. These children have been prohibited from going to hospitals or dental clinic settings unless the dental condition is considered “life-threatening” (RCSENG, 2018⁴⁹). Due to confinement of these children at home, most of their healthcare needs have remained largely unattended. It is a known fact that mouth is the mirror of the human body; hence, good oral health leads to an overall maintenance of good general health. Hence, minimizing the progression of the existing condition seems like the best alternative treatment of choice and this can be achieved through techniques such as non-restorative cavity treatment which requires minimum armamentarium and where treatments do not specifically have to be done at a dental setting. Hence, it is only logical to prioritize and emphasize all oral health preventive and therapeutic measure during this time.⁵⁰

A 2016 European Academy of Pediatric Dentistry policy document regarding the best clinical practice guidance for the management of early caries lesions in children and young adults concluded that non-cavitated caries lesions can be managed non-invasively in the majority of cases. The spectrum of measures includes a low cariogenicity tooth-friendly diet, daily and appropriate management of the biofilm, home and within the dental office/surgery, usage of fluorides as well as sealing techniques. The policy emphasized on the importance of performing caries the risk assessment at a child's first dental visit and reassessments on a regular basis.⁵¹

COVID-19 is and will be a part and parcel of pediatric dental practice henceforth, triaging cases into advice only, urgent, and emergency cases should become a standard practice during the current pandemic. Avoidance of aerosol-generating procedure leave us with the option of deterring the use of minimally invasive or non-invasive procedures. Non-restorative cavity treatment can be a very logical approach when combined with adhering to appropriate case selection can serve as a fruitful line of management.

Unanswered Questions

- In children with early childhood caries, there is an enormous increase in the bacterial load. A study done to investigate the prevalence of *Streptococcus mutans* in active and arrested dentine carious lesions of children with early childhood caries suggests that the amount of *S. mutans* was high in both active and arrested lesions; however, a higher relative quantity of oral total streptococci was seen in arrested lesions, reaching a proportion of 17% from the oral total bacterial load.⁵² Considering such scenarios will treatments such as NRCC really help in bringing down the bacterial load? Or will just preventive interventions in this case help in completely stopping the lesions from progressing further, this is debatable.
- During slicing of the proximal surfaces of primary teeth because no restorative material is placed, there is always a possibility of mesial drifting of the teeth if the slicing is

done incorrectly, the amount of slicing done would again be subjective, i.e., vary on the clinicians judgment.⁵³

- If the slicing is done incorrectly, there is a chance of food impaction that could farther progress the condition.⁵³
- Once a tooth is sliced, restoration is often no longer possible and extraction is the only remaining alternative. In practice, this concern is usually unfounded. The technique opens up the undisturbed area for the biofilm and with carer cleaning, the caries process will slow down or arrest.

Due to limited research on the current concept, these questions remain unanswered and further research and longitudinal studies shall help in understanding and strengthening this concept of caries management.

Conclusion

Dental caries is no longer considered as an infectious disease. With the change in understanding of this process, the modern philosophies believe in providing treatment to control their activity rather than completely eliminate them. With the emergence of the pandemic COVID-19, pediatric dentistry has faced a major impact, forcing us to provide care based on triaging where only urgent and emergency management is to be done. Aerosol-generating procedures are to be deferred or kept to a minimum, due to which all the conservative methods of treatment have taken a backseat. Hence, utilizing preventive approaches that are minimally or non-invasive is the best option. Leaving the deciduous teeth unattended would mean an increase in the potential of severe dental and medical consequences as the occurrence of painless alveolar infection is more common.

Non-restorative caries management is one amongst the many biologic strategies for caries management targeted for primary teeth. It requires minimum armamentarium, patient cooperation can be achieved, less time-consuming, cost-effectiveness, to mention a few. The only drawback is its dependence on patient or parental cooperation in maintaining a good oral hygiene without which it is a failure. On ethical grounds, a question may often arise as to “how can we leave a cavitated teeth unrestored?” It is necessary to clear the misunderstanding, there lies a difference in leaving a cavitated teeth untreated and unrestored. In the latter, we are aiming at eliminating the bacterial load that has led to the formation of carious lesions by making the lesions self-cleansable and teaching the parents the correct way of brush the teeth.

Hence, professionals who choose NRCC must commit themselves to being critical regarding their knowledge on the applicability and the use of NRCC and to commence a cycle of quality improvement.

Conflict of Interest
None declared.

Reference

- 1 Black GV. *A Work on Operative Dentistry*. Chicago: Medico-Dental Publishing; 1908
- 2 Schwendicke F, Meyer-Lueckel H, Dörfer C, Paris S. Failure of incompletely excavated teeth—a systematic review. *J Dent* 2013; 41(07):569–580. Doi: 10.1016/j.jdent.2013.05.004
- 3 Ricketts D, Lamont T, Innes NP, Kidd E, Clarkson JE. Operative caries management in adults and children. *Cochrane Database Syst Rev* 2013;(03):CD003808
- 4 van Strijp G, van Loveren C. No removal and inactivation of carious tissue: non-restorative cavity control. *Monogr Oral Sci* 2018; 27:124–136. Doi: 10.1159/000487839
- 5 Ricketts DNJ, Pitts NB. Traditional operative treatment options. *Monogr Oral Sci* 2009;21:164–173. Doi: 10.1159/000224221
- 6 Kandiah T, Johnson J, Fayle SA *British Society of Paediatric Dentistry. British Society of Paediatric Dentistry: a policy document on management of caries in the primary dentition. Int J Paediatr Dent* 2010;20(Suppl 1):5. Doi: 10.1111/j.1365-263X.2010.01087.x
- 7 Black GV. *The Pathology of Hard Tissues of the Teeth. Part III. Treatment of Caries in Operative Dentistry. Vol 1*; London: Medico-Dental Publishing; 1936
- 8 Marsh PD. Dental plaque as a biofilm and a microbial community - implications for health and disease. *BMC Oral Health* 2006;6(1, Suppl 1)S14
- 9 Oong EM, Griffin SO, Kohn WG, Gooch BF, Caufield PW. The effect of dental sealants on bacteria levels in caries lesions: a review of the evidence. *J Am Dent Assoc* 2008;139(03):271–278, quiz 357–358. Doi: 10.14219/jada.archive.2008.0156
- 10 Levine RS, Pitts NB, Nugent ZJ. The fate of 1,587 unrestored carious deciduous teeth: a retrospective general dental practice based study from northern England. *Br Dent J* 2002;193(02):99–103. Doi: 10.1038/sj.bdj.4801495
- 11 Schwendicke F. Removing carious tissue: why and how? *Monogr Oral Sci* 2018;27:56–67. Doi: 10.1159/000487832
- 12 Kher MSRA. *Contemporary Treatment Techniques in Pediatric Dentistry*. SpringerCham2019. Doi: 10.1007/978-3-030-11860-0_1
- 13 Innes NP, Frencken JE, Bjørndal L, et al. Managing carious lesions: consensus recommendations on terminology. *Adv Dent Res* 2016; 28(02):49–57. Doi: 10.1177/0022034516639276
- 14 Gruythuysen RJ. Niet-Restauratieve Caviteitsbehandeling. Carië-sactiviteit beteugelen in plaats van maskeren. [Non-Restorative Cavity Treatment. Managing rather than masking caries activity] *Ned Tijdschr Tandheelkd* 2010;117(03):173–180 Doi: 10.5177/ntvt2010.03.09176
- 15 Gruythuysen RJM. Non-restorative cavity treatment: should this be the treatment of choice? reflections of a teacher in paediatric dentistry. *Dent Update* 2019;46(03):220–228
- 16 Fejerskov O, Nyvad B. Root surface caries-rationale behind good diagnostic practice. *Monogr Oral Sci* 2017;26:43–54. Doi: 10.1159/000479306
- 17 Stel G, Veerkamp JSJ, van Amerongen WE, Martens LC, van Gemert-Schriks MCM. Treatment of (deep) caries lesions in primary teeth. In: *Kindertandheelkunde Part 2*. Houten: Bohn Stafleu van Loghum, 2013: Chapter 32.
- 18 Santamaría RM, Innes NPT, Machiulskiene V, Schmoekel J, Alkilzy M, Splieth CH. Alternative caries management options for primary molars: 2.5-year outcomes of a randomised clinical trial. *Caries Res* 2017;51(06):605–614. Doi: 10.1159/000477855
- 19 Slayton RL, Urquhart O, Araujo MWB, et al. Evidence-based clinical practice guideline on nonrestorative treatments for carious lesions: a report from the American Dental Association. *J Am Dent Assoc* 2018;149(10):837–849.e19. Doi: 10.1016/j.adaj.2018.07.002
- 20 Anderson BG. Clinical study of arresting dental caries. *J Dent Res* 1938;17(06):443–452

- 21 Lo EC, Schwarz E, Wong MC. Arresting dentine caries in Chinese preschool children. *Int J Paediatr Dent* 1998;8(04):253–260. Doi: 10.1046/j.1365-263x.1998.00094.x
- 22 Schwarz E, Lo EC, Wong MC. Prevention of early childhood caries—results of a fluoride toothpaste demonstration trial on Chinese preschool children after three years. *J Public Health Dent* 1998;58(01):12–18. Doi: 10.1111/j.1752-7325.1998.tb02985.x
- 23 Peretz B, Gluck G. Early childhood caries (ECC): a preventive-conservative treatment mode during a 12-month period. *J Clin Pediatr Dent* 2006;30(03):191–194. Doi: 10.17796/jcpd.30.3.h08h8mm843851213
- 24 Mijan M, de Amorim RG, Leal SC, et al. The 3.5-year survival rates of primary molars treated according to three treatment protocols: a controlled clinical trial. *Clin Oral Investig* 2014;18(04):1061–1069. Doi: 10.1007/s00784-013-1077-1
- 25 Mijan M, de Amorim RG, Leal SC, et al. Correction to: The 3.5-year survival rates of primary molars treated according to three treatment protocols: a controlled clinical trial. *Clin Oral Investig* 2018;22(01):545. Doi: 10.1007/s00784-017-2218-8
- 26 Santamaria RM, Innes NP, Machiulskiene V, Evans DJ, Splieth CH. Caries management strategies for primary molars: 1-yr randomized control trial results. *J Dent Res* 2014;93(11):1062–1069
- 27 Criteria Manual: International Caries Detection and Assessment System (ICDAS II). International Caries Detection and Assessment System (ICDAS) Coordinating Committee. Baltimore, Maryland: 12th–14th March; 2005
- 28 Llodra JC, Rodriguez A, Ferrer B, Menardia V, Ramos T, Morato M. Efficacy of silver diamine fluoride for caries reduction in primary teeth and first permanent molars of schoolchildren: 36-month clinical trial. *J Dent Res* 2005;84(08):721–724. Doi: 10.1177/154405910508400807
- 29 Fung MHT, Duangthip D, Wong MCM, Lo ECM, Chu CH. Randomized clinical trial of 12% and 38% silver diamine fluoride treatment. *J Dent Res* 2018;97(02):171–178. Doi: 10.1177/0022034517728496
- 30 Mei ML, Lo EC, Chu CH. Clinical use of silver diamine fluoride in dental treatment. *Compend Contin Educ Dent* 2016;37(02):93–98, z100
- 31 Gao SS, Zhang S, Mei ML, Lo EC, Chu CH. Caries remineralisation and arresting effect in children by professionally applied fluoride treatment – a systematic review. *BMC Oral Health* 2016;16:12
- 32 Mejåre I, Stenlund H, Julihn A, Larsson I, Permert L. Influence of approximal caries in primary molars on caries rate for the mesial surface of the first permanent molar in Swedish children from 6 to 12 years of age. *Caries Res* 2001;35(03):178–185. Doi: 10.1159/000047453
- 33 Barata TJ, Bresciani E, Mattos MC, Lauris JR, Ericson D, Navarro MF. Comparison of two minimally invasive methods on the longevity of glass ionomer cement restorations: short-term results of a pilot study. *J Appl Oral Sci* 2008;16(02):155–160. Doi: 10.1590/s1678-77572008000200014
- 34 Peng JJ, Botelho MG, Matinlinna JP. Silver compounds used in dentistry for caries management: a review. *J Dent* 2012;40(07):531–541. Doi: 10.1016/j.jdent.2012.03.009
- 35 Knight GM, McIntyre JM, Craig GG, Mulyani, Zilm PS, Gully NJ. An in vitro model to measure the effect of a silver fluoride and potassium iodide treatment on the permeability of demineralized dentine to *Streptococcus mutans*. *Aust Dent J* 2005;50(04):242–245. Doi: 10.1111/j.1834-7819.2005.tb00367.x
- 36 Eden E, Frencken J, Gao S, Horst JA, Innes N. Managing dental caries against the backdrop of COVID-19: approaches to reduce aerosol generation. *Br Dent J* 2020;229(07):411–416. Doi: 10.1038/s41415-020-2153-y
- 37 Snyder MR, Ravi SJ. 1818, 1918, 2018: two centuries of pandemics. *Health Secur* 2018;16(06):410–415. Doi: 10.1089/hs.2018.0083
- 38 Su L, Ma X, Yu H, et al. The different clinical characteristics of corona virus disease cases between children and their families in China—the character of children with COVID-19. *Emerg Microbes Infect* 2020;9(01):707–713. Doi: 10.1080/22221751.2020.1744483
- 39 Shen Q, Guo W, Guo T, et al. Novel coronavirus infection in children outside of Wuhan, China. *Pediatr Pulmonol* 2020;55(06):1424–1429. Doi: 10.1002/ppul.24762
- 40 Cruz AT, Zeichner SL. COVID-19 in children: initial characterization of the pediatric disease. *Pediatrics* 2020;145(06):e20200834. Doi: 10.1542/peds.2020-0834
- 41 Zimmermann P, Curtis N. Coronavirus infections in children including COVID-19: an overview of the epidemiology, clinical features, diagnosis, treatment and prevention options in children. *Pediatr Infect Dis J* 2020;39(05):355–368. Doi: 10.1097/INF.0000000000002660
- 42 Royal college of surgeons England. 2020 Recommendations for paediatric dentistry during COVID-19 pandemic. Accessed February 10, 2022 at: <https://www.rcsen.g.ac.uk/-/media/files/rcs/fds/guidelines/paediatric-dentistry-covid-19.pdf>
- 43 ADA Interim Guidance for Minimizing Risk of COVID-19 Transmission Visit ADA.org/InterimGuidance to View the Three Flowcharts Detailing Processes to Minimize COVID-19 Transmission When Treating Dental Emergencies. Accessed February 10, 2022 at: https://snlg.iss.it/wpcontent/uploads/2020/04/ADA_COVID_Int_Guidance_Treat_Pts.pdf
- 44 Centers for Disease Control and Prevention. 2020. Interim guidance for businesses and employers to plan and respond to coronavirus disease 2019 (COVID-19)
- 45 SDCEP COVID-19 guidance update. *BDJ Team* 2020;7(04):4. Doi: 10.1038/s41407-020-0296-y
- 46 Australian Dental Association. ADA dental service restriction in COVID-19. 2020
- 47 New Zealand Ministry of Health. 2020. Guidelines for oral health services at COVID-19 Alert Level 4. New Zealand dental association. Accessed February 10, 2022 at: <https://www.nzda.org.-nz/covid-19/protecting-your-health>
- 48 Al-Halabi M, Salami A, Alnuaimi E, Kowash M, Hussein I. Assessment of paediatric dental guidelines and caries management alternatives in the post COVID-19 period. A critical review and clinical recommendations. *Eur Arch Paediatr Dent* 2020;21(05):543–556. Doi: 10.1007/s40368-020-00547-5
- 49 RCSENG. 2018 Number of children aged 5 to 9 admitted to hospital due to tooth decay rises again. The Royal College of Surgeons of England. Accessed February 10, 2022 at: <https://www.rcseng.ac.uk/news-and-events/media-centre/press-releases/hospital-admission-tooth-decay/>
- 50 Tumba KJ, Twetman S, Splieth C, Parnell C, van Loveren C, Lygidakis NA. Guidelines on the use of fluoride for caries prevention in children: an updated EAPD policy document. *Eur Arch Paediatr Dent* 2019;20(06):507–516. Doi: 10.1007/s40368-019-00464-2
- 51 Kühnisch J, Ekstrand KR, Pretty I, et al. Best clinical practice guidance for management of early caries lesions in children and young adults: an EAPD policy document. *Eur Arch Paediatr Dent* 2016;17(01):3–12. Doi: 10.1007/s40368-015-0218-4
- 52 Bezerra DS, Stipp RN, Neves BG, Guedes SF, Nascimento MM, Rodrigues LK. Insights into the virulence traits of *Streptococcus mutans* in dentine carious lesions of children with early childhood caries. *Caries Res* 2016;50(03):279–287. Doi: 10.1159/000445256
- 53 Gruythuysen RJ, van Loveren C, Wiggelendam JM, van Boven JA, Burgersdijk RC. Neglect of oral care in children: a matter of integral approach (Dutch). *Ned Tijdschr Geneesk* 2015;159:A8071