



Pulmonary Abscess as a Complication of SARS-CoV-2 Pneumonia

Fatih Uzer¹ Sukriye Oner¹ Aykut Cilli¹

¹ Department of Pulmonology, Akdeniz University Faculty of Medicine, Antalya, Turkey

Address for correspondence: Fatih Uzer, MD, Department of Pulmonology, Faculty of Medicine, Akdeniz University, 07070, Antalya, Turkey (e-mail: uzerfatih@gmail.com).

Libyan Int Medical Univ J 2022;7:3–6.

Abstract

Severe acute respiratory syndrome coronavirus 2 (SARS-CoV-2) disease originated in the Wuhan region of China and spread all over the world. This disease typically starts as an acute viral disease, and it is characterized by lung infiltrates and elevation of inflammatory markers. The definitive diagnosis of the disease is confirmed by polymerase chain reaction (PCR) results. Although majority of patients with positive PCR results had mild disease, 5 to 14% of them are severely affected. It has been reported in the literature that a significant proportion of adult patients develops virus-related complications. Lung abscess is one of these complications that is a suppurative infection with an air-fluid level greater than 2 cm in diameter on chest X-ray. Although there is usually a single cavity, it can also be multifocal. It was reported as a possible late-term complication of SARS-CoV-2. We are presenting two cases with lung abscess after SARS-CoV-2 treatment.

Keywords

- SARS-CoV-2
- lung abscess
- pandemic

ملخص المقال باللغة العربية

خراج الرئوي كمضاعفات للالتهاب الرئوي نتيجة فيروس كورونا المستجد

المؤلفون: فاتح عزار، سكريّة أونير، أيكوت سيللي. قسم أمراض الرئة، كلية الطب بجامعة أكنديز، أنطاليا، تركيا.

المؤلف المشرف: فاتح عازر، بريد إلكتروني: fatihuzer@akdeniz.edu.tr

نشأ مرض السارس (فيروس الكورونا المستجد) في منطقة ووهان في الصين وانتشر في جميع أنحاء العالم. يبدأ المرض عادة كمرض فيروسي حاد، ويتسم بارتشاح رئوي وارتفاع علامات الالتهاب. يتم تأكيد التشخيص النهائي للمرض من خلال نتائج تفاعل البوليميراز المتسلسل (PCR). على الرغم من أن غالبية المرضى الذين لديهم نتائج إيجابية في تفاعل البوليميراز المتسلسل (PCR) يعانون من مرض خفيف، فإن 5-14% منهم يتأثرون بشدة من المرض. العديد من الأبحاث المنشورة أوردت أن نسبة كبيرة من المرضى البالغين يصابون بمضاعفات مرتبطة بالفيروس حيث يعد خراج الرئة أحد هذه المضاعفات، وهو عدوى قححية بمستوى سائل هواء يزيد قطره عن 2 سم في صورة الصدر بالأشعة السينية. عادة ما يكون هناك تجويف واحد، إلا أنه يمكن أن يكون متعدد البؤر أيضاً. كما أعتبر خراج الرئة أحد المضاعفات المتأخرة المحتملة لفيروس كورونا المستجد. في هذا البحث نقدم حالتين أصيبا بخراج الرئة بعد علاج فيروس كورونا المستجد.

الكلمات المفتاحية: فيروس كورونا المستجد، سارس-CoV-2، خراج الرئة، جائحة.

published online
May 16, 2022

DOI <https://doi.org/10.1055/s-0042-1744043>.
ISSN 2519-139X.

© 2022. Libyan International Medical University Journal. All rights reserved.

This is an open access article published by Thieme under the terms of the Creative Commons Attribution-NonDerivative-NonCommercial-License, permitting copying and reproduction so long as the original work is given appropriate credit. Contents may not be used for commercial purposes, or adapted, remixed, transformed or built upon. (<https://creativecommons.org/licenses/by-nc-nd/4.0/>)

Thieme Medical and Scientific Publishers Pvt. Ltd., A-12, 2nd Floor, Sector 2, Noida-201301 UP, India

Introduction

Severe acute respiratory syndrome coronavirus 2 (SARS-CoV-2; also called coronavirus disease 2019 [COVID-19]) disease was originated in the Wuhan region of China and spread all over the world. The World Health Organization declared the disease as pandemic in March 2020. This disease typically starts as an acute viral disease, and it is characterized by lung infiltrates and elevation of inflammatory markers. The definitive diagnosis of the disease is confirmed by polymerase chain reaction (PCR) results. Although majority of patients with positive PCR results had mild disease, 5 to 14% of them are severely affected.¹

It has been reported in the literature that a significant proportion of adult patients develops virus-related complications. These include thromboembolic events, arrhythmias, encephalopathy, pneumothorax, and lung abscess.^{2–5} Lung abscess is a suppurative infection with an air-fluid level greater than 2 cm in diameter on chest X-ray; although there is usually a single cavity, it can also be multifocal. It was reported as a possible late-term complication of SARS-CoV-2. We are presenting two cases with lung abscess after SARS-CoV-2 treatment, followed in our clinic.

Case 1

A 70-year-old male patient presented to the emergency department with the complaint of fatigue. In physical examination, his vital signs were as follows: blood pressure—120/70 mm/Hg, pulse rate—102/min, respiratory rate—24/min, temperature—36.9°C, fingertip saturation—94%. His past medical history was unremarkable. Patient had close contact with a known case of SARS-CoV-2 1 week ago. In his laboratory tests, hemoglobin was 12.7 g/dL, leukocyte count was 51,700/mm³, and C-reactive protein was 6.97 mg/dL. There was heterogeneous opacity in the left lower zone in posteroanterior (PA) chest X-ray and computed tomography (CT) showed subpleural ground-glass opacity in the bilateral lower lobes. PCR test for SARS-CoV-2 was positive. Patient was hospitalized with SARS-CoV-2 diagnosis. Hydroxychloroquine (200 mg, twice a day [BID]) and favipiravir (1,600 mg

loading dose BID on day 1, followed by 600 mg BID maintenance dose for 4 days) were administered to the patient. On the third day of his hospitalization, PA chest X-ray was repeated due to worsening in shortness of breath and having a respiratory rate of 40/min. In chest X-ray, there was bilateral heterogeneous opacity. His fingertip saturation was 85%. He was intubated and transferred to intensive care unit (ICU). Piperacillin–tazobactam (4,500 mg three times daily [TID]) was added to the treatment regime. On his eighth day of ICU hospitalization, tracheostomy was performed. On his tracheal aspiration cultures taken during ICU stay, *Acinetobacter baumannii*, *Pseudomonas aeruginosa*, and *Escherichia coli* growth was detected. According to this culture results, meropenem (1,000 mg TID) was added to the treatment regime. On the fourth day of meropenem regime, he had a high-resolution computed tomography (HRCT) of chest due to fever of 38.5°C. In HRCT, a thick-walled cavitary lesion with air-fluid leveling was seen in the upper lobe of the right lung, measuring 72 × 85 × 75 mm. Vancomycin (500 mg four times daily) and ceftazidime (2,000 mg TID) were added to the patient's treatment with the diagnosis of lung abscess. The patient's complaints regressed significantly, and the treatment for lung abscess was continued for 6 weeks in total. Abscess was seen to be regressed significantly in thorax CT performed 6 months after discharge (→ Fig. 1).

Case 2

A 62-year-old male patient presented with complaints of cough and sputum. In his physical examination, blood pressure was 143/84 mm Hg, pulse rate was 111/min, respiratory rate was 20/min, and fever was 37.0°C. Besides having hypertension, his past medical history was unremarkable. The patient was in contact with a person diagnosed with SARS-CoV-2 3 days ago. In his laboratory tests, hemoglobin was 13.1 g/dL, leukocyte count was 10,240/mm³, and C-reactive protein was 1.71 mg/dL. Bilateral heterogeneous opacities were observed in PA chest radiogram. On thorax CT patchy ground-glass areas dominantly located subpleurally in both lungs were seen, which were more prominent in the middle and lower zones. PCR test for SARS-CoV-2 was

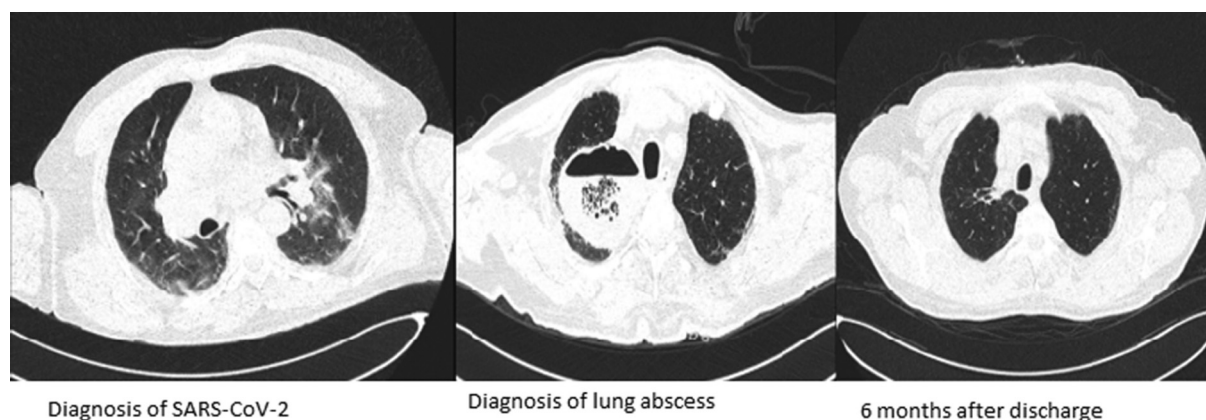


Fig. 1 Radiological images of case 1, chronologically. SARS-CoV-2, severe acute respiratory syndrome coronavirus 2.

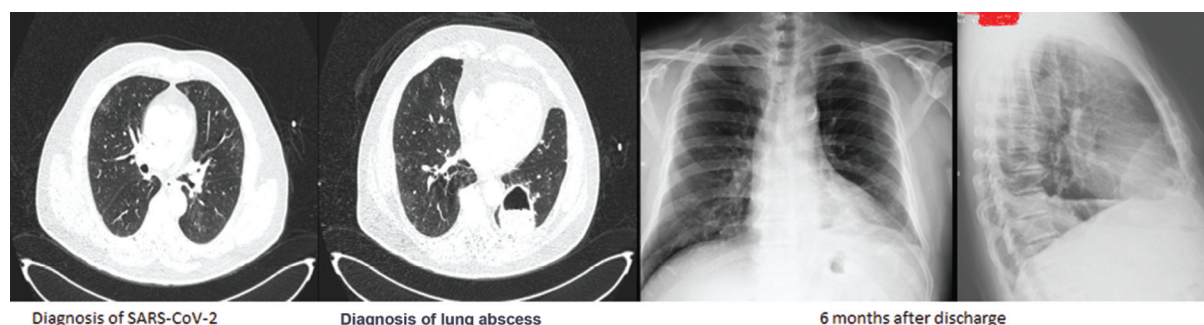


Fig. 2 Radiological images of case 2, chronologically. SARS-CoV-2, severe acute respiratory syndrome coronavirus 2.

positive. The patient was hospitalized with the diagnosis of SARS-CoV-2. The patient was started on favipiravir with loading dose of 1,600 mg BID for the first day, followed by maintenance therapy of 600 mg BID. While his treatment was ongoing, he had a fever of 38.7°C and thorax imaging were repeated. In radiogram and thorax CT, a lung abscess was detected. Piperacillin–tazobactam (4,500 mg TID) and clarithromycin (500 mg BID) were started empirically in the patient who had no microbial growth in blood, urine, and sputum cultures. On the third day of antibiotic treatment, clinical and laboratory improvement was observed, and the treatment for abscess was continued for 6 weeks in total. The abscess was seen to be regressed in the chest X-ray taken at 6 months after discharge (► Fig. 2).

Discussion

SARS-CoV-2 is an important infectious disease affecting the world, which can progress with various complications. Vigorous efforts are being made by politicians and scientists to end this pandemic. Doctors are dealing with SARS-CoV-2-related complications while trying to keep the patient from respiratory failure, which can be fatal. One of these complications is lung abscess. The cases with lung abscess in our clinic, which occurred in the early period after SARS-CoV-2, did not have any significant risk factors, except that they were male and diagnosed with SARS-CoV-2.

Lung abscess is a pulmonary infection that forms a cavity in the lung parenchyma and creates an air-fluid level in the cavity after bronchopulmonary fistula formation.⁶ Lung abscess can occur due to aspiration of oropharyngeal secretions, secondary to parenchymal lung diseases, bronchial obstruction, and hematogenous spread from extrapulmonary sites. Factors facilitating abscess formation in the lung could be advanced age, alcoholism, diabetes mellitus, immunosuppression, poor oral hygiene, mental retardation, and coma. One of our patients had a history of intubation due to SARS-CoV-2, and other patient did not have a risk factor other than SARS-CoV-2 that could cause an abscess.

SARS-CoV-2 pandemic is a relatively novel disease. As time passes, the early and late-term complications of the disease will be revealed in more detail. In literature, abscess after SARS-CoV-2 was defined in a few case reports. In the

case reported by Renaud-Picard et al,⁷ a lung abscess developed after SARS-CoV-2 treatment in an obese female patient who was intubated due to SARS-CoV-2. The authors reported that intubation facilitated the development of this abscess after SARS-CoV-2 treatment. One of our cases also had a history of intubation.

The etiology of lung abscess is polybacterial in 90% of the cases.⁶ However, bacteria cannot always be isolated for various reasons. Muheim et al⁸ reported that no bacteria could be isolated in patients who developed lung abscess after SARS-CoV-2 pneumonia and the treatment was empirical. In one of our cases, bacterial growths such as “*Acinetobacter baumannii*, *Pseudomonas aeruginosa*, and *Escherichia coli*” were detected in the sputum culture and appropriate antibiotics were given. In our other case, no bacterial growth was detected and the treatment was empirical. Both of our cases received antibiotic regime for recommended duration and benefited from the treatment.

To conclude, SARS-CoV-2 is a disease with high mortality and morbidity, and lung imaging can be repeated in patients whose complaints do not regress despite appropriate treatment during their clinical follow-up. In patients with lung abscess, broad-spectrum antibiotic therapy can be started without hesitation.

Conflict of Interest
None declared.

References

- Wu Z, McGoogan JM. Characteristics of and important lessons from the coronavirus disease 2019 (COVID-19) outbreak in China: summary of a report of 72 314 cases from the Chinese Center for Disease Control and Prevention. *JAMA* 2020;323(13):1239–1242
- Filatov A, Sharma P, Hindi F, Espinosa PS. Neurological complications of coronavirus disease (COVID-19): encephalopathy. *Cureus* 2020;12(03):e7352
- Kochi AN, Tagliari AP, Forleo GB, Fassini GM, Tondo C. Cardiac and arrhythmic complications in patients with COVID-19. *J Cardiovasc Electrophysiol* 2020;31(05):1003–1008
- McAteer R. Case Report: SARS-COV-2 Pneumonia Complicated by Lung Abscess [Internet]. Medium 2020 [a.yer 09 Aralık 2020]. Available at: <https://medium.com/case-notes-from-the-SARS-CoV-2-front-lines/case-report-SARS-CoV-2-pneumonia-complicated-by-lung-abscess-96d3f4f9ff01>. Accessed February 3, 2022

- 5 Adams ML, Katz DL, Grandpre J. Population-based estimates of chronic conditions affecting risk for complications from coronavirus disease, United States. *Emerg Infect Dis* 2020;26(08):1831–1833
- 6 Kuhajda I, Zarogoulidis K, Tsirgogianni K, et al. Lung abscess- etiology, diagnostic and treatment options. *Ann Transl Med* 2015; 3(13):183
- 7 Renaud-Picard B, Gallais F, Riou M, Zouzou A, Porzio M, Kessler R. Delayed pulmonary abscess following COVID-19 pneumonia: a case report. *Respir Med Res* 2020;78:100776
- 8 Muheim M, Weber FJ, Muggensturm P, Seiler E. An unusual course of disease in two patients with COVID-19: pulmonary cavitation. *BMJ Case Rep* 2020;13(09):e237967