













# Multiple Medullary Schwannoma Associated with Lumbar Disc Herniation and Cauda Equina Syndrome: Case Report

## *Schwannoma medular múltiplo associado a hérnia de disco lombar e síndrome da cauda equina: Relato de caso*

Anibal Rodrigues Neto<sup>1</sup>  Bianca Bicalho<sup>2</sup>  Giovanna Maria Varandas<sup>2</sup>  Adriano Torres Antonucci<sup>1</sup>   
Gabriel Gomes Freitas de Castro<sup>1</sup>  Shiro Manoel Shimoakoishi de Arruda<sup>1</sup>  Marcel Schiavini<sup>1</sup>   
Lutero Cleuler Moraes dos Santos<sup>1</sup>  Márcio Francisco Lehmann<sup>1</sup>  Francisco Spessatto Pesente<sup>1</sup> 

<sup>1</sup>Department of Clinical Surgery – Neurosurgery, Universidade Estadual de Londrina, Londrina, PR, Brazil

<sup>2</sup>Medicine Program, Pontifícia Universidade Católica do Paraná, PR, Brazil

Address for correspondence Anibal Rodrigues Neto, M.D., Department of Clinical Surgery – Neurosurgery, Universidade Estadual de Londrina, Londrina, PR, Brazil (e-mail: anibalneto.r@gmail.com).

Arq Bras Neurocir 2024;43(2):e117–e120.

### Abstract

**Introduction** Schwannoma is a Schwann cells neoplasm that can occur in various parts of the nervous system, including the medullar region of the cauda equina. Bone involvement is uncommon.

**Objective** To report a multiple schwannoma case that was initially diagnosed as cauda equina syndrome.

**Clinical Case** We report the case of a 44-year-old male who presented with pain irradiating to the lower limbs, urinary retention, and saddle paresthesia. Imaging exams revealed tumors in the cervical spine and in the T12/L1, L2/L3, and L3/L4 levels, the last three causing nervous compression. Histopathological analyses confirmed a Schwannoma pattern.

**Results** The case was solved by surgical resection.

**Conclusion** The case was solved and, in the end, the patient was stable and with improved pain and waits for a cervical surgery.

### Keywords

- ▶ schwannoma
- ▶ neoplasm
- ▶ lombalgia

### Resumo

**Introdução** Schwannoma é uma neoplasia de células de Schwann que pode ocorrer em diversas partes do sistema nervoso, incluindo a região medular da cauda equina. O acometimento ósseo é incomum.

**Objetivo** Relatar um caso de schwannoma múltiplo que foi diagnosticado inicialmente como síndrome da cauda equina.

**Relato de caso** Relatamos o caso de um paciente masculino de 44 anos que apresentou quadro algico com irradiação para os membros inferiores, retenção urinária

### Palavras-chave

- ▶ schwannoma
- ▶ neoplasia
- ▶ lombalgia

received  
September 16, 2021  
accepted  
January 18, 2022  
article published online  
October 10, 2023

DOI <https://doi.org/10.1055/s-0042-1744111>.  
ISSN 0103-5355.

© 2023. Sociedade Brasileira de Neurocirurgia. All rights reserved. This is an open access article published by Thieme under the terms of the Creative Commons Attribution-NonDerivative-NonCommercial-License, permitting copying and reproduction so long as the original work is given appropriate credit. Contents may not be used for commercial purposes, or adapted, remixed, transformed or built upon. (<https://creativecommons.org/licenses/by-nc-nd/4.0/>)  
Thieme Revinter Publicações Ltda., Rua do Matoso 170, Rio de Janeiro, RJ, CEP 20270-135, Brazil

e parestesia em cela. Exames de imagem revelaram tumores na cervical e em níveis de T12/L1, L2/L3 e L3/L4, com os três últimos causando compressão nervosa. A análise histopatológica comprovou padrão de schwannoma.

**Resultados** A correção do quadro se deu através da ressecção cirúrgica.

**Conclusão** O quadro foi resolvido com o paciente apresentando-se estável e com melhora do quadro algíco. O paciente aguarda cirurgia a nível cervical.

## Introduction

Schwannoma, also known as neurilemoma or neurinoma,<sup>1,2</sup> is a neoplasm that occurs in Schwann cells, which are responsible by the formation of the myelin sheath of the peripheral nerves. In most cases, schwannomas are benign,<sup>3</sup> affect more women than men,<sup>4</sup> and are more frequently seen in the 40<sup>th</sup> and 50<sup>th</sup> decades of life. Its incidence is of 0.5 per 100.000 individuals per year.<sup>3</sup> Their most common location is the vestibulocochlear nerve (NC VIII), but they can also affect other nerves.<sup>5</sup> Multiple schwannomas are usually be associated with neurofibromatosis (type I or II) or with schwannomatosis,<sup>3</sup> which are rare conditions. The clinical manifestations are late, due to their slow growth, and occur due to neurological compression.<sup>6</sup>

The aim of the present article is reporting a multiple schwannoma case that was initially diagnosed as cauda equina syndrome.

## Material and Methods

Information was collected from medical records, patient interview, the diagnostic methods to which the patient was submitted, surgical findings, and a literature review.

## Case Report

Patient, C.L., male, 44 years old, white, bricklayer, presented to the hospital due to a 2-month-long backache.

The backache irradiated to the lower limbs and was associated with urinary retention, saddle paresthesia, reduced sensitivity, and paraparesis. At the first evaluation, a diagnosis of cauda equina syndrome was made. Magnetic Resonance (MRI) (►Fig. 1 and ►Fig. 2) demonstrated lesions corresponding to C6/C7, T12/L1, L2/L3, and L3/L4 discal herniation. The patient was referred to urgent surgical medullar decompression (L3-L4 laminectomy). During the intraoperative evaluation, the lesion was suggestive of tumoral etiology. The collected tissue was sent to biopsy. The pathological report confirmed an intradural lesion with a suggestive Schwannoma pattern. A subsequent magnetic resonance imaging (MRI) exam showed that the discal herniation was associated with intradural tumoral lesions.

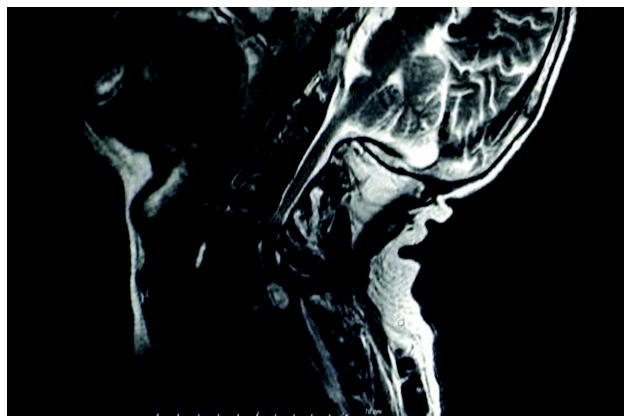
A subsequent surgical approach was made to resect the T12/L1 and L2/L3 lesions and revise the L3/L4. level After the surgery, the patient presented pain improvement.

Currently, the patient is stable, walking normally, without new deficits and with normal neurological examination. The cervical schwannoma is under strict monitoring for the best moment for surgery.

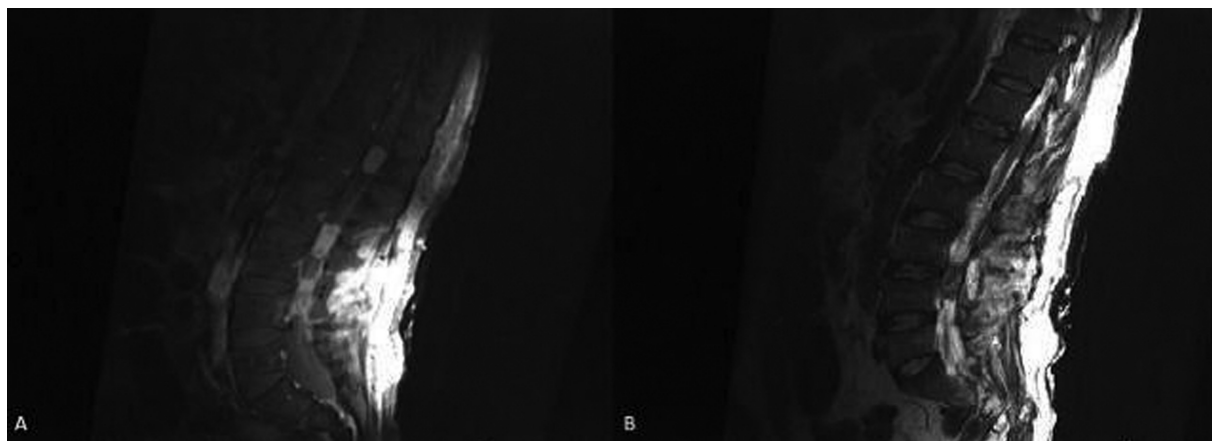
## Discussion

Schwannoma is a benign tumor of the nervous sheath<sup>3</sup> that usually appears isolated, but it can also occur more rarely in multiple form with slow growth,<sup>7</sup> with consequent delay to present symptoms,<sup>6</sup> which happens when it reaches 4 cm in size.<sup>8</sup> The classic symptom is pain, which worsens at night,<sup>9</sup> associated with paresthesia due to compression of sensitive roots.<sup>10</sup> Moreover, the patient can also present with other sensitive and motor changes.<sup>7</sup>

Usually, the roots of the back are the most affected location. Generally, the tumors are intradural,<sup>10</sup> extramedullary (~99%), and most are found in the cervical and lumbar regions. In computed tomography (CT), schwannomas are not distinguishable from neurofibromatosis or discal herniation. However, in MRI, schwannoma have characteristic signs, which are hypointensity in T1, intense improvement in T1+C, and heterogeneous hyperintensity in T2; generally, large tumors appear with hemosiderin areas in T2 sequences.<sup>11</sup> Normally, schwannomas appear as solid, well-defined rounded lesions<sup>10</sup> and are frequently associated with bone remodeling.<sup>11</sup> As they grow, they can extend to several levels of the spine or protrude to the neural foramen. Macroscopically, these tumors are encapsulated and arise eccentrically to the nerve, with nerve fibers along their surface.



**Fig.1** C7 tumor showed in MRI T2-weighted.



**Fig. 2** . Massas em T12/L1, L2/L3 e L3/L4 reveladas por ressonância magnética (A, B).

Histopathological analyses enable confirmation of the diagnosis through fusiform cells, which can be type Antoni A or Antoni B. The pattern Antoni A consists of elongated cells that are thickly involved and organized into fascicles, and alternating palisades with Verocay bodies can occur. Type Antoni B is less compact and tends to cystic degeneration.<sup>12</sup>

Among the differential diagnoses, the most common are neurofibromatosis type 2 (NF2) and neurofibromatosis type 1 (NF1). Neurofibromatosis type 2 is an autosomal dominant disease, progressive and rare,<sup>13</sup> that usually affects the vestibular nerves and originates cranial and multiple spinal tumors.<sup>14</sup> The schwannoma phenotype is very similar to NF2; nevertheless, the former has a good prognosis and the latter does not. Therefore, differentiation between these tumors is necessary in order to determine the right treatment.<sup>15</sup> Neurofibromatosis type 1 is also an autosomal dominant neurocutaneous disorder linked to the formation of benign and malignant tumors; however, it has a different phenotype from NF2. Neurofibromatosis type 1 can present coffee latte stains, neurofibromas in any type, axillary and inguinal freckles, optical nerve glioma, Lisch nodules (pigmented iris hamartomas), typical bone disease lesions, such as small wing sphenoidal dysplasia, thinning of the cortex of long bones with or without pseudarthrosis, and family history.<sup>14</sup> Neurofibromatosis type 1 is linked to the *NF1* gene, which is located in the long arm of chromosome 17 (17q12).<sup>10</sup>

Schwannoma can also be confused with disc herniation. Both can lead to neurological compression, originating the symptoms.<sup>16</sup> The most common locations for herniation are the C6/C7 level in the cervical spine, the L4/L5, and L5/S1 levels in the lumbar spine.<sup>17</sup> The latter causes cauda equina syndrome,<sup>18</sup> just as a medullary tumor in this region would.<sup>19</sup>

Disc protrusion is more common than schwannomas, being the disease that most leads to spinal surgery today. It occurs more in males in the 40<sup>th</sup> decade of life.<sup>20</sup>

The first line of treatment for schwannomas is surgical. Since the tumor does not infiltrate the originating nerve, it can be totally separated, without nerve lesion.<sup>12</sup>

## Conclusion

Spinal schwannoma is a rare neoplasm with unspecific clinical presentation for which the most used imaging exam is MRI. Confirmation of the diagnosis is obtained by histological and immunohistochemical studies. The treatment is surgical and its aim is complete resection. Incomplete resection can lead to future recurrence.<sup>3</sup> The present case report describes a rare concomitant lumbar and cervical multiple schwannoma associated with symptoms of cauda equina syndrome. Surgical approach for the resection of lumbar schwannoma with arthrodesis leads the patient to improvement of symptoms.

## Ethics Statement

In the present case report, neither the patient nor any of his data have been identified.

## Conflict of Interests

The authors have no conflict of interests to declare.

## References

- 1 Safavi-Abbasi S, Senoglu M, Theodore N, et al. Microsurgical management of spinal schwannomas: evaluation of 128 cases. *J Neurosurg Spine* 2008;9(01):40–47
- 2 Kim P, Ebersold MJ, Onofrio BM, Quast LM. Surgery of spinal nerve schwannoma. Risk of neurological deficit after resection of involved root. *J Neurosurg* 1989;71(06):810–814
- 3 Conti P, Pansini G, Mouchaty H, Capuano C, Conti R. Spinal neurinomas: retrospective analysis and long-term outcome of 179 consecutively operated cases and review of the literature. *Surg Neurol* 2004;61(01):34–43, discussion 44
- 4 Friedman AH, Kline DG, Kim DH, Kitagawa RS. Benign tumors of the peripheral nerve. In: Youmans Neurological Surgery. 6th ed Philadelphia, PA: Elsevier Saunders; 2011:2518–2521
- 5 Wostrack M, Shiban E, Obermueller T, Gempt J, Meyer B, Ringel F. Conus medullaris and cauda equina tumors: clinical presentation, prognosis, and outcome after surgical treatment: clinical article. *J Neurosurg Spine* 2014;20(03):335–343
- 6 Jung KW, Park KH, Ha J, Lee SH, Won YJ, Yoo H. Incidence of primary spinal cord, spinal meninges, and cauda equina tumors in Korea, 2006–2010. *Cancer Res Treat* 2015;47(02):166–172

- 7 Engelhard HH, Villano JL, Porter KR, et al. Clinical presentation, histology, and treatment in 430 patients with primary tumors of the spinal cord, spinal meninges, or cauda equina. *J Neurosurg Spine* 2010;13(01):67–77. Doi: 10.3171/2010.3.SPINE09430
- 8 Thakkar SD, Feigen U, Mautner VF. Spinal tumours in neurofibromatosis type 1: an MRI study of frequency, multiplicity and variety. *Neuroradiology* 1999;41(09):625–629
- 9 Iizuka Y, Iizuka H, Kobayashi R, Mieda T, Takagishi K. Giant schwannoma with extensive scalloping of the lumbar vertebral body treated with one-stage posterior surgery: a case report. *J Med Case Reports* 2014;8:421
- 10 Anatomia e Patologia U. Schwannoma, Neurofibroma, Neurofibromatose. acessado em 14.03 em <http://anatpat.unicamp.br/taneuschwannoma.html>2012
- 11 Baranović M, Macan D, Begović EA, Luksic I, Brajdić D, Manojlović S. Schwannoma with secondary erosion of mandible: case report with a review of the literature. *Dentomaxillofac Radiol* 2006;35(06):456–460
- 12 Evans DG, Huson SM, Donnai D, et al. A genetic study of type 2 neurofibromatosis in the United Kingdom. I. Prevalence, mutation rate, fitness, and confirmation of maternal transmission effect on severity. *J Med Genet* 1992;29:841–846
- 13 Aboukais R, Zairi F, Bonne NX, et al. Causes of mortality in neurofibromatosis type 2. *Br J Neurosurg* 2014;25:1–4
- 14 Ferner RE, Gutmann DH. Neurofibromatosis type 1 (NF1): diagnosis and management. *Handb Clin Neurol* 2013;115:939–955
- 15 Koontz NA, Wiens AL, Agarwal A, Hingtgen CM, Emerson RE, Mosier KM. Schwannomatosis: the overlooked neurofibromatosis? *AJR Am J Roentgenol* 2013;200(06):W646–53
- 16 Caputo LA, Cusimano MD. Schwannoma of the cauda equina. *J Manipulative Physiol Ther* 1997;20(02):124–129
- 17 Santos M. Hérnia de Disco: uma revisão clínica, fisiológica e preventiva. *Revista digital Buenos Aires*. 2003:65
- 18 Gardner A, Gardner E, Morley T. Cauda equina syndrome: a review of the current clinical and medico-legal position. *Eur Spine J* 2011;20(05):690–697
- 19 Harrop JS, Hunt GE Jr, Vaccaro AR. Conus medullaris and cauda equina syndrome as a result of traumatic injuries: management principles. *Neurosurg Focus* 2004;16(06):e4
- 20 Spangfort EV. The lumbar disc herniation. A computer-aided analysis of 2,504 operations. *Acta Orthop Scand Suppl* 1972;142:1–95