



# Novel Copy Denture Technique—A Practical Approach for Duplicating Existing Dentures

Mehwish Khan<sup>1</sup> Syed Murtaza Raza Kazmi<sup>2</sup> Sameer Quraeshi<sup>3</sup> Shah wazir<sup>3</sup>

<sup>1</sup>Department of Prosthodontics, Sindh Institute of Oral Health Sciences, Jinnah Sindh Medical University, Karachi, Pakistan

<sup>2</sup>Department of Prosthodontics, Aga Khan University Hospital, Karachi, Pakistan

<sup>3</sup>Department of Prosthodontics, Fatima Jinnah Dental College and Hospital, Karachi, Pakistan

Address for correspondence Mehwish Khan, BDS, FCPS, Department of Prosthodontics, Sindh Institute of Oral Health Sciences, Jinnah Sindh Medical University, Karachi, 75510, Pakistan (e-mail: Khan.mehwish@jsmu.edu.pk).

Eur J Gen Dent 2022;11:132–136.

## Abstract

### Keywords

- copy denture
- duplicate denture
- denture copy technique

Provision of copy dentures to complete denture patients is often needed in clinical practice. Several edentulous patients want an additional set of dentures to avoid being without them in case the existing ones are broken or lost, whereas some patients have adapted to their old dentures so much that they do not want them to be replaced by a completely new prosthesis. This article presents a technique for the fabrication of a copy denture that allows duplicate dentures to be processed in heat-cure acrylic resin in two clinical visits, without leaving the dentures at dental office.

## Introduction

The management of the complete denture patients can be a challenging experience for a dentist.<sup>1</sup> Adaptation to a new prosthesis is a continuous struggle for the frail and older patients who are accustomed to their existing dentures.<sup>2</sup> Several edentulous patients are anxious about being without the dentures in case the existing ones are broken or lost and concerned about being without them during the repair process,<sup>3</sup> whereas some patients have adapted to their old dentures so much that they do not want them to be replaced by a completely new prosthesis. These patients are best managed by making a replica or duplicate denture with minimum alteration in the new dentures. The main purpose of the replica or copy denture is to duplicate the existing denture's polished surface with minimal changes, sometimes also improving the impression surface of the denture.<sup>4</sup> Copy denture is often needed by the patient who is completely satisfied with the existing prosthesis and only want a spare set of denture, in case of unrepairable fracture of the otherwise satisfactory denture, or occasionally when the patient wants to change the color of denture base or artificial teeth. It is not indicated when the existing denture

has major deficiencies in occlusal or impression surface. Several procedures for duplicating dentures have been described in the literature.<sup>1,3–8</sup> Some have used alginate,<sup>1,3</sup> whereas some authors have utilized silicone-based impression materials<sup>4,5</sup> and some recommend using a combination of both materials<sup>8</sup> for the procedure. Almost all of them involve preparing a mold of the present denture and creating a replica in wax or auto-polymerizing acrylic resin. Most of them require at least three to four visits of the patient to the dental office. This article presents a technique for the fabrication of a copy denture that does not necessitate the patient to leave the dentures with the practitioner and dentures are made in heat-processed acrylic resin without any additional clinical appointment. Additionally, in cases where the exact mold of the artificial teeth in the existing prosthesis is not known, a proposed technique for duplicating the teeth has also been described.

## Case Presentation

A 60-year-old male, complete denture patient referred to the Department of Prosthodontics, in a Private Dental Teaching

published online  
April 6, 2022

DOI <https://doi.org/10.1055/s-0042-1744206>.  
ISSN 2320-4753.

© 2022. The Author(s).

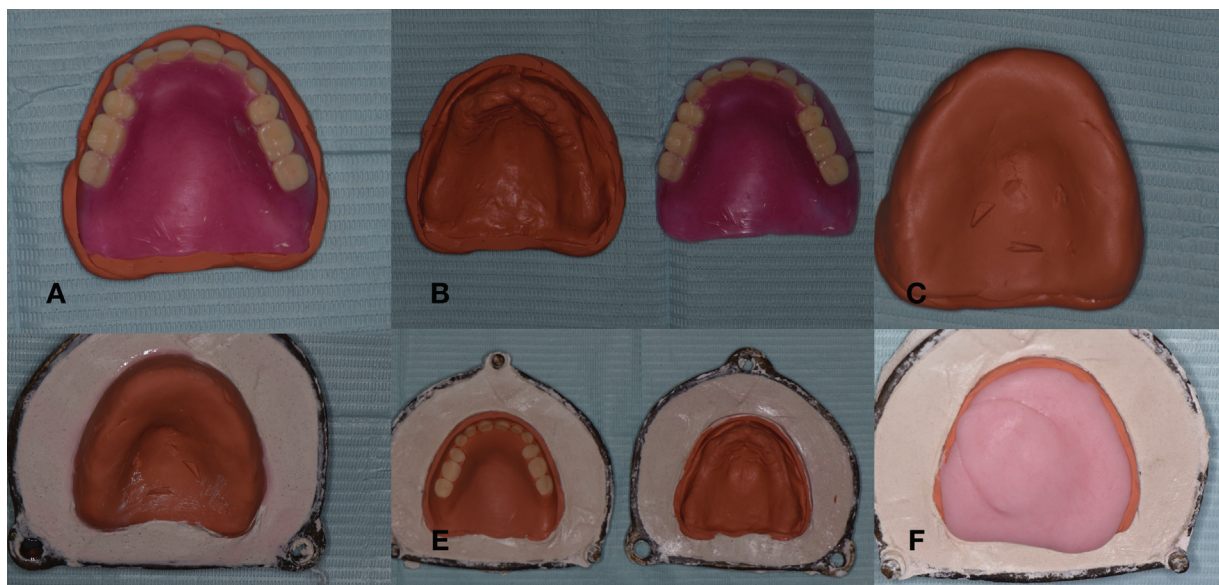
This is an open access article published by Thieme under the terms of the Creative Commons Attribution License, permitting unrestricted use, distribution, and reproduction so long as the original work is properly cited. (<https://creativecommons.org/licenses/by/4.0/>)

Thieme Medical and Scientific Publishers Pvt. Ltd., A-12, 2nd Floor, Sector 2, Noida-201301 UP, India

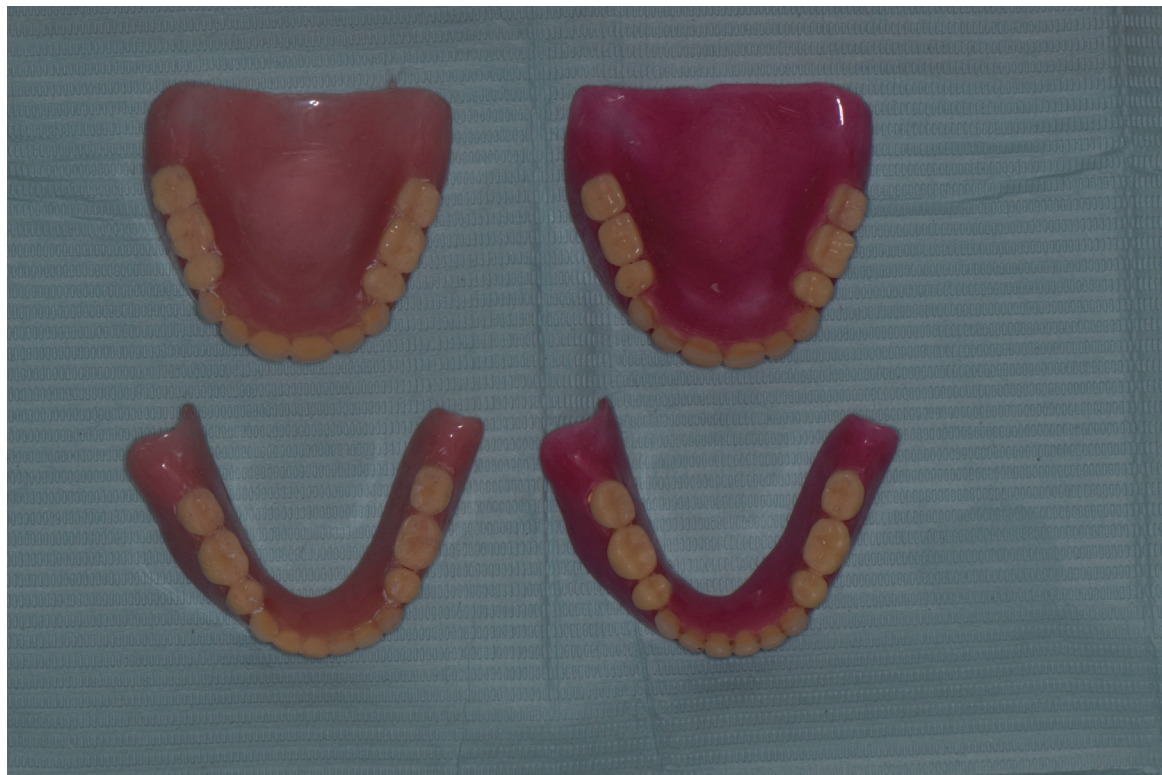Hospital, Karachi, Pakistan. He had a set of complete dentures made 2 months ago in the same hospital with which he was satisfied. He was traveling out of the country within a week and wanted to get a duplicate of his existing dentures, which he could use in case the existing one is lost or broken. The patient was fit medically. On intra-oral examination, well-formed edentulous maxillary and mandibular ridges were found. The patient's existing dentures were esthetically and functionally satisfactory and exhibited adequate vertical dimension of occlusion, retention, and stability. However, the patient expressed his concerns over the dark color of denture base and teeth and preferred a lighter color in the duplicate one. Other treatment options given to the patient were conventional complete denture, implant-supported overdenture, and implant-supported fixed prosthesis but the patient preferred a copy denture due to time constraint. As medical history of the patient was not contributory and no surgical procedure was planned, fabrication of copy denture was proceeded without further investigations.

### Procedure

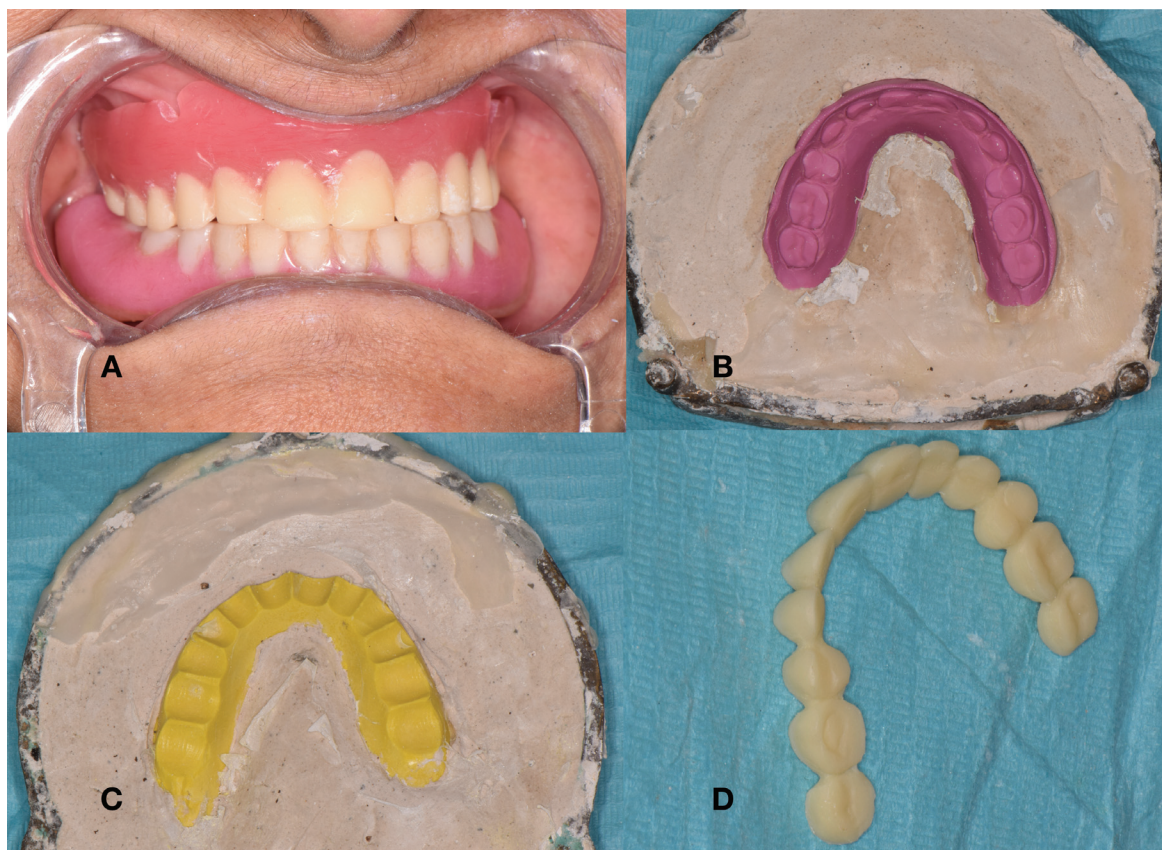
- The patient's dentures were taken and cleaned by using a denture cleansing solution. The fitting surface of the denture was filled with polyvinyl siloxane (PVS) impression material of putty consistency (3M ESPE Express STD), covering 2 mm of the peripheral borders of the denture (►Fig. 1A–B). Petroleum jelly was applied as separating media over the borders, and PVS impression material was adapted over the polished and occlusal surface of the denture smoothly joining the impression of fitting surface (►Fig. 1C). Dentures were retrieved from the impressions, and molds of polished and fitting surfaces were inspected for any defects which can be filled with light body PVS impression material (3M ESPE Express Light Body). Siloxane putty mold with the denture in place was flaked in the usual manner using dental plaster (Gypsum) type II (►Fig. 1D). After setting of the dental plaster, the denture was retrieved, cleaned, and returned to the patient. Shade and mold of the teeth to be used was carefully chosen using a commercially available acrylic shade guide (HI-I VITACRILIC), before returning the dentures to the patient. The existing denture had shade no. 3, whereas lighter shade no.1 was selected for copy denture teeth due to the patient's preference.
- This technique requires approximately 45 minutes of clinical time. Since the PVS impression material has long-term dimensional stability, the process of duplication can be completed later at a suitable time. Selected teeth were then placed into the mold formed by the polished and occlusal surface of the denture after minor adjustments in the ridge lap. Teeth were stabilized in position using super glue (►Fig. 1E) Dentures were then processed using heat-cure acrylic resin by a compression-molding technique (dough technique) (►Fig. 1F). To minimize processing errors, acrylic polymer and monomer were mixed in the proper ratio of 3:1 by volume and processed at 74°C for approximately 2 hours followed by boiling at 100°C for 1 hour.<sup>8</sup> After finishing and polishing, the dentures were inserted with minor occlusal adjustments (►Fig. 2).
- Initial follow-up visit was done after 24 hours and then after 6-months. Other than a few occlusal adjustments, the patient was satisfied with the copy denture. For cases where the exact mold of teeth used in the original denture is unknown or existing denture has teeth that exhibit considerable wear, then the teeth can be custom made in self-cure acrylic resin (►Fig. 3A–D). A separate mold for teeth was formed by taking the PVS impression of only the occlusal surface of the existing denture and poured in die



**Fig. 1** Steps in denture duplication. (A) Impression of the tissue surface of the denture. (B) Check the impression for defects. (C) Impression of the polished surface of denture. (D) Impression flaked with denture in place. (E) Denture retrieved and teeth placed in mold. (F) Packing of mold with heat cure acrylic resin.



**Fig. 2** Comparison of patient's existing dentures (on right) with copy dentures (on left).



**Fig. 3** Custom-made teeth with auto-polymerizing acrylic resin. (A) Maxillary copy denture fabricated using custom-made teeth opposing mandibular original denture. (B) Siloxane putty impression of the teeth in the flask. (C) Teeth ground off from dental stone. (D) Cured and finished custom-made teeth strip.

stone. This was then flaked in the usual manner using a dental plater (→Fig. 3B–C). On separation of the two halves of the flask, teeth were ground off on the die stone model (→Fig. 3C). Self-cure acrylic resin (tempron) was used to fill the putty mold, and the flask was closed and allowed to bench cure under pressure. Teeth strip was retrieved from the flask and finished with appropriate gingival contours (→Fig. 3D). This teeth strip can then be used for copy denture using above-mentioned technique (→Fig. 3A).

## Discussion

An inadequate prosthesis may be used by a patient for a long period because it is comfortable and a patient has developed muscular skills to control it. To get accustomed to a new prosthesis, a different learning sequence is required. Therefore, the practitioner must identify the patients who are reluctant to learn new skills and will have difficulty adapting to the new prosthesis.<sup>9,10</sup> Lindquist and Ettinger<sup>5</sup> used addition silicone impression material for replication of polished and tissue surfaces of the existing denture and fabricated record bases of auto-polymerizing resin from the silicone impression for the subsequent denture-making procedure. A somewhat similar technique was described by Habib and Vohra<sup>1</sup> except that they used irreversible hydrocolloid impression material in place of silicone. Both of these techniques required at least four clinical appointments of the patient with increased laboratory time and cost. Mohamed and Faraj<sup>11</sup> described a technique which utilizes the dental stone to replicate the denture which is associated with increased chances of fracture of the existing denture and the mold itself, whereas Nassif and Jumbelic<sup>3</sup> advocated the use of irreversible hydrocolloid molds of the existing denture followed by denture fabrication using auto-polymerizing acrylic resin. On contrary to the above-mentioned techniques, the technique described in this case report to duplicate a denture is easy and requires reduced chair-side and laboratory time. Greater patient satisfaction is achieved as the patient does not need to leave the denture during the duplication process. Use of face-bow or jaw record appointment and denture trial are not required. Furthermore, the use of PVS impression material makes this technique preferable for situations with undercuts; furthermore, dental stone used for flasking provides a rigid support to silicone putty mold minimizing errors during packing and curing. One limitation of this technique is that it does not allow modifications/corrections in jaw relation, occlusal vertical dimension, or fitting surface of the denture. However, if improvements in denture retention and support are required, reline procedure may be done once the patient has worn the copy denture satisfactorily. And if slight changes in the impression or fitting surface of the denture are required, this technique can be modified by taking PVS impression of the edentulous ridges with the dentures by closed-mouth technique before investing them in the flask.

The technique presented provides a time-efficient solution for a patient needing a spare set of denture ensuring greater patient satisfaction when the mold of teeth is known. It also describes modification when the exact mold of teeth cannot be found. However, such self-cure acrylic resin custom-made teeth are prone to staining and have low wear resistance. The use of other materials with improved properties is suggested for better esthetic results in this technique. Some of the newer materials for denture teeth include multiplex polymer matrix resin teeth, resin teeth containing an IPN of polymers, double crosslinked resins, and nano-filled composite resin teeth.<sup>8</sup> The use of optical scanner and a 3D printer for copying complete dentures has been described recently.<sup>12</sup> Digital imaging provides a quick procedure with minimal errors, little waste of material, and lesser chair-side time.<sup>12,13</sup> But the increased cost of the system and lack of training have limited the practice of digital techniques for duplicating dentures. However, with enhancements in the digital techniques, they may replace the conventional techniques in near future.

## Conclusion

The technique described offers a time-efficient and easy method for the fabrication of copy denture in a patient who needs a spare set of denture providing a satisfactory solution for the treatment of elderly patients who cannot tolerate long appointments and are accustomed to their existing prosthesis.

### Conflict of Interest

None declared.

## References

- 1 Habib SR, Vohra FA. Replacing existing dentures by copy-denture technique for geriatric patients: a case report. *JDA* 2013;22(04): 265
- 2 Lindquist TJ, Narhi TO, Ettinger RL. Denture duplication technique with alternative materials. *J Prosthet Dent* 1997;77(01):97–98
- 3 Nassif J, Jumbelic R. Duplicating maxillary complete dentures. *J Prosthet Dent* 1984;52(05):755–759
- 4 McCord JF, Hannah VE, Cameron D, Watson D, Donaldson AC. An update on the replica denture technique. *Dent Update* 2010;37(04):230–232, 235
- 5 Lindquist TJ, Ettinger RL. Patient management and decision making in complete denture fabrication using a duplicate denture procedure: a clinical report. *J Prosthet Dent* 1999;82(05):499–503
- 6 Ghani F. The provision of new complete dentures by duplicating the existing plates. Report of a case. *Pak Oral Dent J* 1992; 13:29–34
- 7 Duthie N, Lyon FF, Sturrock KC, Yemm R. A copying technique for replacement of complete dentures. *Br Dent J* 1978;144(08): 248–252
- 8 Zarb GA, Hobkirk J, Eckert S, Jacob R. *Prosthodontic Treatment for Edentulous Patients: Complete Dentures and Implant-Supported Prosthesis*. 13th ed. St. Louis, MO: Elsevier Health Sciences; 2013: 134–143
- 9 Yemm R. Analysis of patients referred over a period of five years to a teaching hospital consultant service in dental prosthetics. *Br Dent J* 1985;159(09):304–306

- 10 Lechner SK, Champion H, Tong TK. Complete denture problem solving: a survey. *Aust Dent J* 1995;40(06):377–380
- 11 Mohamed TJ, Faraj SA. Duplication of complete dentures using a sectional mold technique. *J Prosthet Dent* 2001;85(01):12–14
- 12 Kurahashi K, Matsuda T, Goto T, Ishida Y, Ito T, Ichikawa T. Duplication of complete dentures using general-purpose handheld optical scanner and 3-dimensional printer: introduction and clinical considerations. *J Prosthodont Res* 2017;61(01):81–86
- 13 Lee SY, Kim H, Lee D, Park C. Modified digital workflow for artificial tooth exchange in a complete denture: a dental technique. *J Prosthet Dent* 2020;123(02):236–238