



Direct Fluoroscopic-Guided Sclerotherapy for Vulvoperineal Varices: An Experience in 70 Patients

Karim A. Abd El Tawab¹ Mohamed A. A. Hagag² Rana T. M. Khafagy¹

¹Department of Radiology, IR Unit, Ain Shams University Hospitals, Cairo, Egypt

²Department of Vascular Surgery, Ain Shams University Hospitals, Cairo, Egypt

Address for correspondence Karim A. Abd El Tawab, MD, 1 Ahmed Abd El Nabi Street, El Nozha ElJadida, Cairo, Egypt (e-mail: Karimabdeltawab@gmail.com).

Arab J Intervent Radiol 2022;6:25–32.

Abstract

Purpose The aim of this study was to assess the safety and effectiveness of percutaneous vulvoperineal varices sclerotherapy using 2% polidocanol foam under fluoroscopic guidance.

Subjects and Methods This is a retrospective review of prospectively collected data of 70 patients treated between June 2020 and November 2021, with a mean age of 31 years (range: 24–42 years). All patients were not pregnant with residual vulvoperineal varices after embolization of their refluxing tributaries of the ovarian vein and/or internal iliac veins presenting with vulvoperineal heaviness/pain with or without lower limb varicosities. Technical and clinical successes together with procedural complications were assessed.

Results The technical success rate was 100%. No minor or major complications have been reported. Follow-up was at 1 week, 2 weeks, 6 months, and 12 months post sclerotherapy. Clinical success was observed in all patients with improvement in their symptoms.

Conclusion Direct fluoroscopic-guided sclerotherapy for vulvoperineal varices offers a safe and effective treatment option with the ability of visualization and embolization of the pelvic leak points to avoid recurrence.

Keywords

- ▶ vulvoperineal varices
- ▶ pelvic leak points
- ▶ sclerotherapy

Introduction

Vulvar varicosities can occur due to various reasons including refluxing intrapelvic veins, venous obstruction, increased venous pressure, and venous insufficiency, most commonly during pregnancy.¹

Pelvic congestion syndrome (PCS) with chronic pelvic pain (CPP) is commonly associated with the presence of vulvar, perineal, and less commonly inguinal and buttocks varicose veins whether alone or associated with lower limbs

varicosities.² Consequently, vulvar varices became a pathognomonic symptom of pelvic varicosities. Its detection should draw our attention to the high possibility of intrapelvic veins' varicose transformation.³

Recently, pelvic venous disorder has become the terminology to describe women with CPP of venous origin, combining many syndromic conditions such as May–Thurner syndrome, nutcracker syndrome, and PCS.⁴

Varicosities can be detected in the labia majora and minora, perineum, inguinal region, and vagina with or

published online
April 20, 2022

DOI <https://doi.org/10.1055/s-0042-1744214>.
ISSN 2542-7075.

© 2022. The Pan Arab Interventional Radiology Society. All rights reserved.

This is an open access article published by Thieme under the terms of the Creative Commons Attribution-NonDerivative-NonCommercial-License, permitting copying and reproduction so long as the original work is given appropriate credit. Contents may not be used for commercial purposes, or adapted, remixed, transformed or built upon. (<https://creativecommons.org/licenses/by-nc-nd/4.0/>)

Thieme Medical and Scientific Publishers Pvt. Ltd., A-12, 2nd Floor, Sector 2, Noida-201301 UP, India

without extension to the medial thigh or the buttocks and the lateral thigh, more noted in pregnant women as opposed to nonpregnant women causing medical and cosmetic concerns. During pregnancy, damage may occur in the venous tributaries because of the increase in peripheral pelvic vein resistance and consequently of venous pressure. This may persist after delivery causing a 4:1 higher vulvoperineal varices rates in parous versus nulliparous women.⁵

The anatomy of the pelvic venous system in women is rather complex. Studies described six parietal escape points through which pelvic reflux can cause external genitalia and/or gluteal or inguinal varices or transmitted to lower limbs and cause varicose veins. Pelvic leak points reflux can spread either in the ipsilateral or contralateral sides due to the fact of lack of valves of all the pelvic veins except for the ovarian vein.⁶⁻⁹

Elimination of the vulvar and perineal varices of the external genital organs is achieved in various ways, including the surgical phlebectomy, sclerotherapy, and embolization of the tributaries of the refluxing internal iliac vein and ovarian veins.¹⁰⁻¹²

Our study aims to describe the feasibility and efficacy of polidocanol sclerotherapy treatment in patients with vulvar and/or perineal varices due to refluxing intrapelvic veins under fluoroscopic guidance aiming at treating the leak points that can cause the recurrence of these varicosities if untreated adequately.

Materials and Methods

This is a retrospective review of prospectively collected data of 70 patients treated by percutaneous vulvar varices sclerotherapy under fluoroscopic guidance between June 2020 and November 2021. Informed consent was obtained from the patients. Approval from the ethical committee was obtained.

All sclerotherapy procedures were done by two interventional radiologists (K.A, R.K) with 15 and 7 years of experience, respectively, in the same institution (Interventional Radiology Unit, Ain Shams University Hospital, Cairo, Egypt).

Inclusion criteria included nonpregnant patients at the time of the procedure with residual vulvoperineal varices after embolization of their refluxing tributaries of the ovarian vein and/or internal iliac veins using sclerosant or combined sclerosant and coils (► **Fig. 1**). All the patients were suffering from PCS symptoms including CPP on their initial presentation before having their refluxing pelvic veins embolized. The time interval between the initial embolization procedure and vulvar varices treatment was 2 weeks. Patients aged between 24 and 42 years (mean age: 31 years). In addition to visualized vulvar, perineal, gluteal, or inguinal varices, other clinical symptoms included perineal pain, perineal heaviness dyspareunia, engorgement of the labia especially on standing or straining, perineal discomfort, and continuous or recurrent genital arousal.

All patients underwent duplex ultrasound (US) examination of the vulvar varices and veins of the lower extremities using a linear probe (7.5–12 MHz) over the vulva, perineum, inguinal and gluteal regions at rest first then during Valsalva

maneuver, while the patient was in semirecumbent lithotomy position to increase intra-abdominal pressure.

In 20 (28.5%) patients, a combination of vulvoperineal varices with varicose veins on the buttocks was found. Seven (10%) patients had vulvoperineal varices and varicose veins on the posterolateral surface of the upper thigh. Ten (14.2%) patients had vulvoperineal varices and varicose veins on the medial aspect of the upper thigh and inguinal region. However, twenty-four (34.2%) patients had a combination of all the previously described varicosities.

Direct percutaneous sclerotherapy of the vulvoperineal and/or gluteal or inguinal veins was done using a foam form of 2% lauromacrogol 400 or Polidocanol (Aethoxysklerol 2%; Chemische Fabrik Kreussler & Co. GmbH, Germany) for all patients.

Sclerotherapy Technique

Patients with planned vulvar punctures underwent US-guided pudendal block of the affected side using lidocaine hydrochloride 1% infiltration with a maximum dose of 300 mg (4.5 mg/kg). This was done to avoid extreme pain of the subcutaneous punctures due to the very high sensory nerve supply of the vulvar area unlike the perineal, gluteal, and inguinal areas. Consequently, patients who needed perineal, gluteal, or inguinal punctures underwent subcutaneous lidocaine 1% injection with no need for a pudendal block. US-guided percutaneous puncture of the varices was performed using an 18 G cannula with the injection of contrast under fluoroscopic guidance to delineate the anatomy of the veins and to detect large direct communicating veins connecting the vulvoperineal and the intrapelvic veins. Foam form of 2% Polidocanol was injected (with ratio 1:4 sclerosant to room air mixed via the classic Tessari method¹³). Based on our experience, a maximum of 8 cc of the sclerosant material (40 cc of foam) was injected per session to avoid toxicity. The end point of the sclerotherapy injection was achieved by filling the varicosities and reaching the leak points. After occlusion of the vulvar varices, as monitored by stasis of the contrast under fluoroscopy and US, manual compression for 3 to 5 minutes was done. After the procedure, the patients were advised to wear tight underwear for 1 week applying hot fomentation for 3 days. Patients were discharged directly after the procedure with no specific medication post-procedure except for any analgesic medications if needed.

Technical Success

Technical success was defined as the ability to embolize the branches supplying the vulvar and perineal varices draining into the internal iliac veins and ovarian veins with cessation of blood flow to these branches.

Follow-Up

Follow-up was done by the interventional radiologist at 1 week, 2 weeks, 6 months, and 12 months after the treatment session by doing a US examination for the vulvar and perineal varices along with monitoring the symptoms. A follow-up of complications was also assessed.

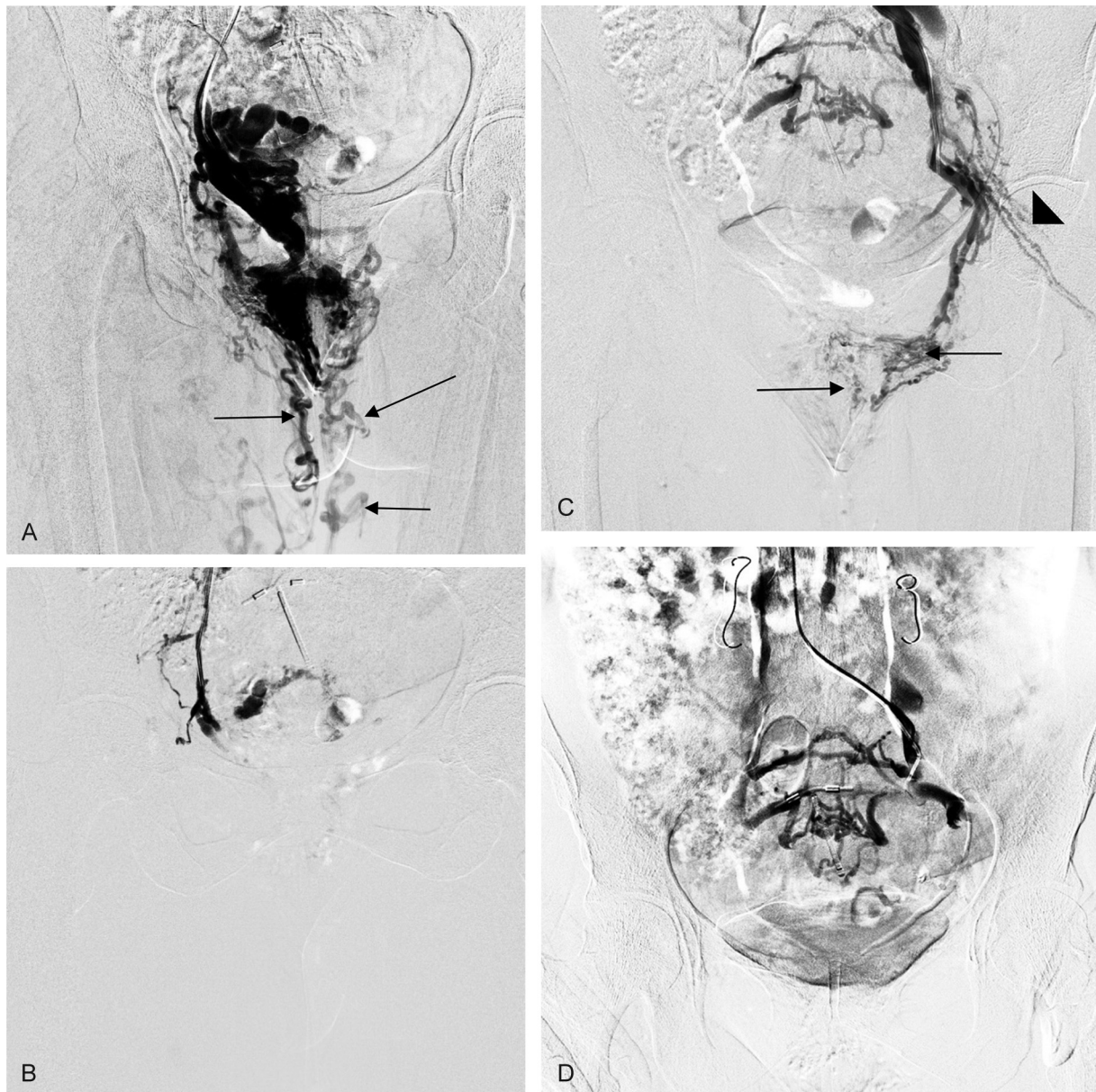


Fig. 1 Marked vulvoperineal varices supplied by refluxing internal iliac vein tributaries. (A) Injection through right internal iliac vein (IIV) revealing marked bilateral vulvar and perineal varices (black arrows). (B) Post sclerotherapy by 3% polidocanol foam. (C) Injection through left IIV revealing bilateral vulvar and perineal varices (black arrows) as well as gluteal connection (black arrowheads). (D) Post sclerotherapy by 3% polidocanol foam showing complete cessation of flow to the vulva.

The criteria for evaluating the clinical success include the disappearance of treated varices on the US and, by visual assessment, the disappearance of the related pain and swelling of the labia.

Results

Technical success was seen in all cases (100%). All patients had marked improvement in their symptoms.

All patients on venography of the draining veins showed drainage of the vulvar varices and/or the perineal veins into the pelvic veins mainly the internal iliac veins through mainly perineal veins and internal pudendal veins. Ovarian venous drainage was not seen since they were embolized in a

previous session in all the patients. In 13 (18.6%) patients, connection with the vaginal veins through vaginal varices that eventually drained into the inferior superficial epigastric vein and the pelvic veins was noted.

One patient was found to have high flow drainage of the vulvar veins into distal right external iliac veins (iliofemoral junction) in a high flow pattern (►Fig. 2) in which the sclerotherapy from this puncture was aborted for fear of thrombosis of the veins draining the lower limb with consequent deep vein thrombosis (DVT) or pulmonary embolism (PE). Another puncture was done successfully that showed communication with the pelvic veins with consequent embolization.

Also, several preliminary punctures revealed an isolated venous blowout (►Fig. 3) not communicating to pelvic veins.

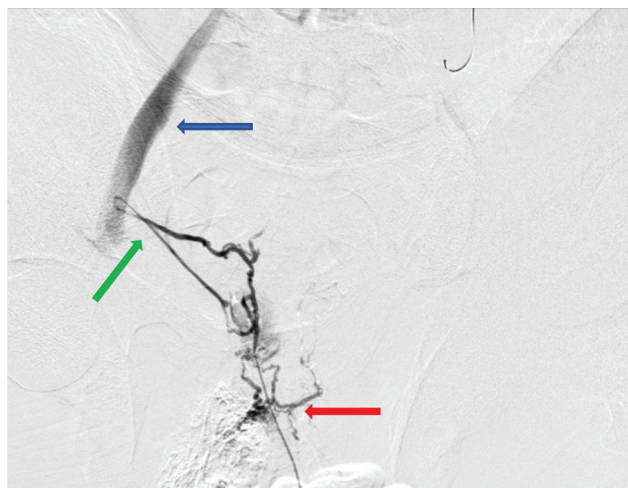


Fig. 2 Right labial injection revealed small diameter vulvar varices (red arrow) with direct high flow connection (green arrow) with the external iliac vein (blue arrow). The injection was aborted to avoid deep vein thrombosis and another safer puncture site was chosen.

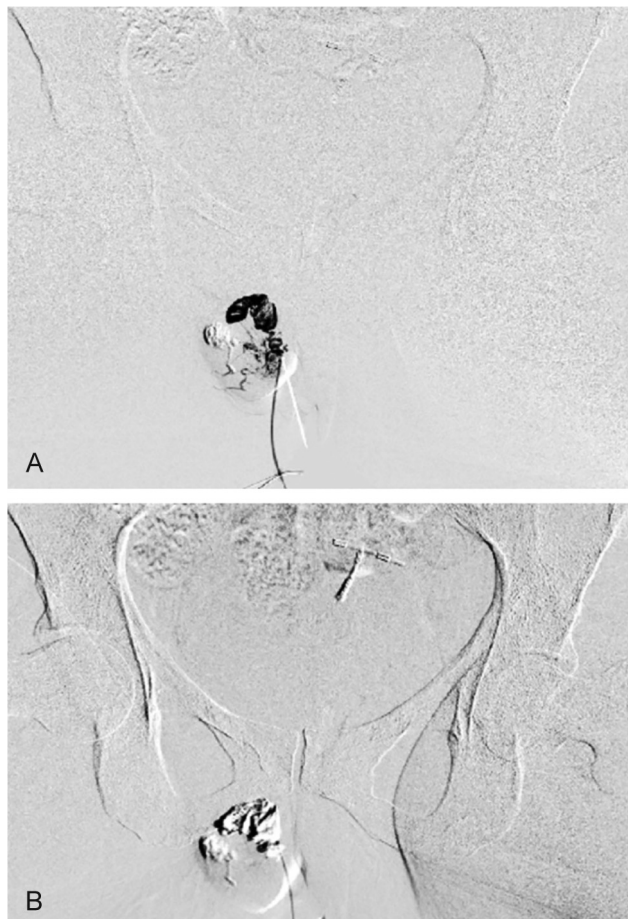

Fig. 3 Injection via right labia majora (A), revealing isolated vulvar blow out that was injected with 1 cc foam. (B) Control venogram showing cessation of flow after sclerotherapy.

These blowouts were injected with a little amount of sclerosant foam (depending on the size of the blow out) (→ **Table 1**). In these cases puncturing different varicosity, draining into the pelvic veins was done. The high flow

Table 1 Drainage of the vulvoperineal varices to the pelvic veins

Drainage of the vulvoperineal varices to the pelvic veins	No. of patients (%)
Through the perineal and internal pudendal veins	70 (100)
Through the vaginal veins and the inferior superficial epigastric vein	13 (18.6)
Drainage into external iliac vein	1 (0.014)
Isolated venous blowout	53 (75.7)

external iliac communication as well as the isolated blow-outs show the value of fluoroscopic guided injection.

Sclerosis and the disappearance of the vulvar veins in 56 (80%) patients were observed after one session of sclerotherapy. In these patients, a control examination 1 week after the injection indicated the presence of thrombophlebitis with an unexpressed local inflammatory reaction, which did not require the use of additional drugs. The subsidence of the phenomena of thrombophlebitis was noted by the second week from the start of treatment.

A second session was done for 14 (20%) patients who had residual varices at the 2-week follow-up revealed by US examination.

No minor or major complications were reported. All patients underwent a control US of the pelvic veins with no signs of thrombosis were found. No cases of hyperpigmentation, allergic reaction, or skin necrosis were found. No signs of PE were encountered; however, five patients (7.1%) developed mild self-limiting cough immediately after the procedure. All the patients reported improvement in their symptoms with the disappearance of the related pain and swelling of the labia.

Twenty (28.5%) patients completed a 1-year follow-up. During the entire follow-up period, recurrence was found in only five (7%) women who became pregnant within 1 to 3 months after treatment. The rest of the patients showed a stable therapeutic effect with no vulvar or perineal varices, no pain, or swelling of the labia. Fifty (71.5%) patients are still under follow-up; 23 (32.8%) patients are between 6 and 12 months, and the rest are less than 6 months follow-up with none showing recurrence during their short-term follow-up period.

Discussion

The venous drainage of the vulva is via pudendal and perineal veins, which then depend on the competence of the ovarian and iliac veins. The majority of varicose veins of the vulva and perineum are caused by reflux in the pelvic veins, ovarian vein reflux, internal iliac vein reflux, or a combination of all. Extension of varicosities into the medial thigh is a common finding in patients with varicosities of the vulva.¹⁴

Based on previously published studies, six anatomical parietal leak points (PLP) of reflux from the pelvic veins to

the external genitalia and lower limbs could be identified. This subsequently highlighted the need for the treatment of these leak points in such patients and opened the door to propose minimally invasive therapeutic surgical and image-guided approaches.^{8,9,15,16}

The six leak points include the perineal point, the inguinal point, the clitoral point, the superior gluteal point, the inferior gluteal point, and finally the obturator point.

The perineal point (PP) is the most frequently seen pelvic leak point, representing ~60 to 70% of all the treated leak points as it drains perineum through the perineal vein, labia majora, frenulum of labia minora through anterior, and posterior labial veins respectively as well as the vulvar venous plexus (►Fig. 4). The vulvar plexus drains into the perineal vein to reach the internal pudendal vein into the Alcock's canal to reach the internal iliac vein (►Fig. 5). PP reflux can extend to the ipsilateral or contralateral saphenous network through superficial perineal plexuses. The inguinal point is the superficial ring of the inguinal canal crossed by the mons veneris veins, draining the superficial perineal and inguinocrural areas connecting to the uterine round ligament vein, yet they can feed ipsilateral and contralateral vulvar or perineal varices (►Fig. 6), as well as lower limbs varicose veins through branches of the superficial perineal venous network.

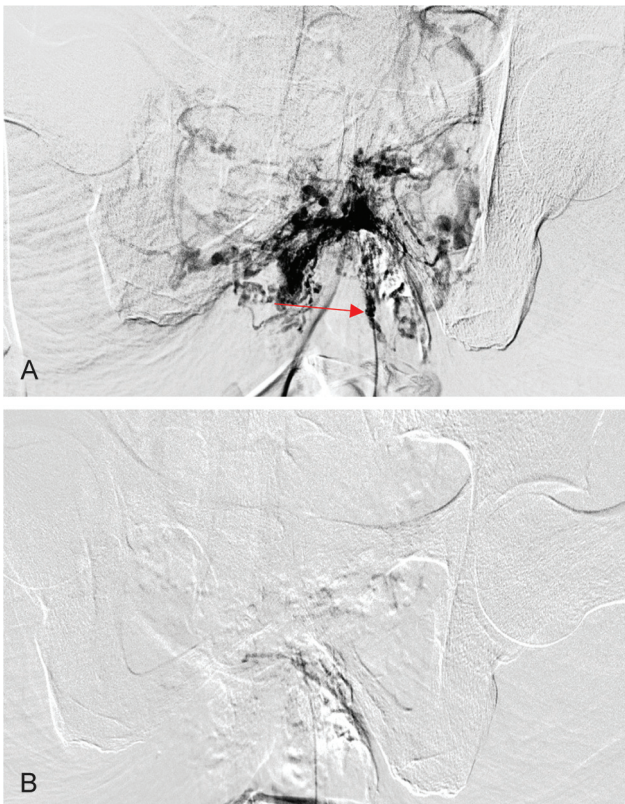


Fig. 4 A case of bilateral vulvoperineal varices in a 36-year-old patient suffering from back pain genital heaviness and continuous genital arousal; (A) injection via perineal puncture (red arrow) revealed extensive vulvoperineal varices draining in both vulvar plexuses to pudendal veins. (B) Complete cessation of variceal filling post sclerotherapy in control venogram.

The clitoris point is related to incontinence of the medial pudendal vein that generates increased venous pressure; hence, reflux can feed ipsilateral or contralateral perineal and anterior labial veins and/or the lateral pudendal external vein to reach the great saphenous vein. Clitoris points are located on each side of the clitoris and are rarely identified in practice.^{6,7}

Superior gluteal point and inferior gluteal point drain directly into the internal iliac vein (►Fig. 7). Finally, the obturator point is the confluence of the anterior muscular circumflex vein into the confluence between the saphenous arch and the femoral vein.^{6,7}

The prevalence of vulvar varices in the general population is still unknown. In a series of over 4,000 female vein clinic patients, the incidence of vulvar varices was 4%, as described by Hobbs in his research.³

The incidence rises to 24 to 40% in patients with PCS, who are typically multiparous, premenopausal women between 20 and 45 years of age.¹⁷⁻²⁰

In 8 to 10% of pregnancies, vulvar varices occur as a transient phenomenon and usually fully resolve within 6 weeks postpartum.^{3,11}

There is an overall scarcity of literature discussing pelvic leak points and vulvoperineal varices, particularly in non-pregnant women. Most of the treatment approaches are derived from case reports or small case series. Management options for these varices include compression, sclerotherapy, ovarian and internal iliac veins embolization, surgical ligation, or phlebectomy.²¹

Craig and Hobbs in their study published in 1975 suggested that patients with vulvar varices should be examined radiologically by percutaneous vulvar vein injection of contrast medium. However, according to our knowledge, no studies assessed the fluoroscopic-guided percutaneous sclerotherapy. Previous studies mentioning percutaneous sclerotherapy described the use of sclerosing agents, whether in liquid or foam form, through US-guided injection of the extra pelvic veins.⁹

Fluoroscopic guidance can help to identify the draining veins into the pelvis, monitor the sclerotherapy injection till reaching stasis, and avoid the injection of aberrant draining veins if seen joining the external iliac veins, for the fear of developing lower limb DVT; also it can help identify isolated blowouts that will need puncturing another varicosity.

Some studies stated that vulvar or lower limbs varicose veins of pelvic origin exist and the US-guided minimally invasive surgical phlebectomy or sclerotherapy of pelvic leaks under local anesthesia, without any need of pelvic varicose embolization before PLP reflux ablation leaks, is reliable and durable.⁴

However, from our experience, we would not support the treatment of vulvoperineal varices, resulting from refluxing gonadal and/or iliac veins, before the treatment of these veins to avoid recurrence. Previous studies stated that pelvic vein embolization usually reduces PLP reflux and many cases usually need complementary superficial treatment whether surgically or image-guided.¹²

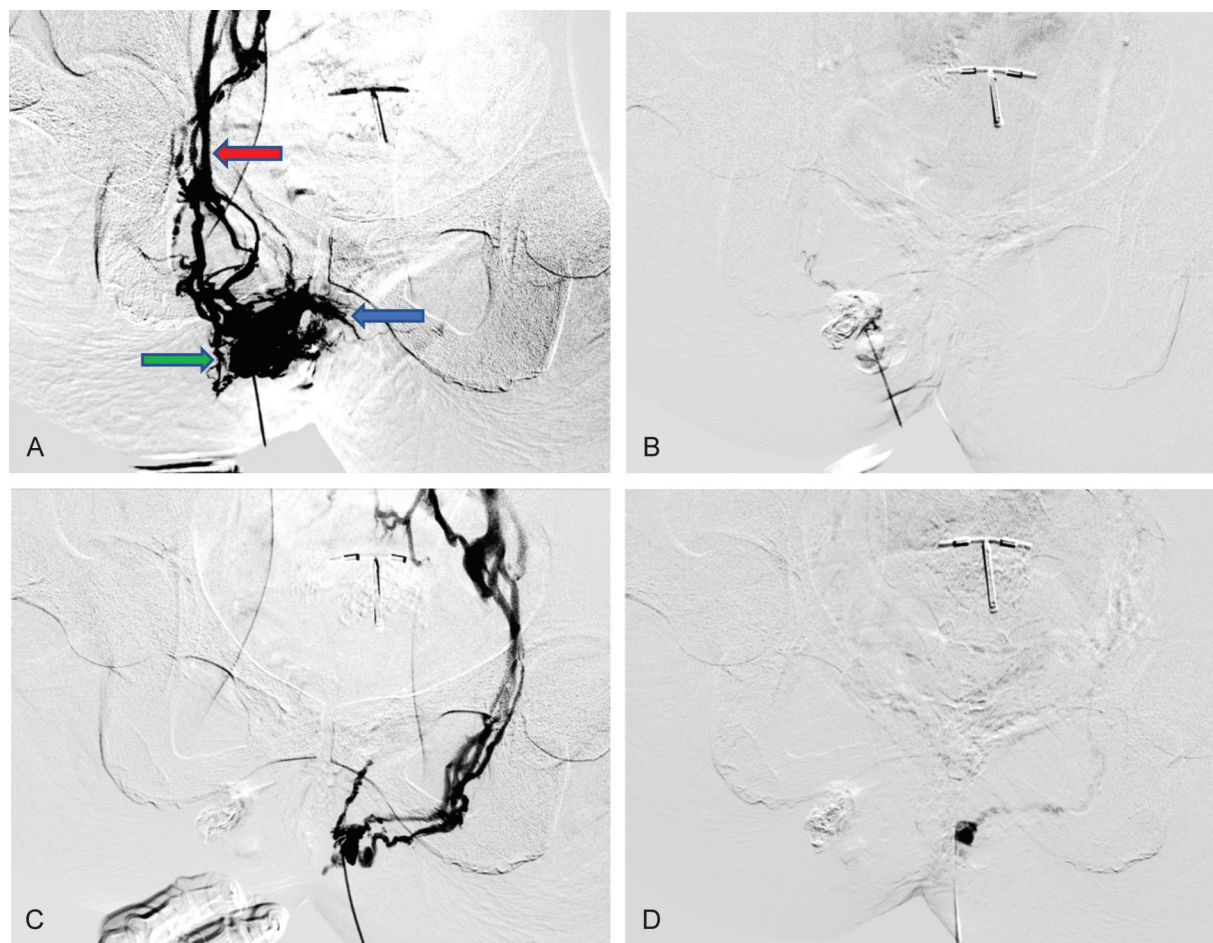


Fig. 5 A case of bilateral vulvar varices in a 31-year-old patient suffering from genital heaviness and dyspareunia; (A) injection through right labia majora revealing marked vulvoperineal varices draining into the internal iliac vein via vulvar venous plexus (green arrow), perineal vein (blue arrow), and internal pudendal vein (red arrow). (B) After sclerotherapy of the right side with no flow within the treated veins. (C) Injection through left labia majora with similar findings to the right side. (D) After sclerotherapy with no flow within the veins.

Also, Gavrilov mentioned in his study that the selection criteria for the US-guided vulvar varices sclerotherapy, without the need of prior pelvic vein embolization, included the absence of an obvious connection between the dilated vulvar vein and a large tributary of the internal iliac vein detected by the duplex US. This indicates that the presence of such connection requires intervention first that matches our theory.²²

Reported sclerosants used successfully for vulvar varices included liquid and foam sodium tetradecyl sulfate (0.33–3%) liquid and foam polidocanol (1–2%) and liquid polyiodinated iodine 2%.^{10,11,22–26}

In our study, we used 2% foam Polidocanol as the preferred sclerosing agent with no evidence of allergic reactions or hyperpigmentation. We assumed, based on our experience in treating lower limb varicosities, that this percentage would be the best to treat these superficial veins with deep intrapelvic venous connections. We believe that using a sclerosant with a less percentage concentration will probably mean it will be diluted before reaching such deep venous connections.

However, to our knowledge, there were no definite published guidelines or enough research to recommend a specific sclerotherapy form or percentage to be used in the treatment of vulvar varices.

None of the treated patients in our study developed pelvic vein thrombosis through the obvious communications between the vulvoperineal veins and the intrapelvic veins. Five (7.1%) patients developed mild self-limiting cough immediately after the procedure that was self-limiting; it could be a mild form of PE yet with no major signs of it. This could be explained by the dilution of the injected sclerosant foam in the veins before reaching the pulmonary arteries.

Given the absence of thrombotic complications of the vulvar veins sclerotherapy and its high efficiency in relieving the symptoms, this method can be considered valid and safe.

Recurrence was noted in five (7%) women who became pregnant within 1 to 3 months after treatment so it is recommended to advise the patients not to get pregnant for at least 6 months after treatment with avoiding hormonal contraceptives.

The study carries some limitations; being a single-center experience, with the lack of a control group of patients who would undergo sclerotherapy or surgical removal of the vulvar and perineal veins without embolization of the ovarian veins and iliac vein tributaries. The biggest limitation of our study is the subjective nature of the treatment decisions taken depending mainly on the authors' wide cumulative

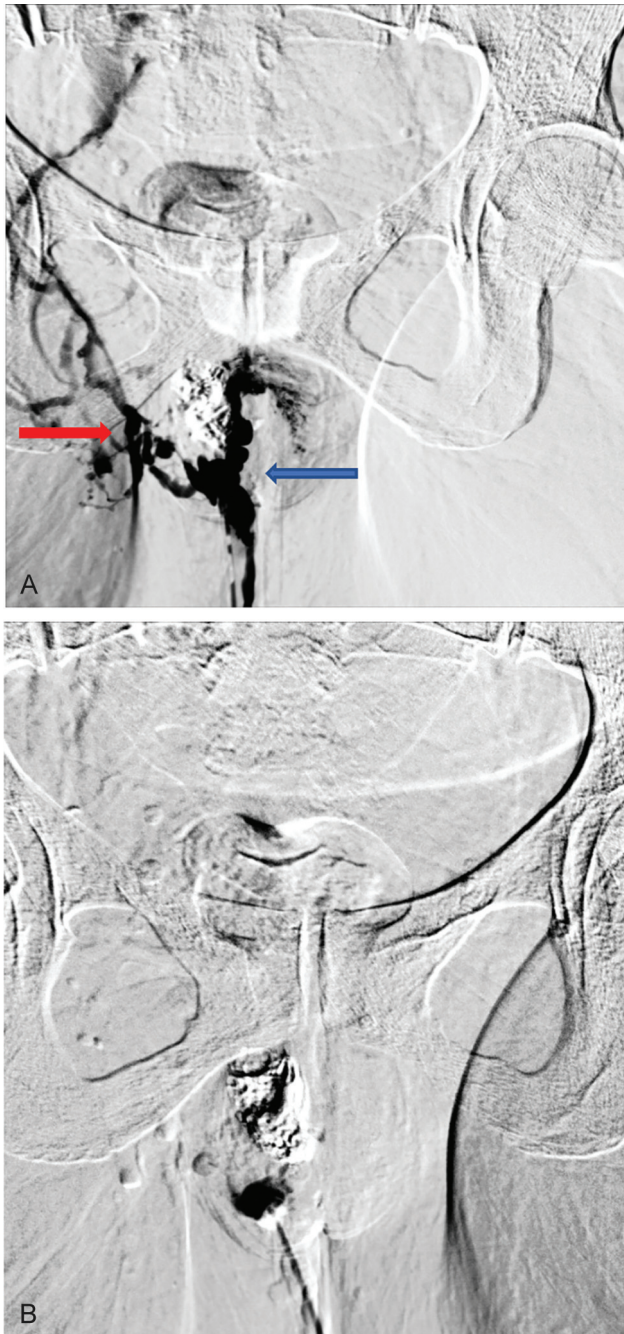


Fig. 6 A case of right vulvar varices in a 32-year-old patient suffering from genital heaviness and swelling on straining; (A) injection via right labial puncture revealing extensive vulvoperineal varices (blue arrow) refluxing to the internal iliac vein via inguinal point filling (red arrow) and (B) post sclerotherapy with disappearance of varicosities.

experience in pelvic and lower limb varicose veins treatment; however, this can be accepted due to the scarcity of publications concerning this issue with no consensus on the treatment of such cases whatsoever.

Conclusion

The proposed technique of the percutaneous vulvoperineal veins sclerotherapy, under fluoroscopic guidance, is an effective and safe way to treat vulvar and perineal varices with the

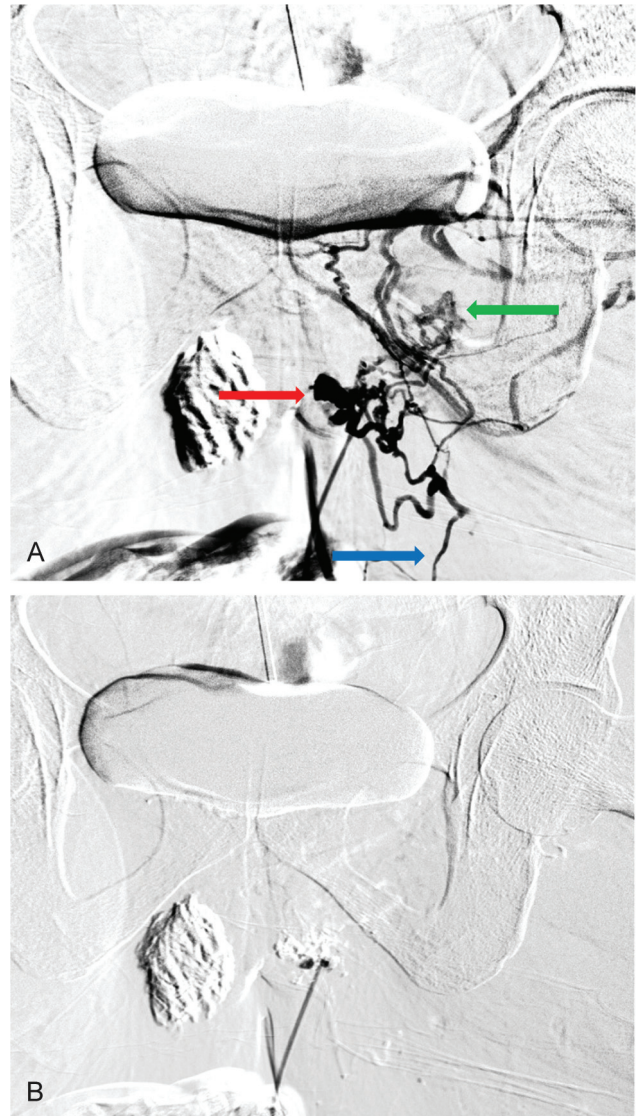


Fig. 7 A 26-year-old patient suffering from heaviness and pain during standing due to genital, gluteal, and extra-axial lower limbs varices; injection through a gluteal puncture in lithotomy position revealed; (A) gluteal varices (red arrow) connecting with vulvar (green arrow) and lower limbs (blue arrow) with no visible pelvic connections through this puncture. (B) Control venogram showing cessation of varicosities flow after sclerotherapy.

ability of visualization and embolization of the pelvic leak points to avoid recurrence.

Conflict of Interest

None declared.

References

- 1 Johnson NR. Vulvovaginal varicosities and pelvic congestion syndrome. UpToDate. 2011. Available at: <https://www.uptodate.com/contents/vulvovaginal-varicosities-and-pelvic-congestion-syndrome>. Accessed February 10, 2022
- 2 van Rij AM, Jiang P, Solomon C, Christie RA, Hill GB. Recurrence after varicose vein surgery: a prospective long-term clinical study with duplex ultrasound scanning and air plethysmography. *J Vasc Surg* 2003;38(05):935–943

- 3 Van Cleef J-F. Treatment of vulvar and perineal varicose veins. *Phlebology* 2011;18(01):38–43
- 4 Winokur RS. The new vocabulary of pelvic venous disorders. *Endovascular Today*. 2021;20(04):54–56
- 5 Rozenblit AM, Ricci ZJ, Tuvia J, Amis ES Jr. Incompetent and dilated ovarian veins: a common CT finding in asymptomatic parous women. *AJR Am J Roentgenol* 2001;176(01):119–122
- 6 Delfrate R, Bricchi M, Franceschi C. Minimally-invasive procedure for pelvic leak points in women. *Veins and Lymphatics* 2019;8(01):7789
- 7 Zamboni P, Mendoza E, Gianesini S. *Saphenous Vein-Sparing Strategies in Chronic Venous Diseases*. Ferrara, Italy: Springer; 2018 ISBN: 978-3-319-70638-28
- 8 Thomas ML, Fletcher EWL, Andress MR, et al. The venous connections of vulvar varices. *Clin Radiol* 1967;18(03):313–317
- 9 Craig O, Hobbs JT. Vulvar phlebography in the pelvic congestion syndrome. *Clin Radiol* 1975;26(04):517–525
- 10 Paraskevas P. Successful ultrasound-guided foam sclerotherapy for vulvar and leg varicosities secondary to ovarian vein reflux: a case study. *Phlebology* 2011;26(01):29–31
- 11 Verma SB. Varicosities of vulva (vulvar varices): a seldom seen entity in dermatologic practice. *Int J Dermatol* 2012;51(01):123–124
- 12 Lopez AJ. Female pelvic vein embolization: indications, techniques, and outcomes. *Cardiovasc Intervent Radiol* 2015;38(04):806–820
- 13 Tessari L, Cavezzi A, Frullini A. Preliminary experience with a new sclerosing foam in the treatment of varicose veins. *Dermatol Surg* 2001;27(01):58–60
- 14 Theresa M. Soto. Accessed December 10, 2021 at: Understanding-vulvar-varicosities. <https://www.centerforvein.com/blog/>
- 15 Franceschi C, Bahnini A. Leak points between pelvic viscera and lower limb varicosities. *Phlebologie* 2004;57:37–42
- 16 Francheschi C, Bahnini A. Treatment of lower extremity venous insufficiency due to pelvic leak points in women. *Ann Vasc Surg* 2005;19(02):284–288
- 17 Hobbs JT. The pelvic congestion syndrome. *Br J Hosp Med* 1990;43(03):200–206
- 18 Maleux G, Stockx L, Wilms G, Marchal G. Ovarian vein embolization for the treatment of pelvic congestion syndrome: long-term technical and clinical results. *J Vasc Interv Radiol* 2000;11(07):859–864
- 19 Nasser F, Cavalcante RN, Affonso BB, Messina ML, Carnevale FC, de Gregorio MA. Safety, efficacy, and prognostic factors in endovascular treatment of pelvic congestion syndrome. *Int J Gynaecol Obstet* 2014;125(01):65–68
- 20 Kies DD, Kim HS. Pelvic congestion syndrome: a review of current diagnostic and minimally invasive treatment modalities. *Phlebology* 2012;27(Suppl 1):52–57
- 21 Gavrilov SG, Zolotukhin IA, Moskalenko EP, Turishcheva OO. Sclerotherapy of vulvar varicose veins. *Flebologia*. 2016;10(01):50. Doi: 10.17116/flebo201610150-53
- 22 Gavrilov SG. Vulvar varicosities: diagnosis, treatment, and prevention. *Int J Womens Health* 2017;9:463–475
- 23 Ninia JG, Goldberg TL. Treatment of vulvar varicosities by injection-compression sclerotherapy. *Dermatol Surg* 1997;23(07):573–574, discussion 574–575
- 24 Nabatoff RA. Varicose veins of pregnancy. *JAMA* 1960;174:1712–1716
- 25 Naous J, Siqueira L. A vulvovaginal mass in a 16-year-old adolescent: a case report. *J Pediatr Adolesc Gynecol* 2016;29(01):e17–e19
- 26 Zelikovski A, Sternberg A, Haddad M, Urca I. Varicosities of uncommon sites: therapeutic aspects. *Int Surg* 1981;66(01):73–77