Article published online: 2022-10-03

Short Communication

Post-Laminectomy Non-Osseous Intraspinal Extradural Tuberculous Granulation Tissue: An Undescribed Entity

Jeyaselva Senthilkumar Thotlampatti Pachiyappan[1] Sekar Chinnamuthu[1]

[1] Department of Neurosurgery, SRM Medical College Hospital and Research Centre, SRM Institute of Science & Technology, Kattankulathur, Chengalpet, Tamil Nadu, India

Indian J Neurosurg

Address for correspondence T.P. Jeyaselva Senthilkumar, MCh (Neuro), Department of Neurosurgery, Faculty of Medical Sciences, SRM Medical College Hospital & Research Centre, SRM Institute of Science & Technology, Kattankulathur, Chengalpet-603203, Tamil Nadu, India (e-mail: jeyaselp@srmist.edu.in).

Abstract

Spinal tuberculosis (TB) is well studied and described in the literature. It is known to occur anywhere along the transverse plane of the spine. Vertebral TB accounts for less than 1% of all TB infections in the body and more than 50% of musculoskeletal infections. It is considered the most serious type of skeletal TB, with possible neurological symptoms due to compression of neural structures. It may also lead to deformity and significant vertebral structure destruction and instability. Though non-osseous intraspinal extradural tuberculous granulation tissue is reported in several instances, to the best of our knowledge and thorough literature search, the post-laminectomy occurrence of extradural tuberculous granuloma is not reported in the literature so far. Whether it is the reactivation of previously dormant tuberculous infection or naive infection is elusive. Surgical excision and anti-tuberculous therapy is the mainstay of treatment.

Keywords
- spinal tuberculosis
- tuberculosis spine
- postoperative spine tuberculosis

Aim

To describe an undescribed complication following laminectomy and discuss its etiology.

Introduction

Spinal tuberculosis (TB) is well studied and described in the literature. It is known to occur anywhere along the transverse plane of the spine. Vertebral TB accounts for less than 1% of all TB infections in the body and more than 50% of musculoskeletal infections.[1] It is considered the most serious type of skeletal TB, with possible neurological symptoms due to compression of neural structures. It may also lead to deformity and significant vertebral structure destruction and instability. Though non-osseous intraspinal extradural tuberculous granulation tissue is reported in several instances, its occurrence post laminectomy is not reported so far in the literature. We are presenting the first case of post-laminectomy non-osseous intraspinal extradural tuberculous granulation tissue and its management.

Index Case

A 60-y-old, non-hypertensive/non-diabetic, healthy, kidney donor, female patient was admitted with c/o low back pain and neurogenic claudication. On examination, the straight leg raising test (SLRT) was 40 degrees on the left side with left ankle dorsiflexion weakness and left L4 numbness. She was

DOI https://doi.org/10.1055/s-0042-1744251.
ISSN 2277-954X.

© 2022. Neurological Surgeons' Society of India. All rights reserved.
This is an open access article published by Thieme under the terms of the Creative Commons Attribution-NonDerivative-NonCommercial-License, permitting copying and reproduction so long as the original work is given appropriate credit. Contents may not be used for commercial purposes, or adapted, remixed, transformed or built upon. (https://creativecommons.org/licenses/by-nc-nd/4.0/)
Thieme Medical and Scientific Publishers Pvt. Ltd., A-12, 2nd Floor, Sector 2, Noida-201301 UP, India

evaluated in another hospital with magnetic resonance imaging (MRI) lumbosacral spine and referred to us, the MRI showed L3–L4 sequestrated disc prolapse on the left side. She was evaluated for surgery and underwent left L3 fenestration and discectomy. She was completely relieved of preoperative pain and was discharged home on the fifth postoperative day.

One month later, she presented again with right lower limb radicular pain. She had a restricted SLRT of 60 degrees on the right side with normal SLRT on the left side with an intact neurological examination. She was advised MRI but lost to follow-up. Again after 2 months following surgery, she reported swelling and pain at the operated site. MRI LS spine showed post hemilaminectomy status with extradural collection on the left side extending up to the subcutaneous plane. The thecal sac was pushed to the right side (►**Figs. 1** and **2**). She was planned for re-exploration and underwent revision complete laminectomy at L3 level and the granulation tissue was excised completely. No pus was seen. Both roots were adequately decompressed. Granulation tissue was subjected to microbiological studies, which showed AFB+, Gram's stain and culture negative. Histopathologic Examination (HPE) revealed chronic granulomatous inflammation with Langhans type giant cells—S/O tuberculous etiology. The patient was started on anti-tuberculous therapy (ATT). Three months post-ATT, she was asymptomatic and tolerating ATT well.

Fig. 1 T1 SAG image showing spondylodiscitis changes at L3–L4 level with intraspinal collection and subcutaneous inflammation.

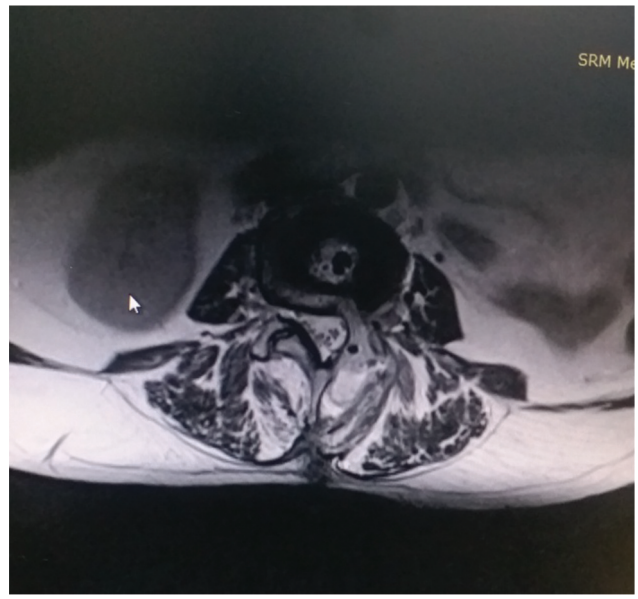

Fig. 2 T2 Axial Image Showing Granulation Tissue Extending from Subcutaneous Plane to Disc Space Through Laminotomy Defect.

Discussion

Tuberculosis of the spine is known to occur along any plane in the spine. There is a general consensus that intraspinal tuberculous lesions are always secondary to spinal TB.[2] Intraspinal extradural tuberculous granulomas rarely cause spinal cord compressions. Isolated tuberculous granulomas without vertebral involvement are still rarer.[3,4] Intraspinal tuberculosis, which includes intraspinal tuberculoma, tuberculous abscess, and tuberculous granulation tissue, is rarely reported.[5] Isolated intraspinal tuberculosis without radiological evidence of vertebral involvement is rather uncommon. Kumar et al[6] reported 22 patients with intraspinal TB, which includes 12 extradural granulomas. Of these extradural granulomas, only three were found to have no osseous involvement. Most cases of intraspinal extradural tuberculous granuloma reported in the literature involved the thoracic or lumbar regions of the spine. In 1981, there were reports of cervical extradural tuberculous granuloma by Reichenthal et al[4] and Shah et al.[7] To the best of our knowledge and thorough literature search, the post-laminectomy occurrence of extradural tuberculous granuloma is not reported in the literature so far. Whether it is the reactivation of previously dormant tuberculous infection or naive infection is elusive. Preoperative evaluation of our patient ruled out the possibility of pre-existing tuberculous infection. Taking account of all these, we are reporting the first case of post-laminectomy intraspinal extradural tuberculous granulation tissue. Surgical excision and anti-tuberculous therapy is the mainstay of treatment.

Conclusion

Though rare, tuberculous etiology should be thought of in postspinal surgery infections and screened for the same, otherwise we will miss this spectrum of disease.

 © 2022. Neurological Surgeons' Society of India. All rights reserved.

Funding
None.

Conflict of Interest
None declared.

References

1 Hsu LC, Leong JC. Tuberculosis of the lower cervical spine (C2 to C7). A report on 40 cases. J Bone Joint Surg Br 1984;66(01):1–5
2 Arseni C, Samitca DC. Intraspinal tuberculous granuloma. Brain 1960;83:285–292
3 Mantzoros CS, Brown PD, Dembry L. Extraosseous epidural tuberculoma: case report and review. Clin Infect Dis 1993;17 (06):1032–1036. Doi: 10.1093/clinids/17.6.1032
4 Reichenthal E, Cohen ML, Shalit MN. Extraosseous extradural tuberculous granuloma of the cervical spine: a case report and review of intraspinal granulomatous infections. Surg Neurol 1981;15(03):178–181
5 Watts HG, Lifeso RM. Tuberculosis of bones and joints. J Bone Joint Surg Am 1996;78(02):288–298
6 Kumar S, Jain AK, Dhammi IK, Aggarwal AN. Treatment of intraspinal tuberculoma. Clin Orthop Relat R 2007:62–66
7 Shah A, Nadkarni T, Goel N, Goel A. Circumferential craniocervical extradural tuberculous granulations. J Clin Neurosci 2010;17(06): 808–809. Doi: 10.1016/j.jocn.2009.07.120

 © 2022. Neurological Surgeons' Society of India. All rights reserved.