



# Concomitant Pneumocephalus and Pneumorrhachis after Posterior Fossa Surgery

Sameera Vattipalli<sup>1</sup> Mayank Tyagi<sup>1</sup> Charu Mahajan<sup>1</sup> Arvind Chaturvedi<sup>1</sup>

<sup>1</sup>Department of Neuroanaesthesiology and Critical Care, All India Institute of Medical Sciences, New Delhi, India

J Neuroanaesthesiol Crit Care

**Address for correspondence** Charu Mahajan, MD, DM, Department of Neuroanaesthesiology and Critical Care, Neurosciences Centre, All India Institute of Medical Sciences, New Delhi 110029, India (e-mail: charushrikul@gmail.com).

Pneumorrhachis, the presence of air in the spinal canal, may be caused by diverse pathologies such as incidental durotomy, barotrauma, pneumothorax, and trauma.<sup>1</sup> It is usually asymptomatic, being often noted on radiological investigations, but at times can cause features of cord compression.<sup>2</sup> The occurrence of pneumocephalus is quite common after posterior fossa surgery, but pneumorrhachis is a rare entity despite an existing communication between the cerebral and spinal subarachnoid spaces. We report a case of pneumorrhachis, wherein air was incidentally detected on postoperative scans in a child after posterior fossa surgery. Parent of this child provided written consent for the publication of this letter.

A 7-year-old child with a history of headache, vomiting, and imbalance while walking underwent suboccipital craniotomy and excision of posterior fossa tumor in prone position. Sevoflurane with oxygen-air mixture (1:1) was used for the maintenance of anesthesia. The surgery lasted for 8 hours and was uneventful. Due to the large size of tumor and its proximity to vital brain structures, subtotal excision was performed. Postoperatively, it was decided to mechanically ventilate the patient overnight. Postoperative magnetic resonance imaging revealed cervical pneumorrhachis and pneumocephalus with pneumoventricle (► **Fig. 1**). There were no apparent new neurological deficits or cerebrospinal fluid leak. The patient was shifted to neurosurgical intensive care unit and mechanically ventilated overnight with 100% oxygen. Patient was weaned and successfully extubated next morning. The entrapped air cleared over the next few days and patient was discharged 4 days later with no new neurological deficits.

Loss of cerebrospinal fluid from the operative site in posterior fossa surgeries is known to create vacuum leading

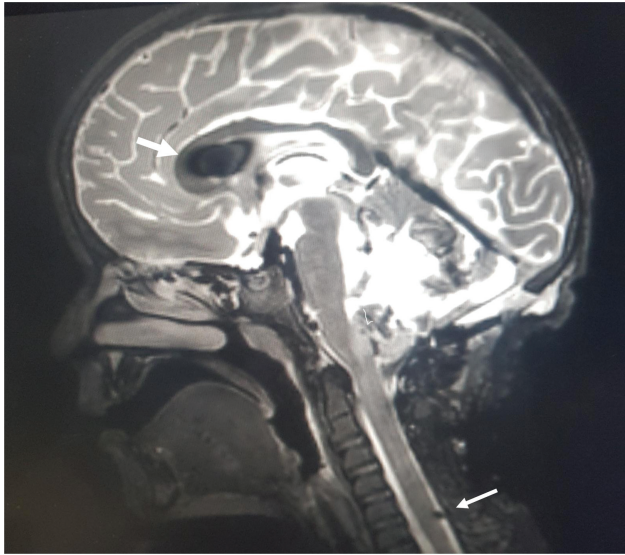
to entrainment of air (commonly known as inverted soda bottle effect) and could explain large pneumoventricle and pneumocephalus in our patient. Subarachnoid spaces in the intracranial and spinal compartments are essentially continuous spaces enabling spread of air from one compartment to another. As air tends to move upwards, position of the patient plays an important role in the direction of movement of air. There is ample evidence for such movement in the form of reports of pneumocephalus after spinal surgery and pneumorrhachis after skull fractures.<sup>3,4</sup> Migration of air through foramen magnum is the proposed mechanism of pneumorrhachis after traumatic skull fractures; the occurrence is especially noted in face-down position.<sup>4</sup> Restoring normocarbica, adequate hydration, flushing of subdural space with saline before a watertight dural closure can decrease the incidence of entrained air. Also, altering the patient's position such that the last dural stitch lies at the highest point is a suggested strategy to minimize the amount of air entrained.<sup>5</sup> In our patient, the position of the operating table was altered (head down, up, and lateral tilt to access all boundaries of the tumor) multiple times intraoperatively. This possibly facilitated the migration of air into the spinal canal. Albeit the theoretical possibility, it has been rarely described after elective intracranial surgery in prone position.<sup>6,7</sup> The sparsity in literature might be because the evidence for pneumorrhachis is seldom sought in cases of intracranial surgery, unless patients present with symptoms of cord compression without an apparent cause. The presence of air was noted as an incidental finding in our patient due to the accidental inclusion of sections of upper cervical spine during imaging. This makes one wonder if the incidence of pneumorrhachis in posterior fossa surgeries is more common than previously thought.

DOI <https://doi.org/10.1055/s-0042-1744394>.  
ISSN 2348-0548.

© 2022. Indian Society of Neuroanaesthesiology and Critical Care. All rights reserved.

This is an open access article published by Thieme under the terms of the Creative Commons Attribution-NonDerivative-NonCommercial-License, permitting copying and reproduction so long as the original work is given appropriate credit. Contents may not be used for commercial purposes, or adapted, remixed, transformed or built upon. (<https://creativecommons.org/licenses/by-nc-nd/4.0/>)

Thieme Medical and Scientific Publishers Pvt. Ltd., A-12, 2nd Floor, Sector 2, Noida-201301 UP, India



**Fig. 1** T2-weighted sequence of magnetic resonance imaging (sagittal section) showing pneumoventricle (thick arrow) and pneumorrhachis of cervical spine (thin arrow).

This case draws attention to the possibility of spinal cord compression due to pneumorrhachis after posterior fossa surgery. This makes it important to assess for cranial as well as spinal entrapped air after posterior fossa surgery. In case of new-onset motor deficits, the possibility of pneumorrhachis must be considered as one of the differential diagnoses

during evaluation. Diagnosis requires a high index of suspicion and inclusion of cervical spine during postoperative imaging.

#### Conflict of Interest

None declared.

#### References

- 1 Dimar JR II, Smail J, Carreon LY. Traumatic pediatric pneumorrhachis: case report and review of the literature. *Spine* 2010;35(17):E860–E863
- 2 Ould-Slimane M, Ettori MA, Lazennec JY, Pascal-Moussellard H, Catonne Y, Rousseau MA. Pneumorrhachis: a possible source of traumatic cord compression. *Orthop Traumatol Surg Res* 2010;96(07):825–828
- 3 Karavelioglu E, Eser O, Haktanir A. Pneumocephalus and pneumorrhachis after spinal surgery: case report and review of the literature. *Neurol Med Chir (Tokyo)* 2014;54(05):405–407
- 4 Goh BK, Yeo AW. Traumatic pneumorrhachis. *J Trauma* 2005;58(04):875–879
- 5 M Das J Bajaj J. Pneumocephalus. [Updated 2021 Jun 11]. In: StatPearls [Internet]. Treasure Island (FL): StatPearls Publishing; 2021 Jan-. Accessed December 12, 2021 at: <https://www.ncbi.nlm.nih.gov/books/NBK535412/>
- 6 Prabhakar H, Bithal PK, Ghosh I, Dash HH. Pneumorrhachis presenting as quadriplegia following surgery in the prone position. *Br J Anaesth* 2006;97(06):901–903
- 7 Ogul H, Pirimoglu B, Kantarci M. A very rare complication of the posterior fossa decompression surgery: lumbar pneumorrhachis. *Spine J* 2014;14(12):3060