



Anesthetic Implications of Nephrotic Syndrome in Neurosurgical Practice

Roshna C. Puthiyedath¹ Ashutosh Kumar¹ Ranganatha Praveen¹ Manikandan Sethuraman¹

¹Neuroanaesthesia Division, Department of Anaesthesiology, Sree Chitra Tirunal Institute for Medical Sciences and Technology, Trivandrum, Kerala, India

Address for correspondence Ranganatha Praveen, MD, DM, Department of Anaesthesiology, Neuroanaesthesia Division, Sree Chitra Tirunal Institute for Medical Sciences and Technology, Trivandrum, Kerala 695011, India (e-mail: drrrpcs@gmail.com).

J Neuroanaesthesiol Crit Care

Abstract

Nephrotic syndrome (NS) is a common medical disorder especially in pediatric population with hypoproteinemia as an important feature. NS has multisystem involvement and multiple organ effects due to the disease or the treatment itself, which has important implications in the perioperative period. Hypoproteinemia in NS can result in reduction in availability of protein binding sites for certain intravenous anesthetics, leading to their increased free fraction that can concentrate at the receptor sites, thereby prolonging their action. NS can have phases of relapse and remission with increased propensity for complications, such as thromboembolism during relapse phase. Such patients presenting for neurosurgery pose unique challenge to the anesthesiologist. We hereby report a case of NS and its implication in neurosurgical practice and management.

Keywords

- ▶ nephrotic syndrome
- ▶ steroid resistant
- ▶ idiopathic intracranial hypertension
- ▶ proteinuria

Introduction

Nephrotic syndrome (NS) is characterized by proteinuria, hypoalbuminemia, and edema, with annual incidence of 2 to 7/100000 in children and 3/100000 in adults.^{1,2} NS can involve multiple systems with cortical venous thrombosis and idiopathic intracranial hypertension (IIH) as neurological manifestations.^{3,4} However, to the best of our knowledge, anesthetic implications of NS patients for neurosurgery are not previously described. We report anesthetic concerns among these subsets in an adult patient for the surgical management of benign intracranial hypertension.

Case Report

A 33-year-old female, weight 70 kg, height 142 cm, with body mass index (BMI) of 34.72, a known case of NS for the last 6 years presented with severe headache and increased

episodes of visual blurring for a week. Her baseline heart rate was 70/min, blood pressure (BP) 130/86 mm Hg, and Glasgow coma score 15, without any neurological deficits. Albuminuria—30 mg/dL—(normal <10 mg/dL) was present, with erythrocyte sedimentation rate—11 mm/h, platelet—2,50,000, D-dimer—300 ng/mL, prothrombin time—14 seconds, activated partial thromboplastin time—33 seconds, international normalized ratio—0.91, serum creatinine—1.0 mg/dL, serum sodium—135 mEq/L, potassium—4.2 mEq/L, and other normal laboratory values. Her bilateral lower limb Doppler ultrasound examination was normal.

Six months ago, she presented with similar complaints (though milder) with cerebrospinal fluid (CSF) pressure of 36 cmH₂O on acetazolamide with albuminuria—1,000 mg/dL and preserved renal functions. Her renal biopsy showed membranous glomerulonephritis. She was diagnosed to have NS relapse and was started on tacrolimus as she had

DOI <https://doi.org/10.1055/s-0042-1744400>.
ISSN 2348-0548.

© 2022. Indian Society of Neuroanaesthesiology and Critical Care. All rights reserved.

This is an open access article published by Thieme under the terms of the Creative Commons Attribution-NonDerivative-NonCommercial-License, permitting copying and reproduction so long as the original work is given appropriate credit. Contents may not be used for commercial purposes, or adapted, remixed, transformed or built upon. (<https://creativecommons.org/licenses/by-nc-nd/4.0/>)

Thieme Medical and Scientific Publishers Pvt. Ltd., A-12, 2nd Floor, Sector 2, Noida-201301 UP, India

developed steroid resistance. CSF pressure reduction surgery was rescheduled after attaining remission and acetazolamide dose was increased. She achieved remission with rituximab after 3 months. Also, 2 years back she had complaints of mild headache and occasional visual blurring with CSF pressure of 30 cmH₂O and was on regular follow-up since then. Presently, her magnetic resonance imaging (MRI) brain showed mild tortuosity of optic nerves (→ Fig. 1). Her BP was optimized with telmisartan for the last 5 years. She had short neck and Mallampati grade of 3 upon airway examination. Lumboperitoneal shunt with endoscopic transnasal optic nerve fenestration surgery was planned.

With adequate fasting and standard monitoring, anesthesia was induced with intravenous (iv) fentanyl 200 µg, propofol 100 mg, and atracurium 35 mg under hydrocortisone cover. C-MAC videoscope facilitated endotracheal intubation after which throat pack was placed. Anesthesia was maintained with 1:1 oxygen/air mixture, desflurane (0.8–1 MAC), fentanyl, and atracurium infusion. Left radial arterial line monitored hemodynamics, blood gases, and electrolytes. Antibiotic prophylaxis and lower limb intermittent pneumatic compression device placement was ensured.

Following induction of anesthesia BP dropped to 88/52 mm Hg, resistant to multiple boluses of mephentermine and intravenous fluids, requiring noradrenaline through brachial peripherally inserted central catheter (PICC) to maintain BP. Ringer lactate (RL) and normal saline were used alternately. Ventilation was adjusted real time to ensure normocarbica. Patient was carefully positioned left lateral for lumboperitoneal shunt with adequate padding of all pressure points and subsequently supine for endoscopic optic nerve fenestration. Surgery was uneventful and patient was extubated once fully awake. Noradrenaline was stopped

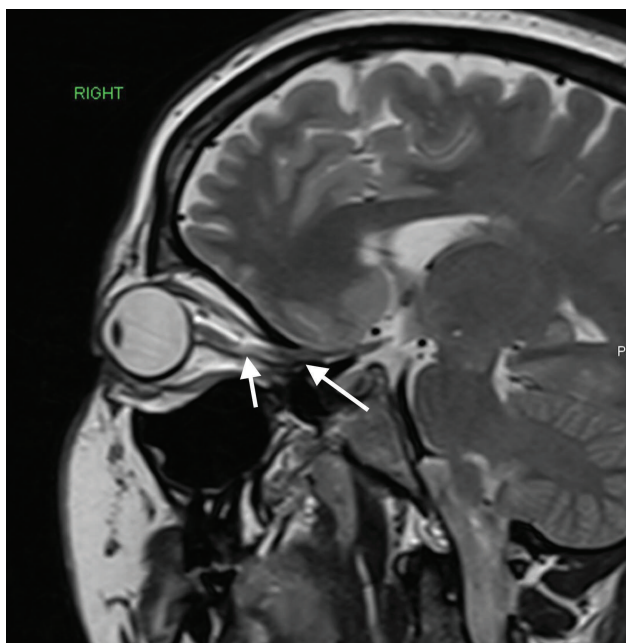


Fig. 1 Magnetic resonance imaging brain showing mild tortuosity of optic nerve.

and PICC was removed 6 hours later. Her neurologic status was same as preoperative with good recovery.

Discussion

NS is usually managed with steroids and other immunosuppressants. Systemic manifestations include hypertension, hyperlipidemia, restricted cardiomyopathy, pleural effusion, chronic kidney disease, seizures, cerebral venous thrombosis, IIH, posterior reversible encephalopathy syndrome.^{3,5} Also paraneoplastic NS is described in a patient with meningioma who achieved remission following surgery.⁶ IIH (headache, papilledema, raised CSF pressure) can occur in NS associated renal failure, corticosteroids, or cyclosporine therapy more common in fertile obese females,^{5,7,8} similar to our patient. CSF pressure reduction either medically, serial lumbar punctures, or surgery would preserve vision.

Renal loss of plasma hemostatic proteins, increased production of prothrombotic factors by liver, and genetic association (antithrombin deficiency) make NS a prothrombotic state, especially during relapse and steroid resistance.⁵ Cerebral thromboembolism also occurs during relapse in this cohort. Also, occurrence of thromboembolism is more common in adults (26.7%) as compared with pediatric nephrotic population (1.8–5.3%).¹ Hence, avoiding elective neurosurgeries during NS relapse phase would prevent perioperative thromboembolic complications, considering the possible postoperative initiation delay of pharmacoprophylaxis in them. Chronic steroids can cause hypernatremia, hypertension, hypokalemia, thromboembolism, and infections³ Galloway-Mowat syndrome with facial dysmorphism, hypotonia, seizure is a rare association of NS.⁹

Maintaining cerebral perfusion, fluid-electrolyte balance, renal protection, steroid supplementation for stable hemodynamics are anesthetic goals. Fentanyl, propofol, etomidate (without free metabolites, short redistribution) and isoflurane, and desflurane are safely used. Effect of benzodiazepines and thiopentone is prolonged due to their increased free fraction secondary to hypoalbuminemia.³ Edema and steroid treatment-induced difficult intravenous access, acetazolamide-related metabolic acidosis, steroid-related osteoporosis are few other concerns. Diuretics, alternating normal saline with RL, can prevent further sodium overload and for osmotherapy mannitol is used.² Difficult airway, secondary to chronic steroid use or syndromic association, requires video laryngoscope for intubation and supraglottic devices in the MRI suite. Some patients have antithrombin III deficiency causing heparin resistance, and pose great challenge during digital subtraction angiography.⁵ Intraoperative antifibrinolytics commonly used in neurosurgery to minimize blood loss are not an option here, as they can induce tubular proteinuria.³ Central venous catheters can be thrombogenic in already existing prothrombotic state and hence used only for specific indication and duration.⁵ Rapid sodium fluctuations can contribute to seizures. Hence, its serial monitoring and timely modification of antiepileptic dosages reduce perioperative seizure frequencies.

Our patient who was steroid resistant, with high BMI, short neck, different surgical positions, was at a high risk of thromboembolic events, difficult airway, and osteoporosis. Her surgery was rescheduled after she attained remission. In general, such patients are considered to have achieved remission from relapse when there is more than 50% reduction in proteinuria and edema has subsided, which cannot be applied for emergency procedures.¹⁰ However, our patient was on medical treatment with lumbar puncture performed during her relapse. Moreover, generalized edema including ascites can cause difficulty in shunt placement in abdomen and abdominal compression that can compromise urine output in lateral position. We used mechanothromboprophylaxis device, renal safe medications, C-MAC for intubation, optimized electrolytes and carefully padded pressure points to mitigate the risks. Refractory hypotension here could be secondary to use of telmisartan.

Conclusion

Avoiding elective neurosurgery during relapse phase, till remission of NS, and optimizing electrolyte, volume status, renal parameters, and BP are the key for safe anesthesia and prevention of perioperative complications in NS patients for neurosurgery.

Conflict of Interest

None declared.

References

- 1 Stabouli S, Chrysaidou K, Kupferman JC, Zafeiriou DI. Neurological complications in childhood nephrotic syndrome: a systematic review. *Eur J Paediatr Neurol* 2019;23(03):384–391
- 2 Hull RP, Goldsmith DJA. Nephrotic syndrome in adults. *BMJ* 2008; 336(7654):1185–1189
- 3 Datt V, Tempe DK, Arora K, Virmani S, Joshi CS, Agarwal S. Anesthetic management of a child with nephrotic syndrome undergoing open heart surgery: report of a rare case. *Ann Card Anaesth* 2012;15(04):305–308
- 4 Barnett M, Sinha MD, Morrison D, Lim M. Intracranial hypertension presenting with severe visual failure, without concurrent headache, in a child with nephrotic syndrome. *BMC Pediatr* 2013;13:167
- 5 Rener-Primec Z. Neurological complications in nephrotic syndrome - could they be prevented? *Eur J Paediatr Neurol* 2019;23(03):342–343
- 6 Sardhara J, Shukla M, Jamdar J, et al. Paraneoplastic nephrotic syndrome in a patient with Planum Sphenoidale Meningioma. *Asian J Neurosurg* 2018;13(03):864–866
- 7 Fischbach ADScholz-Hehn, Gerloff C, et al. Case series of idiopathic intracranial hypertension in three patients with immune-complex glomerulonephritis. *BMC Neurol* 2021;21:278
- 8 Costa KM, Almeida JB, Félix RH, Silva Júnior MF. [Pseudotumor cerebri associated with cyclosporin use following renal transplantation]. *J Bras Nefrol* 2010;32(01):136–139
- 9 Lin PY, Tseng MH, Zenker M, et al. Galloway-Mowat syndrome in Taiwan: OSGEP mutation and unique clinical phenotype. *Orphanet J Rare Dis* 2018;13(01):226
- 10 Polanco N, Gutiérrez E, Covarsí A, et al; Grupo de Estudio de las Enfermedades Glomerulares de la Sociedad Española de Nefrología. Spontaneous remission of nephrotic syndrome in idiopathic membranous nephropathy. *J Am Soc Nephrol* 2010;21(04):697–704