



Establishment of a Percutaneous Nephrostomy Service to Treat Obstructive Uropathy Secondary to Cervical Cancer in Tanzania

Ivan Rukundo¹ Erick M. Mbuguje¹ Azza Naif¹ Manish Patel² Fabian Laage-Gaupp³
Murray Asch⁴ Vijay Ramalingam⁵

¹ Department of Radiology, Muhimbili University of Health and Allied Sciences, Dar es Salaam, Tanzania

² University of Illinois College of Medicine, Chicago, Illinois, United States

³ Department of Radiology and Biomedical Imaging, Yale School of Medicine, New Haven, Connecticut, United States

⁴ Diagnostic and Interventional Radiology, Lakeridge Health Corporation, Oshawa, Ontario, Canada

⁵ Division of Interventional Radiology, Beth Israel Deaconess Medical Center, Boston, Massachusetts, United States

Address for correspondence Ivan Rukundo, MD, MMED, Department of Radiology, Muhimbili University of Health and Allied Sciences, Dar es Salaam, Tanzania (e-mail: ivanruk7@gmail.com).

Arab J Intervent Radiol 2022;6:33–36.

Abstract

Background Cervical cancer is the fourth most common cancer among women globally. Age-standardized cervical cancer mortality is higher in East Africa than anywhere else in the world. Prior to October 2018, patients presenting with obstructive uropathy secondary to late-stage cervical cancer in Tanzania who were no longer eligible for palliative chemoradiation therapy were discharged home without intervention. The purpose of this study was to evaluate whether the establishment of a percutaneous nephrostomy service in a quaternary hospital in Dar es Salaam, Tanzania, a resource-limited country, benefits patients who have late-stage cancer induced obstructive uropathy.

Materials and Methods A retrospective study was performed on patients who presented with obstructive uropathy secondary to late-stage cervical cancer and have undergone percutaneous nephrostomy at Muhimbili National Hospital and Ocean Road Cancer Institute from October 2018 to May 2021. Twenty-one interventional radiology (IR) teaching teams consisting of IR attendings, IR technologists, and nurses travelled to Tanzania from North America on monthly 2-week trips during that period. A review of preprocedural, procedural, and follow-up data was performed using Research Electronic Data Capture. Statistical analysis and comparison were performed on patients' creatinine levels preprocedure, 7 days and 30 days postprocedure.

Results Sixty-two patients qualified to be included in this study. In addition to the initial 62 nephrostomy placements, 14 follow-up procedures were performed either under visiting faculty supervision or independently by the Tanzanian IR fellows.

Keywords

- ▶ percutaneous nephrostomy
- ▶ creatinine
- ▶ chemotherapy
- ▶ obstructive uropathy
- ▶ cervical cancer

published online
April 20, 2022

DOI <https://doi.org/10.1055/s-0042-1744507>.
ISSN 2542-7075.

© 2022. The Pan Arab Interventional Radiology Society. All rights reserved.

This is an open access article published by Thieme under the terms of the Creative Commons Attribution-NonDerivative-NonCommercial-License, permitting copying and reproduction so long as the original work is given appropriate credit. Contents may not be used for commercial purposes, or adapted, remixed, transformed or built upon. (<https://creativecommons.org/licenses/by-nc-nd/4.0/>)

Thieme Medical and Scientific Publishers Pvt. Ltd., A-12, 2nd Floor, Sector 2, Noida-201301 UP, India

Technical success rate was 98.7%. Complications (SIR Class A and B) occurred in eight cases. The average preprocedure creatinine ($1051.48 \pm 704.08 \mu\text{mol/L}$) decreased by 59% 7 days postprocedure and by 77% 30 days postintervention. Postprocedural clinical information was obtained for 28 (45.2%) patients and 18 were able to restart chemotherapy following nephrostomy.

Conclusion Prior to 2018, percutaneous nephrostomy placement was not available in Tanzania. This study presented the initial safety, technical feasibility, and clinical benefit of establishing a percutaneous nephrostomy service in such a resource-limited setting.

Introduction

Cervical cancer is the fourth most common cancer among women globally. It is the leading cause of gynecological cancer-related deaths in sub-Saharan Africa, Central America, and South-Central Asia.¹ The estimated age-standardized rate of cervical cancer mortality in East Africa is higher than any other region in the world.² Most cervical cancer patients in Tanzania present in an advanced stage of the disease due to the lack of a national screening program, human papillomavirus vaccination inaccessibility, and limited pathology expertise in early diagnosis of cervical dysplasia.³

Patients with advanced stage cervical cancer present with a wide range of complications and morbidities including renal failure caused by obstruction.⁴ In addition to electrolyte abnormalities such as hyperkalemia, patients might also present with sepsis. These factors can preclude patients from receiving systemic chemotherapy.^{5,6}

Prior to 2018, the only treatment option for patients with advanced stage cervical cancer complicated by obstructive uropathy in Tanzania was retrograde placement of ureteral stents by urologists. However, this is often not successful in the setting of pelvic masses.^{7,8} In 2018, an interventional radiology (IR) program in Muhimbili National Hospital (MNH) provided patients with more therapeutic options including percutaneous nephrostomy. In this study, we reviewed the feasibility, safety, and initial results of percutaneous nephrostomy services to treat patients with obstructive uropathy secondary to late-stage cervical cancer in this resource-limited setting by studying procedural complications and patient outcomes.

Methods

A retrospective study was conducted on patients who presented with obstructive uropathy secondary to late-stage cervical cancer at MNH and Ocean Road Cancer Institute in Dar es Salaam, Tanzania, and had nephrostomy placements from October 2018 to May 2021.

During this time, a total of 21 teaching teams consisting of an interventional radiologist, an IR technologist, and an IR nurse traveled to Tanzania mainly from North America and South Africa on 2-week monthly teaching trips. A 2-year

Master of Science in IR program was established in the nation's main public medical university, modeled after IR training curricula in the United States.

Procedures were performed by Tanzanian IR fellows, initially exclusively under the supervision of visiting IR faculty, and later supervised or unsupervised. All patients involved consented and agreed to participate in the study. All laboratory data was collected from the Hospital Management Information System, procedural, and postprocedural data was collected using Research Electronic Data Capture (REDCap 8.7.1 - ©2021 Vanderbilt University), a web-based Health Insurance Portability and Accountability Act of 1996 (HIPAA) compliant data management software managed by MNH.

Data was categorized into baseline data, procedure information, postprocedure, and outcomes data. The baseline data consisted of patient's demographic information, comorbidities, baseline laboratory workup, procedure indication, referral source, and the treatment status. Postprocedure and outcomes data consisted of postprocedure complications as defined by the Society of Interventional Radiology, follow-up laboratory workup such as creatinine at 1 week and 1 month, and the treatment status after the procedure was measured.⁹

Ceftriaxone (1 g intravenous [IV]) and metronidazole (500 mg IV) were administered 30 minutes prior to the procedure for any patient who was not already on antibiotics. Patients received moderate sedation using IV fentanyl and midazolam based on overall condition, weight, and procedure length. Access to the renal collecting system was obtained with the patient in a prone position via posterior inferior calyces using 18/21/22 Gauge needles under ultrasound and fluoroscopic guidance. After confirming adequate access by contrast injection, this was converted to an 0.035-inch system and 8 to 10 French drainage catheters were placed. Tubes were connected to drainage bags and sutured at the skin using 2-0 nonabsorbable Nylon sutures. Tube exchanges were performed every 2 to 3 months on a routine basis or whenever a tube was found to be obstructed or dislodged.

Statistical analysis to calculate the mean, standard deviation, and two-tailed *p*-test was performed using Microsoft Excel (Microsoft Corporation, Redmond, Washington, United States). In addition, Microsoft Excel was used to generate all charts included in this manuscript.

Results

From October 2018 to May 2021, 62 patients who underwent nephrostomy procedures were included in this study. In addition to the 62 initial nephrostomy procedures, 14 follow-up procedures including routine nephrostomy tube exchanges and tube exchanges due to tube-related complications were also performed, which makes a total of 76 procedures. Of those, 49 procedures (64.5%) were performed under supervision of visiting faculty and 27 procedures (35.5%) were performed independently by the Tanzanian IR fellows. The average patient age was 49.8 ± 11.13 years. 69/76 (90.8%) did not have any intraprocedural complication; minor complications (SIR Class A and B) occurred in seven cases. These complications included hematoma in six procedures (9.7%) and one unilateral placement failure (1.6%). No major complications were recorded. Seventy-five of seventy-six procedures (98.7%) were technically successful.

Indications for nephrostomy placements for patients include obstructive renal failure, urosepsis, pain, and vesicovaginal fistula (►Table 1). Thirty-day postprocedure complications include tube site infections, dislodged tubes, and tube blockage (►Table 2).

Preprocedure creatinine level was obtained in 39/62 (62.9%) patients with an average of $1051.48 \mu\text{mol/L}$ (704.08). Seven days postprocedure creatinine level was obtained in 25 (40.3%) patients with an average of $429.30 \mu\text{mol/L}$ (408.87), 59% decrease compared with baseline. Thirty postprocedure follow-up creatinine was obtained in 26 (41.9%) patients with an average of $240.14 \mu\text{mol/L}$ (192.79); 77% decreased compared with baseline. Data analysis was performed on 15 patients who had all three sets of creatinine data recorded (►Fig. 1).

Continuous patients follow-up were obtained in 28 patients. One patient initiated chemotherapy, while 18 patients resumed chemotherapy following nephrostomy placement.

Table 1 Procedure indications

Characteristics of patient population, <i>n</i> = 62		
Indications	<i>N</i>	%
Obstructive renal failure	42	66.7
Urosepsis	15	24.2
Pain	3	4.8
Vesicovaginal fistula	2	3.2

Table 2 Thirty follow-up complications

30-day patient procedure outcome/complications *** 35 patients were lost to follow-up		
Complication	<i>N</i>	%
Tube site infection	6	9.7
Dislodged tube	2	3.2
Tube blockage	2	3.2

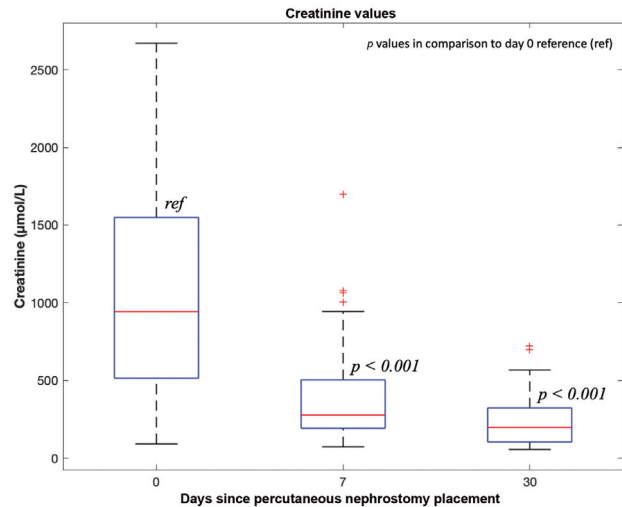


Fig. 1 Creatinine values before percutaneous nephrostomy (day 0), creatinine values after 7 days, and creatinine values after 30 days.

Discussion

Cervical cancer continues to be a leading cause of cancer-related mortality in East Africa and specifically in Tanzania. Several reasons for the current state of cervical cancer mortality in the region have been documented including lack of national screening, immunization, and medical expertise in diagnosis of early-stage cervical cancer. In addition, there is lack of formal education and awareness surrounding cervical cancer, lack of health care insurance, and fear of attending formal healthcare facilities.³

The introduction of IR in 2018 in Tanzania added percutaneous nephrostomy as an option for the treatment of obstructive uropathy in patients with advanced cervical cancer.¹⁰ Prior to this program, the only nonsurgical method of urinary diversion was retrograde ureteric stent placement by urology. However, given the anatomic distortion and pelvic masses that are typically found in patients with advanced cervical cancer, retrograde stent placement is usually not possible. As a result of renal failure and sepsis, patients with advanced cervical cancer were often not candidates for chemotherapy and were discharged to the community to die at home. The addition of a percutaneous nephrostomy service to the repertoire of Interventional Radiology Services at MNH has been found to be valuable in potentially improving survival length and improving treatment options.

In this study, we document the early clinical impact of this newly established service on 62 patients who had percutaneous nephrostomy from October 2018 to May 2021. A total of 76 procedures were performed including 62 initial procedures and 14 follow-up procedures. We demonstrated a high technical success rate with only one procedure unable to be completely performed. In this case, only unilateral access was obtained rather than the originally planned bilateral access. Furthermore, while limited in patient follow-up, the results of our study clearly demonstrate a steady

improvement in renal function over time at both 7 and 30 days in those patients who were able to obtain follow-up laboratories. However, this study demonstrated a slightly higher complication rate following nephrostomy tube placement on follow-up 10/62 (16.1%) compared with the published literature in Eastern Europe.¹¹ While this deserves future attention, possible reasons for this are the continued development of the service line and lack of experience, lack of long-term follow-up, and the need for better postprocedural protocols to ensure that patients have adequate training, skin care, and supplies for dressing changes and follow-up. Finally, in addition to the significant effects of improving renal function in our patient cohort, we were able to demonstrate that since the addition of this service line, patients with prior renal failure caused by advanced cervical cancer were able to initiate or resume chemotherapy after the procedure, hence a chance of prolonging life.

The results of this data demonstrate the initial safety and feasibility of establishing a percutaneous nephrostomy drainage service in a country where it has not been previously available. The rates of technical success with graduated independence and no major complications shown in this study demonstrate a safety profile similar to large North American and European studies.^{12,13} In addition, our early data suggests that the establishment of the program has led to significant improvements in renal function and eligibility for chemotherapy.

There are several limitations to this study. There were a high number of patients that were lost to follow-up due to poor electronic medical records and network infrastructure between partner institutions like MNH and Ocean Road Cancer Institute. Follow-up of patients was also a challenge due to limited human resources, lack of a reliable electronic patient follow-up system, and logistical challenges for patients in a resource-limited setting traveling long distances to see providers. Another major challenge encountered in the establishment of this program is the timely and consistent procurement of IR equipment and supplies. Early in our experience equipment availability depended on donated supplies as our supply chain was being established. This delayed tube exchanges and sometimes led to lack of service in times when there were no nephrostomy tubes.

Conclusion

Percutaneous nephrostomies were not available in Tanzania prior to 2018. We have demonstrated the feasibility of establishing a sustainable percutaneous nephrostomy service in a safe and effective manner in a resource-limited setting.

This study highlights the next emphasis of the Tanzania Interventional Radiology Program including developing a robust follow-up system and continuing to expand the services offered by the Interventional Radiology Department to help manage the growing number of patients at MNH.

Conflict of Interest

None declared.

Acknowledgments

The authors wish to specially acknowledge Rae Ruixue Zhang for her invaluable contribution in proofreading the final manuscript.

References

- Arbyn M, Weiderpass E, Bruni L, et al. Estimates of incidence and mortality of cervical cancer in 2018: a worldwide analysis. *Lancet Glob Health* 2020;8(02):e191–e203
- Ntekim A. Cervical Cancer in Sub Sahara Africa. Topics on Cervical Cancer with an Advocacy for Prevention. 2012. Doi: 10.5772/27200
- Runge AS, Bernstein ME, Lucas AN, Tewari KS. Cervical cancer in Tanzania: a systematic review of current challenges in six domains. *Gynecol Oncol Rep* 2019;29:40–47
- Mlange R, Matovelo D, Rambau P, Kidenya B. Patient and disease characteristics associated with late tumour stage at presentation of cervical cancer in northwestern Tanzania. *BMC Womens Health* 2016;16:5
- Hsu L, Li H, Pucheril D, et al. Use of percutaneous nephrostomy and ureteral stenting in management of ureteral obstruction. *World J Nephrol* 2016;5(02):172–181
- van Aardt MC, van Aardt J, Mouton A. Impact of percutaneous nephrostomy in South African women with advanced cervical cancer and obstructive uropathy. *Southern African Journal of Gynaecological Oncology* 2017;9(01):6–10
- Santosa KB, Prawira MM, Pramana IBP, et al. Predictor of successful DJ stent insertion in advanced cervical cancer. *Open Access Maced J Med Sci* 2020;8(B):882–886
- Mishra K, Desai A, Patel S, Mankad M, Dave K. Role of percutaneous nephrostomy in advanced cervical carcinoma with obstructive uropathy: a case series. *Indian J Palliat Care* 2009;15(01):37–40
- Khalilzadeh O, Baerlocher MO, Shyn PB, et al. Proposal of a new adverse event classification by the Society of Interventional Radiology Standards of Practice Committee. *J Vasc Interv Radiol* 2017;28(10):1432–1437.e3
- Laage Gaupp FM, Solomon N, Rukundo I, et al. Tanzania IR initiative: training the first generation of interventional radiologists. *J Vasc Interv Radiol* 2019;30(12):2036–2040
- Turo R, Horsu S, Broome J, et al. Complications of percutaneous nephrostomy in a district general hospital. *Turk J Urol* 2018;44(06):478–483
- Li AC, Regalado SP. Emergent percutaneous nephrostomy for the diagnosis and management of pyonephrosis. *Semin Intervent Radiol* 2012;29(03):218–225
- New FJ, Deverill SJ, Somani BK. Outcomes related to percutaneous nephrostomies (PCN) in malignancy-associated ureteric obstruction: a systematic review of the literature. *J Clin Med* 2021;10(11):2354