Article published online: 2022-07-05

Endosonography-Guided Caudate Lobe Liver Abscess Drainage: A Case and Review of Methods

Shankar Zanwar[1] Amit Agrawal[2]

[1] Department of Gastroenterology, Care Hospitals, Nagpur, India
[2] Department of Gastroenterology, Disha Clinics, Nagpur, India

Address for correspondence Shankar Zanwar, MD, DNB, Gastroenterologist, Care Hospitals Nagpur, India (e-mail: shankar.jhanwar@gmail.com).

J Digest Endosc 2022;13:119–124.

Abstract

There are only 11 cases of caudate lobe liver abscess drainage described in the published literature. We present a case of liver abscess drainage done by endosonography (EUS) and review of various EUS-guided liver abscess drainage techniques and endoprostheses. Here we have aimed at reviewing the data for paving the way for the development of a consensus for liver abscess drainage.

Keywords
- endosonography
- liver abscess drainage
- percutaneous drainage

A 70-year-old retired male patient presented with pain in the abdomen and fever of 8 days in April 2021. Laboratory evaluation showed neutrophilic leukocytosis (total leukocyte count [TLC]: 28,000). Ultrasonography (USG) abdomen showed space-occupying lesion (SOL) in the caudate lobe of the liver. For further characterization of the mass contrast-enhanced computerized tomography (CECT) abdomen was done on next day after the creatinine normalized with hydration. CECT abdomen showed a deep-seated liver abscess in the caudate lobe of the liver of size 6 × 5 × 6 cm (►**Fig. 1**).

Because the patient was in sepsis, drainage of the abscess was needed. A multidisciplinary discussion was held and surgical drainage was considered as the preferred choice because percutaneous access in the abscess had to traverse a longer distance. Vascular and biliary structures were coming in the path of needle tract if CT-guided drainage was done. The patient was explained the need for surgery but he refused surgery. Thus, endosonography-guided access was planned.

On EUS (►**Fig. 2**), there was a large hypoechoic SOL in the caudate lobe of size 6 × 5 × 6 cm. Walls of the lesions were well-defined and thick with a rim of liver parenchyma of around 1 cm near the gastric end. There were no calcifications, large vessels crossing the SOL. The lesion was punctured from the transgastric route with 19-gauge Olympus EZ shot needle. Fluid aspirated (►**Fig. 3**) from the SOL was purulent in appearance, which was sent for microscopy and culture. Nearly 20 mL of thick aspirate could be suctioned. A guidewire was inserted through the needle and then the tract was dilated with 6 Fr cystotome. This was further dilated with 6 mm Hurricane balloon. Another guidewire was inserted alongside the previous guide wire. A 7 Fr × 5 cm double pigtail plastic stent was inserted and through the second guidewire, naso-abscess drain (7Fr) was placed and left for continuous drainage attached to a uro-bag. Post procedure on the second day, nearly 70 mL of pus was collected in the bag and later in next 3 days pus drainage gradually stopped. Meanwhile from the post procedure day 2, the patient stopped having fever spikes. His TLC steadily showed improving trend and day 4 post procedure, it reduced to 13,000 cmm^3. Because the drainage and fever spikes had stopped, the naso-abscess drain was cut near the nasal end and internalized using a forward-viewing endoscope and left in the stomach.

The blood and abscess aspirate cultures were sterile, *Entamoeba histolytica* serology was positive. Metronidazole was continued for 3 weeks (initially IV then oral). The patient was discharged asymptomatic on day 5 post procedure. He was asymptomatic later. Blood tests including hemogram and transaminases were normalized after 4 weeks. Both stent and drain were removed. CECT abdomen done to see for status

DOI https://doi.org/10.1055/s-0042-1747912.
ISSN 0976-5042.

© 2022. Society of Gastrointestinal Endoscopy of India. All rights reserved.
This is an open access article published by Thieme under the terms of the Creative Commons Attribution-NonDerivative-NonCommercial-License, permitting copying and reproduction so long as the original work is given appropriate credit. Contents may not be used for commercial purposes, or adapted, remixed, transformed or built upon. (https://creativecommons.org/licenses/by-nc-nd/4.0/)
Thieme Medical and Scientific Publishers Pvt. Ltd., A-12, 2nd Floor, Sector 2, Noida-201301 UP, India

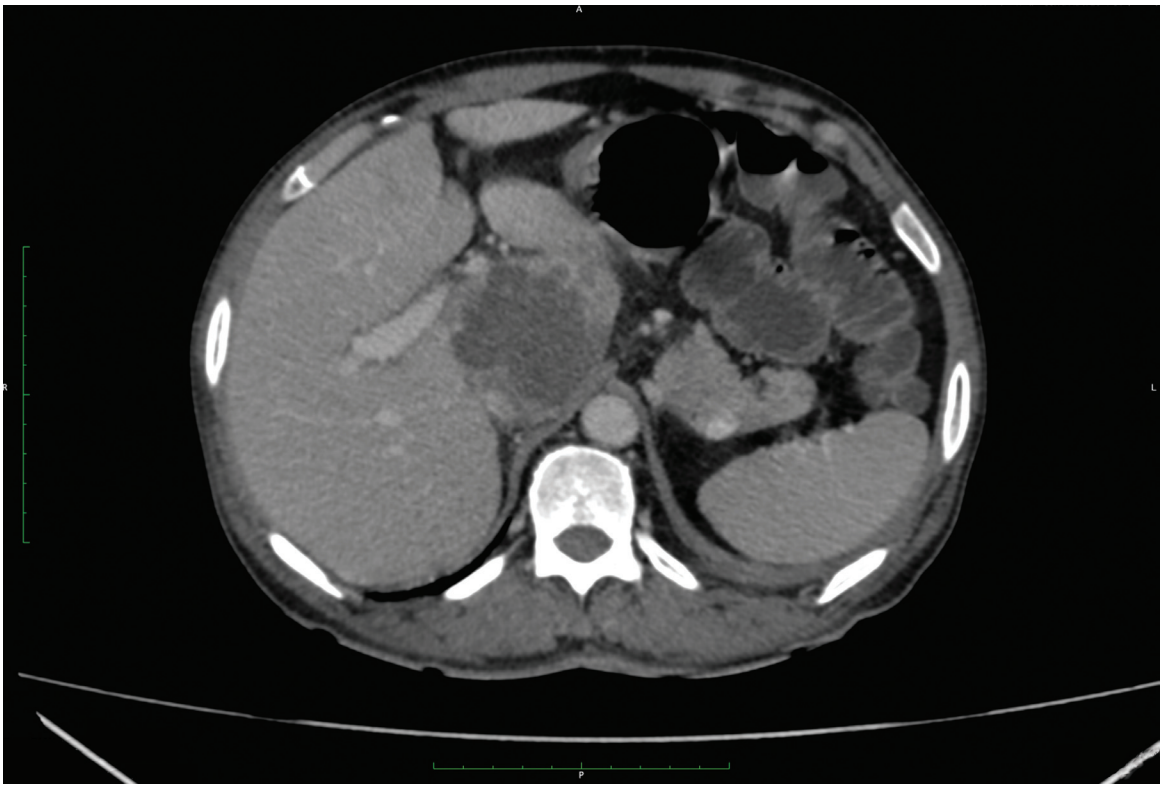

Fig. 1 CECT abdomen showing abscess in the caudate lobe.

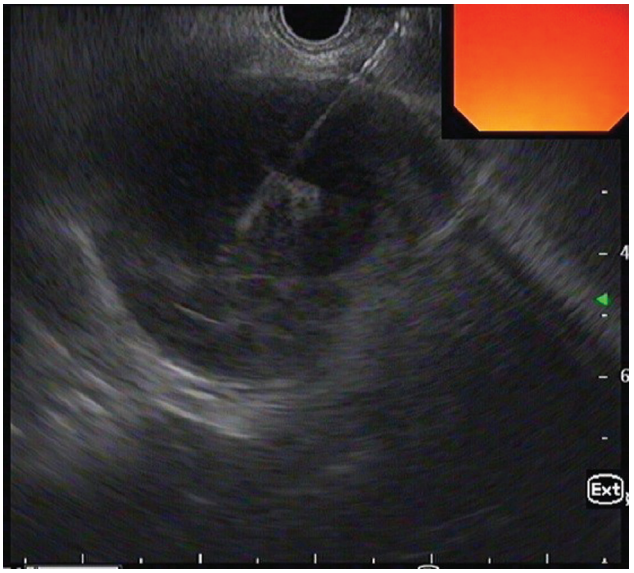

Fig. 2 EUS image showing the abscess.

of the abscess after 6 weeks of EUS drainage showed complete resolution of the abscess.

Discussion

Liver abscess has been noted since at least last 2500 years, when Hippocrates had described it as a blister in the liver associated with fever, pus accumulation, and death.[1] Treatment of liver abscess as drainage, was well known since the

Fig. 3 Pus being aspirated from the abscess with EUS image in the background.

 © 2022. Society of Gastrointestinal Endoscopy of India. All rights reserved.

Table 1 Compilation of all the published cases of EUS guided liver abscess drainage

Study, location	Indications	Number of cases	Location of Abscess	Approach	Endoprosthesis for drainage	Complication	Removal of drainage accessory
Seewald et al. (2005), Germany[3]	Failed ABX therapy (1 week)	1	Lateral segment of left lobe	Proximal TG	7F NAC	None	7 days
Ang et al. (2009), Singapore[4]	Failed ABX and PCD (ruptured)	1	Left subhepatic space collection	TG	8F and 10F × 7cm DPS	None	11 days
Noh et al. (2010), Korea[5]	Failed ABX and PCD	1	Gastrohepatic space	TG	7F DPS	None	6 weeks (mean)
	Failed ABX and PCD	1	Caudate lobe of liver	TG	7F DPS	None	
	Failed ABX and inaccessible to PCD	1	Caudate lobe of liver with portacaval extension	TD	2 7F DPS with NAC	None	
Itoi et al. (2011), Japan[6]	Failed ABX and PCD (TB)	1	Between pancreas and caudate lobe of liver	TD	7F SS and 5F NAC	None	**
	Failed ABX and PCD (TB)	1	Caudate lobe	TG	7F DPS and 5F NAC	None	
Keohane et al. (2011)[7]	Failed ABX and PCD	2	Caudate lobe (2)	TG	7F DPS	None	8 weeks
				TG	10F DPS	None	
Ivanina et al. (2012)[8]	Failed ABX and PCD	1	Caudate lobe	TG	NAC	NAC traversing the esophagus, new para-esophageal collection	**
Medrado et al. (2013)[9]	Upfront EUS drainage	1	Left lobe	TG	PCSEMS, 60 × 10 mm	Stent migration in the abscess 2weeks, 10Fr DPS inserted within SEMS	8 weeks
Alcaide et al. (2013)[10]	Upfront EUS drainage	1	Left lobe	TG	LAMS (Axios 10 × 10 mm)	None	3 months
Kawakami et al. (2014)[11]	Upfront EUS drainage	1	Left lobe	TG	BFMS (Nagi 16 × 30 mm)	None	**
Koizumi et al. (2014)[12]	Failed ABX no percutaneous access	1	Left lobe	TG	5F NAC	None	2weeks
Kodama et al. (2015)[13]	Failed ABX	1	Left lobe	TG	6 Fr NAC inadvertent removal later replaced by FCSEMS 10 mm x 120 mm	None	**
Ogura et al. (2016)[14]	Failed PCD/self PCD removal	8	Left lobe (6)	TG (6)	FCSEMS (10 mm x 6, 8, 12 cm), 7 Fr DPS inserted in the stent	None	**
			Right lobe (2)	TD (2)	FCSEMS	None	
Tonozuka et al. (2015)[15]	Failed ABX and PCD	7	Left lobe (6)	TG (6)	FCSEMS (16 mm x 2 cm for lesion near the	None	Removed in 2 out of 7 cases

(*Continued*)

 © 2022. Society of Gastrointestinal Endoscopy of India. All rights reserved.

Table 1 (*Continued*)

Study, location	Indications	Number of cases	Location of Abscess	Approach	Endoprosthesis for drainage	Complication	Removal of drainage accessory
					wall and 10 mm 6–8 cm for lesions away from wall)		
			Right lobe (1)	TD (1)	FCSEMS	None	
Yamamoto et al. (2017)[16]	Failed ABX and Chilaiditi	1	Right lobe	TD	5-F NAC, internalized after 6 days	None	**
Carbajo Lopez et al. (2019)[17]	Failed PCD	9	Left lobe (3)	TG (3)	FCSEMS (60 × 10 and 40 × 10 mm)	1 bleed and 1 perforation - managed conservatively	In 50% of cases after a mean of 92 days
			Right lobe (6)	TD (6)	LAMS (2) (10 × 10 mm and 10 × 15 mm)	None	
Rana et al. (2020), India[18]	Difficult PCD access	11	Left lobe	TG(10)	Two 7F DPS	1 repeat procedure and exchange of stent	6 weeks
		3	Caudate lobe	TE(4)		None	
Chandra et al.(2021), India[19]	Ruptured abscess	1	Caudate	TG	8F DPS and 8 F NAC, active aspiration with biliary dilator before stenting	None	8weeks - 3months
		2	Left lobe and seg 4		Internalization of NAC after 1-2 weeks	None	
Molinario et al.(2021), Italy[20]	Failed ABX	1	Left lobe	TG	LAMS (Axios 10 × 20 mm), 8.5 Fr x 3 cm DPS placed inside the LAMS	None	1 month

Abbreviations: ABX, antibiotics; BFMS, biflanged metal stent; DPS, double pigtail plastic stent; FCSEMS, fully covered self-expanding metal stent; LAMS, lumen apposing stent; NAC, naso-abscess catheter; PCD, percutaneous drainage; seg, segment; SS, straight stent; TD, transduodenal; TE, Transesophageal; TG, transgastric.
**No mention in the study.

 © 2022. Society of Gastrointestinal Endoscopy of India. All rights reserved.

Summary box	
What is already known about this subject?	Liver abscess drainage using EUS is known
What are the new findings?	We have reviewed all the available published data on indications and methods of EUS-guided liver abscess drainage
How might it impact on clinical practice in the foreseeable future?	This data can be an initiator for a consensus and comparative studies opinion on EUS-guided drainage prosthesis and techniques

first century AD when Archigenes of Apamea,[1] described using acrid concoctions of pepper and smyrnion that were applied superficially to facilitate the opening of abscess and letting the fluid outward. Centuries later, we do the same, only our methods have refined.

It is generally held that if abscess size is > 5 cm, walls are thick and contents of the abscess appear echogenic—drainage is preferable to aspiration. A prospective randomized comparison of aspiration versus drainage concluded that drainage is a better modality as compared to aspiration, especially in larger abscesses which are partially liquefied or with thick pus.[2]

EUS-guided drainage is fairly recent concept of drainage of the liver abscess, first case was reported in 2005. There are a total of 18 case series published on this subject with a total of 58 patients in these series, where liver abscess was drained using EUS. We have summarized the details of these studies in the table. Currently, there is no consensus regarding EUS-guided drainage of the liver abscess; also, there is no guideline regarding the use of endoprosthesis for drainage of the abscess. Here are some bullet points from the published studies (►**Table 1**).

Indication for drainage: The most common indication of EUS drainage was the failure of antibiotic therapy or difficult percutaneous approach. One of the cases had interesting indication of the presence of Chiladiti's syndrome preventing percutaneous approach (Yamamoto et al.)[16]

Location and approach: The majority (37/58) of the lesions were either in the left lobe or gastro hepatic space. The second common site was caudate lobe (11/58 cases). Approach for drainage was commonly trans-gastric or trans-esophageal as in 1 case. Ten abscesses drained were in the right lobe where a trans-duodenal approach was considered.

Endoprosthesis for drainage: In 24 cases out of 58, only plastic accessories were used. In 4 cases, naso-abscess catheter (NAC) (5–8 Fr) was used alone, while in 6 cases it was used along with a plastic stent for lavage. Sixteen of 58 cases had used plastic stents of various sizes alone (7–10 Fr).

Metal accessories included lumen apposing metal stents (LAMS) or partially covered (PC)/ fully covered self-expanding metal stent (FCSEMS)—One study used partially covered SEMS (Medrado et al.)[9]. FCSEMS was used in 19/58 cases of size varying from 6 cm to 12 cm in length and diameter of 10 mm and LAMS and BFMS (biflanged metal stent) were used in 8 of the cases, size ranging from10 mm to 16 mm diameter and maximum 3 cm length.

Adjunctive method for abscess evacuation: Three patients with LAMS had undergone direct endoscopic necrosectomy. Chandra et al suggested the use of Sohendra biliary dilator as an aspiration device after abscess needle puncture to break the septae and aspirate the content before placing the stents/NAC that hastened the recovery in their series.

Success: Technical and clinical success was achieved in all cases.

Complications: Four of the 58 cases (6%) had complications in the form of bleeding, perforation, new paraoesophageal collection formation due to NAC traversing the esophagus and stent migration within the abscess. All these complications were managed conservatively and there was no mortality due to above complications.

Removal of drainage endoprosthesis: In these studies, this ranged from 7 days to 3 months. There was no uniformity in the duration and frequency of lavage through NAC in these studies.

Summary

We present our case of liver abscess drainage with EUS using NAC and plastic stent. There are limited numbers of case series in the published domain.

- We have found that the common indication is for EUS-guided liver drainage are failure of antibiotics or inaccessible percutaneous drainage.

There is no consensus regarding the use of accessories and the need for auxiliary drainage methods. All methods have succeeded clinically in these series; probably the unsuccessful ones are never published. Also, there is no particular time line when the accessories need to be removed.

It should be reiterated the treatment of choice for liver abscess and EUS-guided drainage should only be attempted if percutaneous drainage is not feasible. As the abscess cavity is nonadherent to the gastric or duodenal wall, the excessive dilatation of the tract should be avoided to prevent spillage into the peritoneum and use non–cautery-based technique for tract creation should be preferred.

We perceive that there is a strong need for prospective comparative studies for various modalities of drainage and societal guidelines for EUS drainage of liver abscess.

Consent

Consent from the patient was obtained regarding the publication of this case.

Conflict of Interest

None declared.

 © 2022. Society of Gastrointestinal Endoscopy of India. All rights reserved.

References

1 Papavramidou N, Samara A, Christopoulou-Aletra H. Liver abscess in ancient Greek and Greco-Roman texts. Acta Med Hist Adriat 2014;12(02):321–328

2 Singh S, Chaudhary P, Saxena N, Khandelwal S, Poddar DD, Biswal UC. Treatment of liver abscess: prospective randomized comparison of catheter drainage and needle aspiration. Ann Gastroenterol 2013;26(04):332–339

3 Seewald S, Imazu H, Omar S, et al. EUS-guided drainage of hepatic abscess. Gastrointest Endosc 2005;61(03):495–498

4 Ang TL, Seewald S, Teo EK, Fock KM, Soehendra N. EUS-guided drainage of ruptured liver abscess. Endoscopy 2009;41(Suppl 2):E21–E22

5 Noh SH, Park DH, Kim YR, et al. EUS-guided drainage of hepatic abscesses not accessible to percutaneous drainage (with videos). Gastrointest Endosc 2010;71(07):1314–1319

6 Itoi T, Ang TL, Seewald S, et al. Endoscopic ultrasonography-guided drainage for tuberculous liver abscess drainage. Dig Endosc 2011;23(Suppl 1):158–161

7 Keohane J, Dimaio CJ, Schattner MA, Gerdes H. EUS-guided transgastric drainage of caudate lobe liver abscesses. J Interv Gastroenterol 2011;1(03):139–141

8 Ivanina E, Mayer I, Li J, et al. EUS-guided drainage of hepatic abscess. Gastrointest Endosc 2012;75(04):AB114

9 Medrado BF, Carneiro FO, Vilaça TG, et al. Endoscopic ultrasound-guided drainage of giant liver abscess associated with transgastric migration of a self-expandable metallic stent. Endoscopy 2013;45 (Suppl 2):E331–E332

10 Alcaide N, Vargas-Garcia AL, de la Serna-Higuera C, Sancho Del Val L, Ruiz-Zorrilla R, Perez-Miranda M. EUS-guided drainage of liver abscess by using a lumen-apposing metal stent (with video). Gastrointest Endosc 2013;78(06):941–942

11 Kawakami H, Kawakubo K, Kuwatani M, et al. Endoscopic ultrasonography-guided liver abscess drainage using a dedicated, wide, fully covered self-expandable metallic stent with flared-ends. Endoscopy 2014;46(Suppl 1 UCTN):E982–E983

12 Koizumi K, Masuda S, Uojima H, et al. Endoscopic ultrasound-guided drainage of an amoebic liver abscess extending into the hepatic subcapsular space. Clin J Gastroenterol 2015;8(04): 232–235

13 Kodama R, Saegusa H, Ushimaru H, Ikeno T, Makino M, Kawaguchi K. Endoscopic ultrasonography-guided drainage of infected intracystic papillary adenocarcinoma of the liver. Clin J Gastroenterol 2015;8(05):335–339. Doi: 10.1007/s12328-015-0607-6

14 Ogura T, Masuda D, Saori O, et al. Clinical outcome of endoscopic ultrasound-guided liver abscess drainage using self-expandable covered metallic stent (with video). Dig Dis Sci 2016;61(01): 303–308

15 Tonozuka R, Itoi T, Tsuchiya T, et al. EUS-guided drainage of hepatic abscess and infected biloma using short and long metal stents (with videos). Gastrointest Endosc 2015;81(06):1463-–1469. Doi: 10.1016/j.gie.2015.01.023

16 Yamamoto K, Itoi T, Tsuchiya T, Tanaka R, Nagakawa Y. EUS-guided drainage of hepatic abscess in the right side of the liver of a patient with Chilaiditi syndrome. VideoGIE 2017;2(11):299–300

17 Carbajo AY, Brunie Vegas FJ, García-Alonso FJ, et al. Retrospective cohort study comparing endoscopic ultrasound-guided and percutaneous drainage of upper abdominal abscesses. Dig Endosc 2019;31(04):431–438

18 Rana SS, Ahmed S, Sharma R, Gupta R. Safety and efficacy of EUS-guided drainage of liver abscess: a single-center experience. Endosc Ultrasound 2020;9(05):350–351

19 Chandra S, Chandra U. Endoscopic ultrasound-guided transgastric drainage of radiologically inaccessible left lobe liver abscess involving segment 4, caudate lobe, and left lateral segments using a modified technique. Endosc Int Open 2021;9(01): E35–E40

20 Molinario F, Rimbaş M, Pirozzi GA, et al. Endoscopic ultrasound-guided drainage of a fungal liver abscess using a lumen-apposing metal stent: case report and literature review. Rom J Intern Med 2021;59(01):93–98

 © 2022. Society of Gastrointestinal Endoscopy of India. All rights reserved.