



# Midface Infection after COVID-19 Vaccination in a Patient with Calcium Hydroxylapatite Dermal Filler: A Case Report and Literature Review

Hong Bae Jeon, MD<sup>1</sup> Jae Hee Yoon, MD<sup>1</sup> Nam Kyu Lim, MD<sup>1,2</sup>

<sup>1</sup>Department of Plastic and Reconstructive Surgery, Dankook University Hospital, Cheonan, Chungnam, Republic of Korea

<sup>2</sup>Department of Plastic and Reconstructive Surgery, Dankook University College of Medicine, Cheonan, Chungnam, Republic of Korea

**Address for correspondence** Nam Kyu Lim, MD, Department of Plastic and Reconstructive surgery, Dankook University Hospital, 201 Manghyang-ro, Dongnam-gu, Cheonan, Chungnam, 31116, Republic of Korea (e-mail: linakyer@daum.net; LimNK.PS@dankook.ac.kr).

Arch Plast Surg 2022;49:310–314.

## Abstract

The emergence of vaccines for coronavirus disease 2019 (COVID-19) raises risk of possible adverse events from interaction between the vaccines and facial aesthetic care. A 47-year-old female with no medical comorbidities visited our emergency room due to midface painful swelling after 3 hours following receiving the second dose of the messenger RNA BNT162b2 COVID-19 vaccine. About 14 years ago, she underwent nonsurgical augmentation on the nasojugal groove with a calcium hydroxylapatite dermal filler. We performed incision and drainage under general anesthesia on the next day. During operation, yellowish pus-like materials bulged out. After an operation, we performed a combination therapy with antibiotics and methylprednisolone. Her symptoms improved day by day after surgery, and then a complete recovery was achieved at 3 weeks after the treatment. In conclusion, providers of aesthetic procedures are to be aware of the potential risks of such vaccines for patients who already had or seek to receive dermal filler injections.

## Keywords

- ▶ COVID-19 vaccine
- ▶ dermal filler
- ▶ inflammation

The emergence of vaccines for coronavirus disease 2019 (COVID-19), including two messenger RNA (mRNA)-based vaccines, the first of their kind, raises risk of possible adverse events from interaction between the vaccines and facial aesthetic care. In the few months after the first two vaccines to gain approval in the United States were introduced, patients with dermal fillers were already reporting postvaccination inflammatory reactions.<sup>1–4</sup>

Dermal fillers can become inflamed much later after injection, as observed in some cases after other vaccinations, the flu vaccine being a case in point. Other triggers include

sinus infections, common viral infections, dental work, and systemic inflammatory conditions, while the inflammation can also occur for no particular reason. The ingredients injected into the mRNA COVID-19 vaccines, and also the spike protein generated by the mRNA payloads, introduce to the immune system several novel potential sensitizers or adjuvants, any of which could result in delayed inflammation of fillers.<sup>1,3–6</sup>

So far, the adverse effects of dermal fillers related to COVID-19 vaccination reported almost have been hyaluronic acid (HA) components worldwide.<sup>3,4,7</sup> We report the first

DOI <https://doi.org/10.1055/s-0042-1748643>.  
ISSN 2234-6163.

© 2022. The Korean Society of Plastic and Reconstructive Surgeons. All rights reserved.

This is an open access article published by Thieme under the terms of the Creative Commons Attribution-NonDerivative-NonCommercial-License, permitting copying and reproduction so long as the original work is given appropriate credit. Contents may not be used for commercial purposes, or adapted, remixed, transformed or built upon. (<https://creativecommons.org/licenses/by-nc-nd/4.0/>)

Thieme Medical Publishers, Inc., 333 Seventh Avenue, 18th Floor, New York, NY 10001, USA

case of delayed inflammatory reaction (DIR) after receiving a second dose of the mRNA COVID-19 vaccination in a patient with a calcium hydroxylapatite dermal filler.

## Case Report

Following institutional guidelines, this study was approved by the Institutional Review Board (IRB No. 2021-10-017). A 47-year-old female with no medical comorbidities and allergies visited our emergency room due to midface swelling and pain after 3 hours following receiving the second dose of the mRNA BNT162b2 COVID-19 vaccine (Pfizer/BioNTech, NY). The firm mass-like nodules presented on both cheeks, but symptoms such as erythema and tenderness were much prominent on the left side (►Fig. 1A). About 14 years ago, she underwent nonsurgical augmentation on the nasojugal groove with a calcium hydroxylapatite dermal filler (Radiesse, Bioform Medical, Inc., NC) at a primary aesthetic clinic. Since then, she has been experiencing mild swelling in both cheeks once a year on average, but it improved spontaneously within few days. And, there were no such symptoms within recent months, including after the first dose of the COVID-19 vaccine 3 weeks ago. At the initial enhanced computed tomography (CT) scan, it showed abscess-like lesion on both cheeks (►Fig. 2A).

The next day, we performed incision and drainage under general anesthesia. During operation, yellowish pus-like materials bulged out (►Fig. 3A,B). We conducted the bacterial/fungal/tuberculosis culture, cytology, and biopsy immediately. The initial treatment was aimed at simultaneously controlling antibacterial and immune regulation. The first sets of empirical antibiotics were the unasin, clindamycin, and netilmicin for wide spectrum coverage until the culture result come out. And then 125 mg intravenous methylprednisolone was applied for 3 days. The C-reactive protein level, which increased to 7.13 mg/dL the day after surgery, decreased to 0.97 mg/dL on the third day

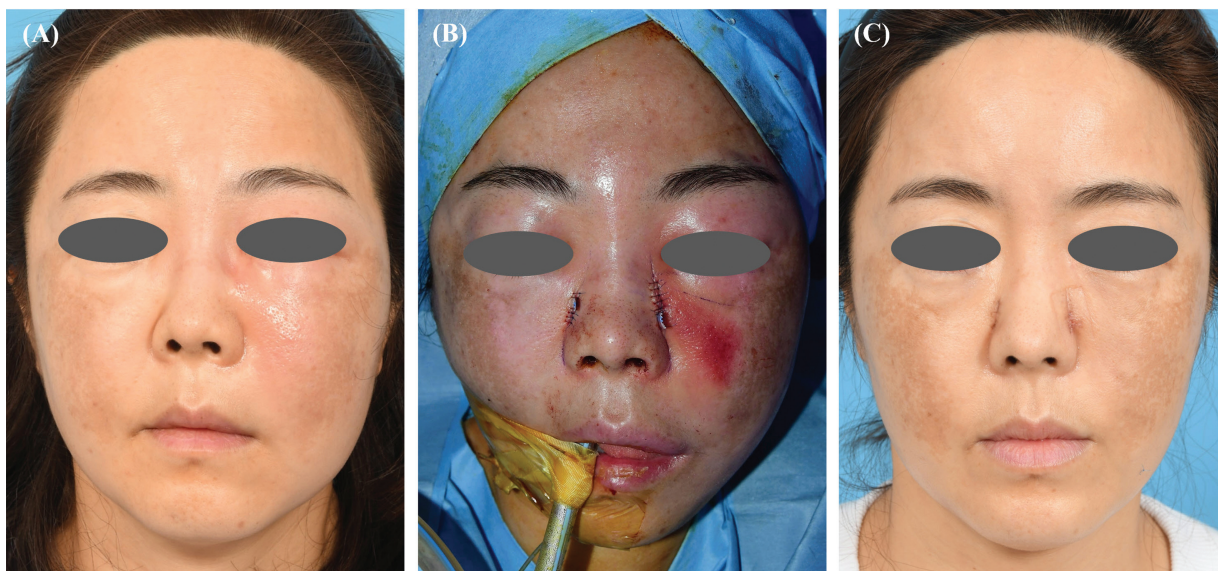
after surgery, and normalized to 0.29 mg/dL at 7 days after surgery. Meanwhile, the methicillin-sensitive *Staphylococcus aureus* was reported at postoperative 7 days; hence we changed antibiotics to the nafcillin at the following day (►Fig. 4). In biopsy, it showed amorphous basophilic foreign materials with inflammatory cells (►Fig. 3C).

Although soft tissue inflammation and fluid collection were observed on the enhanced CT scan and magnetic resonance imaging the next day after surgery (►Fig. 2B,C), her symptoms such as swelling and erythema improved day by day after surgery. However, the serobloody discharge continued to come out and was maintained by Penrose drainage for ~2 weeks. A complete recovery was achieved at 3 weeks after the treatment (►Fig. 1C).

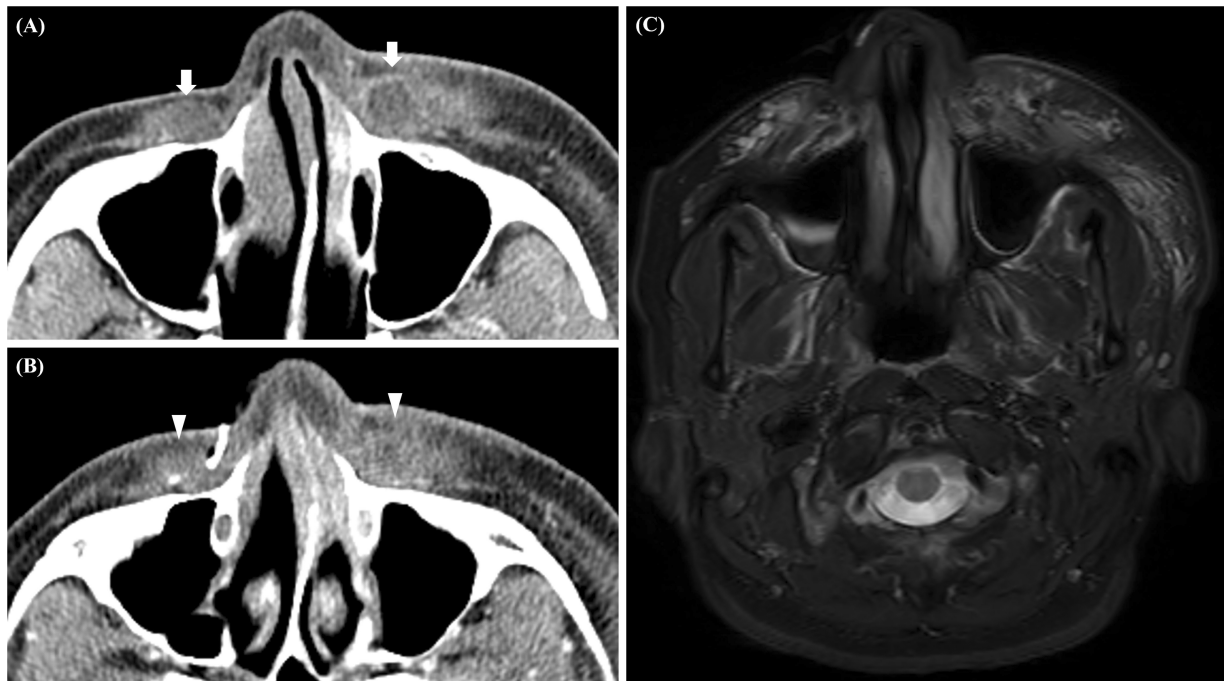
## Discussion

The risk of a reaction occurring much after injecting dermal fillers has gone down from 0.7% before 1999 when methods of production were less advanced, to the more recent figure of 0.02%, thanks to use of highly purified products. But the use of HA fillers that include high and low HA chains for better longevity has increased the occurrence of such adverse events again, as the modification alters the morphology of HA molecules, potentially affecting their immunogenicity.<sup>3,8</sup> The fact that some manufacturers add other substances such as mannitol or dextran to make the product more hydrophilic increases the risk of antigens triggering an immune response.<sup>8</sup>

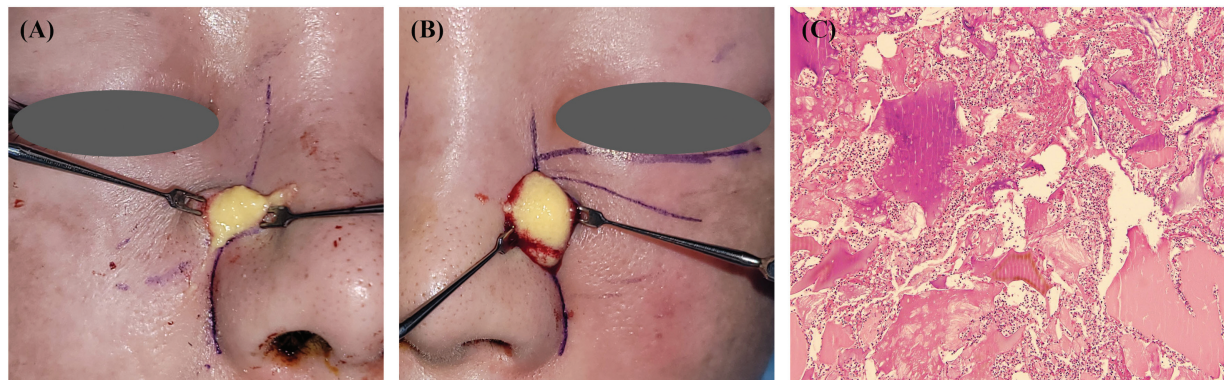
The injectable implant under the commercial name of Radiesse (Bioform Medical, Inc., NC) is 30% composed of uniform calcium hydroxylapatite microspheres, sized from 25 to 45  $\mu\text{m}$  in diameter, while 70% is an aqueous gel carrier of carboxymethylcellulose. The calcium hydroxylapatite serves as a scaffold to promote formation of new tissue that resembles its environment when injected in the form of small microspheres.<sup>9</sup> The normal reaction of tissue to any



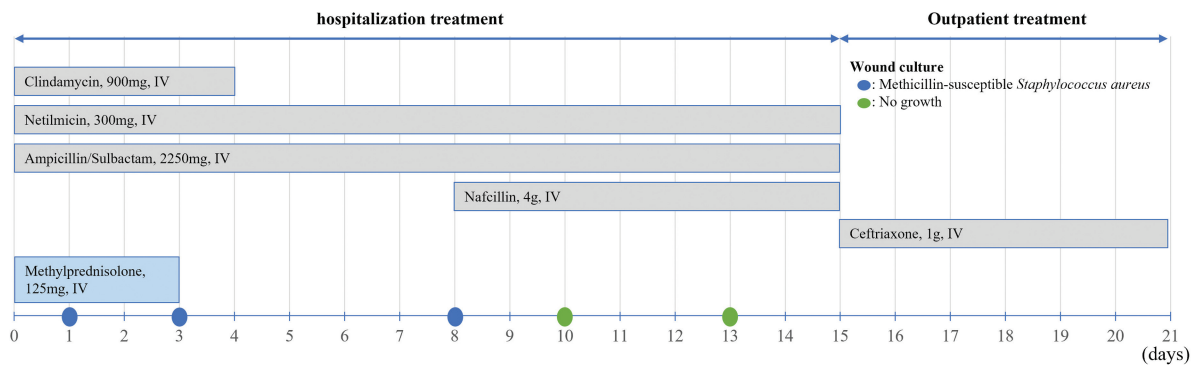
**Fig. 1** Clinical photographs. (A) Preoperative image. (B) Intraoperative image. (C) Postoperative image after 3 weeks.



**Fig. 2** Radiological images. (A) Preoperative image with enhanced computed tomography (CT). White arrows indicate the abscess-like lesion on both cheeks. (B) Postoperative 1-day image with enhanced CT. White triangles indicate the sequelae after removing the abscess. (C) Postoperative 1-day image with magnetic resonance imaging. Diffuse soft tissue inflammation was observed on both cheeks.



**Fig. 3** Clinical and histological images. (A, B) Intraoperative photographs: Yellowish foreign materials with pus-like discharge were observed in both cheeks. (C) Histological image: The amorphous basophilic foreign materials with inflammatory cells were observed.



**Fig. 4** A schematic image for the clinical course during treatment.



foreign body is typically phagocytosis, which is known as the single most important factor that decides the longevity of the fillers. Phagocytosis of particles larger than 5 µm requires aggregated macrophages (foreign-body giant cells), while particles larger than 15 to 20 µm are generally not ingested by macrophages or transported to the local lymph nodes, failing to phagocytose. Failure to effectively phagocytose leads to formation of granuloma, while the aggregates of activated macrophages take on an epithelioid morphology, and there are giant cells of different types, surrounded by an infiltrate of T-lymphocytes that release cytokines including tumor necrosis factor-α, interferon gamma, and interleukin-12, which continue to activate macrophages.<sup>3</sup> The development of bacterial biofilms or colonies of microorganisms contained in an extracellular matrix that may surround a foreign body may result in a low-grade chronic infection with idiopathic or injury-induced reactivation. This may cause acute inflammation accompanied by a quiescent granuloma after a significant period of time since the patient had the injection.<sup>2</sup> Even in our case, she had been experiencing a low-grade chronic infection for 14 years. However, current symptoms such as obvious erythematous and tenderness were the first experience after dermal filler injection, and we assumed that the mRNA COVID-19 vaccine (Pfizer/BioNTech, NY) acts as a trigger to induce a DIR.

One possible explanation for COVID-19 spike protein related to DIR with dermal fillers could be by binding and blocking the receptors of angiotensin-converting enzyme 2 (ACE2). Skin and other tissues maintain immune homeostasis with relatively higher levels of ACE2 that regulates the production of proinflammatory angiotensin II in relation to the amount of the metabolites. However, spike proteins and dermal ACE2 receptors interact and activate Th1 for inflammation, helping a CD8+ T-lymphocyte-mediated reaction.<sup>3,5,10</sup> Finally, angiotensin II is known to upregulate CD44 glycoprotein, found on the surface of many mammalian cells, including endothelial cells, fibroblasts, macrophages, keratinocytes, and lymphocytes. CD44 glycoprotein tends to bind free extracellular HA, offering another potential locus for inflammatory reaction against the quiescent HA granuloma.<sup>10</sup> Although our patient had not been injected with an HA dermal filler, we deduced progress of midface infection with a similar mechanism because she also had a quiescent inflammatory granuloma due to low-grade chronic infection.

Because the COVID-19-related DIR mechanism has not clearly been investigated, treatment could be quite controversial. Usually, in consideration of inhibited host immune response, clinicians are reluctant to prescribe oral corticosteroid as a treatment for an active infection. However, COVID-19 triggers what is apparently a hyperimmune response, for which corticosteroid can be helpful. Another suggestion that does require further study would be to administer ACE inhibitors or angiotensin receptor blockers to treat acute-phase DIR.<sup>5</sup> Meanwhile, if the nodules do not improve and are painful and tender, accompanied by edema and erythema, surgery and antibiotics treatment are necessary.<sup>3</sup> We performed surgical treatment immediately after visiting the emergency room, and used antibiotics as regard

bacterial infection. Simultaneously, steroid therapy was applied, but such anti-inflammatory treatment did not adversely affect infection control. Rather, we felt that the anti-inflammatory treatment improved a patient's symptoms faster during the arrival of blood concentration of antibiotics. However, antihistamines are not recommended because their effectiveness is limited.<sup>10</sup>

According to the report from the American Society for Dermatologic Surgery in 2020, there do not seem to be many postvaccination inflammatory reactions. Only 3 participants out of 15,184 patients who had at least one shot of mRNA-1273 in the mRNA-1273 COVID-19 vaccine (Moderna, MA) trial developed swelling on the face that was potentially related to dermal fillers. Moreover, all patients showed no serious adverse event and had cured spontaneously.<sup>7</sup> Delayed inflammations of dermal fillers in general are also rare and mostly self-limited.<sup>3</sup> In addition to that, individual tendencies, such as HLA-B\*08 and DR1\*03 haplotypes, were found to raise the risk of delayed, immune-mediated, adverse reactions to dermal fillers; as such combinations of human leukocyte antigen subtypes were linked to almost four times higher probability of adverse reactions.<sup>8</sup>

In conclusion, people should not be dissuaded from COVID-19 vaccination, in consideration of the morbidity, mortality rates, and the socioeconomic impact of the pandemic. It should be noted that many DIRs with immunological causes are localized and self-limited and are often spontaneously resolved. Also, the low probability of DIRs after dermal fillers indicates that they should not be a deterrent against receiving the COVID-19 vaccines. Meanwhile, providers of aesthetic procedures are to be aware of the potential risks of such vaccines for patients who already had or seek to receive dermal filler injections.

#### Author Contributions

Conceptualization: N.K.L. Data curation: H.B.J., J.H.Y., and N.K.L. Formal analysis: N.K.L. Methodology: N.K.L. Project administration: N.K.L. Visualization: J.H.Y. and N.K.L. Writing-original draft: H.B.J., J.H.Y., and N.K.L. Writing-review and editing: H.B.J. and N.K.L.

#### Ethical Approval

This study was approved by the Institutional Review Board (IRB No. 2021-10-017).

#### Patient Consent

The patient provided written informed consent for the publication and the use of her images.

#### Conflict of Interest

None declared.

#### References

- Nayak LM. Commentary on "Coronavirus Vaccine Considerations for the Aesthetic Patient" by Rice et al.—Our Duty to Our Patients. *Facial Plast Surg Aesthet Med* 2021;23(02):76-77
- Gotkin RH, Gout U, Sattler S, et al. Global recommendations on COVID-19 vaccines and soft tissue filler reactions: a survey-based

- investigation in cooperation with the International Society for Dermatologic and Aesthetic Surgery (ISDS). *J Drugs Dermatol* 2021;20(04):374–378
- 3 Michon A. Hyaluronic acid soft tissue filler delayed inflammatory reaction following COVID-19 vaccination - a case report. *J Cosmet Dermatol* 2021;20(09):2684–2690
  - 4 Rowland-Warmann MJ. Hypersensitivity reaction to hyaluronic acid dermal filler following novel coronavirus infection - a case report. *J Cosmet Dermatol* 2021;20(05):1557–1562
  - 5 Munavalli GG, Guthridge R, Knutsen-Larson S, Brodsky A, Matthew E, Landau M. "COVID-19/SARS-CoV-2 virus spike protein-related delayed inflammatory reaction to hyaluronic acid dermal fillers: a challenging clinical conundrum in diagnosis and treatment". *Arch Dermatol Res* 2022;314(01):1–15
  - 6 Ghasemi S, Dashti M. Fight against COVID-19 with mRNA vaccines and interaction with dermal fillers. *Clin Exp Vaccine Res* 2021;10(02):151–153
  - 7 Pau M, Reinbacher KE, Feichtinger M, Navysany K, Kärcher H. The mandibular symphysis as a starting point for the occlusal-level reconstruction of panfacial fractures with bicondylar fractures and interruption of the maxillary and mandibular arches: report of two cases. *J Craniomaxillofac Surg* 2014;42(04):e51–e56
  - 8 Owczarczyk-Saczonek A, Zdanowska N, Wygonowska E, Placek W. The Immunogenicity of hyaluronic fillers and its consequences. *Clin Cosmet Investig Dermatol* 2021;14:921–934
  - 9 Jansen DA, Graivier MH. Evaluation of a calcium hydroxylapatite-based implant (Radiesse) for facial soft-tissue augmentation. *Plast Reconstr Surg* 2006;118(3, Suppl):22S–30S
  - 10 Munavalli GG, Knutsen-Larson S, Lupo MP, Geronemus RG. Oral angiotensin-converting enzyme inhibitors for treatment of delayed inflammatory reaction to dermal hyaluronic acid fillers following COVID-19 vaccination—a model for inhibition of angiotensin II-induced cutaneous inflammation. *JAAD Case Rep* 2021;10:63–68