



Chronic Infection and Nodule Formation following Deoxycholate Injection

Shahab Shahid, MRCS¹ Fawaz Al-Hassani, MRCS¹

¹ St Andrew's Centre for Plastic Surgery and Burns, Broomfield Hospital, Chelmsford, United Kingdom

Address for correspondence Shahab Shahid, MRCS, 44 Summerston House, 51 Starboard Way, London E16 2PE, United Kingdom (e-mail: Shahab_shahid@outlook.com).

Arch Plast Surg 2022;49:315–318.

Abstract

Aqualyx (Marllor International Ltd, Rimini, Italy) was originally developed in Italy by Professor Pasquale Motolese and has been commercially available since 2009. It is a deoxycholate, aqueous gelatinous solution mixed with saline and buffering compounds. It is the only drug approved by the European Union for the reduction in localized fat. Aqualyx is sold exclusively to doctors and nurses trained in intralipotherapy. In the case of our patient, the product administered was advertised as Aqualyx, but was not administered by a trained health professional and was administered too superficially. The patient developed severe pain following the injection and was unable to sit for several weeks. There was localized skin necrosis, and palpable collections where the injection was administered. Our initial suspicion was development of an abscess or hematoma. To characterize further, we arranged an ultrasound scan that showed a “superficial hypoechoic lesion” but no deeper infection or spread. The numerous painful nodules ruptured onto the skin surface, resulting in purulent and bleeding lesions. This case demonstrates the importance of appropriate training and competence in performing cosmetic procedures including injections and fat dissolving treatments.

Keywords

- ▶ aqualyx
- ▶ cosmetics
- ▶ complication
- ▶ training
- ▶ safety

Targeted fat reduction through injection came to prominence in 2001. Rittes, a Brazilian dermatologist, reported reduction in infraorbital fat following subcutaneous injection of a combined phosphatidylcholine (PC) and sodium deoxycholate (DC) solution.¹ Both these compounds are bile salts, and work by causing breakdown of adipocyte cell membranes and cell lysis. Further research on this compound established that only the DC component of the injection was effective for fat loss; hence, further treatments based on the compound were developed. Aqualyx (Marllor International Ltd, Rimini, Italy) was originally developed by Italian Professor Pasquale Motolese and has been commercially available since 2009. Other commonly used DC-based compounds include ATX-101 (Allergan Aesthetics, Dublin, Ireland) and Kybella/Belkyra (Allergan Aesthetics, Dublin, Ireland).²

Case Report

A 51-year-old female patient presented to our plastic surgery clinic a month ago following DC-based injection treatment. This was described as Aqualyx to the patient. The patient had a body mass index of 25 kg/m², and had no previous treatment of liposuction, lipolysis, or any cosmetic

DOI <https://doi.org/10.1055/s-0042-1748644>.
ISSN 2234-6163.

© 2022. The Korean Society of Plastic and Reconstructive Surgeons. All rights reserved.

This is an open access article published by Thieme under the terms of the Creative Commons Attribution-NonDerivative-NonCommercial-License, permitting copying and reproduction so long as the original work is given appropriate credit. Contents may not be used for commercial purposes, or adapted, remixed, transformed or built upon. (<https://creativecommons.org/licenses/by-nc-nd/4.0/>)

Thieme Medical Publishers, Inc., 333 Seventh Avenue, 18th Floor, New York, NY 10001, USA

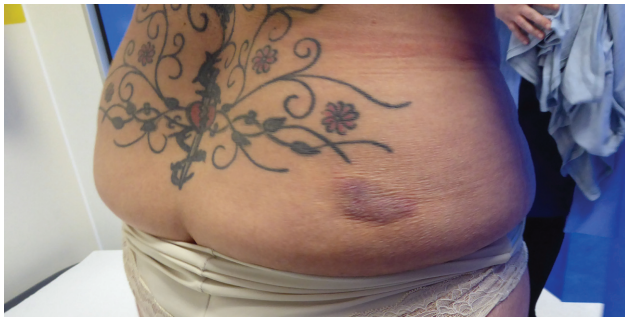

Fig. 1 Two months postprocedure—posterior view of buttocks.

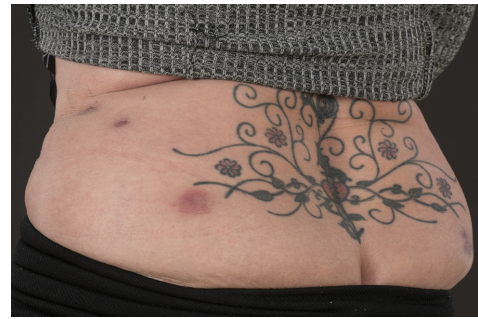

Fig. 2 Four months postprocedure—posterior view of buttocks.

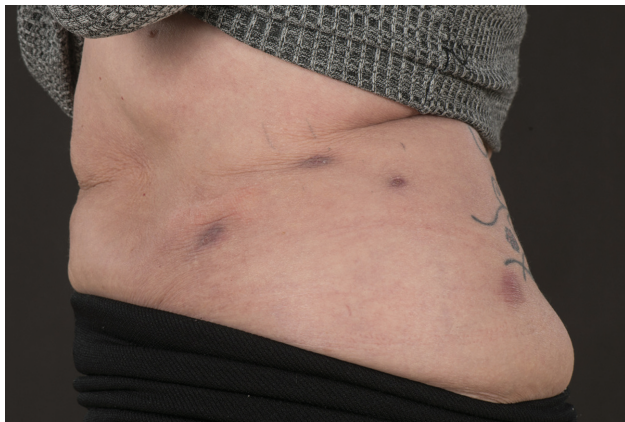


Fig. 3 Four months postprocedure—left hip region.

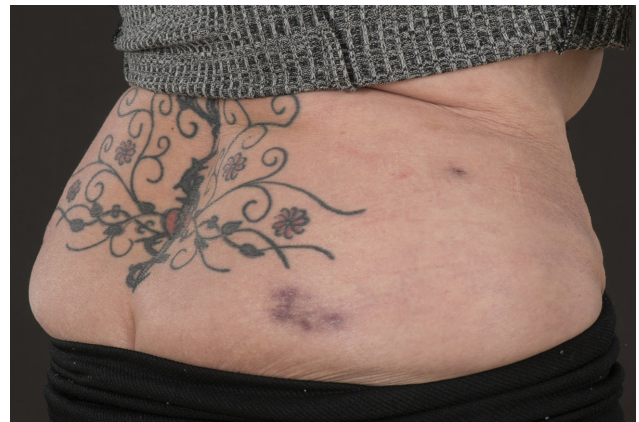

Fig. 4 Four months postprocedure—right hip and buttock region.

surgery. The treatment areas in question were the buttocks, hips, and flanks bilaterally. The patient reported shooting pains down the posterior aspect of her right leg, painful nodules in the injected areas, fevers, and severe pain when the treated areas came into contact with clothing. She had no past medical history and had received the treatment from a cosmetics clinic, where the injections were administered by a nonhealth professional. On examination, there were several firm nodules in the injected areas, tender to palpation with focal skin necrosis (see ►**Fig. 1**). Written informed consent was obtained from the patient and clinical photography was performed.

We performed blood tests and arranged an outpatient ultrasound of the right buttock, lower back, and flank. Blood tests were normal, with a white cell count of $6.8 \times 10^9/L$, and a C-reactive protein level of 1.3 mg/L. By the stage of review in our clinic, the patient had already had several courses of antibiotics from her general practitioner, with no resolution of the painful nodules.

The patient had ultrasound of the injected areas, which demonstrated shallow, dermally based heterogeneously hypoechoic lesions. There was no evidence of subcutaneous extension, abscess, or collection. The main concern for the patient was the painful nature of the lesions, making it difficult to wear jeans and sit comfortably when the affected areas came into contact with surfaces. As these nodules began to heal, they eventually expressed themselves into

the surface of the skin, resulting in bruising and purulent, bleeding lesions. Three months following treatment, the patient was still dependent on regular painkillers and not able to wear jeans or any clothing that puts pressure on the injected areas (see ►**Figs. 2–4**).

After being seen in our plastic surgery trauma clinic, the patient was followed up in a consultant plastic surgery clinic. The decision was to manage the patient conservatively by encouraging the lesions to drain through regular massage and keeping the nodules covered with plasters to prevent abrasive action of clothes on the highly sensitive nodules. The focal areas of necrosis had largely healed by the time the patient was seen in our clinic initially; hence, excision was not felt to be indicated. Six months posttreatment, the nodules have become less painful and indurated with no further discharge from the wounds. She is now able to wear fitted clothing without pain and is able to manage without painkillers, and with regular massage.

Discussion

We hypothesize that these lesions resulted from injection of lipotherapy in a plane that was too superficial, resulting in necrosis of the overlying skin. The likelihood is that the injection of the solution was also in a discontinuous fashion resulting in a bumpy and uneven skin surface. This has been demonstrated to occur more often when less experienced practitioners perform the procedure.³ The solution may have

been injected in too high a concentration, but this has not been possible to confirm. We have also been unable to confirm if the solution in question was Aqualyx as approved by the manufacturer; however, it was marketed as such to the patient.

In 2012, the European medicine regulation body approved Aqualyx (a DC-based injection) as the only fat loss injection therapy within the European Union (EU). The EU approved the treatment for "localized fat reduction" and was not specific to the submental region as specified by the U.S. Food and Drug Administration (FDA). Existing research demonstrates that DC-based fat loss injections yield effective results with minimal complications, when administered correctly.⁴

Aqualyx is only licensed for use by physicians and nurses trained in the intralipotherapy technique. It has been in use for over a decade and it is used to treat conditions such as buffalo hump and localized adiposity from hypertrophy or hyperplasia.^{5,6} Since its inception, Aqualyx is intended to be used alongside ultrasound, to generate microcavitation and cause adipocytes to dissolve and release their contents. However, the treatment is most commonly used without ultrasound; the use of DC-based compounds including Aqualyx has been demonstrated to yield effective results.^{1,3,5,7-11} Intralipotherapy involves multiple passes of a sharp 23-gauge needle in a fan-like pattern, with retrograde continuous administration of the solution at varying depths. The solution should not be injected too superficially near the skin, or too deep, that is, into the muscles.⁶ Off-label use of this treatment is dependent on a thorough understanding of the anatomy of the treated region as well as an understanding of possible complications.

In 2015, FDA approved Kybella, a DC-based solution for the treatment of submental fat. This followed significant evidence from multiple centers demonstrating efficacy and safety.^{9,11-13} This approval was specifically for the compound to be used by trained physicians, and in the submental region only. However, off-label use is practiced widely, with positive results in difficult to treat areas including the bra line, gluteal trochanteric region, buccal fat pad, and lipomatous tumors.¹⁴

In the case of Aqualyx, if the solution is injected in a discontinuous fashion, nodules form under the skin's surface and the reduction in fat is uneven, leading to a poorer aesthetic result.¹⁵ These nodules are usually self-limiting, and the vast majority have been reported to be resolved by 4 months.¹⁵

Nodule formation has been reported in numerous studies, with nodules usually decreasing in size within 6 months of initial treatment.⁸ Raouf and Salti reported a 42% nodule rate in a 145-patient series of Aqualyx treatments. The nodule formation was closely correlated with limited physician experience, as 53 of the 61 patients who developed nodules had treatment performed by less experienced doctors.³

In addition, the patient in this case report suffered from a small amount of necrosis of the skin overlying the nodules. This in itself is a rare complication and was first reported in

2015.¹⁵ Although a licensed treatment, DC-based injections can result in severe complications including skin and muscle necrosis, and if injected intra-arterially around the head and neck region, damage can happen to the tongue, floor, or mouth and nerves supplying the face.¹⁶ Even when experienced physicians use DC-based injections, there is still a risk of complications following the treatment. Alopecia of the injected area has also been reported in two cases of submental DC-based injection in two healthy males. This resolved over 7 and 14 months, with near normal return of hair growth.¹⁵⁻¹⁸

ATX-101 was approved by the FDA for submental fat reduction and in one case, intra-arterial injection of the drug resulted in skin necrosis.¹⁹ This necessitated long-term dressings, and carbon dioxide laser therapy following re-epithelialization. Other vascular injuries following the injection have also been reported.²⁰ However, off-label use of ATX-101 for peri-axillary fat reduction was demonstrated to be safe and effective with no serious complications and high rates of patient satisfaction.⁷ Infraorbital fat pad reduction using ATX-101 injection in two patients was found to be safe with minimal edema and bruising, and intralesional use of deoxycholic injection has been shown to reduce xanthelasma around the eyes, with minimal side effects.¹⁰

Common side effects of deoxycholic acid-based injections include swelling, redness, pain, and bruising. Simple measures include stopping of anticoagulant medication 7 to 10 days preprocedure, ibuprofen use preprocedure, local anesthetic with adrenaline injected into the site, and cold compression before and after the treatment. All the above treatments have been shown to reduce these side effects.²¹

Correct training in safe use of DC-based products is essential, and must be based upon both a sound understanding of surrounding anatomy and the correct technique for injection. Injecting around the jaw area brings important neurovascular structures such as the marginal mandibular nerve and facial artery into the surgical field. Taking Aqualyx as an example, injecting the treatment too superficially can result in skin necrosis and nodule formation, and those that are too deep risk underlying neurovascular and musculo-tendinous structures. Use of the product should be contingent upon medical or nursing qualification, and after attending an approved aesthetic practitioner course with appropriate certification and validation of competencies. As such, this training should be originated from a central aesthetics authority that regulates practitioners using these products. The central government should, therefore, legally mandate that only qualified healthcare professionals should be able to use these products; there is no such legislation as yet in the United Kingdom or United States, despite the nonsurgical cosmetics industry being a multibillion-dollar industry.²²

Prevention of complications is crucial, and close patient follow-up is necessary following the treatment. In the case of our patient, the practitioner performing the procedures was not medically qualified and therefore not able to manage the complications of the procedure they had performed. Early identification and treatment of complications including skin

necrosis and nodule formation improve prognosis. Had closer follow-up been available to our patient, any complication would have been identified and managed in a timely manner.

Conclusion

Aqualyx and other DC-based fat dissolving injections are approved for use by trained physicians within the EU, United States, and wider international community. Correct training, monitoring, and follow up, as well as close attention to the safety of the compound being injected, are essential for maintaining high standards of patient care. The regulation of nonsurgical aesthetic treatments is also limited in the United Kingdom, with no central authority determining competencies or delivering qualifications. Further research on the safety and efficacy of DC-based compounds for fat reduction in an off-label manner is essential for the maintenance of patient safety and the improvement of outcomes.

Author Contributions

Conceptualization: S.S. and F.A.-H. Funding acquisition: No funding for study. Methodology: S.S. and F.A.-H. Writing-original draft: S.S. and F.A.-H. Writing-review and editing: S.S. and F.A.-H.

Patient Consent

The patient provided written informed consent for the publication and the use of images.

Conflict of Interest

None declared.

References

- Rittes PG. The use of phosphatidylcholine for correction of lower lid bulging due to prominent fat pads. *Dermatol Surg* 2001;27(04):391–392
- Rotunda AM, Suzuki H, Moy RL, Kolodney MS. Detergent effects of sodium deoxycholate are a major feature of an injectable phosphatidylcholine formulation used for localized fat dissolution. *Dermatol Surg* 2004;30(07):1001–1008
- Rauso R, Salti G. A CE-marked drug used for localized adiposity reduction: a 4-year experience. *Aesthet Surg J* 2015;35(07):850–857
- Sykes JM, Allak A, Klink B. Future applications of deoxycholic acid in body contouring. *J Drugs Dermatol* 2017;16(01):43–46
- Rauso R, Rusciani A, Curinga G. An adipocytolytic aqueous micro-gelatinous solution for buffalo hump deformity reduction. *J Drugs Dermatol* 2014;13(10):1282–1284
- Pinto H, Hernandez C, Turra C, Manzano M, Salvador L, Tejero P. Evaluation of a new adipocytolytic solution: adverse effects and their relationship with the number of vials injected. *J Drugs Dermatol* 2014;13(12):1451–1455
- Shridharani SM. Injection of an adipocytolytic agent for reduction of excess periaxillary fat. *Aesthet Surg J* 2019;39(12):NP495–NP503
- Humphrey S, Sykes J, Kantor J, et al. ATX-101 for reduction of submental fat: a phase III randomized controlled trial. *J Am Acad Dermatol* 2016;75(04):788–797
- Liu M, Chesnut C, Lask G. Overview of Kybella (deoxycholic acid injection) as a fat resorption product for submental fat. *Facial Plast Surg* 2019;35(03):274–277
- Lindsey SF, Benesh G, Pavlis J, Zaiac M. Deoxycholic acid injections for the treatment of infraorbital fat pads. *Dermatol Surg* 2019;45(12):1720–1723
- Dayan SH, Humphrey S, Jones DH, et al. Overview of ATX-101 (deoxycholic acid injection): a nonsurgical approach for reduction of submental fat. *Dermatol Surg* 2016;42(01, Suppl 1):S263–S270
- Humphrey S, Femmer P, Belezny K, Carruthers JDA. Deoxycholic acid for submental fullness and more: real-world experience with 202 patients. *Dermatol Surg* 2019;45(04):624–627
- Behr K, Kavali CM, Munavalli G, et al. ATX-101 (deoxycholic acid injection) leads to clinically meaningful improvement in submental fat: final data from CONTOUR. *Dermatol Surg* 2020;46(05):639–645
- Sung CT, Lee A, Choi F, Juhasz M, Mesinkovska NA. Non-submental applications of injectable deoxycholic acid: a systematic review. *J Drugs Dermatol* 2019;18(07):675–680
- Di Toro G, Rauso R. Skin necrosis following adipocytolytic solution injections. *Aesthet Surg J* 2016;36(02):NP74–NP76
- Lindgren AL, Welsh KM. Inadvertent intra-arterial injection of deoxycholic acid: a case report and proposed protocol for treatment. *J Cosmet Dermatol* 2020;19(07):1614–1618
- Grady B, Porphirio F, Rokhsar C. Submental alopecia at deoxycholic acid injection site. *Dermatol Surg* 2017;43(08):1105–1108
- Souyoul S, Gioe O, Emerson A, Hooper DO. Alopecia after injection of ATX-101 for reduction of submental fat. *JAAD Case Rep* 2017;3(03):250–252
- Riswold K, Flynn V. A cautionary tale: a vascular event with deoxycholic acid injection. *Dermatol Surg* 2018;44(06):887–889
- Sachdev D, Mohammadi T, Fabi SG. Deoxycholic acid-induced skin necrosis: prevention and management. *Dermatol Surg* 2018;44(07):1037–1039
- Fagien S, McChesney P, Subramanian M, Jones DH. Prevention and management of injection-related adverse effects in facial aesthetics: considerations for ATX-101 (deoxycholic acid injection) treatment. *Dermatol Surg* 2016;42(01, Suppl 1):S300–S304
- Save Face. Laws and Regulations of the Non-surgical Cosmetic Industry. Accessed April 9, 2022 at: <https://www.saveface.co.uk/laws-regulations-non-surgical-cosmetic-industry/>