



Unicortical Bone Necrosis of the Fibula Free Flap Associated to the Fixation with a Nonlocking 2.0-mm Reconstruction Plate and Screws

Gustavo N. Pereira, MD¹ Diogo Ribeiro, MD¹ Luís Saraiva, MD¹ Hugo Freitas, MD¹ Ana R. Santos, MD²

¹Department of Plastic Surgery, Hospital de Santa Maria (Centro Hospitalar Universitário Lisboa Norte), Lisbon, Portugal

²Department of Otorhinolaryngology, Hospital de Santa Maria (Centro Hospitalar Universitário Lisboa Norte), Lisbon, Portugal

Address for correspondence Luís Saraiva, MD, Rua Julieta Ferrão, Lote RS, 1600-131 Lisboa, Portugal (e-mail: lfv Saraiva@gmail.com).

Arch Plast Surg 2022;49:413–417.

Abstract

The authors present a unique case of osteonecrosis of a cortical half of a fibula free flap that has not been reported in the literature yet. This complication was associated with the impairment of the vascularization of periosteum in the cortical half of fibula that was fixated with a nonlocking reconstructive 2.0-mm plate and screws but other factors could have been involved. The patient was submitted to excision of a cemento-ossifying fibroma that resulted in a left hemimaxilectomy mesoinfrastructure defect classified as the Cordeiro type 2B. The 42-year-old female patient was submitted to reconstruction with an osteomusculocutaneous fibula free flap plus a segment of fibula graft. The two bone segments of the free flap used to reconstruct the anterior and left alveolar crest were fixated with a reconstructive 2.0-mm plate of matrixMANDIBLE system. The only reported complication was an oronasal fistula that healed with conservative treatment and the referred osteonecrosis of the external cortical half of the fibula free flap with plate exposure at 2.5 years postoperatively. Surgical excision of the osteonecrosed cortical half of the fibula with the plate and screws was performed, while the other cortical underwent bone union as corroborated by computed tomography scans.

Keywords

- ▶ bone plates
- ▶ osteonecrosis
- ▶ free tissue flaps
- ▶ reconstructive surgical procedures
- ▶ postoperative complications

Maxillary reconstruction after tumor resection is one of the most challenging areas of head and neck surgery. Partly because tumors involving this region are rare,¹ such as the cemento-ossifying fibroma (COF), that we present in this case report. COF is a slow-growing, encapsulated, and benign fibroosseous lesion that is considered to originate from the periodontal ligament,² causing enlargement of the affected bone.³ It has a definite female predilection, with a female-to-male ratio as high as 5:1, and is more frequently diagnosed

between 20 and 40 years of age, even though they can occur in a wider age range (between second and sixth decades).³

The treatment is only surgical when margins of the resection are free of tumor. Regarding the complexity of the defect and the function and esthetics of the face, the type of reconstructions is diverse. It includes a broad spectrum of surgical options, such as bone graft, obturators, soft tissue, and/or bone free flaps.^{1,4} The internal fixation of the bone can be performed with plates and screws of diverse types. In

DOI <https://doi.org/10.1055/s-0042-1748655>.
ISSN 2234-6163.

© 2022. The Korean Society of Plastic and Reconstructive Surgeons. All rights reserved.

This is an open access article published by Thieme under the terms of the Creative Commons Attribution-NonDerivative-NonCommercial-License, permitting copying and reproduction so long as the original work is given appropriate credit. Contents may not be used for commercial purposes, or adapted, remixed, transformed or built upon. (<https://creativecommons.org/licenses/by-nc-nd/4.0/>)

Thieme Medical Publishers, Inc., 333 Seventh Avenue, 18th Floor, New York, NY 10001, USA

the bone graft or flap reconstruction of head and neck tumors, reconstruction plates and miniplates are the most commonly used. Most literature does not find a statistically significant difference between these two types of plates in overall complication rates, and all other specific complications.⁵⁻¹¹ However, the focal impairment of periosteum vasculature in the sites of compression by the plates and screws is well known.¹² Comparing nonlocking reconstruction plates and screws to miniplates and to locking plates and screws, the former is the one that involves more disruption of periosteal vessels and cortical bone perfusion, the latter is the lesser and the second is in between.¹³

With this case report, we intend to stress out the risk of bone necrosis with the fixation of the segments of fibula bone free flap with a nonlocking reconstruction plate and screws.

Case Report

A 42-year-old female, with a body mass index of 29 kg/m², former smoker (15 pack-years smoking history), with no other relevant medical history, was reported to our department with a progressive and slow-growing mass (7.5 cm × 7.5 cm × 4.5 cm) on the left side of the upper maxilla that appeared 3 years before. Intraoral examination showed a giant exophytic round-shaped lesion in the second quadrant of the mouth extending to the palate (→ Fig. 1). The biopsy revealed a COF of the hard palate.

Tracheostomy, excision of the tumor, left submaxilectomy, left level-2 neck dissection was performed by the otorhinolaryngology surgical team, resulting in a left hemimaxilectomy mesoinfrastructure defect classified as the Cordeiro type 2B⁴ or Brown class 2d.¹⁴ Our surgical team performed the reconstruction with an osteomusculocutaneous fibula free flap (the left leg as the donor site). The bone of the flap was 8-cm long, harvested approximately 15 cm below the head of the fibula, and it was osteotomized into two distal segments. The proximal segment (3-cm long) reconstructed the anterior alveolar crest and the distal segment (5-cm long) reconstructed the left lateral alveolar crest. The two segments were fixated to each other with a 2.0-mm-thick reconstruction plate of the matrixMANDIBLE plating system (Synthes, Paoli, PA) and two monocortical

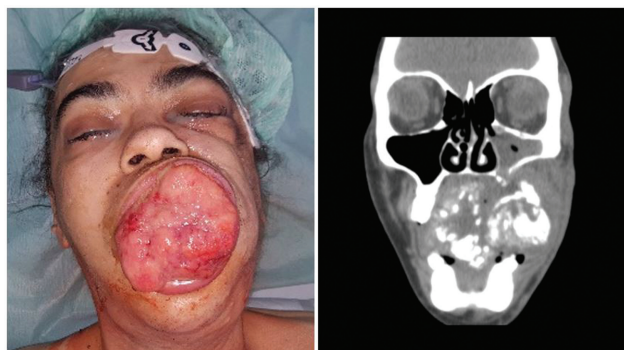

Fig. 1 Preoperative photo (left) and a CT scan with a coronal view (right) both showing the lesion. CT, computed tomography.

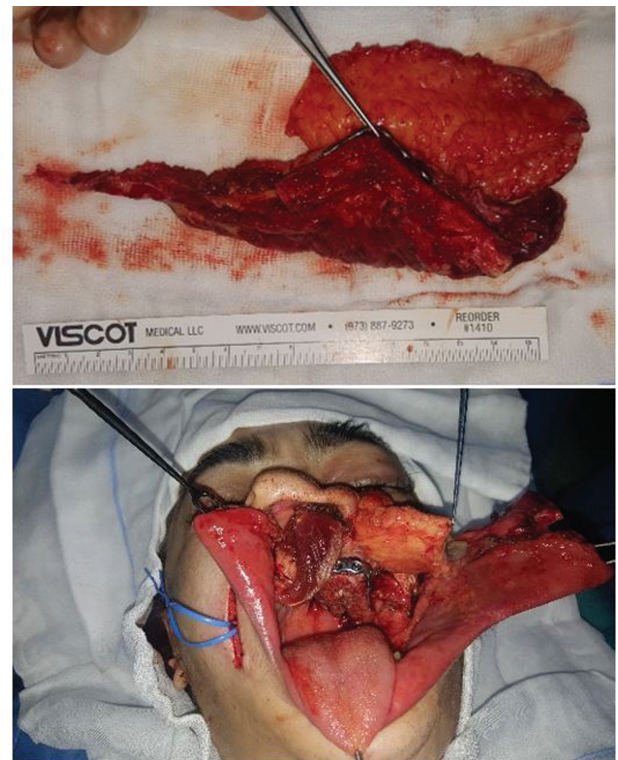


Fig. 2 On the top, the osteomusculocutaneous fibula free flap. The two vascularized bone segments were fixated with a nonlocking 2.0-mm reconstruction plate and five monocortical screws. On the bottom, the intraoperative photo showing the defect reconstructed with the osteomusculocutaneous fibula free flap.

screws in the anterior segment and three monocortical screws in the posterior segment (Synthes; → Fig. 2). The anterior segment was fixated to the right nasomaxillary buttress with an "L" of 1.5-mm thick plate with monocortical screws (Synthes). The left zygomaticomaxillary buttress was reconstructed with a 3-cm long fibula graft fixated to the posterior segment of the fibula and to the inferior orbital rim with a 1.5-mm thick plate with monocortical screws (Synthes). The skin paddle (7 cm × 3 cm) was used to reconstruct the intraoral mucosal defect (→ Fig. 2). The pedicle of the flap was 9-cm long and the anastomosis was end to lateral of the right facial artery to the peroneal artery at the level of the right nasogenian crease; the venous anastomosis was end to end with Flowcoupler 2.0 mm (Synovis Micro Companies Alliance, Inc., Birmingham, England) of comitant peroneal vein to the right facial vein. The donor site was closed requiring a skin graft.

The immediate postoperative computed tomographic (CT) scan showed coaptation between the anterior segment of the fibula to the maxilla and between the anterior and posterior segment of the fibula. The postoperative course was uneventful, with no vascular complications of the flap, monitored by clinical evaluation, and in the first postoperative week, with the doppler monitorization of venous pedicle flow with Flowcoupler. The only early complication was the development of an oronasal fistula at the posterior region of the palate that healed with conservative treatment. The

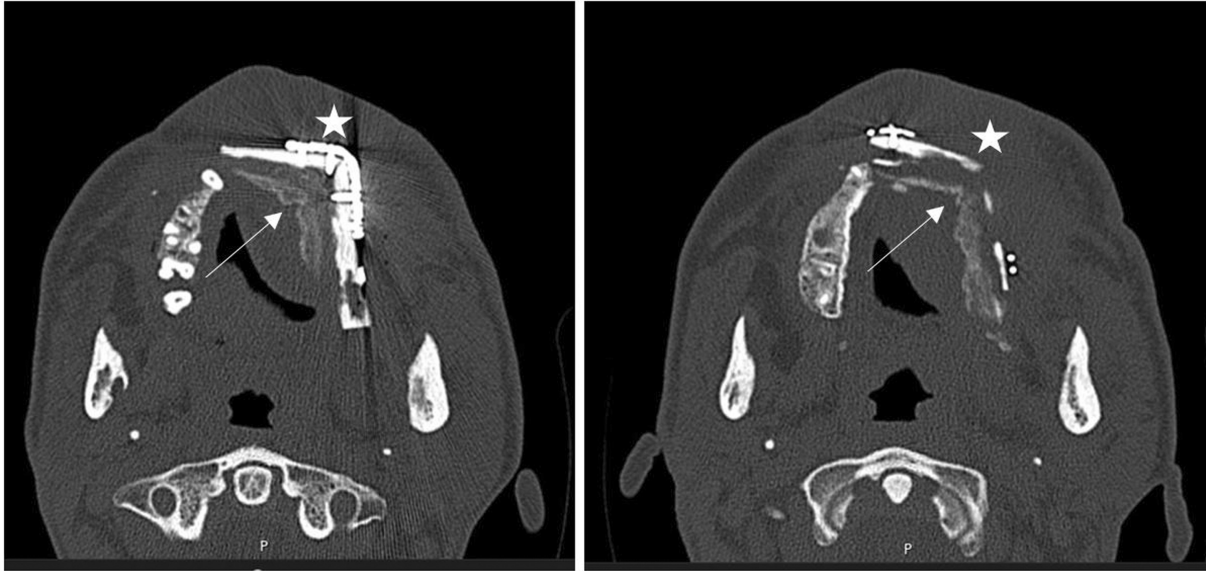


Fig. 3 CT scan images in an axial view, 2 months postoperatively, showing different radiographical bone healing of the external comparing to the internal cortical half of the fibula. The external/ventral cortical half of the bone flap is marked with a star, and the inner one is marked with an arrow. CT, computed tomography.

anatomopathological study revealed that all surgical margins were free of tumor.

At the second month, postoperatively, the patient was submitted to another CT scan (► **Fig. 3**) which showed different radiographical bone healing of the external comparing to the internal cortical half of the fibula. The latter showed more bone union to the maxilla than the former.

At the 2.5 years postoperatively, the plate fixing the segments of the fibula became exposed intraorally. CT scan showed excellent ossification of the nonnecrotized half fibula and separation in all extent of the necrotized half (► **Figs. 4 and 5**). We surgically extracted the necrotized half with no need for osteotomy, as the separation between the

two halves was total (► **Fig. 6**). Also, minor surgical procedures were done to the nose and lips to improve its esthetics.

The remaining follow-up until the present time of publication, corresponding to 3 years of postoperative time, was uneventful.

At that time, the patient had an intelligible speech, a good esthetic appearance (► **Fig. 7**), could chew low consistency food, and oral deglutition was normal.

Discussion

COF is a rare, benign, and slow-growing tumor that can affect both the mandible and maxilla due to its probable origin in

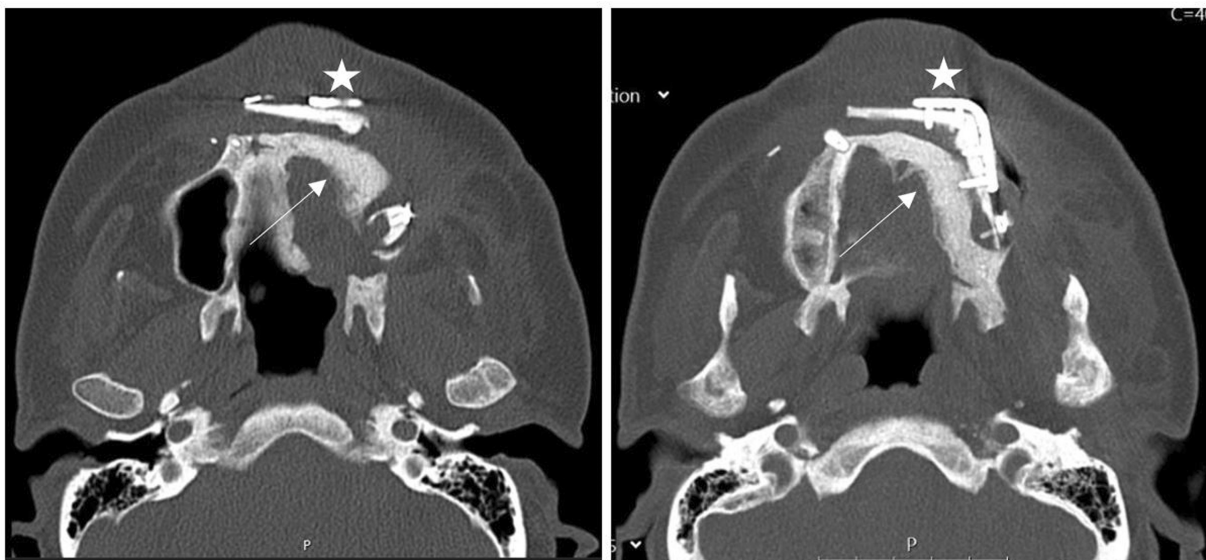

Fig. 4 CT scan images in an axial view, 2.5 years postoperatively, showing complete ossification of the nonnecrotized half fibula (inner cortical) and separation in all extent of the necrotized half (external/ventral half). The external/ventral cortical half of the bone flap is marked with a star, and the inner one is marked with an arrow.

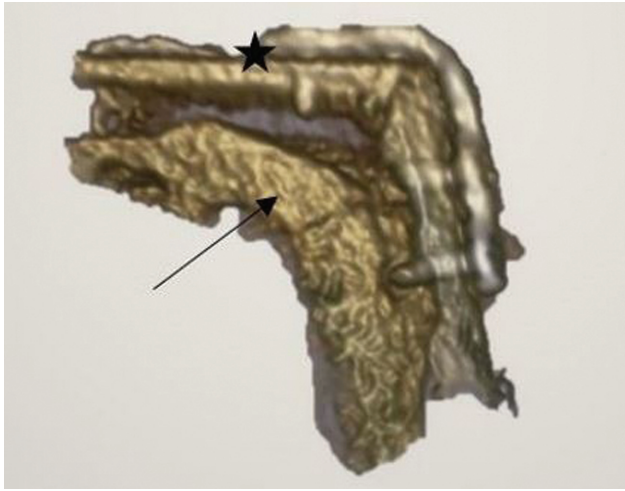


Fig. 5 A 3D reconstruction of the fibula bone, 2.5 years postoperatively, showing the two halves of the bone of the fibula flap: the external/vestibular one (star) with osteonecrosis, in contact with the plate and screws, and the inner healthy one (arrow) revealing bone union with the maxilla. 3D, three-dimensional.

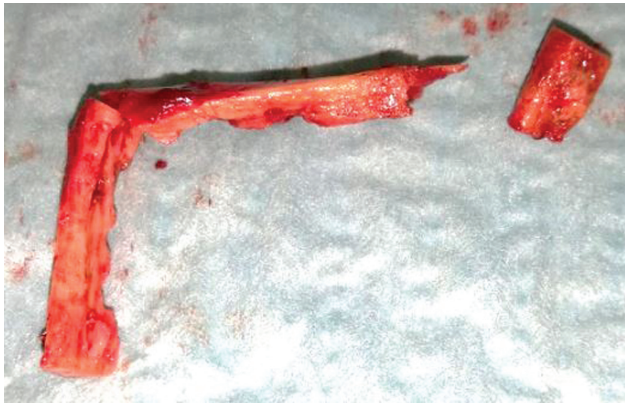


Fig. 6 The debrided necrotized half of the fibula, at the 2.5 years postoperatively.

the periodontal ligament. In this case report, the tumor grew from the left maxilla, for 3 years, making it almost impossible for the patient to eat or to speak.

The tumor was completely removed, resulting in a defect classified as the Cordeiro type 2B⁴ or Brown class 2d¹⁴ because all of the lower five walls and the anterior arch of the maxilla were excised.

In this type of defect, palate, nasal lining, and maxillary arch need to be addressed in the reconstruction. It is consensual that an osteocutaneous free flap should be used.^{1,4,15} Not so consensual is which free flap to choose. Cordeiro and Chen defended that the radial forearm osseocutaneous (RFOC) free flap is the best choice for reconstruction because it can supply enough bone stock for osseointegrated implants without the bulge, thickness, and stiffness of the cutaneous paddle of the osteocutaneous fibula flap, impeding a reconstruction of the anterior and lateral sulcus.⁴ On the other hand, RFOC leaves an important esthetic sequela of the donor area, and the small thickness of the cutaneous paddle and the inexistence of muscle in the flap provide a less robust

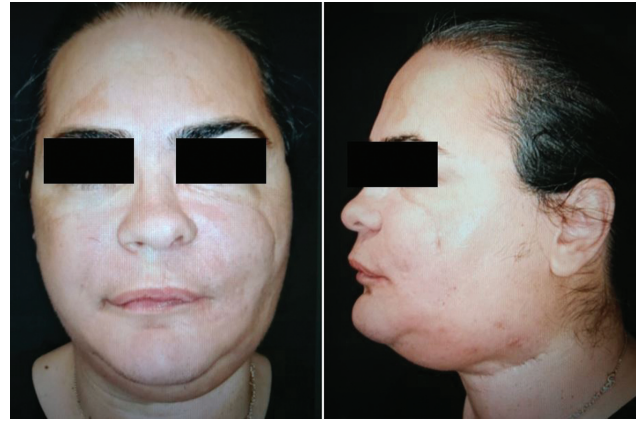

Fig. 7 Pictures of the face of the patient with a good aesthetic outcome, three years postoperatively.

reconstruction, therefore facilitating the exposure of the plate and screws.

In a comparative study¹⁵ of the various osseocutaneous free flaps, fibula and iliac crest were the most adequate because of their bone dimensions for implant placement.

For this patient, we chose to harvest an osseomusculocutaneous fibula free flap because it met the requirements to reconstruct this defect. A provision of bicortical bone that can provide three-dimensional contouring to simulate the maxillary arch: a good recipient for osseointegrated implants, a skin paddle to reconstruct the mucosa, and muscle to obliterate the maxillary sinus. Also, this flap is widely used by our team to reconstruct bone defects, making the harvesting a fast procedure. It has low donor morbidity, with almost no limitations in walking or running, and it allows for a two-team operation when reconstructing head and neck.¹⁵⁻¹⁸ The dominant arterial supply of this flap is the nutrient artery from the peroneal artery. It arises as a branch of the peroneal artery and enters the fibula posterior to the interosseous membrane into the nutrient foramen, approximately 15-cm below the styloid process in the posterior medial edge of the midfibula, two-fifths of the way down.¹⁹ We harvested 8 cm of the fibula, 15-cm below its head, so probably the nutrient artery was not included in this free flap. Consequently, the arterial supply was exclusive by the periosteal and muscular branches of the peroneal artery in both the segments.

The surgery was successful with no vascular complications of the flap. Clinical and venous anastomosis doppler monitorization was uneventful. Only an oronasal fistula in the posterior palate developed but healed with conservative treatment. No infection or dehiscence of the cutaneous paddle happened. At 2 months postoperatively, the CT scan showed different radiographical bone healing of the external, comparing to the internal cortical half of the fibula. It developed in a plate exposure and osteonecrosis of both segments of the external/vestibular cortex of the fibula flap at the 2.5 years postoperatively.

We assume that the osteonecrosis of the external/vestibular cortical half of the fibula free flap was favored by the compression, leading to the impairment of the periosteal vascular supply

by the nonlocking 2.0-mm reconstructive plate and screws. Considering that this bone was supplied only by the periosteal vessels, the risk of osteonecrosis was bigger. But other factors, such as not including the nutrient artery in the flap and the compression forces caused by the screws placed on the bone, could have also contributed to this outcome. The periosteal vascular lesion that we assume to have happened was impossible to be identified with the clinical assessment of the cutaneous paddle or even with doppler monitorization in the venous anastomosis. Moreover, other possible causes of local vascular compromise were not identified such as infection or wound dehiscence. Lastly, only the outer cortical of the fibula, in contact with the plate and screws, was affected with the inner cortical ossifying uneventfully, leading to an excellent overall outcome.

This osteonecrosis led to intraoral exposure of the plate. Surgical exploration corroborated the separation of the necrosed bone and the viability of the inner cortical half. The necrosed bone was extracted alongside plates and screws and no more intraoral exposure happened in the follow-up.

Conclusion

In conclusion, the fixation of plates and screws to the bone can affect the vascularization of the periosteum in such a way that bones uniquely vascularized by this mean can suffer from osteonecrosis of the cortical bone. In this case, the osteomusculocutaneous fibula free flap was fixated in the maxilla with a reconstructive plate with nonlocking screws. Miniplates or locking system plates and screws with less contact surface, providing less compression to the bone, could have been used to prevent this osteonecrosis from happening.

Author Contributions

G.N.P.: Responsible for planning, collecting and interpreting data, writing the manuscript, review of the final version, and answering to the reviewers. D.R.: Responsible for collecting and interpreting data and review of the final version. L.S.: Responsible for collecting and interpreting data and review of the final version. H.F.: Responsible for critical review, important intellectual content, and approval of the final version. A.R.S.: Responsible for critical review and important intellectual content.

Patient Consent

Informed consent was obtained from all individual participants included in the study.

Conflict of Interest

None declared.

References

- Hanasono MM, Silva AK, Yu P, Skoracki RJ. A comprehensive algorithm for oncologic maxillary reconstruction. *Plastic and Reconstructive Surgery* 2013;131(Suppl 1):47–60
- Katti G, Khan MM, Chaubey SS, Amena M. Cemento-ossifying fibroma of the jaw. *BMJ Case Rep* 2016;2016:bcr2015214327
- Peravali RK, Bhat HHK, Reddy S. Maxillo-mandibular cemento-ossifying fibroma: a rare case report. *J Maxillofac Oral Surg* 2015;14(Suppl 1):300–307
- Cordeiro PG, Chen CM. A 15-year review of midface reconstruction after total and subtotal maxillectomy: part II. Technical modifications to maximize aesthetic and functional outcomes. *Plastic and Reconstructive Surgery* 2012;129(Suppl 1):139–147
- Al-Bustani S, Austin GK, Ambrose EC, Miller J, Hackman TG, Halvorson EG. Miniplates versus reconstruction bars for oncologic free fibula flap mandible reconstruction. *Ann Plast Surg* 2016;77(03):314–317
- Shaw RJ, Kanatas AN, Lowe D, Brown JS, Rogers SN, Vaughan ED. Comparison of miniplates and reconstruction plates in mandibular reconstruction. *Head Neck* 2004;26(05):456–463
- Swendseid B, Kumar A, Sweeny Let al. Long-term complications of osteocutaneous free flaps in head and neck reconstruction. *Otolaryngol Head Neck Surg* 2020;162(05):641–648
- Farwell DG, Kezirian EJ, Heydt JL, Yueh B, Futran ND. Efficacy of small reconstruction plates in vascularized bone graft mandibular reconstruction. *Head Neck* 2006;28(07):573–579
- López-Arcas JM, Arias J, Del Castillo JL, et al. The fibula osteomyocutaneous flap for mandible reconstruction: a 15-year experience. *J Oral Maxillofac Surg* 2010;68(10):2377–2384
- Ansari E, Chargin N, van Gemert JTM, et al. Low skeletal muscle mass is a strong predictive factor for surgical complications and a prognostic factor in oral cancer patients undergoing mandibular reconstruction with a free fibula flap. *Oral Oncol* 2020;101:104530
- Zhang ZL, Wang S, Sun CF, Xu ZF. Miniplates versus reconstruction plates in vascularized osteocutaneous flap reconstruction of the mandible. *J Craniofac Surg* 2019;30(02):e119–e125
- Ehrenfeld M, Manson PN, Prein J. *Principles of Internal Fixation of the Craniomaxillofacial Skeleton*. AO Foundation. New York, NY: Georg Thieme Verlag; 2012
- Harjani B, Singh RK, Pal US, Singh G. Locking v/s non-locking reconstruction plates in mandibular reconstruction. *Natl J Maxillofac Surg* 2012;3(02):159–165
- Brown JS, Rogers SN, McNally DN, Boyle M. A modified classification for the maxillectomy defect. *Head Neck* 2000;22(01):17–26
- Futran ND, Wadsworth JT, Villaret D, Farwell DG. Midface reconstruction with the fibula free flap. *Arch Otolaryngol Head Neck Surg* 2002;128(02):161–166
- Hamscha UM, Weninger WJ, Freystätter C, Tzou CH, Radtke C. Anatomical study of a chimeric fascio-osteomyocutaneous fibula flap for free microvascular tissue transfer. *J Reconstr Microsurg* 2019;35(06):438–444
- Nakayama B, Matsuura H, Ishihara O, Hasegawa H, Mataga I, Torii S. Functional reconstruction of a bilateral maxillectomy defect using a fibula osteocutaneous flap with osseointegrated implants. *Plast Reconstr Surg* 1995;96(05):1201–1204
- Triana RJ Jr, Uglesic V, Virag M, et al. Microvascular free flap reconstructive options in patients with partial and total maxillectomy defects. *Arch Facial Plast Surg* 2000;2(02):91–101
- Wei FC, Mardini S. *Flaps and Reconstructive Surgery*. Edinburg, Scotland: Elsevier; 2009