







# Misdiagnosis of Human Herpes Virus-8-Associated Kaposi's Sarcoma as Adverse Drug Eruptions

Tae Hyung Kim, MD<sup>1</sup>  Syeo Young Wee, MD, PhD<sup>1</sup>  Hyun Gyo Jeong, MD, PhD<sup>1</sup>   
Hwan Jun Choi, MD, PhD<sup>2</sup> 

<sup>1</sup> Department of Plastic and Reconstructive Surgery, Soonchunhyang University Gumi Hospital, Soonchunhyang University College of Medicine, Gumi, Republic of Korea

<sup>2</sup> Department of Plastic and Reconstructive Surgery, Soonchunhyang University Cheonan Hospital, Soonchunhyang University College of Medicine, Cheonan, Republic of Korea

Address for correspondence Hwan Jun Choi, MD, PhD, Soonchunhyang University Hospital, 31, Soonchunhyang 6-gil, Dongnam-gu, Cheonan-si, Chungcheongnam-do 31151, Republic of Korea (e-mail: iprskorea@gmail.com).

Arch Plast Surg 2022;49:457–461.

## Abstract

Kaposi's sarcoma (KS) is a cancer that causes patches of abnormal tissue to grow under the skin. It also occurs in the immunosuppressive population. KS is currently believed to be caused by infection with human herpes virus-8 (HHV-8) in non-human immunodeficiency virus patient. A 79-year-old female visited the outpatient clinic presenting with increasing number and size of palpable masses on both upper and lower extremities. She was first diagnosed as drug-erupted dermatitis and stopped her medications, but the symptoms got worse. We did partial biopsy, and KS with HHV-8 was diagnosed histopathologically. She planned to undergo further evaluations and proper treatments. This rare case suggests the need to consider a classic type of KS in the differential diagnosis of specific dermatologic symptoms such as macular, nodular, and darkish patches of upper or lower extremities in elderly patients. It is believed that this case helps to strengthen awareness of this rare disease.

## Keywords

- ▶ extremities
- ▶ non-AIDS-related Kaposi sarcoma
- ▶ adverse drug reactions

Kaposi described five patients with “idiopathic pigmented sarcoma of the skin,” which is now denoted as Kaposi's sarcoma (KS). KS is a multifocal neoplasm of vascular origin characterized by spindle-shaped tumor cells, angiogenesis, extravasated erythrocytes, edema, and a mononuclear cell infiltrate,<sup>1</sup> which has cutaneous symptoms of abnormal tissue to grow under the skin. Prototypic cases of KS represent in adult patients with acquired immunodeficiency syndrome (AIDS) with hyperpigmented cutaneous lesions and edema.<sup>2</sup> Classic KS typically develops in elderly with cutaneous lesions on the lower extremities. KS had been described in three other cases: African-endemic KS, immu-

nosuppressive-drug-associated KS, and AIDS-associated KS.<sup>3</sup> Endemic (African) KS occurs mostly in children in Africa. Posttransplantation (iatrogenic) KS occurs in allograft recipients receiving immunosuppressive therapy, and AIDS-related (epidemic) KS arises in human immunodeficiency virus (HIV)-infected individuals. ▶ **Table 1** explains four types of KS.

The cancer had been known to the public as the first symptom of AIDS epidemic. KS appeared as the most common skin cancer in the AIDS epidemic up to 20% of HIV-1-positive patients. The pathogenesis of KS is multifaceted and currently uncertain. Molecular basis of the exact

DOI <https://doi.org/10.1055/s-0042-1748664>.  
ISSN 2234-6163.

© 2022. The Korean Society of Plastic and Reconstructive Surgeons. All rights reserved.

This is an open access article published by Thieme under the terms of the Creative Commons Attribution-NonDerivative-NonCommercial-License, permitting copying and reproduction so long as the original work is given appropriate credit. Contents may not be used for commercial purposes, or adapted, remixed, transformed or built upon. (<https://creativecommons.org/licenses/by-nc-nd/4.0/>)

Thieme Medical Publishers, Inc., 333 Seventh Avenue, 18th Floor, New York, NY 10001, USA

**Table 1** Four types of Kaposi's sarcoma

Type	Frequency	Clinical features
AIDS-associated	Common	Aggressive, often involving mucosa
Endemic	Rare	Lymphadenopathy with sparse mucosal or skin lesions
Iatrogenic	Very rare	Variable
Classic	Extremely rare	Disseminated cutaneous lesion with occasional lymphadenopathy

Abbreviation: AIDS, acquired immunodeficiency syndrome.

relationships between HIV-1, human herpesvirus-8 (HHV-8), cytokines, and growth factors responsible for causing KS skin lesions remains to be studied further. However, the etiology of KS has been revealed after the discovery of HHV-8 from KS lesions. Several studies support that HHV-8 is essential for the development of KS. In addition, all the patients have been found to have specific antibodies to HHV-8 antigens.<sup>1</sup> Therefore, it is now believed to be caused by infection with HHV-8 in non-HIV population.

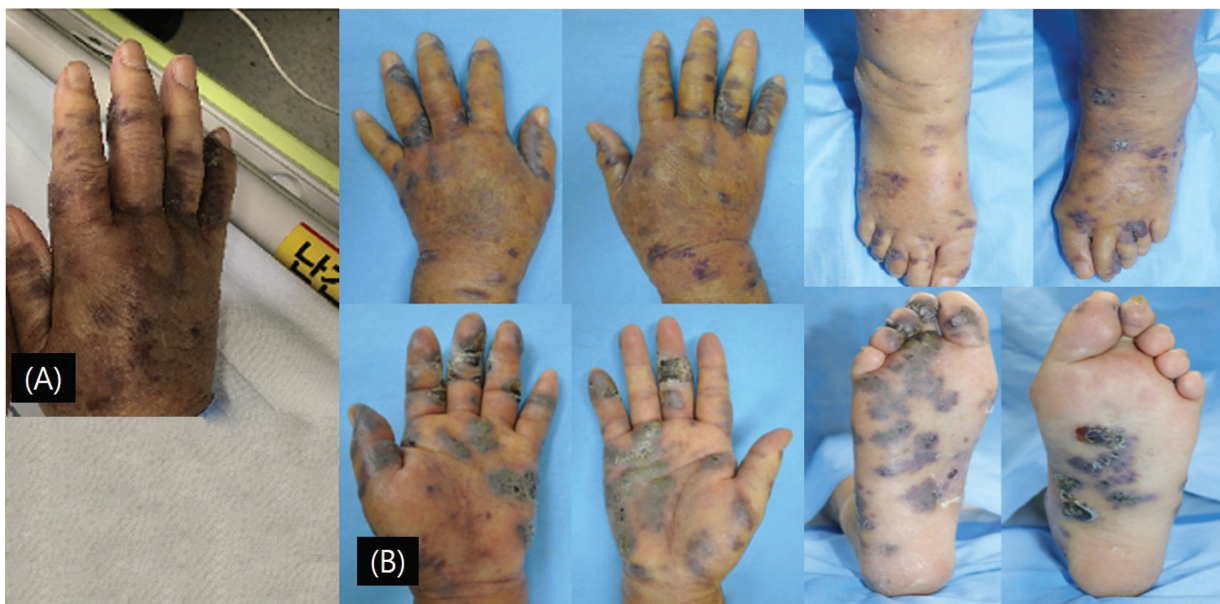### Differential Diagnosis

Differential diagnoses include blue nevus syndrome, pyogenic granuloma, melanoma, and carcinoma cutis.<sup>4</sup> Drug reactions should also be considered. It can cause an adverse cutaneous reaction in the structure of the epidermis and its appendages. Drug reactions can be categorized into immunologic and nonimmunologic etiologies. In the previous studies, just ~45% of all the adverse drug reactions were demonstrated in the skin. Most drug eruptions are self-limited and usually resolve after the offending agent has been stopped. Severe eruptions occur in ~1 in 1,000 hospital patients. Stevens-Johnson syndrome and toxic epidermal necrolysis has a mortality rate of ~5 to 30%. In particular, elderly patients have an increased occurrence of adverse drug reactions compared with young populations.<sup>5</sup>

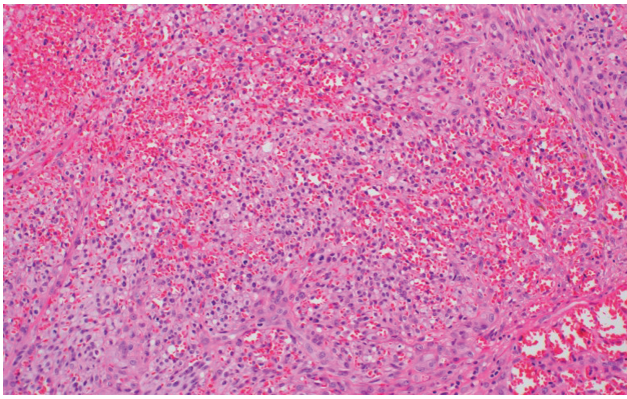
We, herein, report a rare case of KS in non-HIV elderly. The patient was at first misdiagnosed as drug-erupted dermatitis in an outpatient clinic. No regression was found despite discontinuation of the previous medications. This patient appears to be diagnosed with KS after partial biopsy of the cutaneous lesion.

### Case Report

A 79-year-old female with diabetes mellitus and hypertension visited the outpatient clinic presenting with increasing number and size of palpable masses on both upper and lower extremities (→ Fig. 1). The symptom had first started 2 years ago as petechiae on both hands and developed to increase its size and number. Its color changed from reddish to darkish. She originally had been taking medicines such as aspirin (100 mg bid) and nonsteroidal anti-inflammatory drugs (ibuprofen 800 mg/8 mL/vial, 3 vials qd; methocarbamol 1 g/10 mL/vial, 1 vial qd) for her underlying old cerebrovascular disease and multiple compression fracture of T7, T12, and L3. At the local clinic, she was first diagnosed as drug-erupted dermatitis because the mass-like lesions improved when she took these medications. Despite discontinuation of the drugs, her cutaneous symptoms did not heal during 2 years. The cutaneous symptoms had the appearance of



**Fig. 1** Clinical photos of extremities of the patient. The patient was presenting an increasing number and size of palpable masses on both upper and lower extremities.



**Fig. 2** Pathologic finding of the specimen. It demonstrates sheets of plump spindle cells.

papules, patches, plaques, or nodules rather than epidermolysis and erythema. A multifocal origin was observed on her hand and foot mainly. Skin lesions on left hand including normal tissues were excised for a biopsy.

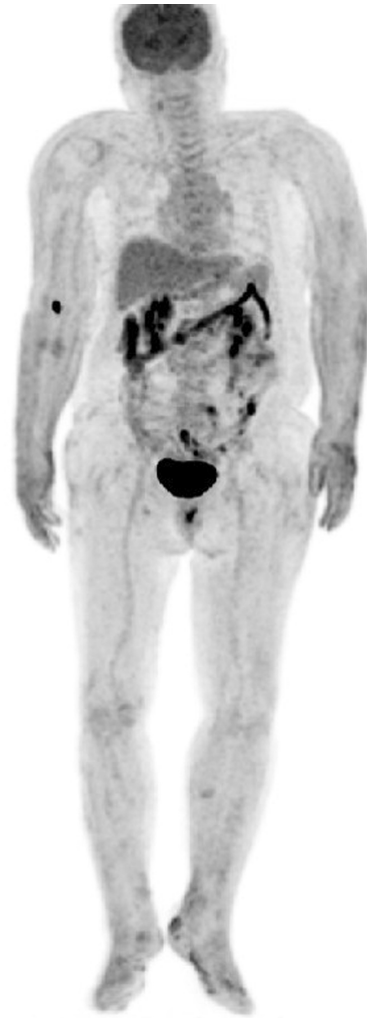On histopathologic examination, KS was confirmed and immunohistochemical stain was positive for HHV-8, CD34, CD32, and D2-40 (→**Fig. 2**). Her other laboratory findings were normal including serologic testing of HIV antibodies, but HHV-8 serology testing was not performed.

The patients' follow-up included physical examination and abdominal, thoracic computed tomography (CT) scans, as well as whole body positron emission tomography-CT for staging work-up. The imaging studies showed that tumors were only confined to skin layer and no other lymph node was enlarged (→**Fig. 3**), which found her in the low risk of KS progress. Since her lesions were presented in the large area of hand and foot, she was planned to undergo further evaluations and proper treatments at hemato-oncologic department. A hemato-oncologist first decided to perform palliative radiotherapy alone, due to her old age, with 30 Gy in 10 fractions for both upper and lower extremities. Her absolute neutrophil count was in the normal range and no immunocompromised issue was reported. After the radiation therapy, her skin lesions improved (→**Fig. 4**).

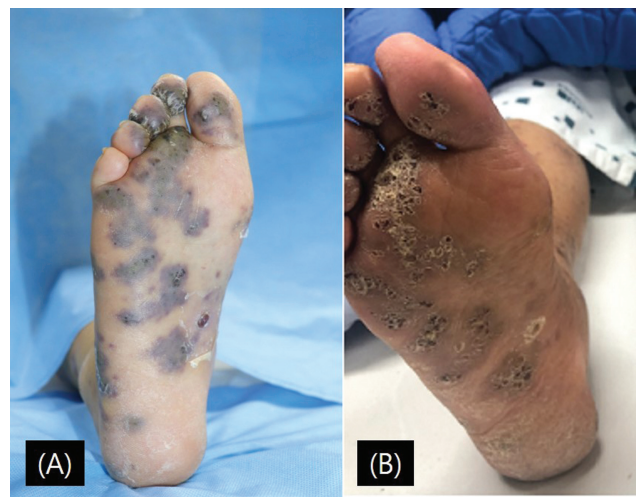
## Discussion

KS is a rare disease and typically involves the skin of the lower extremities. Previous cases about nonepidemic KS are related to HHV-8 infection. However, risk factors for HHV-8 transmission are incompletely understood and unclear. Some studies suggest potential risk factors for HHV-8 including age, increased number of sexual partners, and having a relationship with KS.<sup>6</sup>

According to previous studies, KS represents cutaneous lesions on various sites such as face, upper and lower limbs, trunk, and penis. Some studies describe KS lesions on gastrointestinal tract as well.<sup>4,6</sup> Nonepidemic KS, arising in individuals without AIDS, has been described in patients from Okinawa, Japan, in the early 1990s.<sup>7</sup> It is also usually



**Fig. 3** Positron emission tomography-computed tomography finding of the patient. It shows skin thickness with edematous change/multiple nodular hypermetabolic lesions in both upper extremities without discernible hypermetabolic lesion of other sites.



**Fig. 4** (A) Initial photographic finding. (B) The lesions improved after the radiation therapy, 30 Gy in 10 fractions for 11 days.

presents as nodules or plaques on the lower extremities. Lanternier et al reported the largest case series of nonepidemic KS to date in 2010.<sup>8</sup> Most patients (89%) in this study had at least one lesion found on the lower limb. Immunohistochemistry staining for HHV-8 showed strong immunopositivity.<sup>6</sup>

Several studies show positive results on the treatment of KS.<sup>7,9,10</sup> The therapy plan must consider the type of KS. For the treatment of KS, in the HHV-8-associated KS, the antiviral therapy is targeted at nullifying HHV-8 replication theoretically. It has been known that 50% of AIDS-KS respond to antiretroviral therapy (ART). Also, if its skin lesion was local, it could be treated with a local excision or topical cream.<sup>11</sup> In the iatrogenic KS, the chemical immune suppressive regimen such as rapamycin/sirolimus leads to the suppression.<sup>12</sup> Although its effect has not been extensively studied, interferon- $\alpha$  may be used as adjunctive therapy in conjunction with highly active ART in the advanced case with HIV-related KS.<sup>9</sup> In recent studies with HIV-related KS, ART with chemotherapy such as paclitaxel shows good results in the treatment.<sup>13</sup> The progression-free survival in non-HIV KS is average 11.7 months (range, 3–48 months), and overall survival is 28.5 months (range, 12–48 months) according to Rescigno et al.<sup>7</sup> Plus, May N. Tsao et al reported that 87% of skin KS lesion responded to radiotherapy (91% was classical type).<sup>14</sup> Studies show that 4 to 30% of the patients showed complete response with repetition of radiotherapy.<sup>7,10</sup> Radiotherapy is also known as one of the most efficient therapies for all types of KS. Higher dose per fractions like this case (>3 Gy per fraction) was not recommended with concomitant systemic treatment due to the risk of long-term complications.<sup>15</sup> As a first line therapy for HIV-related KS, ART was a choice of option with or without radiation and systemic therapy according to the National Comprehensive Cancer Network guidelines.<sup>11</sup> Due to widespread lesions on her body in our case, radiation therapy was first started in consultation with a hemato-oncologist.

KS is a rare angioproliferative tumor associated with HHV-8. Our patient was referred with a long-standing history of medication due to underlying diseases such as old cerebrovascular disease, hypertension, and back pain, and spontaneous skin lesion eruption on both upper and lower extremities not healing with discontinuation of the drugs. Therefore, accurate diagnosis is mandatory for improving disease control rate. In this case, she was thought to develop drug reactions at first. For the management of adverse cutaneous drug reactions, the ultimate goal is to discontinue the offending medication if possible. Misdiagnosis could happen at clinics because disease such as iatrogenic KS is very rare. Accurate diagnosis and proper treatment help to keep this disease under control. Thus, we present a rare case of KS in non-HIV elderly patient to share experiences. In elderly with multiple cutaneous tumors on extremities, KS must be kept in mind in differential diagnosis. Although KS is hardly thought to be concerned with the lesion because they have shown very rare occurrence, physicians should be alarmed to consider the diagnosis of the tumor. Since the patient was transferred to some other tertiary medical

center due to her personal reasons, the last photo of the patient was not taken. However, **Fig. 4** still shows remarkable improvement in the wound after the radiation therapy for 1 month.

#### Author Contributions

Conceptualization : H.J.C. Writing-original draft : T.H.K. Writing-review and editing: H.G.J. and S.Y.W. All authors read and approved the final manuscript.

#### Ethical Approval

This study was approved by the Institutional Review Board of Soonchunhyang University Cheonan Hospital (IRB No. 2020-11-056) and performed in accordance with the principles of the Declaration of Helsinki. The patient provided informed consent to publish.

#### Patient Consent

Informed consent was obtained from all individual participants included in the study.

#### Funding

This work was supported by the National Research Foundation of Korea grant funded by the Korea government (MSIT; 2020R1A2C1100891), and was supported by Soonchunhyang University research fund.

#### Conflict of Interest

None declared.

#### References

- Nickoloff BJ, Foreman KE. Etiology and pathogenesis of Kaposi's sarcoma. In: Dummer R, Nestle FO, Burg G., eds. *Cancers of the Skin*. vol. 160, Berlin, Heidelberg:: Springer;; 2002:331–342
- Kamiyango W, Villiera J, Silverstein A, Peckham-Gregory E, Campbell LR, El-Mallawany NK. Navigating the heterogeneous landscape of pediatric Kaposi sarcoma. *Cancer Metastasis Rev* 2019;38(04):749–758
- Tappero JW, Conant MA, Wolfe SF, Berger TG. Kaposi's sarcoma. Epidemiology, pathogenesis, histology, clinical spectrum, staging criteria and therapy. *J Am Acad Dermatol* 1993;28(03):371–395
- Schwartz RA. Kaposi's sarcoma: an update. *J Surg Oncol* 2004;87(03):146–151
- Nayak S, Acharjya B. Adverse cutaneous drug reaction. *Indian J Dermatol* 2008;53(01):2–8
- Vangipuram R, Tying SK. Epidemiology of Kaposi sarcoma: review and description of the nonepidemic variant. *Int J Dermatol* 2019;58(05):538–542
- Rescigno P, Di Trollo R, Buonerba C, et al. Non-AIDS-related Kaposi's sarcoma: a single-institution experience. *World J Clin Oncol* 2013;4(02):52–57
- Lanternier F, Lebbé C, Scharz N, et al. Kaposi's sarcoma in HIV-negative men having sex with men. *AIDS* 2008;22(10):1163–1168
- Krown SE, Lee JY, Lin L, et al. Interferon- $\alpha$ 2b with protease inhibitor-based antiretroviral therapy in patients with AIDS-associated Kaposi sarcoma. *J Acquir Immune Defic Syndr* 2006;41:5
- Oyucu Orhan S, Bilgehan Sahin A, Cubukcu E, et al. Efficacy of chemotherapeutics in classic and non-classic Kaposi sarcoma: a single-center retrospective real-world data. *Bosn J Basic Med Sci* 2021;21(06):746–751

- 11 Reid E, Suneja G, Ambinder RF, et al; CGC. AIDS-related Kaposi sarcoma, version 2.2019, NCCN Clinical Practice Guidelines in Oncology. *J Natl Compr Canc Netw* 2019;17(02):171–189
- 12 Schneider JW, Dittmer DP. Diagnosis and treatment of Kaposi sarcoma. *Am J Clin Dermatol* 2017;18(04):529–539
- 13 Krown SE, Moser CB, MacPhail P, et al; A5263/AMC066 protocol team. Treatment of advanced AIDS-associated Kaposi sarcoma in resource-limited settings: a three-arm, open-label, randomised, non-inferiority trial. *Lancet* 2020;395(10231):1195–1207
- 14 Tsao MN, Sinclair E, Assaad D, et al. Radiation therapy for the treatment of skin Kaposi sarcoma. *Ann Palliat Med* 2016;5(04):298–302
- 15 Lebbe C, Garbe C, Stratigos AJ, et al; European Dermatology Forum (EDF), the European Association of Dermato-Oncology (EADO) and the European Organisation for Research and Treatment of Cancer (EORTC) Diagnosis and treatment of Kaposi's sarcoma: European consensus-based interdisciplinary guideline (EDF/EADO/EORTC). *Eur J Cancer* 2019;114:117–127