Article published online: 2022-06-01

Risk Factors Associated with Malignant Transformation of Astrocytoma: Competing Risk Regression Analysis

Thara Tunthanathip[1] Surasak Sangkhathat[2,3] Kanet Kanjanapradit[4]

[1] Division of Neurosurgery, Department of Surgery, Faculty of Medicine, Prince of Songkla University, Songkhla, Thailand
[2] Department of Surgery, Faculty of Medicine, Prince of Songkla University, Songkhla, Thailand
[3] Department of Biomedical Sciences, Faculty of Medicine, Prince of Songkla University, Songkhla, Thailand
[4] Department of Pathology, Faculty of Medicine, Prince of Songkla University, Songkhla, Thailand

Address for correspondence Thara Tunthanathip, MD, PhD, Division of Neurosurgery, Department of Surgery, Faculty of Medicine Prince of Songkla University, Hat Yai, Songkhla, 90110, Thailand (e-mail: tsus4@hotmail.com).

AJNS 2022;17:3–10.

Abstract

Background Malignant transformation (MT) of low-grade astrocytoma (LGA) triggers a poor prognosis in benign tumors. Currently, factors associated with MT of LGA have been inconclusive. The present study aims to explore the risk factors predicting LGA progressively differentiated to malignant astrocytoma.

Methods The study design was a retrospective cohort study of medical record reviews of patients with LGA. Using the Fire and Gray method, the competing risk regression analysis was performed to identify factors associated with MT, using both univariate and multivariable analyses. Hence, the survival curves of the cumulative incidence of MT of each covariate were constructed following the final model.

Results Ninety patients with LGA were included in the analysis, and MT was observed in 14.4% of cases in the present study. For MT, 53.8% of patients with MT transformed to glioblastoma, while 46.2% differentiated to anaplastic astrocytoma. Factors associated with MT included supratentorial tumor (subdistribution hazard ratio [SHR] 4.54, 95% confidence interval [CI] 1.08–19.10), midline shift > 1 cm (SHR 8.25, 95% CI 2.18–31.21), and nontotal resection as follows: subtotal resection (SHR 5.35, 95% CI 1.07–26.82), partial resection (SHR 10.90, 95% CI 3.13–37.90), and biopsy (SHR 11.10, 95% CI 2.88–42.52).

Conclusion MT in patients with LGA significantly changed the natural history of the disease to an unfavorable prognosis. Analysis of patients' clinical characteristics from the present study identified supratentorial LGA, a midline shift more than 1 cm, and extent of resection as risk factors associated with MT. The more extent of resection would significantly help to decrease tumor burden and MT. In addition, future molecular research efforts are warranted to explain the pathogenesis of MT.

Keywords
- malignant transformation
- low-grade glioma
- high-grade glioma
- diffuse astrocytoma

published online
June 1, 2022

DOI https://doi.org/10.1055/s-0042-1748789.
ISSN 2248-9614.

© 2022. Asian Congress of Neurological Surgeons. All rights reserved.
This is an open access article published by Thieme under the terms of the Creative Commons Attribution-NonDerivative-NonCommercial-License, permitting copying and reproduction so long as the original work is given appropriate credit. Contents may not be used for commercial purposes, or adapted, remixed, transformed or built upon. (https://creativecommons.org/licenses/by-nc-nd/4.0/)
Thieme Medical and Scientific Publishers Pvt. Ltd., A-12, 2nd Floor, Sector 2, Noida-201301 UP, India

Introduction

Astrocytomas are divided into four grades based on the 2016 World Health Organization (WHO) central nervous system (CNS) tumor classification. These tumors are usually categorized as low-grade (LGAs) and high-grade astrocytomas. LGAs, including pilocytic astrocytoma (WHO I) and diffuse astrocytoma (WHO II), are benign tumors that have a prognosis significantly longer than high-grade tumors. The median survival time of diffuse astrocytoma ranges from 44 to 57 months, while anaplastic astrocytoma (WHO III) and glioblastoma prognosis (WHO IV) had a median survival time ranging from 15 to 24 months and 11 to 14 months, respectively.[1–3]

Malignant transformation (MT) of low-grade gliomas, including fibrillary astrocytoma, diffuse astrocytoma, oligodendroglioma, mixed oligoastrocytoma, and ganglioglioma, has been reported in 19.5 to 21% cases.[4–7] In addition, Broniscer et al revealed the 10-year cumulative incidence of MT was 3.8%, and the median time of MT was 5.1 years.[7] Although the pathogenesis of MT has been unknown, factors associated with this rare event have been reported. Murphy et al reported older age, male gender, multiple tumors, chemotherapy alone, and the extent of resection were potential predictors of MT, whereas common genetic profiling of MT was TP53 overexpression, deletions of *RB1*, *CDKN2A*, and PTEN pathway abnormalities.[6,7] However, the heterogeneity of the study population was observed from previous studies. Oligodendroglioma, mixed oligoastrocytoma, and other gliomas were included in the study.[4–7]

In addition, benign tumors can develop to malignancy when patients have to wait for long-term follow-ups. If death occurs before MT during the follow-up period, the MT rate will be changed from another competing event.[8] From this concept, we performed a competing risk regression to evaluate clinical characteristics associated with MT in LGA patients.

Materials and Methods

Study Population

According to the primary objective, the sample size was calculated using the log-rank test formula.[9] Using data from the study of Murphy et al,[6] total resection was significantly associated with MT (hazard ratio [HR] 0.47, 95% confidence interval [95% CI] 0.31–0.72) and proportion of total resection group was found in 34.9%. Therefore, these parameters were performed for sample size estimation at α of 0.05 and β of 0.2 via Web-based calculator.[10] The sample size comprised at least 61 patients for testing the hypothesis.

The study was conducted with a medical record review and included all patients newly diagnosed with pilocytic astrocytoma and diffuse astrocytoma between January 2003 and December 2018 in the tertiary hospital of southern Thailand. Some patients were part of the multicenter CNS tumor registry of Thailand, which was published and had the endpoint of study with death.[1] The histological diagnosis was confirmed by a pathologist, according to the 2016 WHO classification of CNS tumors.[11]

The exclusion criteria were as follows: patients with mixed oligoastrocytoma or other gliomas and unavailable imaging. Moreover, patients who obtained tissue for diagnosis by free-hand biopsy or ultrasound-guided biopsy were excluded, whereas patients with a stereotactic biopsy were not excluded in the present study. Preoperative, postoperative, and follow-up magnetic resonance imaging (MRI) were reviewed by a neurosurgeon, such as tumor size, location, side, and midline shift. Moreover, a tumor volume calculation was performed based on a prior study of Tunthanathip and Madteng.[12]

The extent of resection was assessed from postoperative imaging and was divided into four groups as follows: total resection (no visible residual tumor both enhanced and unenhanced portions), subtotal resection ($\geq$ 90% of resection), partial resection ($>$ 50% of resection), and biopsy ($<$ 5%).[13,14]

In our institute, the postoperative MRIs were routinely performed every 3 to 6 months for the follow-up purpose. We assess each visit's outcome according to the revised Response Evaluation Criteria in Solid Tumors guidelines (version 1.1). In detail, progressive disease was defined as an increased size of tumors of at least 20%, the absolute growth of tumors of at least 5 mm, or the appearance of one or more new lesions.[15]

MT was defined as a tumor progressively differentiated to high-grade astrocytoma with histology-confirmed evidence of at least WHO III astrocytoma.[4–7] Besides, patients' death status was assessed from the Office of Central Civil-Registration on June 30, 2020. A human research ethics committee approved the present study. The present study did not require informed consent from patients because the study design was the retrospective approach. Besides, the patients' identification numbers were encoded before analysis.

Statistical Analysis

The endpoint of the study was the MT from which the starting date was the date of diagnosis of LGA and the endpoint of the study was the date of histology-confirmed diagnosis of MT by a pathologist or until June 2020 as the exiting date.

Descriptive statistics were used for describing the baseline characteristics of the patients. Kaplan–Meier curve and log-rank test were performed for comparing prognosis between the MT group and non-MT group. Using Cox regression analysis, the effect of MT on survival time was analyzed and reported as a HR with 95% CI.

Using Nelson–Aalen estimator, nonparametric test was performed to describe MT's overall cumulative hazard rate function. Because death is another event that affects the rate at which MT events occur, we use Fine and Gray's competing risk regression analysis to assess the risk associated with MT.[16,17] The subdistribution HR (SHR) was used instead of HR to report MT's risk in both univariate and multivariable analyses. For fitting the model, candidate variables that had a p-value of 0.1 or less in univariate analysis were analyzed in a

 © 2022. Asian Congress of Neurological Surgeons. All rights reserved.

multivariable model with backward stepwise selection. The proposed model was considered by the Akaike information criterion (AIC). After fitting the model, each covariate's survival curve was plotted for estimating the cumulative incidence of MT in each covariate.[18,19] Statistical analysis was performed using Stata v16 (StataCorp, Texas, United States, SN 401606310234).

Results

Initially, 101 patients who were newly diagnosed with LGA were reviewed. Eleven patients were excluded with unavailable imaging and final diagnosis of mixed glioma. Therefore, 90 patients were analyzed, and baseline clinical characteristics were summarized, as shown in ►**Table 1**.

There were nearly equal proportions of males and females, 52.2 and 47.8%, respectively. Seizure, progressive headache, and hemiparesis were the first and third common clinical presentation of the eligible patients. The typical location of pilocytic astrocytoma was the cerebellum and suprasellar region of 7/14 (50.0%) and 5/14 (35.7%), while the frontal lobe, temporal lobe, and corpus callosum were the common location of diffuse astrocytoma in 32/72 (44.4%), 16/72 (22.2%), and 8 (11.1%), respectively. Moreover, 91% of astrocytoma with WHO grade II were in the supratentorial location, while more than half (58.1%) of WHO grade I astrocytoma were placed in the infratentorial location (chi-square test, p-value < 0.001).

All eligible patients underwent an operation for histological diagnosis. Therefore, the first diagnosis was diffuse astrocytoma (80%), pilocytic astrocytoma (15.6%), gemistocytic astrocytoma (2.2%), and pleomorphic xanthoastrocytoma (2.2%). Total tumor resection was observed in 14.4%,

Table 1 Baseline characteristics of patients newly diagnosed low-grade astrocytoma ($N = 90$)

Factor	*N* (%)
Gender	
Male	47 (52.2)
Female	43 (47.8)
Mean age, year (SD)	35.7 (19.3)
Signs and symptoms	
Seizure	46 (51.1)
Progressive headache	37 (41.1)
Weakness	20 (22.2)
Visual disturbance	9 (10.0)
Ataxia	6 (6.7)
Behavior change	1 (1.1)
Preoperative Karnofsky Performance Status score	
< 80	28 (31.1)
≥ 80	62 (68.9)
Location	
Frontal lobe	33 (36.7)
Temporal lobe	16 (17.8)
Corpus callosum	10 (11.1)
Cerebellum	9 (10.0)
Sellar/suprasellar area	6 (6.7)
Parietal lobe	4 (4.4)
Brainstem	3 (3.3)
Basal ganglion	3 (3.3)
Thalamus	3 (3.3)
Occipital lobe	1 (1.1)
Periventricular area	1 (1.1)
Pineal gland	1 (1.1)
Site of tumor	
Left	33 (36.7)
Right	33 (36.7)
Midline	22 (24.4)
Bilateral sites (for multiple lesions)	2 (2.2)
Mean maximum diameter of tumor, cm (SD)	5.5 (2.0)
Mean tumor volume, cm^3 (SD)	58.0 (48.0)
Eloquent area	35 (38.9)
Preoperative hydrocephalus	24 (26.7)
Preoperative leptomeningeal dissemination	5 (5.6)
Preoperative multiple lesions	4 (4.4)
Mean preoperative midline shift, cm (SD)	4 (4.4)
Extent of resection	
Total resection	13 (14.4)
Subtotal resection	17 (18.9)
Partial resection	26 (28.9)
Stereotactic biopsy	34 (37.8)
Postoperative radiotherapy	58 (64.4)
Postoperative chemotherapy	
No	87 (95.6)
Temozolomide	2 (2.2)
Vincristine and cyclophosphamide	2 (2.2)
Postoperative Karnofsky Performance Status score	
< 80	36 (40.0)
≥ 80	54 (60.0)
Histology of the first diagnosis	
Pilocytic astrocytoma	14 (15.6)
Diffuse astrocytoma	72 (80.0)
Gemistocytic astrocytoma	2 (2.2)
Pleomorphic xanthoastrocytoma	2 (2.2)

Abbreviation: SD, standard deviation.

 © 2022. Asian Congress of Neurological Surgeons. All rights reserved.

Table 2 Characteristics of patients with malignant transformation ($N = 13$)

Factor	*N* (%)
MT	13/90 (14.4)
Progressive disease without MT	36/90 (40.0)
Extent of resection at MT	
Subtotal resection	6 (46.2)
Partial resection	6 (46.2)
Biopsy	1 (7.7)
History of exposure RT	
No	12 (92.3)
Radiotherapy before MT	1 (7.7)
Histology at MT	
Anaplastic astrocytoma	6 (46.2)
Glioblastoma	7 (53.8)

Abbreviations: MT, malignant transformation; RT, radiotherapy.

and more than two-thirds of patients received postoperative adjuvant radiotherapy. Also, five patients received postoperative chemotherapy.

MT occurred in 14.4% of the study population when the median time of follow-up was 20 months (interquartile range [IQR] 36 months), and median time of MT was 13 months (IQR 21.5 months). The clinical characteristics of patients who developed MT during the follow-up period are listed in ►**Table 2**. More than half of MT was transformed into glioblastoma, whereas 46.2% of MT turned to anaplastic astrocytoma, as shown in ►**Fig. 1A–F** and ►**Fig. 2A–D**. Moreover, almost all patients with MT had never been exposed to radiotherapy before, and all of MT patients had never received adjuvant chemotherapy before MT.

As shown in ►**Fig. 3**, MT of LGA was significantly associated with poor prognosis (log-rank test, $p = 0.006$). The median survival time of patients without MT was 78 months (95% CI: 55.2–100.7), whereas patients with MT had a median survival time of 32.0 months (95% CI: 11.3–52.6). Using Cox regression analysis, MT significantly affected shortening survival time with HR of 2.46 (95% CI: 1.26–4.80, *p*-value 0.008).

MT was the failure event in the present study that is likely to occur over time, as shown in ►**Fig. 4A**. Patients with LGA risk to MT were 8.2% in 1-year probability, and the 2-year risk of MT in patients was 16.6%. The MT risk was steady at 19.4% when patients were followed-up in the third year, as shown in ►**Table 3**.

Factor Associated with MT by the Competing Risk Regression Analysis

Various clinical factors were analyzed in the univariate analysis by competing risk regression. Significant factors comprised supratentorial tumor (SHR 7.68, 95% CI: 1.78–33.1), midline shift of more than 1 cm from preoperative imaging (SHR 10.29, 95% CI: 2.89–35.67), and nontotal resection as follows: subtotal resection (SHR 12.51, 95% CI: 2.59–60.44), partial resection (SHR 21.20, 95% CI: 7.02–64.27), and biopsy (SHR 16.57, 95% CI: 4.68–58.40). In addition, tumors with WHO grade II tended to risk MT.

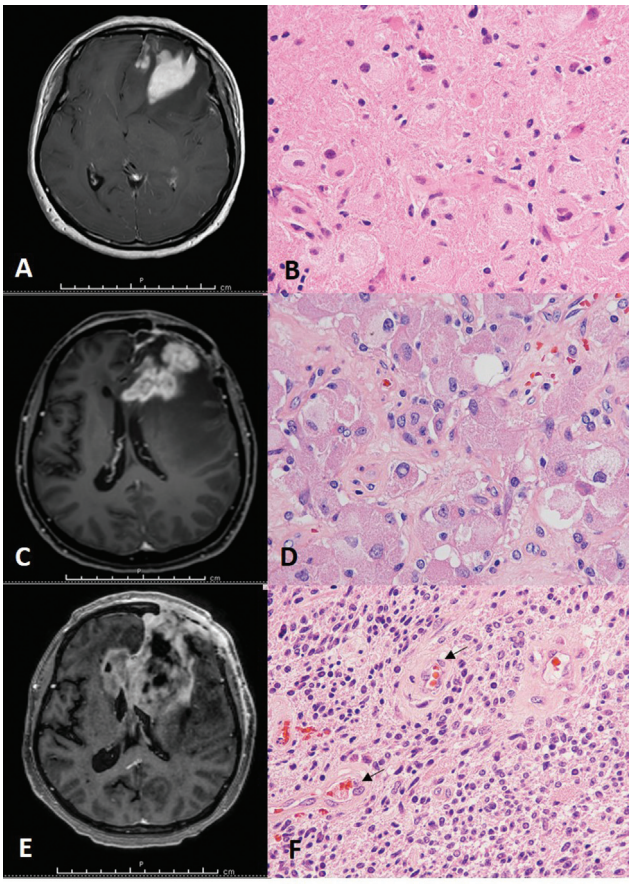

Fig. 1 Illustrative cases of malignant transformation of diffuse astrocytoma. (**A**) Preoperative T1W postcontrast magnetic resonance imaging (MRI) showing left frontal mass. (**B**) Hematoxylin and eosin (H&E) stain showing moderate cellularity with nuclear atypia of astrocytes. (**C**) T1W postcontrast MRI at 4 months later showing progressive left frontal mass with corpus callosum involvement. (**D**) H&E stain showing an anaplastic transformation, including astrocytes with pleomorphism. (**E**) T1W postcontrast MRI at 8 months later showing left frontal tumor crossing to the right side. (**F**) H&E stain showing glioblastoma multiforme (GBM) features, including hypercellularity of astrocytes and endothelial proliferation (*arrow*).

For multivariable analysis, candidate factors were analyzed with backward stepwise selection. The model which had the least AIC comprised supratentorial tumor (SHR 4.54, 95% CI: 1.08–19.10), midline shift of more than 1 cm from preoperative imaging (SHR 8.25, 95% CI: 2.18–31.21), and nontotal resection as follows: subtotal resection (SHR 5.35, 95% CI: 1.07–26.82), partial resection (SHR 10.90, 95% CI: 3.13–37.90), and biopsy (SHR 11.10, 95% CI: 2.88–42.52), as shown in ►**Table 4**. Subsequently, the significant covariates in the model have constructed the survival curve for estimating the cumulative incidence of MT in each covariate, as shown in ►**Fig. 4B–D**.

Discussion

MT of LGA is the process by which benign astrocytes turn malignant. When MT developed, the prognosis of patients

 © 2022. Asian Congress of Neurological Surgeons. All rights reserved.

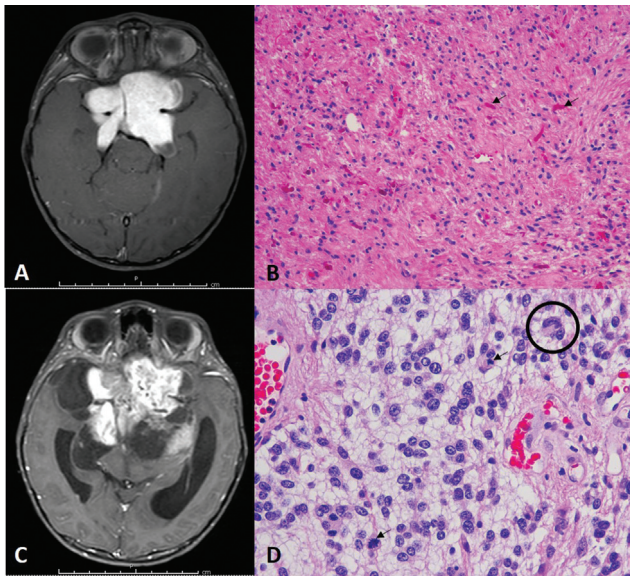

Fig. 2 Anaplastic transformation illustrative case of pilocytic astrocytoma. (**A**) Preoperative T1W postcontrast magnetic resonance imaging (MRI) showing an enhanced suprasellar mass. (**B**) Hematoxylin and eosin (H&E) stain showing astrocytic cells neoplastic astrocytes in the glial fibrillary background, with numerous Rosenthal fibers (*arrows*). (**C**) T1W postcontrast MRI at 3 years later showing the larger residual tumor. (**D**) H&E stain showing an anaplastic transformation, including increased cellularity and pleomorphism of tumor cells with multinucleated cells (*circle*) and mitoses (*arrows*).

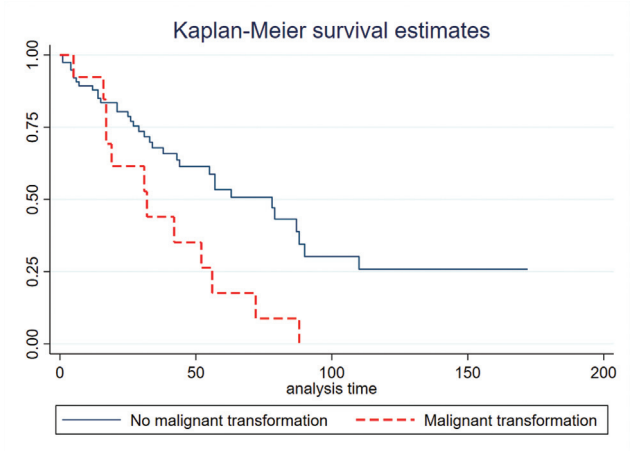

Fig. 3 Kaplan–Meier curve showing malignant transformation group had a significantly poorer prognosis than nonmalignant transformation (log-rank test, $p = 0.006$).

with LGA accelerated downward and had a significantly shorter survival time than the non-MT group. In the present study, MT of LGA developed in 14.4%, and the median time to MT was 13 months. The results in the present study were in concordance with prior studies. The incidence of MT in low-grade gliomas has been reported in 3.8 to 21%,[6,7] and Chaichana et al reported the median latency of MT ranging from 13 to 66 months.[4] However, various methodologies and definitions from prior studies were observed in the literature

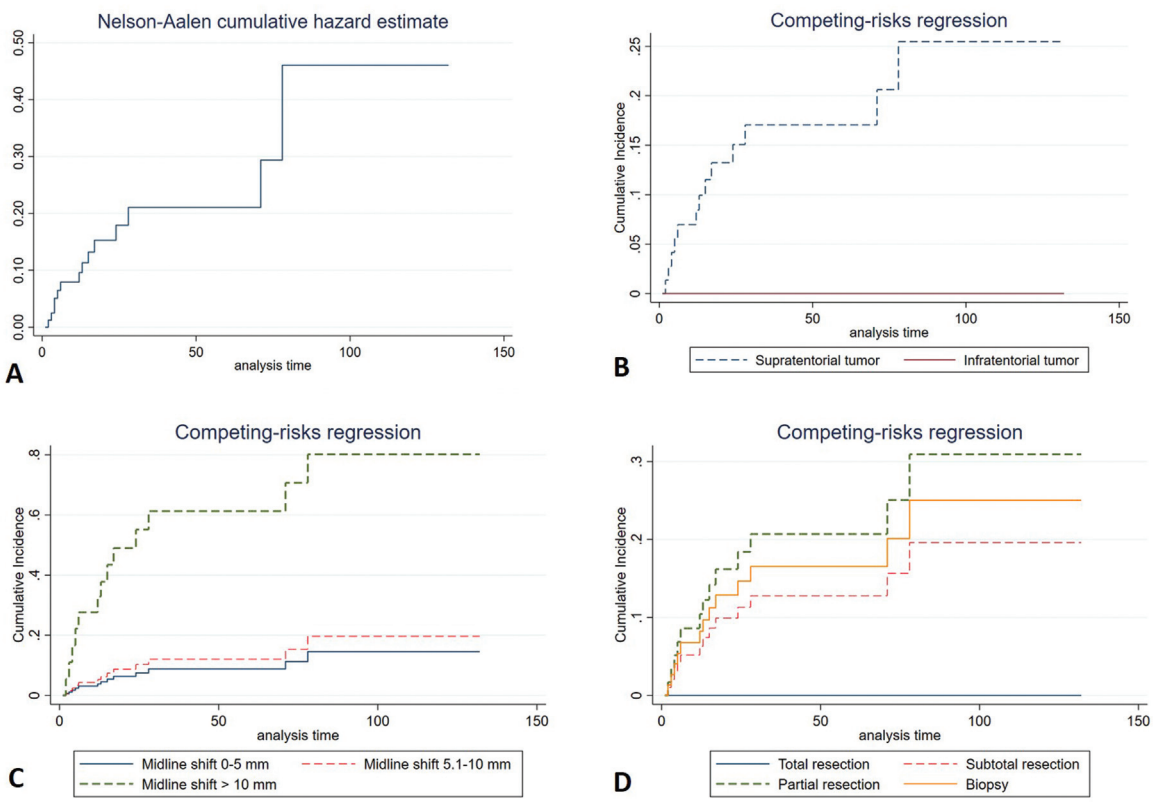

Fig. 4 Survival curve of the cumulative incidence of malignant transformation (MT) for each factor. (**A**) Nelson–Aalen estimator of the cumulative hazard function. (**B**) Supratentorial tumor. (**C**) Midline shift on preoperative imaging. (**D**) The extent of resection.

 © 2022. Asian Congress of Neurological Surgeons. All rights reserved.

Table 3 Risk of malignant transformation in patients with low-grade astrocytoma overtime

Follow-up time (mo)	Proportion of risk to malignant transformation (95% CI)
12	8.2% (3.7–1.8)
24	16.1% (8.7–31.4)
36	19.7% (10.6–36.7)
48	19.7% (10.6–36.7)
60	19.7% (10.6–36.7)

Abbreviation: CI, confidence interval.

Table 4 Univariate and multivariable analysis for malignant transformation of low-grade astrocytoma

Factor	Univariate analysis		Multivariable analysis	
	SHR (95% CI)	*p*-Value	SHR (95% CI)	*p*-Value
Age, y				
< 40	Ref			
≥ 40	0.75 (0.24–2.34)	0.62		
Gender				
Male	Ref			
Female	1.22 (0.41–3.57)	0.36		
Seizure				
No	Ref			
Yes	0.55 (1.87–1.61)	0.27		
Preoperative KPS				
< 80	Ref			
≥ 80	1.03 (0.33–3.20)	0.95		
Location				
Frontal lobe[a]	2.46 (0.81–7.43)	0.12		
Temporal lobe[a]	0.73 (0.17–3.01)	0.67		
Corpus callosum[a]	2.19 (0.45–10.66)	0.32		
Eloquent area[a]	0.88 (0.29–2.63)	0.82		
Sellar/suprasellar area[a]	1.44 (0.22–9.29)	0.69		
Supratentorial tumor[a]	7.68 (1.78–33.1)	< 0.001	4.54 (1.08–19.10)	< 0.001
WHO grade I[a]	0.54 (0.06–4.23)	0.10	1.14 (0.10–12.92)	0.91
Midline shift, cm				
0–0.50	Ref		Ref	
0.51–1.00	1.39 (0.34–5.57)	0.63	1.18 (0.30–4.53)	0.80
> 1.00	10.29 (2.89–35.67)	< 0.001	8.25 (2.18–31.21)	0.002
Extent of resection				
Total resection	Ref		Ref	
Subtotal resection	12.51 (2.59–60.44)	0.001	5.35 (1.07–26.82)	< 0.001
Partial resection	21.20 (7.02–64.27)	0.001	10.90 (3.13–37.90)	< 0.001
Biopsy	16.57 (4.68–58.40)	0.001	11.10 (2.88–42.52)	< 0.001
Postoperative RT[a]	1.03 (0.31–3.36)	0.96		
Postoperative KPS				
< 80	Ref			
≥ 80	0.51 (0.06–3.96)	0.52		

Abbreviations: CI, confidence interval; KPS: Karnofsky Performance Status; RT, radiotherapy; SHR, subdistribution hazard ratio; WHO, World Health Organization.
[a]Data show only "yes group" while reference groups (no group) are hidden.

 © 2022. Asian Congress of Neurological Surgeons. All rights reserved.

review. Heterogeneity of low-grade gliomas such as fibrillary astrocytoma, oligodendroglioma, and mixed glioma may be an influence on MT rate and time to MT, whereas the study population of the present study was focused on astrocytoma. In addition, MT in prior publications included both histology-confirmed MT and imaging characteristic MT,[6] whereas MT in the present study excluded cases without a histological diagnosis.

Clinical predictors associated with MT in the present study were observed as follows: supratentorial LGA, a preoperative midline shift of more than 1 cm, and extent of resection. Supratentorial astrocytoma was significantly prone toward MT, these may be related to the WHO grading of LGA. Although the WHO grading was not significantly associated with MT, LGA with WHO grade II tended to be MT's risk factor. Chaichana et al reported that fibrillary astrocytoma, which is WHO grade II, according to the 2007 CNS tumor classification, was significantly associated with MT.[4]

Midline shift of more than 1 cm was one of the predictors of MT in the present study. As the author's knowledge, this factor has never been reported as a MT predictor, but several studies observed greater tumor size or volume were associated with MT.[4,20,21] Peritumoral edema has been reported as a typical finding of malignant gliomas and contributed as a prognostic factor.[22] These regions promote tumor cell invasion from the blood–brain barrier impairment that may be the mechanism of MT.[23,24] Therefore, our findings that a midline shift of more than 1 cm increased the risk of MT should be further explored with a larger cohort or meta-analysis in the future.

The extent of resection has been considered as a predictor associated with MT in previous studies. Kiliç et al and Murphy et al reported that total tumor resection were risk factors of MT. Total tumor resection is the critical factor that modified the patient's prognosis and MT event because residual tumors could transform over time.[6,25] Moreover, total tumor resection has broadly been known as a prognostic factor for increased survival time.[26–28] When patients develop the event of death competing MT event, the probability of MT will be directly interfered. Hence, the new survival analysis concept has been published in several neurosurgical conditions such as meningioma, metastases, and cerebral aneurysms.[29–31] Additionally, multiple lesions of low-grade glioma were reported as a preventative factor of MT.[6] The findings may be an effect from competing events of patients with multiple lesions associated with poor prognosis.[32,33]

Several variables have been reported as MT predictors, but these are still inconclusive. Tom et al reported that males were associated with MT, while females were a risk factor of MT in the study of Murphy et al. Furthermore, older age was reported as related to MT,[6] whereas Rotariu et al observed that MT frequently was found in younger patients.[34]

Although the present study is the first article proposing MT predictors of LGA to the authors' knowledge by Fine and Gray's method, several limitations of the study should be acknowledged. First, the biopsy procedure may cause inadequate tissue diagnosis of MT. We managed this bias by eliminating cases that underwent nonstereotactic biopsy. However, the stereotactic biopsy was accepted in the present study because this procedure has been accepted to take adequate tissue for diagnosis in prior studies.[6,18,35] Secondly, the study design may lead to bias from retrospective studies. However, the prospective study also has limitations by conducting to explore predictors of MT. Because MT does not frequently occur with time-consuming differentiations, a longitudinal follow-up is needed in prospective cohort study design. We used the multivariable analysis to adjust the results and confounders.[36] Moreover, the propensity score approach and meta-analysis are alternative ways to explore focused interventions or predictors.[36–38] Third, the present study reported that only clinical predictors of MT and genetic investigation should be conducted. From molecular findings, the pathogenesis of MT has been discovered and explains clinical predictors. Glioma with wild-type *IDH* was associated with MT in the study of Tom et al,[20] while Broniscer et al studied nine tissue samples of MT and found that the common molecular pathways of MT were TP53 overexpression, alteration of PTEN, *RB1*, and *CDKN2A*.[7] Moreover, Park et al studied in three MT patients with *IDH1*-mutated gliomas using next-generation sequencing technology which found an altered genetic expression in U2AF2, TCF12, and ARID1A.[39]

Conclusion

MT in patients with LGA significantly changed the natural history of the disease to an unfavorable prognosis. Supratentorial LGA, a midline shift of more than 1 cm, and the extent of resection as risk factors associated with MT. Particularly total tumor resection, the more extent of resection would significantly help to decrease tumor burden and MT. In addition, future molecular research efforts are warranted to explain the pathogenesis of MT.

Authors' Contributions

T.T.: Concept, study design, data collection, statistical analysis, literature overview, and discussion. S.S.: Concept, study design, data collection, literature overview, and discussion. K.K.: Concept, data collection, and discussion.

Funding

The study was supported by the Health Systems Research Institute (Thailand; grant no. 63-078).

Conflict of Interest

None declared.

References

1 Tunthanathip T, Ratanalert S, Sae-Heng S, et al. Prognostic factors and nomogram predicting survival in diffuse astrocytoma. J Neurosci Rural Pract 2020;11(01):135–143

2 Dong X, Noorbakhsh A, Hirshman BR, et al. Survival trends of grade I, II, and III astrocytoma patients and associated clinical

 © 2022. Asian Congress of Neurological Surgeons. All rights reserved.

practice patterns between 1999 and 2010: a SEER-based analysis. Neurooncol Pract 2016;3(01):29–38
3 Stupp R, Mason WP, van den Bent MJ, et al; European Organisation for Research and Treatment of Cancer Brain Tumor and Radiotherapy Groups National Cancer Institute of Canada Clinical Trials Group. Radiotherapy plus concomitant and adjuvant temozolomide for glioblastoma. N Engl J Med 2005;352(10):987–996
4 Chaichana KL, McGirt MJ, Laterra J, Olivi A, Quiñones-Hinojosa A. Recurrence and malignant degeneration after resection of adult hemispheric low-grade gliomas. J Neurosurg 2010;112(01): 10–17
5 Sakarunchai I, Sangthong R, Phuenpathom N, Phukaoloun M. Free survival time of recurrence and malignant transformation and associated factors in patients with supratentorial low-grade gliomas. J Med Assoc Thai 2013;96(12):1542–1549
6 Murphy ES, Leyrer CM, Parsons M, et al. Risk factors for malignant transformation of low-grade glioma. Int J Radiat Oncol Biol Phys 2018;100(04):965–971
7 Broniscer A, Baker SJ, West AN, et al. Clinical and molecular characteristics of malignant transformation of low-grade glioma in children. J Clin Oncol 2007;25(06):682–689
8 Klein JP. Modelling competing risks in cancer studies. Stat Med 2006;25(06):1015–1034
9 Schoenfeld DA. Sample-size formula for the proportional-hazards regression model. Biometrics 1983;39(02):499–503
10 Kohn MA, Senyak J. Sample Size Calculators [Internet]. Accessed May 25, 2021 at: https://sample-size.net/sample-size-survival-analysis/
11 Gupta A, Dwivedi T. A simplified overview of World Health Organization classification update of central nervous system tumors 2016. J Neurosci Rural Pract 2017;8(04):629–641
12 Tunthanathip T, Madteng S. Factors associated with the extent of resection of glioblastoma. Precis Cancer Med 2020;3:12
13 Im JH, Hong JB, Kim SH, et al. Recurrence patterns after maximal surgical resection and postoperative radiotherapy in anaplastic gliomas according to the new 2016 WHO classification. Sci Rep 2018;8(01):777
14 Tunthanathip T, Kanjanapradit K. Glioblastoma multiforme associated with arteriovenous malformation: a case report and literature review. Ann Indian Acad Neurol 2020;23(01):103–106
15 Schwartz LH, Litière S, de Vries E, et al. RECIST 1.1-update and clarification: from the RECIST committee. Eur J Cancer 2016; 62:132–137
16 Fine JP, Gray RJ. A proportional hazards model for the subdistribution of a competing risk. J Am Stat Assoc 1999;94:496–509
17 Austin PC, Fine JP. Practical recommendations for reporting Fine-Gray model analyses for competing risk data. Stat Med 2017;36 (27):4391–4400
18 Stata.com. [Internet]. Competing-risks regression. Accessed May 9, 2020 at: https://www.stata.com/features/overview/competing-risks-regression/
19 Stata.com. [Internet]. stcurve-Stata. Accessed May 9, 2020 at: https://www.stata.com/manuals/ststcurve.pdf
20 Tom MC, Park DYJ, Yang K, et al. Malignant transformation of molecularly classified adult low-grade glioma. Int J Radiat Oncol Biol Phys 2019;105(05):1106–1112
21 Kreth FW, Faist M, Rossner R, Volk B, Ostertag CB. Supratentorial World Health Organization Grade 2 astrocytomas and oligoastrocytomas. A new pattern of prognostic factors. Cancer 1997;79 (02):370–379
22 Wu CX, Lin GS, Lin ZX, et al. Peritumoral edema on magnetic resonance imaging predicts a poor clinical outcome in malignant glioma. Oncol Lett 2015;10(05):2769–2776
23 Blystad I, Warntjes JBM, Smedby Ö, Lundberg P, Larsson EM, Tisell A. Quantitative MRI for analysis of peritumoral edema in malignant gliomas. PLoS One 2017;12(05):e0177135
24 Lin ZX. Glioma-related edema: new insight into molecular mechanisms and their clinical implications. Chin J Cancer 2013;32(01): 49–52
25 Kiliç T, Ozduman K, Elmaci I, Sav A, Necmettin Pamir M. Effect of surgery on tumor progression and malignant degeneration in hemispheric diffuse low-grade astrocytomas. J Clin Neurosci 2002;9(05):549–552
26 Majchrzak K, Kaspera W, Bobek-Billewicz B, et al. The assessment of prognostic factors in surgical treatment of low-grade gliomas: a prospective study. Clin Neurol Neurosurg 2012;114(08):1135–1144
27 Sanai N, Berger MS. Glioma extent of resection and its impact on patient outcome. Neurosurgery 2008;62(04):753–764, discussion 264–266
28 Kaewborisutsakul A, Sae-Heng S, Kitsiripant , et al. The first awake craniotomy for eloquent glioblastoma in Southern Thailand. J Health Sci Med Res. 2020;38(01):61–65
29 Champeaux C, Houston D, Dunn L, Resche-Rigon M. Intracranial WHO grade I meningioma: a competing risk analysis of progression and disease-specific survival. Acta Neurochir (Wien) 2019. Doi: 10.1007/s00701-019-04096-9
30 Lucas JT Jr, Colmer HG IV, White L, et al. Competing risk analysis of neurologic versus nonneurologic death in patients undergoing radiosurgical salvage after whole-brain radiation therapy failure: who actually dies of their brain metastases? Int J Radiat Oncol Biol Phys 2015;92(05):1008–1015
31 Kimura T, Ochiai C, Kawai K, Morita A, Saito N. How definitive treatment affects the rupture rate of unruptured cerebral aneurysms: a competing risk survival analysis. J Neurosurg 2019;132 (04):1062–1067
32 Singh G, Mehrotra A, Sardhara J, et al. Multiple glioblastomas: are they different from their solitary counterparts? Asian J Neurosurg 2015;10(04):266–271
33 Tunthanathip T, Sangkhathat S, Tanvejsilp P, Kanjanapradit K. The clinical characteristics and prognostic factors of multiple lesions in glioblastomas. Clin Neurol Neurosurg 2020;195:105891
34 Rotariu D, Gaivas S, Faiyad Z, et al. Malignant transformation of low grade gliomas into glioblastoma a series of 10 cases and review of the literature. Romanian Neurosurgery. 2010;17(04):403–412
35 Taweesomboonyat C, Tunthanathip T, Sae-Heng S, Oearsakul T. Diagnostic yield and complication of frameless stereotactic brain biopsy. J Neurosci Rural Pract 2019;10(01):78–84
36 Pourhoseingholi MA, Baghestani AR, Vahedi M. How to control confounding effects by statistical analysis. Gastroenterol Hepatol Bed Bench 2012;5(02):79–83
37 Tunthanathip T, Sangkhathat S. Temozolomide for patients with wild-type isocitrate dehydrogenase (IDH) 1 glioblastoma using propensity score matching. Clin Neurol Neurosurg 2020;191:105712
38 Tunthanathip T, Mamueang K, Nilbupha N, Maliwan C, Bejrananda T. No association between isocitrate dehydrogenase 1 mutation and increased survival of glioblastoma: a meta-analysis. J Pharm Negat Results 2020;11(01):1–8
39 Park CK, Park I, Lee S, et al. Genomic dynamics associated with malignant transformation in IDH1 mutated gliomas. Oncotarget 2015;6(41):43653–43666

 © 2022. Asian Congress of Neurological Surgeons. All rights reserved.