



# Transradial Embolization of Hemorrhagic Adrenal Myelolipoma

Griffin Mcnamara<sup>1</sup> Ahmed Abdelbaki<sup>1</sup> Jeremy Mccarver<sup>2</sup> David Owens<sup>1</sup> Ali Malik<sup>1</sup>  
Keith Pereira<sup>1</sup> Alejandro Mendez<sup>1</sup>

<sup>1</sup> Department of Interventional Radiology, Saint Louis University, Missouri, United States

<sup>2</sup> Department of Radiology, Saint Louis University, Saint Louis, Missouri, United States

Address for correspondence Ahmed Abdelbaki, MD, Department of Interventional Radiology, Saint Louis University, Saint Louis, MO 63103, United States (e-mail: a.baki@aol.com).

Arab J Intervent Radiol 2022;6:99–101.

## Abstract

Adrenal myelolipomas are largely benign, non-functioning, and asymptomatic adrenal tumors found incidentally on imaging. These tumors have an extremely low incidence and are exceedingly rare. We report a case of trans-radial embolization of hemorrhagic adrenal myelolipoma.

## Keywords

- ▶ adrenal
- ▶ embolization
- ▶ myelolipoma

## Introduction

Adrenal myelolipomas (ML) are a rare, benign tumor with an autopsy prevalence of 0.1 to 0.2% that most commonly present as incidental adrenal tumors (incidentalomas) on imaging.<sup>1</sup> MLs are followed clinically with or without radiologic follow-up, and intervention is not necessary unless patients develop symptoms of mass effect, endocrine function, or the mass is larger than 4–7 cm due to increased risk for spontaneous retroperitoneal hemorrhage.<sup>1,2</sup> Literature on the management of acute hemorrhage from ML is limited. Several reports show that adrenal artery embolization efficacious in the treatment of symptomatic incidentalomas and acute hemorrhage.<sup>3</sup> Here, we show radial access is suitable for adrenal artery embolization and highlight the use of minimally invasive techniques in the treatment of spontaneous hemorrhage from ML.

## Case Presentation

An 84-year-old man with a known right-sided adrenal myelolipoma, coronary artery disease, atrial flutter, mitral valve

regurgitation on rivaroxaban, prostate cancer, type II diabetes mellitus, chronic malnutrition, and hypothyroidism presented with acute-onset intense, right-sided back, and abdominal pain. He denied any recent trauma or falls. Workup revealed worsening anemia, elevated d-dimer, and lactic acidosis. Vital signs remained stable throughout admission.

We performed a computer tomography (CT) angiogram that revealed a large hematoma with active extravasation posterior to the right lobe of the liver, adjacent to the patient's myelolipoma (▶ Fig. 1). There were also two hepatic cysts in the right and left lobes, and a flash filling hemangioma in the right lobe. The ML was found incidentally on MRI 13 years ago and monitored by subsequent CT scans. The lesion had previously been stable, but was noted to be 1.6 × 3.3 × 4.1 cm at the time of admission–3.1 cm larger in the greatest dimension when compared with 8 months ago. Interventional radiology was consulted for embolization.

The left radial artery measured 2 mm in the AP diameter and had a Barbeau type B waveform. Access was obtained and a 5 Fr vascular sheath was placed. A radial cocktail of 200 mcg nitroglycerin and 2.5 mg verapamil was administered.

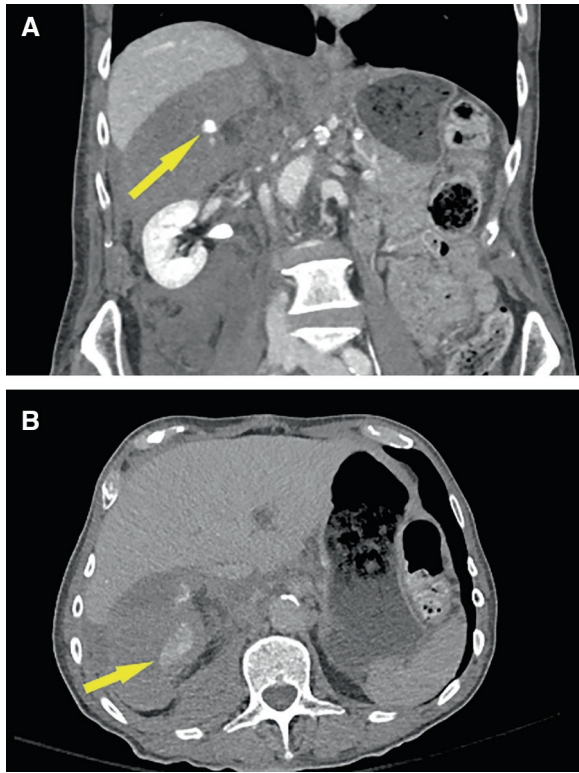
published online  
July 12, 2022

DOI <https://doi.org/10.1055/s-0042-1749071>.  
ISSN 2542-7075.

© 2022. The Pan Arab Interventional Radiology Society. All rights reserved.

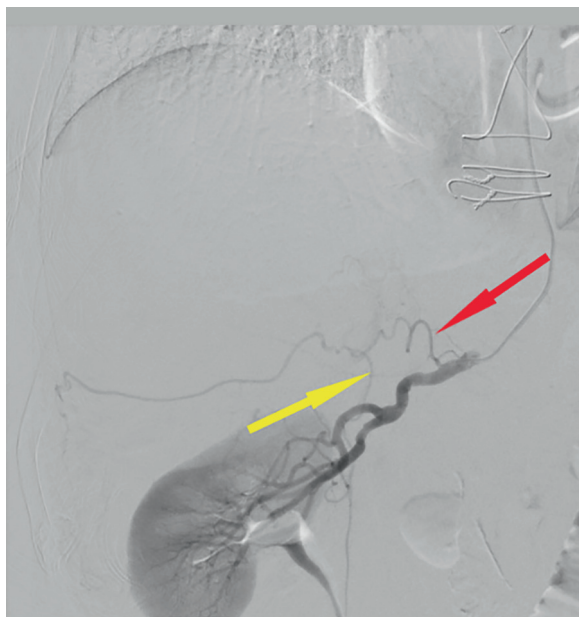
This is an open access article published by Thieme under the terms of the Creative Commons Attribution-NonDerivative-NonCommercial-License, permitting copying and reproduction so long as the original work is given appropriate credit. Contents may not be used for commercial purposes, or adapted, remixed, transformed or built upon. (<https://creativecommons.org/licenses/by-nc-nd/4.0/>)

Thieme Medical and Scientific Publishers Pvt. Ltd., A-12, 2nd Floor, Sector 2, Noida-201301 UP, India

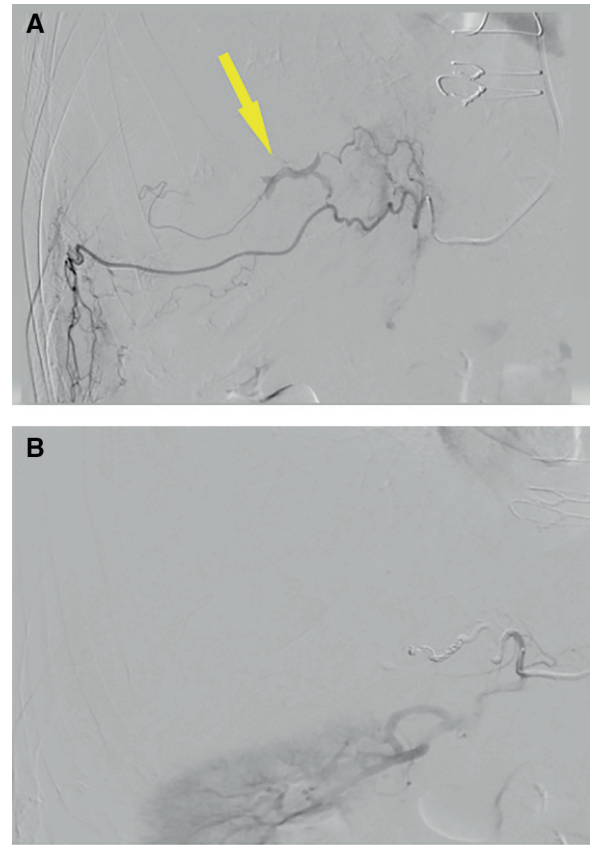


**Fig. 1** (A) Coronal arterial phase CTA shows an area of active extravasation within large hematoma (yellow arrow). (B) Axial delayed image confirms active extravasation (yellow arrow).

Abdominal aortography demonstrated the right renal artery without active extravasation. Angiogram of the right renal artery demonstrated the origins of the medial and lateral inferior suprarenal arteries without extravasation (→**Fig. 2**).



**Fig. 2** Selective angiogram of the right renal artery did not show active extravasation. The medial inferior adrenal artery (red arrow) and the lateral inferior adrenal artery (yellow arrow) were identified.

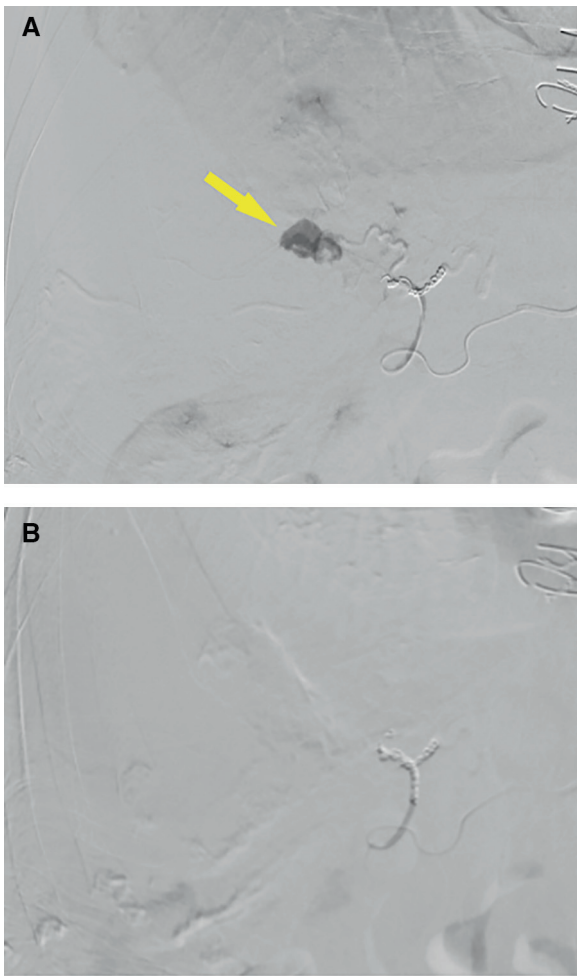


**Fig. 3** (A) Subselection of the medial inferior suprarenal artery and angiogram shows active extravasation (yellow arrow). (B) Post-embolization angiogram of the medial inferior suprarenal artery shows satisfactory hemostasis.

Angiography of the medial inferior suprarenal artery with a 2.0 Fr microcatheter demonstrated extravasation around the patient's myelolipoma (→**Fig. 3A**). Hemostasis of the medial inferior suprarenal artery was achieved with 1/10 vial of 100–300 micron Embosphere (MeritMedical, South Jordan, Utah) and a 2 mm Concerto coil (Medtronic, Minneapolis Minnesota) (→**Fig. 3B**). Subsequent angiography of the lateral inferior suprarenal artery showed extravasation in the area of the myelolipoma (→**Fig. 4A**). This artery was embolized with 1/2 vial of 100–300 micron Embosphere (MeritMedical) and 2, 3, and 4 mm Concerto coils (Medtronic) (→**Fig. 4B**). No additional extravasation was noted and hemostasis of the left wrist was obtained with a radial TR band (Terumo, Europe).

The post procedure period was notable for a drop in hemoglobin from 9.1 to 7.7 overnight despite reported improvement in abdominal pain. CT angiogram the next morning did not show additional extravasation.

The patient received one unit of packed red blood cells 1 and 3 days after the procedure for persistent anemia. Hemoglobin stabilized on postop day 8 and the patient was cleared for discharge. The recovery period was prolonged secondary to severe malnutrition that predated this admission. The patient did not have any further complications from retroperitoneal bleed after embolization and he remained stable at a follow-up visit 1 month later.



**Fig. 4** (A) Subselective catheterization of the medial inferior suprarenal artery showing active extravasation (yellow arrow). (B) Post embolization angiogram showing satisfactory hemostasis of the medial inferior suprarenal artery.

## Discussion

Myelolipomas are benign, mostly non-functioning, and asymptomatic incidentalomas.<sup>1</sup> Although most do not require treatment, tumors with rapid growth may be predisposed to acute hemorrhage, and others may require

treatment for suppression of endocrine function or for size reduction.<sup>1,4</sup> Clinical decision-making during monitoring of these tumors should focus on these factors, and particularly tumor size, when considering the risk for spontaneous hemorrhage. For example, in a case report of 75 patients with diagnosed ML, the incidence of hemorrhage was associated with larger masses (14.4 cm vs. 10.4 cm).<sup>4</sup>

In patients who do require intervention, transcatheter arterial embolization is a proven method for treatment and we demonstrate its use in the management of acute hemorrhage in a patient who was not an ideal surgical candidate due to several comorbidities.<sup>1,5</sup> Moreover, this case highlights the use of minimally invasive techniques in patients with complex medical histories that require urgent hemostasis. Further, we present the use of radial artery access for embolization of acute hemorrhage to achieve fewer complications and faster recovery times.

## Conclusion

Transcatheter arterial embolization via radial artery access is a suitable method for treatment of acute spontaneous hemorrhage from MLs and can be used in patients that fail supportive therapy and may not be good surgical candidates.

## Conflict of Interest

None declared.

## References

- 1 Badawy M, Gaballah AH, Ganeshan D, et al. Adrenal hemorrhage and hemorrhagic masses; diagnostic workup and imaging findings. *Br J Radiol* 2021;94(1127):20210753 PMID
- 2 McGeoch SC, Olson S, Krukowski ZH, Bevan JS. Giant bilateral myelolipomas in a man with congenital adrenal hyperplasia. *J Clin Endocrinol Metab* 2012;97(02):343–344 PMID
- 3 Nakajo M, Onohara S, Shinmura K, Fujiyoshi F, Nakajo M. Embolization for spontaneous retroperitoneal hemorrhage from adrenal myelolipoma. *Radiat Med* 2003;21(05):214–219 PMID
- 4 Rao P, Kenney PJ, Wagner BJ, Davidson AJ. Imaging and pathologic features of myelolipoma. *Radiographics* 1997;17(06):1373–1385 PMID
- 5 Kabeel K, Marjara J, Bhat R, Gaballah AH, Abdelaziz A, Bhat AP. Spontaneous hemorrhage of an adrenal myelolipoma treated with transarterial embolization: a case report. *Radiol Case Rep* 2020;15(07):961–965 PMID