

NanoScope Arthroscopy: Lessons Learned in the First 75 Cases

Christine Oh, MD¹ Sanjeev Kakar, MD, FAOA¹ 

¹Department of Orthopaedic Surgery, Mayo Clinic, Rochester, Minnesota

Address for correspondence Sanjeev Kakar, MD, FAOA, Department of Orthopaedic Surgery, Mayo Clinic, Rochester, MN 55905 (e-mail: Kakar.sanjeev@mayo.edu).

J Wrist Surg 2022;11:280–287.

Abstract

Keywords

- ▶ NanoScope arthroscopy
- ▶ upper extremity arthroscopy

Background The field of arthroscopy has exponentially grown in the past decade, especially in the realm of upper extremity surgery.

Description The use of smaller cameras and further advancements in arthroscopy technology have allowed innovative expansion in the application of arthroscopy in small joints.

Clinical Relevance Included in the advancements is the NanoScope, a 1.9-mm flexible scope specifically designed for small joint visualization.

Wrist arthroscopy has an extensive history marked by the innovating efforts of hand surgery pioneers who believed in the promise of arthroscopy to broaden the scope of the field.¹ Masaki Watanabe's *Atlas of Arthroscopy* was first published in 1957. Terry Whipple, Gary Poehling, and James Roth organized the first wrist arthroscopy course in 1986 with 47 attendees, including 10 former Presidents of the American Society of the Hand.¹

Advancements in miniaturization of existing technology have allowed for a broader application of arthroscopy, namely, in small joints. The first 1.9-mm arthroscope was developed by Watanabe, the No. 25 arthroscope. This model was quite fragile and even the current 1.9-mm arthroscopes can be brittle and easily susceptible to scratches and damage. Although the diameters of these arthroscopes were small, the size of the camera remained large and heavy, with the first models the size of a “bread box.”¹ This was quite difficult for the surgeon to manipulate intraoperatively and, as one can imagine, created limitations in its applicability.

Traditionally, wrist arthroscopy is performed with a wet technique using constant saline flow irrigation.² The wet technique has been the standard until del Piñal and Atzei described dry wrist arthroscopy.^{3–5} With today's dry technique, there is no fluid used except when using the automatic washout technique.^{3,6–8} This decreases the theoretical risk of compartment syndrome in fracture cases, improves visuali-

zation, and allows for concomitant open procedures given minimal tissue distension and fluid egress.⁶

A 2.7-mm small joint arthroscope is most commonly used for upper extremity arthroscopy. The cannula for the 2.7-mm scope is 4 mm, which can be quite difficult to place into a tight joint, such as the distal radioulnar joint (DRUJ), thumb carpometacarpal joint, or metacarpophalangeal joint (MCPJ). A rigid standard small joint arthroscope poses the risk of iatrogenic cartilage injury at the time of portal entry. This is a greater concern especially with tighter, smaller joint spaces. The surgeon may decrease the arthroscope size to the standard 1.9-mm scope. This is used typically with a 30-degree lens, and although the diameter is smaller, it too is rigid and can potentially damage cartilage upon entry. The field of view for a standard 1.9-mm scope can range from 60 to 75 degrees.

In 2019, the 1.9-mm NanoScope (Arthrex, Naples, FL) with a 2.2-mm outer diameter cannula was introduced. The arthroscope comprises chip-on-tip technology with a zero-degree view (looks straight on) and 120-degree panoramic field of view. It is lightweight and flexible, permitting access to the smallest of joints such as the DRUJ, MCPJ, and proximal interphalangeal joint. This feature improves surgeon ergonomics and comfort. It is a single-use camera system with a portable console imaging system, which allows for use beyond the operating room, with application in the clinic procedural setting as well.

received

February 1, 2022

accepted

April 11, 2022

© 2022, Thieme. All rights reserved.
Thieme Medical Publishers, Inc.,
333 Seventh Avenue, 18th Floor,
New York, NY 10001, USA

DOI <https://doi.org/10.1055/s-0042-1749089>.
ISSN 2163-3916.

Since its release in August 2019, we have performed over 75 cases with the NanoScope, and the purpose of this article is to share our learning curve and clinical experience using a case-based approach of both arthroscopic and nonarthroscopic uses.

Wrist Arthroscopy Surgical Technique

One of the benefits of the NanoScope is the portable console, which allows the surgeon to perform arthroscopy in a procedure room or in the formal operating room. If proceeding in the operating room, a 13-inch HD monitor can be connected to the arthroscope tower for a more expansive view. We find that less traction is needed with the NanoScope as it is smaller than the traditional 4-mm trocar used with 2.7-mm arthroscopes. Typically, 5 to 7 pounds of longitudinal traction is used. The 3–4 portal is first identified with an 18-gauge needle. Next, a small radiocarpal transverse skin incision is made and the joint is entered with tenotomy scissors followed by the outer 2.2-mm sheath cannula. The NanoScope is then placed within the sheath to start radiocarpal joint examination. We typically perform dry wrist arthroscopy with the tourniquet insufflated to 250 mm Hg. The flexibility of the scope minimizes iatrogenic cartilage injury in contrast to the stiff stem of a standard arthroscope. This can be especially helpful in the academic setting with trainees' learning curve as they become more proficient with arthroscopy. To help with precise control of the NanoScope and stability, the NanoGrip is placed onto the cannula so the camera can be held like a pencil (→ Fig. 1). The initial view within the joint may be limited secondary to synovial fluid or joint debris. As such, we will either wipe the lens within the soft tissues or use the automatic washout technique. This entails placing a normal saline-filled 10-mL syringe onto the side port within the cannula. A 2-mm shaver is simultaneously placed within the 6R portal, and as the surgeon debrides the joint with suction on, the irrigation will clear the debris for a clear visual field. Repeating this

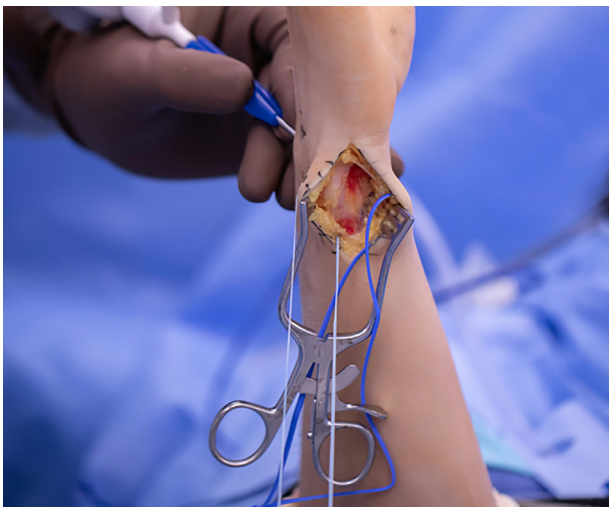

Fig. 1 Intraoperative photograph demonstrating use of the NanoGrip during foveal TFCC repair.

maneuver as needed is quick and simple. One does not need to remove the scope from the portal for cleaning unless the soft-tissue wiping maneuver fails. For those surgeons who prefer wet arthroscopy, they can use either the 2.2-mm cannula or the “high-flow sheath cannulas” that also have a 30-degree bend as noted within traditional arthroscopes.

Distal Radioulnar Joint Arthroscopy

Wrist arthroscopy is a widely indicated and utilized treatment in ulnar wrist disorders, including triangular fibrocartilage complex (TFCC) pathology. While central and peripheral tears are readily apparent from the radiocarpal joint, foveal injuries may be harder to diagnose. With suspected TFCC foveal tears, the trampoline, hook, and suction tests are most often used via radiocarpal arthroscopy.^{7,9–12} This provides an indirect assessment of the fovea, which can be confirmed with DRUJ arthroscopy. Direct DRUJ arthroscopy is often difficult to perform with a standard 2.7-mm arthroscope given the very limited joint space. A traditional 1.9-mm arthroscope can be used but may not be readily available. It is also rigid and has a lens susceptible to damage. We have found DRUJ arthroscopy an ideal indication for the NanoScope.

The current technique of DRUJ arthroscopy¹³ has evolved from the first descriptions by Whipple and utilizes distal and proximal portals along the dorsal aspect of the DRUJ. More recently, volar and direct foveal portals have also been described.^{2,11,14–16}

DRUJ Arthroscopy Operative Technique

Sterile finger traps are applied to the index, long, ring, and small fingers, and the arm is suspended in a traction tower. The NanoScope is initially placed in the 3–4 portal. While keeping the TFCC in view, the surgeon can aim an 18-gauge needle directly under the TFCC and, by moving the needle up and down, can directly visualize TFCC movement (since the needle is deep to the complex). This maneuver confirms that the needle is in the DRUJ space with the TFCC distal and the ulnar head proximal. A small transverse skin incision is made overlying the needle entry point and the DRUJ portal can then be developed using tenotomy scissors. The NanoScope packet contains two 2.2-mm outer diameter cannulas, allowing the second cannula to be placed directly under the TFCC through the distal DRUJ portal. Its position is confirmed to be in the correct location under the TFCC as the NanoScope is still within the radiocarpal joint and the surgeon can move the TFCC up and down using the second cannula confirming accurate placement of the trocar. The NanoScope is then withdrawn from the radiocarpal joint and placed into the DRUJ cannula. We have found this technique quick and reliable for entry into the DRUJ. Oftentimes, the camera will be advanced too far and will rest against the volar capsule, obscuring the DRUJ view. The surgeon then slowly pulls the camera back to allow visualization of the ulnar head, the TFCC, and its foveal insertion as well as the sigmoid notch of the DRUJ.

Case 1

A 15-year-old boy was referred from the pediatric orthopaedic surgeon for right ulnar-sided wrist pain after sustaining a distal radius and ulna fracture 9 months earlier (►Fig. 2A–C). He had undergone closed reduction and pinning at the time of injury. Examination in the clinic revealed foveal tenderness and instability of the right DRUJ in neutral, pronation, and supination without an end point. Interestingly, the magnetic resonance imaging (MRI) was read by a musculoskeletal radiologist as a possible ulno-triquetral ligament injury with an intact foveal insertion of the TFCC (►Fig. 2D). Given the clinical suspicion for a foveal injury, the patient proceeded to surgery. Radiocarpal joint arthroscopy demonstrated no evidence of a peripheral tear with an equivocal trampoline sign, negative hook, and suction tests (►Fig. 2E). DRUJ arthroscopy, however, revealed foveal detachment accounting for the patient's instability (►Fig. 2F). A modified arthroscopic-assisted transosseous foveal repair, as described by Chen, was then performed.¹⁷ In brief, an ulnar-sided incision was made and the dorsal sensory branch of the ulnar nerve retracted out of harm's way. A volar DRUJ portal was then created and the fovea debrided of scar down to bleeding bone using a curette and a 2-mm shaver (►Fig. 2G). A 0.062-inch K-wire was then used to create a distal ulnar tunnel through which two loops of 2-0 nonabsorbable suture were passed and then retrieved from the 6R portal. Each loop of suture was then cut (leaving four limbs of suture passing through the ulnar tunnel) and were sequentially passed through the periphery of the TFCC or ulnar capsule, thereby completing a four-strand transosseous foveal repair (►Fig. 2H). This repair resulted in immediate DRUJ stability. The patient was placed into a sugar-tong splint in neutral rotation for 2 weeks, followed by an above-elbow Muenster cast for 4 weeks following which he entered into a formal hand therapy program; follow-up 3 months later demonstrated resolution of pain and restoration of DRUJ stability.

Metacarpophalangeal Joint Arthroscopy

Small joint arthroscopy has been well described in the hand and fingers, especially for the trapeziometacarpal joint.^{18–25} With arthroscopy, the surgeon can visualize the ligaments with the opportunity for thermal shrinkage stabilization, joint debridement, and arthroscopic-assisted procedures.^{21–23,26,27} It can also be used for the treatment of thumb ulnar collateral ligament (UCL) injuries as well as to perform a synovectomy in patients with inflammatory arthritis.^{28–31} The indications for MCPJ arthroscopy can be for acute or chronic conditions but more commonly for chronic processes given the limited treatment options for persistent MCPJ pain.²¹ The 30-degree 1.9-mm scope used in temporomandibular joint pathology can be used for standard MCPJ arthroscopy.^{21,23,27} In small joints, it is obviously critical to introduce the trocar into the joint space without causing iatrogenic trauma. We find the NanoScope to be an ideal tool to help with tissue biopsy, irrigation, debridement, synovectomy (where indicated), fracture reduction, and treatment of MCPJ pathology.²¹

Case 2

A 62-year-old, right-handed man presented with chronic pain along the MCPJ of the right long finger for approximately 1 year without any history of trauma. He presented to the hand clinic after observing swelling and tightness of the joint especially in the mornings for several months with progression of his pain and progressive stiffness. Standard radiographs were inconclusive and did not show significant degenerative changes or obvious pathology (►Fig. 3A). An MRI revealed moderate effusion, minimal synovitis, and marginal erosion within the joint (►Fig. 3B). Following rheumatologic evaluation, a decision was made to proceed with arthroscopic examination, as the joint was not amenable to ultrasound-guided biopsy for tissue diagnosis. Right long MCPJ arthroscopic joint biopsy and synovectomy were

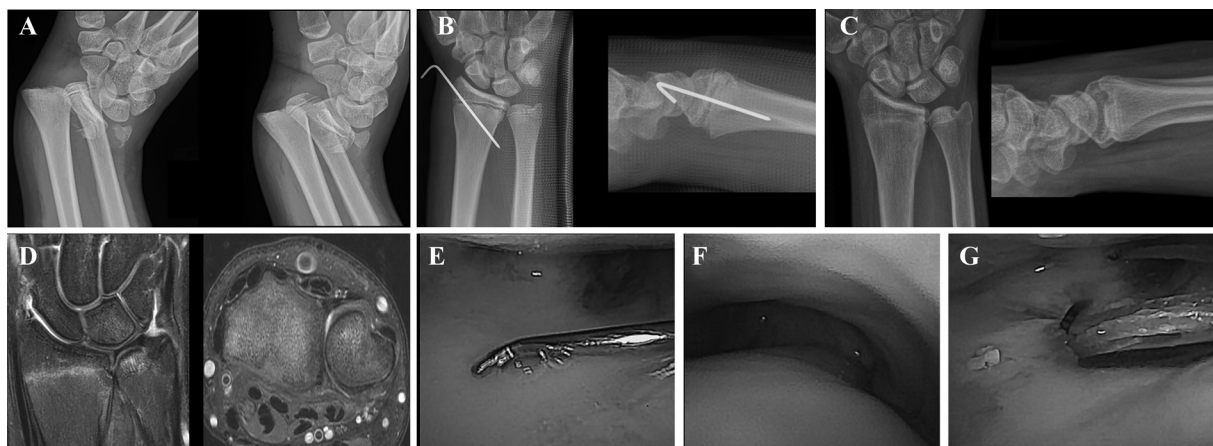

Fig. 2 Radiographs, MRI, and intraoperative photographs of a patient who underwent arthroscopic TFCC foveal repair. (A) Injury X-rays demonstrating a displaced distal radius and ulnar fracture. (B) Patient underwent closed reduction and percutaneous pinning of a distal radius fracture. (C) Radiographs at 8 months postpinning demonstrating healed distal radius and ulnar fractures. (D) Coronal and axial T2-weighted MRI scans showing no apparent foveal TFCC injury. (E) Radiocarpal arthroscopy demonstrating negative trampoline test. (F) DRUJ arthroscopy demonstrating complete foveal injury. (G) Arthroscopic foveal debridement.

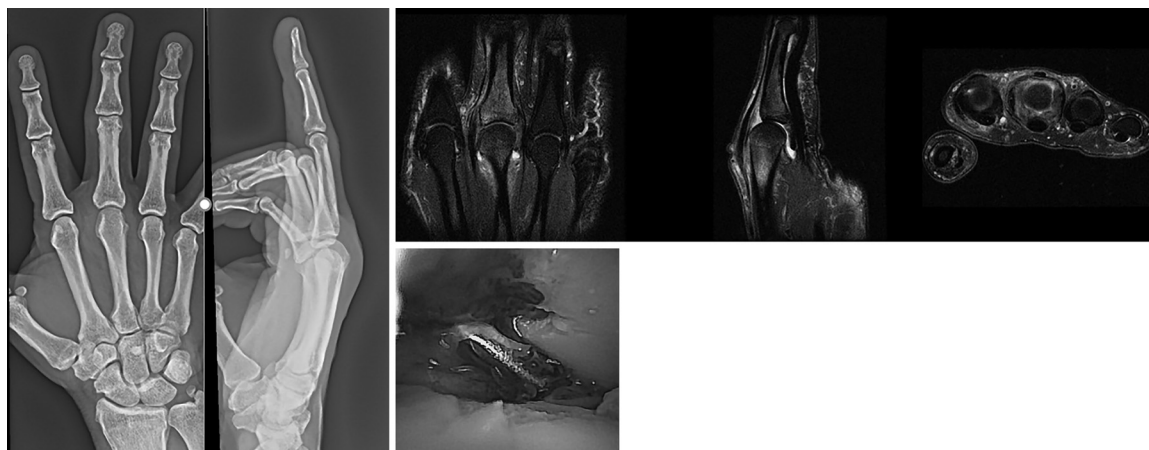


Fig. 3 The case of a 62-year-old patient with psoriatic arthropathy. (A) Anteroposterior (AP) and lateral radiographs of the right hand revealing unremarkable findings within the right long MCPJ. (B) MRI reveals joint effusion and mild synovitis. (C) Arthroscopic findings demonstrating profuse synovitis and articular degeneration.

performed. An ulnar portal to the MCPJ was made followed by insertion of the flexible NanoScope. This can be a controlled motion with minimal risk of iatrogenic injury. Under direct visualization, the radial portal was made. The NanoBiter 2-mm tissue punch was then used to biopsy the synovium for pathology and microbiology. A 2-mm shaver was used to perform an arthroscopic synovectomy after which one could appreciate fraying of the articular cartilage (►Fig. 3C). Pathology confirmed a diagnosis of psoriatic arthritis for which the patient improved on a steroid taper followed by disease-modifying antirheumatic drug regimen by rheumatology. Patients with inflammatory arthropathy are ideal candidates for arthroscopic synovectomy. Arthroscopy of the MCPJ allows for visualization of the joint space without having to disrupt the extensor mechanism allowing for expedited motion and rehabilitation.³² At 2-month follow-up, given the minimal morbidity of MCPJ arthroscopy, our patient's pain and swelling was improved without any evidence of extensor tendon dysfunction or scarring.

Case 3

A 28-year-old woman with a past traumatic history for a left-hand degloving injury presented with MCPJ pain for the past 3 years. At the time of her traumatic injury, she underwent split-thickness skin grafting overlying the dorsoradial aspect of her left wrist and thumb (►Fig. 4A). To treat her MCPJ pain, nonoperative measures including immobilization with splinting, hand therapy, and steroid injections were exhausted with transient relief of her symptoms. Radiographs did not reveal any bony pathology or degenerative changes (►Fig. 4B). Her radial collateral ligament and UCL were stable on clinical examination. MRI demonstrated no degenerative findings of the joint (►Fig. 4C). Due to her refractory symptoms and pain, the patient wished to proceed with MCPJ arthroscopy and debridement, especially given soft-tissue concerns with an open joint evaluation in the setting of her overlying skin graft. With the thumb in 5 pounds of longitudinal traction, two MCPJ portals were

established using a 20-gauge needle on either side of the extensor apparatus. After blunt dissection, the NanoScope was introduced into the MCPJ. Arthroscopic evaluation revealed significant synovitis necessitating extensive arthroscopic synovectomy using the 2-mm shaver. Synovectomy allowed for clear visualization of the cartilage, which was noted to eburnated, consistent with posttraumatic arthritis of the MCPJ (►Fig. 4D). The shaver was again used to debride any loose cartilage bodies. Upon return for her postoperative follow-up, the patient's wounds had healed well and she reported minimal pain with near-comparable MCPJ range of motion compared with her contralateral side. Arthroscopy of the MCPJ assisted in diagnosis and treatment of this case of posttraumatic arthritis.

Arthroscopic-Assisted Compartment Release

Chronic exertional compartment syndrome is a well-recognized cause of upper extremity discomfort in certain athletes such as rowers, cyclists, or motocross riders.^{33,34} In those in whom nonoperative treatment failed, fasciotomy is indicated, either through open, mini-open, or endoscopic techniques.³⁵ The benefits of minimally invasive techniques include faster postoperative recovery, less pain, and improved cosmesis of the surgical site.^{34,36-39} We find the NanoScope to be a useful tool to perform this procedure in a safe and efficient manner, especially in the upper extremity.

Case 4

A 21-year-old collegiate female rower presented with signs and symptoms of exercised-induced bilateral forearm compartment syndrome (dorsal and volar). She had been previously evaluated by neurology, vascular surgery, and physical medicine and rehabilitation specialists and was refractory to nonoperative treatment including physical therapy, dry needling, and botulinum toxin injections. Electrodiagnostic studies did not reveal any neuropathy, while pre- and

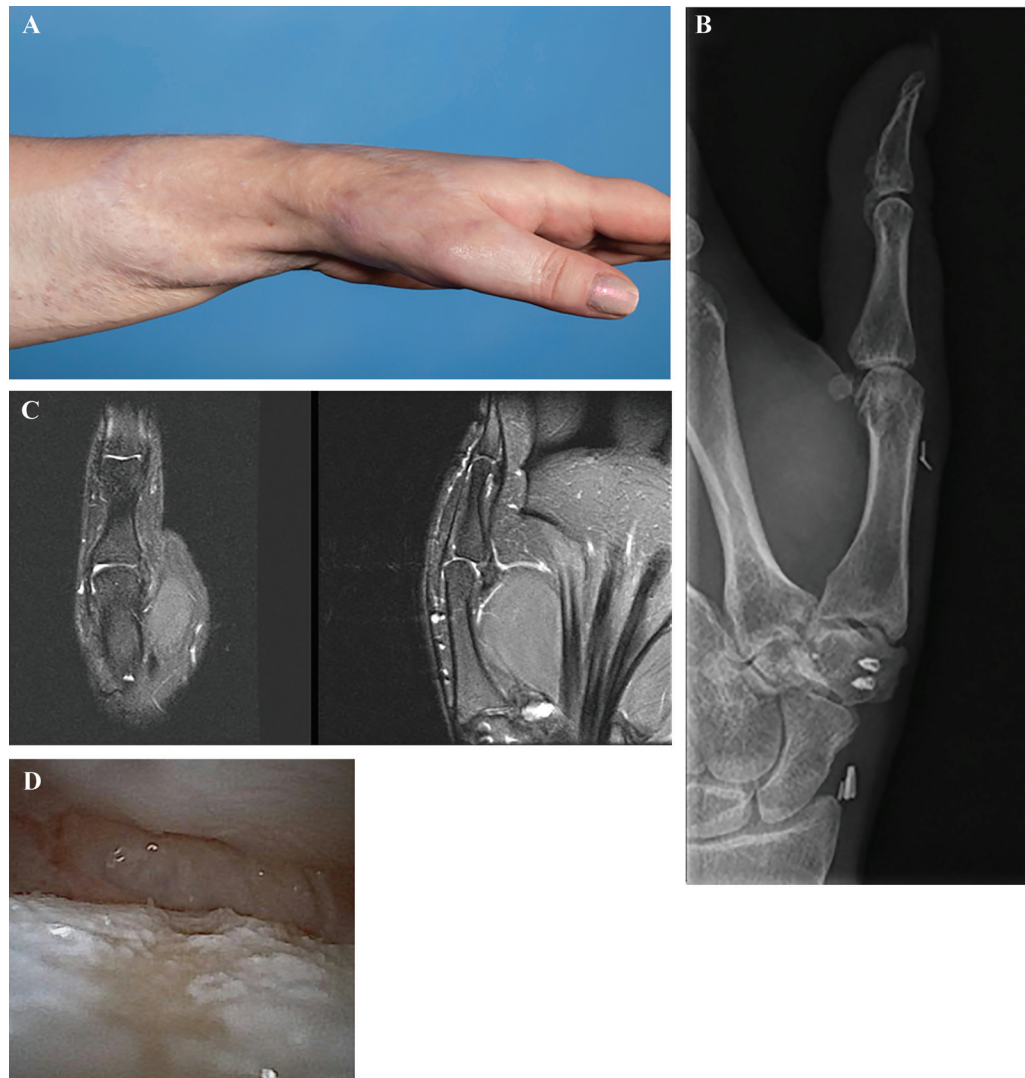

Fig. 4 The case of a 28-year-old patient with refractory MCPJ pain. (A) Healed split-thickness skin graft along the dorsoradial wrist and thumb after traumatic degloving injury. (B) Lateral radiograph of the left thumb without obvious degenerative changes of the MCPJ. (C) T2 MRI sequences of the left thumb MCPJ revealing intact radial and ulnar collateral ligaments. (D) Intraoperative photograph with the 1.9-mm NanoScope revealing cartilage injury consistent with posttraumatic arthritis.

postexercise compartment pressures and MRI were suggestive of bilateral volar and dorsal forearm exertional compartment syndrome. Given her continued symptoms, the patient elected for bilateral forearm fasciotomies of the involved compartments (► Fig. 5). Using the NanoScope, we released the superficial and deep volar, lateral, and dorsal compartments. Through 3-cm-length incisions, dissection was carried down to the level of the forearm fascia with protection of all cutaneous nerves. Initial fasciotomy can be performed through the limited incision, and then with blunt dissection of the superficial and deep fascia, the NanoScope was used to complete the fascial release under direct visualization with tenotomy scissors proximally and distally. To release the deep volar compartment, the interval between flexor carpi ulnaris and flexor digitorum superficialis was developed with identification and protection of the ulnar nerve. Under direct visualization with the NanoScope, the deep volar fascia can then be released proximally and distally. We found this to be a safe and efficient method of performing mini-

incision fasciotomies with the patient returning back to full competition.

Arthroscopic-Assisted Internal Fixation of Perilunate-Like Injuries

Accurate assessment of intra-articular reductions in the management of perilunate-type injuries can be difficult using intraoperative fluoroscopy.^{40,41} Oftentimes, residual articular step-off may persist, which may lead to malreduction, posttraumatic arthritis, and functional sequelae. Whipple described incorporating the use of arthroscopy for the management of intra-articular distal radius fractures.⁴² As it allows for optimizing anatomic reduction,⁴¹ arthroscopy also gives the surgeon the opportunity to evaluate ligaments and the TFCC at the time of fracture fixation. In the intrinsic and extrinsic management of these injuries, we have found the NanoScope to be an integral tool for fracture and joint reduction and stabilization.

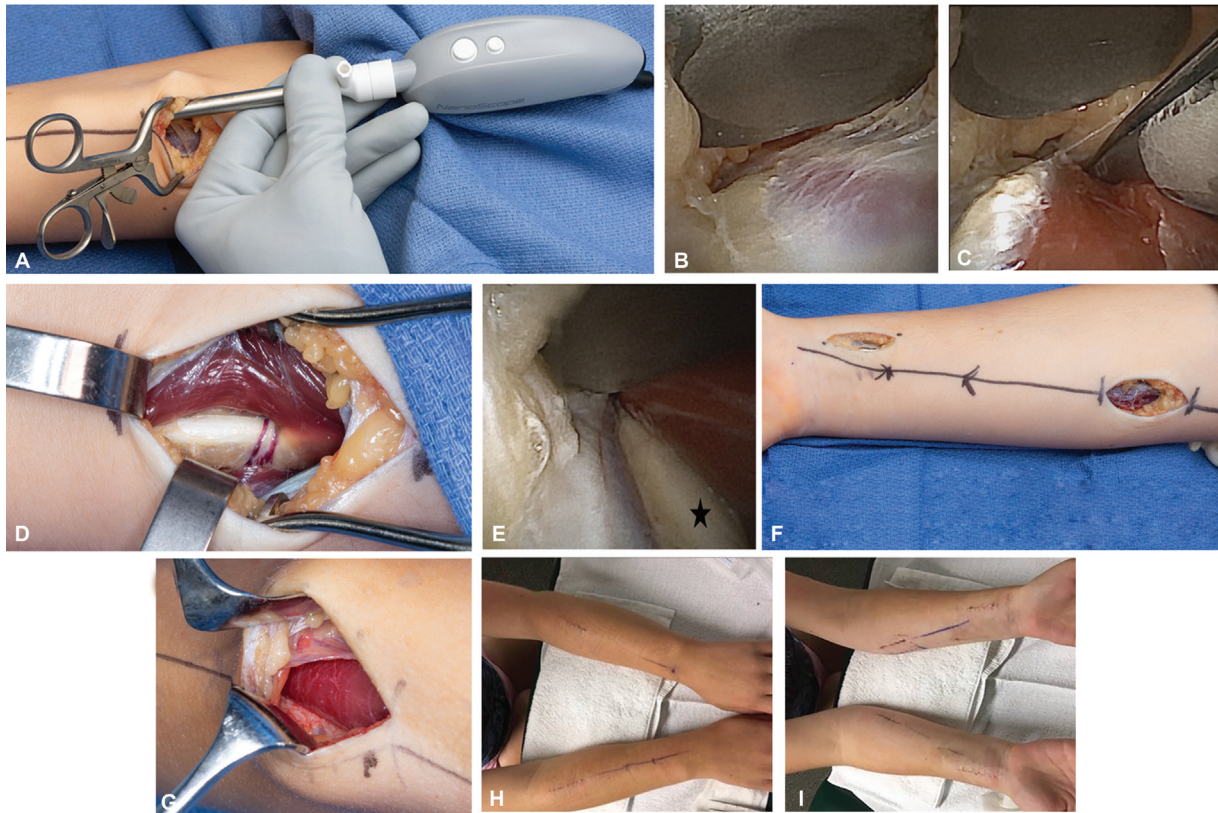


Fig. 5 This figure highlights the use of the NanoScope™ to treat exertional compartment syndrome. (A-B) NanoScope™ being placed for release of the superficial fascia of flexor forearm. (C) Release of the superficial fascia within the flexor forearm. (D) Identification of the ulnar nerve. (E) Release of the deep flexor compartment with protection of the ulnar nerve (*). (F) Release of the superficial and deep flexor forearm compartments with NanoScope™ assistance. Note the length of the incision for a traditional open release. (G) Release of the dorsal extensor compartments. (H-I) Post operative wound healing and scar appearance.

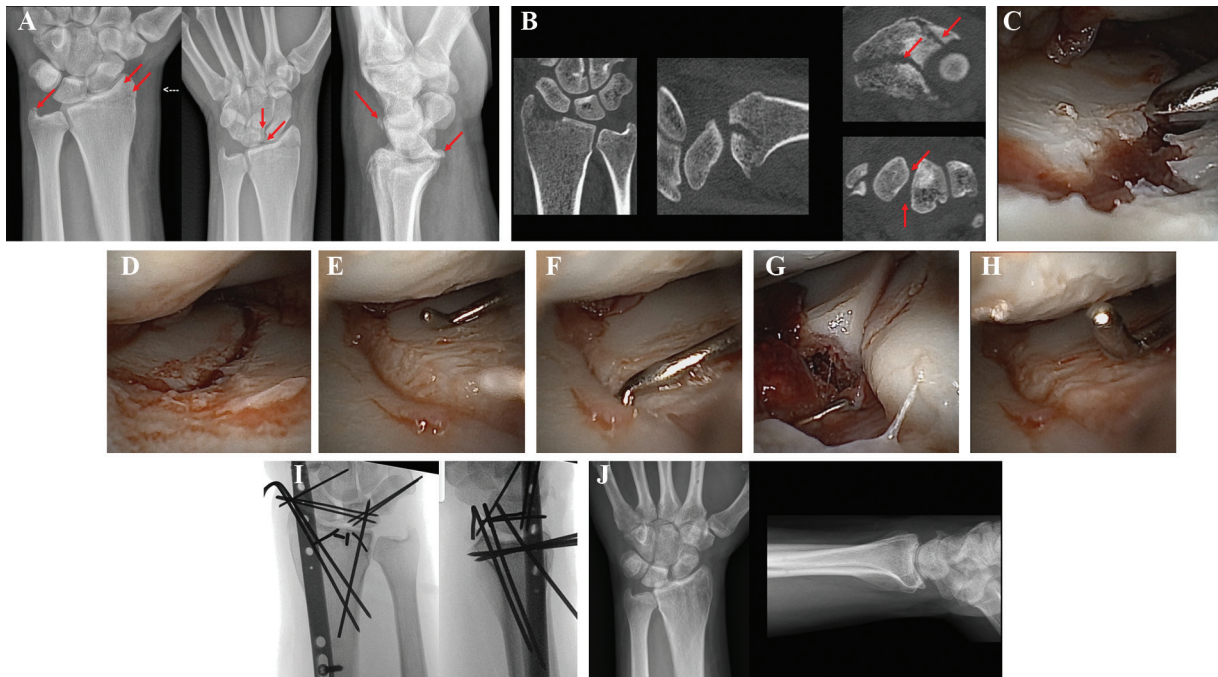


Fig. 6 Details of the use of the NanoScope in the management of a perilunate-like injury to the wrist of a 22-year-old patient. (A, B) Radiographs and computed tomography (CT) scan demonstrating comminuted distal radius fracture with carpal ligament involvement. (C) Arthroscopic view showing displaced radial column injury followed by (D) reduction of articular step-off. (E) Midcarpal arthroscopy demonstrated scapholunate joint step-off, (F) which has been reduced and stabilized by carpal pinning. (G) Associated dorsal capsular avulsion off the lunate and triquetrum. (H) Associated chondral injury of carpus. (I) Fluoroscopic views demonstrating reduction of the distal radius and carpus and dorsal spanning plate application. (J) AP and lateral radiographs 4 months postsurgery.

This document was downloaded for personal use only. Unauthorized distribution is strictly prohibited.

Case 5

A 22-year-old man fell off scaffolding sustaining a closed, comminuted perilunate fracture pattern on his left wrist (→ Fig. 6). Given the nature like of his injury, we proceeded with the NanoScope™-guided reduction and stabilization. Under fluoroscopic control, K-wires were placed into the fracture fragments. Using dry arthroscopy, the NanoScope™ was used to guide fracture, scapholunate and lunotriquetral joint reduction and stabilization.^{43–45} A dorsal spanning plate was also applied to allow the patient immediate joint weight-bearing and use.

Herzberg raised awareness of the perilunate injuries, not dislocated (PLIND) pattern.⁴⁶ Given that they lack the typical features of a perilunate dislocation, namely, disruption of the capitulunate joint on the initial radiograph, a high degree of vigilance is needed not to miss these devastating injuries given the concomitant bony and soft-tissue injuries that need to be treated. In his review of 11 PLIND injuries, Herzberg noted 10 of the 11 acute cases shared these findings and they represented a spectrum of injury including lesser arc, greater arc, and translunate injuries. In the three patients with clinical follow-up, their pain scores were 0 out of 10, grip strength ranged from 68 to 96% of the contralateral extremity, all returned to work, and one of the three patients showed some early degenerative findings (range of follow-up: 6–22 months).

Summary

There have been many advancements in arthroscopy in the past several decades, including the development of the NanoScope. The goal of the NanoScope arthroscopy system is to expand the scope of practice for surgeons to perform minimally invasive, safe and efficient procedures by providing a lightweight, flexible, small joint arthroscope that's been ergonomically designed as well as a portable image console for expanded applications in an OR, procedure room or clinic setting.

Conflict of Interest

Sanjeev Kakar MD is a Consultant for Arthrex.

References

- Baker A, Whipple TL, Poehling GG, Bain GI. History of wrist arthroscopy. *J Arthrosc Surg Sports Med* 2020;1:44–64
- Whipple TL. The basics of wrist arthroscopy. In: Whipple TL, ed. *Arthroscopic Surgery-The Wrist*. Philadelphia, PA: JB Lippincott; 1992:7–9
- del Piñal F, García-Bernal FJ, Pisani D, Regalado J, Ayala H, Studer A. Dry arthroscopy of the wrist: surgical technique. *J Hand Surg Am* 2007;32(01):119–123
- Atzei A, Luchetti R, Sgarbossa A, Carità E, Llusà M. Setup, portals, and normal exploration in wrist arthroscopy. *Chir Main* 2006;25 (Suppl 1):S131–S144
- del Piñal F, García-Bernal FJ, Delgado J, Sanmartín M, Regalado J, Cerezal L. Correction of malunited intra-articular distal radius fractures with an inside-out osteotomy technique. *J Hand Surg Am* 2006;31(06):1029–1034
- del Piñal F. Dry arthroscopy and its applications. *Hand Clin* 2011; 27(03):335–345
- Burnier M, Herzberg G, Luchetti R, Del Piñal F, Kakar S. Dry wrist arthroscopy for ulnar-sided wrist disorders. *J Hand Surg Am* 2020; 27:30479–30472
- Kakar S, Burnier M, Atzei A, Ho PC, Herzberg G, Del Piñal F. Dry wrist arthroscopy for radial-sided wrist disorders. *J Hand Surg Am* 2020;45(04):341–353
- Hermansdorfer JD, Kleinman WB. Management of chronic peripheral tears of the triangular fibrocartilage complex. *J Hand Surg Am* 1991;16(02):340–346
- Ruch DS, Yang CC, Smith BP. Results of acute arthroscopically repaired triangular fibrocartilage complex injuries associated with intra-articular distal radius fractures. *Arthroscopy* 2003; 19(05):511–516
- Atzei A, Rizzo A, Luchetti R, Fairplay T. Arthroscopic foveal repair of triangular fibrocartilage complex peripheral lesion with distal radioulnar joint instability. *Tech Hand Up Extrem Surg* 2008;12 (04):226–235
- Greene RM, Kakar S. The suction test: a novel technique to identify and verify successful repair of peripheral triangular fibrocartilage complex tears. *J Wrist Surg* 2017;6(04):334–335
- Ecker J, Andrijich C. Dry arthroscopy distal radioulnar joint and foveal insertion: surgical technique. *J Wrist Surg* 2022;11(01):2–5
- Yamamoto M, Koh S, Tatebe M, et al. Arthroscopic visualisation of the distal radioulnar joint. *Hand Surg* 2008;13(03):133–138
- Nakamura T, Matsumura N, Iwamoto T, Sato K, Toyama Y. Arthroscopy of the distal radioulnar joint. *Handchir Mikrochir Plast Chir* 2014;46(05):295–299
- Slutsky DJ. Distal radioulnar joint arthroscopy and the volar ulnar portal. *Tech Hand Up Extrem Surg* 2007;11(01):38–44
- Chen WJ. Arthroscopically assisted transosseous foveal repair of triangular fibrocartilage complex. *Arthrosc Tech* 2017;6(01): e57–e64
- Badia A, Riano F, Young LC. Bilateral arthroscopic tendon interposition arthroplasty of the thumb carpometacarpal joint in a patient with Ehlers-Danlos syndrome: a case report. *J Hand Surg Am* 2005;30(04):673–676
- Badia A. Arthroscopic reduction and internal fixation of bony gamekeeper's thumb. *Orthopedics* 2006;29(08):675–678
- Badia A, Sambandam SN. Total joint arthroplasty in the treatment of advanced stages of thumb carpometacarpal joint osteoarthritis. *J Hand Surg Am* 2006;31(10):1605–1614
- Badia A. Arthroscopy of the trapeziometacarpal and metacarpophalangeal joints. *J Hand Surg Am* 2007;32(05):707–724
- Badia A, Khanchandani P. Treatment of early basal joint arthritis using a combined arthroscopic debridement and metacarpal osteotomy. *Tech Hand Up Extrem Surg* 2007;11(02):168–173
- Cobb TK, Berner SH, Badia A. New frontiers in hand arthroscopy. *Hand Clin* 2011;27(03):383–394
- Berger RA. A technique for arthroscopic evaluation of the first carpometacarpal joint. *J Hand Surg Am* 1997;22(06):1077–1080
- Menon J. Arthroscopic management of trapeziometacarpal joint arthritis of the thumb. *Arthroscopy* 1996;12(05):581–587
- Slutsky DJ. The role of arthroscopy in trapeziometacarpal arthritis. *Clin Orthop Relat Res* 2014;472(04):1173–1183
- Wall LB, Goldfarb CA. Metacarpophalangeal joint arthroscopy: outcomes for the painful, radiographically normal joint. *J Hand Surg Eur Vol* 2014;39(08):887–888
- Wilkes LL. Arthroscopic synovectomy in the rheumatoid metacarpophalangeal joint. *J Med Assoc Ga* 1987;76(09):638–639
- Declercq G, Schmitgen G, Verstreken J. Arthroscopic treatment of metacarpophalangeal arthropathy in haemochromatosis. *J Hand Surg [Br]* 1994;19(02):212–214
- Ryu J, Fagan R. Arthroscopic treatment of acute complete thumb metacarpophalangeal ulnar collateral ligament tears. *J Hand Surg Am* 1995;20(06):1037–1042
- Wei N, Delauter SK, Erlichman MS, Rozmaryn LM, Beard SJ, Henry DL. Arthroscopic synovectomy of the metacarpophalangeal joint

- in refractory rheumatoid arthritis: a technique. *Arthroscopy* 1999;15(03):265–268
- 32 Slade JF 3rd, Gutow PA. Arthroscopy of the metacarpophalangeal joint. *Hand Clin* 1999;15(03):501–27
- 33 Liu B, Barrazaeta G, Ruchelsman DE. Chronic exertional compartment syndrome in athletes. *J Hand Surg Am* 2017;42(11):917–923
- 34 Hallock GG. An endoscopic technique for decompressive fasciotomy. *Ann Plast Surg* 1999;43(06):668–670
- 35 Wittstein J, Moorman CT III, Levin LS. Endoscopic compartment release for chronic exertional compartment syndrome. *J Surg Orthop Adv* 2008;17(02):119–121
- 36 Marwan Y, Addar A, Algarni N, Algarni N, Burman M, Martineau PA. Endoscopic fasciotomy for chronic exertional compartment syndrome of the forearm: systematic review of outcomes and complications. *World J Orthop* 2021;12(05):320–328
- 37 Croutzet P, Chassat R, Masméjean EH. Mini-invasive surgery for chronic exertional compartment syndrome of the forearm: a new technique. *Tech Hand Up Extrem Surg* 2009;13(03):137–140
- 38 Gondolini G, Schiavi P, Pogliacomini F, Ceccarelli F, Antonetti T, Zasa M. Long-term outcome of mini-open surgical decompression for chronic exertional compartment syndrome of the forearm in professional motorcycling riders. *Clin J Sport Med* 2019;29(06):476–481
- 39 Havig MT, Leversedge FJ, Seiler JG III. Forearm compartment pressures: an in vitro analysis of open and endoscopic assisted fasciotomy. *J Hand Surg Am* 1999;24(06):1289–1297
- 40 Chen AC, Chan YS, Yuan LJ, Ye WL, Lee MS, Chao EK. Arthroscopically assisted osteosynthesis of complex intra-articular fractures of the distal radius. *J Trauma* 2002;53(02):354–359
- 41 Edwards CC II, Haraszti CJ, McGilivray GR, Gutow AP. Intra-articular distal radius fractures: arthroscopic assessment of radiographically assisted reduction. *J Hand Surg Am* 2001;26(06):1036–1041
- 42 Whipple TL. The role of arthroscopy in the treatment of wrist injuries in the athlete. *Clin Sports Med* 1992;11(01):227–238
- 43 Del Piñal F, Klausmeyer M, Moraleda E, de Piero GHMD, Rúa JSMD. Arthroscopic reduction of comminuted intra-articular distal radius fractures with diaphyseal-metaphyseal comminution. *J Hand Surg Am* 2014;39(05):835–843
- 44 Del Piñal F. Technical tips for (dry) arthroscopic reduction and internal fixation of distal radius fractures. *J Hand Surg Am* 2011;36(10):1694–1705
- 45 Del Piñal F, Clune J. Arthroscopic management of intra-articular malunion in fractures of the distal radius. *Hand Clin* 2017;33(04):669–675
- 46 Herzberg G. Perilunate injuries, not dislocated. *J Wrist Surg* 2013;2(04):337–345