Article published online: 2022-06-22



# Comparative Study of Laparoscopic and Open Pyelolithotomy in the Management of Large Renal Pelvic Stones

Yaqoob Hassan[1] Ajaz Ahmad Rather[1] Arshad Bashir[1] Ishfaq Ahmad Wani[1] Humayoon Rasool[1]

[1] Department of General and Minimal Access Surgery, Sher - i - Kashmir Institute of Medical Sciences Medical College, Srinagar, India

Ibnosina J Med Biomed Sci 2022;14:22–27.

**Address for correspondence** Yaqoob Hassan, MBBS, MS, Department of General and Minimal Access Surgery, Sher - i - Kashmir Institute of Medical Sciences Medical College, Srinagar 190010, India (e-mail: dryaqoobwani@gmail.com).

## Abstract

**Background** Large renal pelvic stones can be effectively managed with laparoscopic pyelolithotomy. The aim of this study was to compare the surgical outcomes of laparoscopic pyelolithotomy versus open surgery for the treatment of large renal pelvic stones.

**Materials and Methods** This prospective comparative study was performed at the Sher-i-Kashmir Institute of Medical Sciences Medical College and Hospital over a period of 8 years. Using computer-generated random numbers, the patients were randomized into two groups: group A received laparoscopic pyelolithotomy, while group B had open pyelolithotomy. The data was collected and analyzed using SPSS software 22.

**Results** Among 74 patients who met the inclusion criteria, the mean age was 39.18 years with 66.21% being males and a male:female ratio of 1.96. Forty-one (55.41%) patients had open surgery and 33 (44.59%) had laparoscopic pyelolithotomy. The difference in mean operative time of laparoscopy (117.66 minutes) and open (78.13 minutes) surgery was statistically significant ($p = 0.05$). The mean blood loss was significantly lower in the laparoscopic pyelolithotomy group (62.12 mL) than in the open group (92.07 mL) ($p = 0.009$). The difference in mean hospital stay between the open and laparoscopic groups was significant ($p = 0.02$). In both laparoscopy and open surgery, we observed a 100% stone-free rate at the end of 1 month. None of our patients expired during the study period.

**Conclusion** Laparoscopic pyelolithotomy is a promising alternative to traditional open and other endourological techniques, with encouraging results. Despite its technical difficulty, it yields high stone-free rates and low postoperative morbidity.

**Keywords**
- laparoscopy
- open surgery
- pyelolithotomy
- renal pelvic stones
- renal stones

## Introduction

In the last three decades, the surgical treatment of kidney stones has progressed from open surgery to minimally invasive treatment modalities. Noninvasive shock wave lithotripsy (SWL), flexible ureteroscopy, percutaneous nephrolithotomy, and laparoscopy were used to reduce postoperative morbidity and improve surgical outcome. Extracorporeal shock wave lithotripsy (ESWL) is the most common and first-choice method of treating urinary tract

**DOI** https://doi.org/10.1055/s-0042-1749143.
**ISSN** 1947-489X.

stones up to 1.5 cm in size that are suitable for this type of treatment. Ureteroscopy visualizes the stones directly, fragments them, and removes them through the urethra.[1] Percutaneous nephrolithotomy is used for large stones and when ESWL is contraindicated for one or more reasons. Though the minimally invasive endourological techniques have reduced the role of open surgery, they are ineffective at preventing recurrence and thus necessitate multiple operative sessions.[2–4] Staghorn calculus is particularly infected, and the stones must be removed completely to avoid recurrence. This is where open or laparoscopic approaches to renal stone management come into play. Though the role of open surgery in the treatment of renal stones has been greatly narrowed and diminished as endourological techniques have advanced, it is still required in 0.47 to 5.4% of cases with definite indications.[5] Laparoscopy has become a more acceptable option for treating large renal stones since the advent of minimal access surgery. Transperitoneal, retroperitoneal, and extraperitoneal laparoscopic access can be used for urological interventions. Because of more familiar anatomical landmarks and a larger working space, the transperitoneal approach has a shorter learning curve. The retroperitoneal laparoscopic approach has the potential benefit of reducing visceral and vascular injuries while also improving postoperative comfort by avoiding the opening of the peritoneal cavity. This method is also associated with a lower incidence of postoperative ileus and adhesion formation. The purpose of this study was to compare the surgical outcomes of laparoscopic pyelolithotomy and open surgery in the treatment of large renal pelvic stones.

## Materials and Methods

This prospective comparative study was conducted over 8-year period in the department of general and minimal access surgery at the Sher-i-Kashmir Institute of Medical Sciences, Medical College and Hospital. Written informed consent was taken from all the patients before the procedure. After receiving proper ethical clearance from the from the Departmental Academic and Research Committee (with reference number—SKIMS/MC/302/2013/55), a total of 74 subjects who underwent pyelolithotomy between 2013 and 2021 and completed 3 months postoperative follow-up were included in our study. Thirty-three patients had laparoscopic pyelolithotomy and forty-one had open pyelolithotomy. Following a thorough history and clinical examination, all patients underwent a complete blood count, kidney/liver function test, routine urine examination, serum electrolytes, calcium, phosphorus, radiograph of the chest and kidney, ureter, bladder, and abdominal ultrasonography. Computed tomographic urogram was used to determine the number, size, and location of the stones. Before any intervention, all patients underwent a diethylenetriaminepentaacetic acid scan to confirm the function of both kidneys and for medicolegal reasons. Patients with solitary, large pelvic stones of $\geq$2.5cms were included in the study. Patients with multiple stones, stone $<$ 2.5cms in size, bilateral stones, congenital kidney anomalies; patients with multiple-time stone formers or previous stone-related operations; and patients with a single kidney with stone were excluded from the study.

The patients were divided into two groups using computer-generated random numbers; group A included patients who underwent laparoscopic pyelolithotomy and group B included patients who had open pyelolithotomy. Postoperatively all the patients were closely monitored in our surgical ward's high-dependency unit. All patients were evaluated 24 hours after surgery with a kidney-ureter-bladder radiograph to check the stent position and any residual stone (►**Fig. 1**). Following hospital discharge, the patients were referred to our outpatient department for further follow-up.

In laparoscopic surgery, we used an extraperitoneal approach in the lateral decubitus position. Balloon dissection was done to establish extraperitoneal working space, and three laparoscopic ports were used (the camera and two working ports). After identifying the ureter, diathermy dissecting forceps were used to carefully dissect the ureter to expose the renal pelvis. To remove stones from the renal pelvis, we performed a T-shaped pyelotomy incision. The stones were delivered intact via camera port in a glove-made endobag. Laparoscopic stenting was performed via 5 mm port (DJ 6/26 both ends open) after saline washes, followed by pyelotomy closure utilizing intracorporeal knotting with 3–0 Vicryl. Pneumothorax was deflated and port sites were closed back after the tube drain was implanted in the perirenal area.

Following the World Health Organization safety checklist and confirming the side of the procedure, open surgery was performed in the lateral kidney position using the conventional extraperitoneal flank approach. The kidney was fully mobilized from lateral to cephalic to caudal directions after dividing Gerota's fascia laterally. The ureter was identified, looped by an 8F feeding tube, and the parapelvic fat was dissected from the renal pelvis using precise blunt dissection at the lower pole and above the psoas muscle. An incision was made at the ureteropelvic junction after two 3–0 catgut stay-sutures were placed at the pyelotomy site. Desjardin's forceps were used to release the stone from the pelvis and remove it all at once. Following normal saline washes and ureter stenting with a 6/26 double-j-stent, the pyelotomy was closed with a 3–0 round body Vicryl sutures. In all cases, a 28F tube drain was placed in the perinephric space between the renal parenchyma and Gerota's fascia and brought in through a separate incision. The incision was reclosed in layers.

Operative time was recorded for each procedure. Intraoperative blood loss was quantified by measuring irrigation fluid and weighing surgical sponges used for blood and fluid mopping during surgery [gravimetric methods] using following equation.

Total amount of Blood loss = Total difference in the swab weight $\times$ 1.5

[ multiplication factor is "2" in case of major blood loss or major Operations]

 

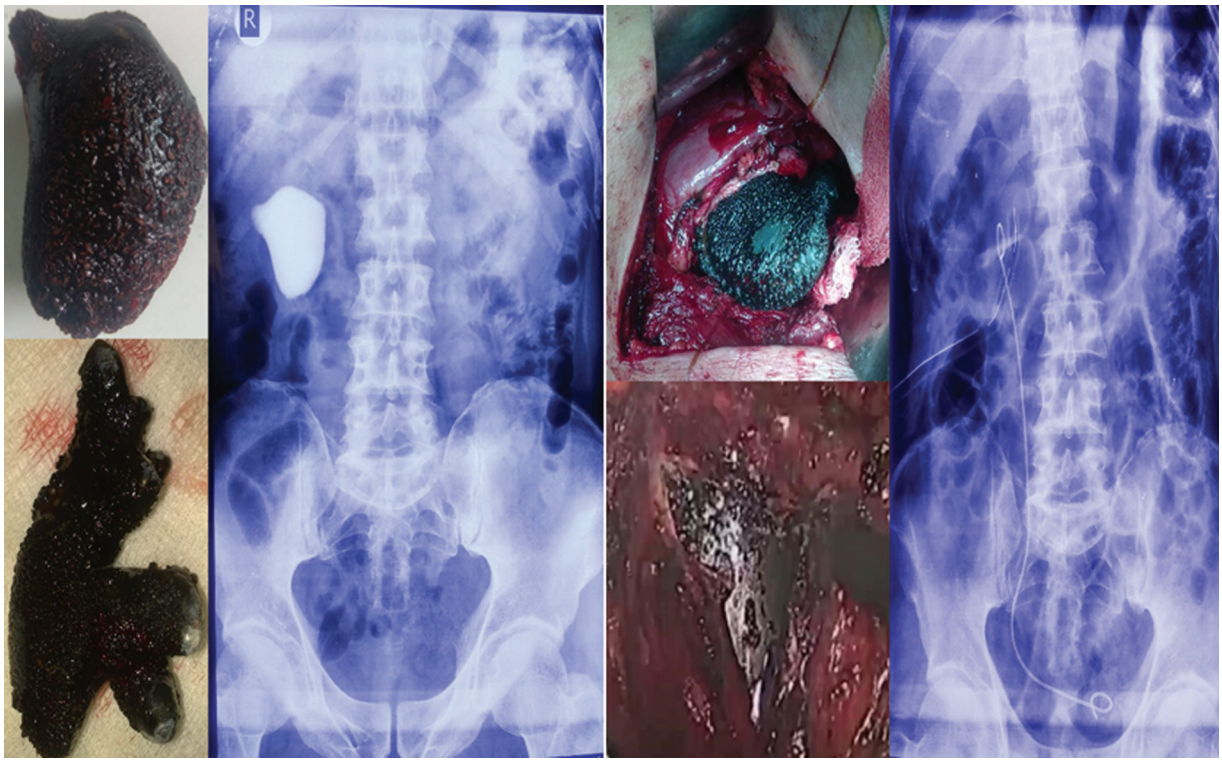

**Fig. 1** Large renal calculi, pre- and postoperative Kidney- Ureter- Bladder radiograph and intraoperative photographs.

In both groups, the Foley's catheter was removed 36 to 48 hours after surgery, and the drain was removed when the drainage was less than 20 mL/24 hours.

The statistical analysis was performed using SPSS software (SPSS version 22, IBM, Armonk, New York, United States). The distribution of continuous variables was evaluated according to the Shapiro–Wilk normality test. If the distribution was normal, Student's *t*-test was used for statistical analysis; if the distribution was not normal, Mann–Whitney U test was used. The categorical variables were analyzed by Fisher's exact test (two-tailed) or chi-squared test. The *p*-value was estimated and $p\text{-value} < 0.05$ was considered significant. The mean and frequency were calculated using Microsoft Excel 2016.

## Results

A total of 74 patients aged between 20 and 70 were included in the study. Males (66.21%) outnumbered females (33.78%) by a factor of 1.96. Fifty-one (68.92%) of our patients underwent right-side surgery, while 23 (31.08%) underwent left-side surgery. Forty-one patients (55.41%) had open surgery, while 33 (44.59%) had laparoscopic pyelolithotomy. The majority of our subjects (39.19%) were in the age group of 31 to 40 years followed by 41 to 50 years (27.02%) (►**Table 1**). The mean age of patients in the laparoscopic and open groups was 36.26 and 41.29 years, respectively. When compared statistically, the age distribution of the patients in both groups was nearly identical ($p = 0.13$). In the laparoscopy

**Table 1** Age distribution

| Age group (y) | Number of patients (frequency) | Laparoscopic group (frequency) | Open group (frequency) |
|---|---|---|---|
| 20–30 | 15 (20.27%) | 10 (30.30%) | 5 (12.19%) |
| 31–40 | 29 (39.19%) | 12 (36.36%) | 17 (41.46%) |
| 41–50 | 20 (27.02%%) | 9 (27.27%) | 11 (26.83%) |
| 51–60 | 7 (9.47%) | 2 (6.06%) | 6 (14.63%) |
| 61–70 | 3 (4.05%) | 0 (0%) | 2 (4.88%) |
| Total | 74 (100%) | 33 (44.59%) | 41 (55.41%) |
| Mean age | 39.18 | 36.26 | 41.29 |

*p*-Value = 0.13.

 

**Table 2** Operative time

| Operative time (min) | Laparoscopic group | Open group |
|---|---|---|
| <60 | 1 (3.03%) | 21 (51.22%) |
| 61–90 | 4 (12.12%) | 12 (29.27%) |
| 91–120 | 12 (36.36%) | 3 (7.32%) |
| 121–150 | 10 (30.30%) | 2 (4.88%) |
| >150 | 6 (18.18%) | 3 (7.32%) |
| **Mean** | **117.66 min** | **78.13 min** |

*p*-Value = 0.05.

and open surgery, the mean stone size was 2.98 0.9 versus 3.02 1 cm, respectively (►**Fig. 1**).

The mean operative time in the laparoscopic pyelolithotomy group was significantly longer than in the open pyelolithotomy group. With a *p*-value of 0.05, the difference between the two groups was statistically significant. The blood loss was significantly lower in the laparoscopic group of patients than in the open group. The mean blood loss in the laparoscopic pyelolithotomy group was 62.12 versus 92.07 mL in the open group, and the difference was statistically significant (*p*-value= 0.009). During the procedure, two (4.87%) of our patients in the open group required blood transfusion. There were no perioperative complications or blood transfusion requirements among our subjects in the laparoscopic group (►**Table 2**).

In the open group, 29.26% of patients developed a postoperative complication, whereas only 12.12% of patients in the laparoscopic group developed a postoperative complication. Wound site infection was the most common complication in the open group of patients, accounting for 14.63% of cases, followed by postoperative paralytic ileus (4.87%), chest infection (2.4%), urinary tract infection (UTI) (2.4%), and postoperative fever (2.4%). The most common complication in the laparoscopy group was postoperative fever, which was present in 9.09% of patients, followed by UTI (3.03% patients). All of the complications were handled conservatively and successfully. One patient (2.43%) in the open group developed an incisional hernia 8 months after surgery, which was treated with mesh hernioplasty.

The length of hospital stay was calculated from date of admission to the date of discharge. The in-hospital stay was significantly shorter in laparoscopic group than in the open group. The mean duration of hospital stay in open group was 6.74 days, while as in laparoscopic group was 3.77 days. About 90.24% of our open group patients were discharged between sixth and eighth day of admission, while 87.87% of our laparoscopic patients were discharged within 5 days. With a *p*-value of 0.02 separating the two groups, the difference was statistically significant.

All patients were seen in the outpatient department on a weekly basis for the first month, then monthly for the next 3 months. We observed a 100% stone-free rate at the end of 1 month in both the laparoscopy and open groups of patients. Stent removal was performed via cystoscopy 6 weeks after surgery. During the course of the study, none of our patients died.

## Discussion

Urolithiasis is one of the leading causes of morbidity worldwide, affecting 5 to 15% of the population and having a 5-year recurrence rate close to 50%.[6,7] Acute typical renal colic is a common presentation that is frequently accompanied by nausea, vomiting, hematuria, and, in some cases, fever. It is one of the three most common reasons for a urological emergency admission.[8] A thorough medical history, clinical presentation, systemic examination, and appropriate imaging all contribute to a correct diagnosis. With a modest diagnostic performance (sensitivity 44–77% and specificity 80–87%), plain radiographs of the abdomen can help distinguish between radiopaque and radiolucent stones.[9] Ultrasonography of the abdomen has been shown to detect renal stones with a sensitivity of 70% and a specificity of 94%.[10] Noncontrast-enhanced computed tomographic is a common imaging technique that has higher sensitivity and specificity for location, size, and composition, as well as the ability to determine stone density and inner structure. The management of renal stones has progressed from open surgery to minimally invasive endourology procedures. A less invasive procedure with lower morbidity, faster recovery, and higher stone clearance rates is ideal. Since the advent of minimal access surgery, laparoscopy has become a more acceptable option for treating large renal stones. Laparoscopic stone surgery has a high one-session stone-free rate, as well as less morbidity and faster recovery, and is appropriate for patients with urinary tract anomalies.[11] Even though retroperitoneal approach has its inherent advantages but transperitoneal approach is also popular and reported successfully. Extraction site is more cosmetic in transperitoneal approach that is from nonvisible area of lower abdomen and if not very large from umbilicus. It can be done faster and urine leak might be less since peritoneal covers renal pelvic closure.[11–14] Concomitant aberrant vessel causing ureteropelvic junction obstruction can be seen and dealt better in transperitoneal approach.[15] In this study, we compare and contrast the advantages, effectiveness, benefits, and safety of laparoscopy versus open surgery in the treatment of renal stones.

In our study, preoperative data such as age, gender, and stone side were homogeneous, with no statistically significant differences. Males (66.21%) outnumbered females (33.78%) by a factor of 1.96. 51 (68.92%) of our patients underwent right-side surgery, while 23 (31.08%) underwent left-side surgery. The majority of our subjects (39.19%) were between the ages of 31 and 40, with a mean age of 39.18 years. The mean age of the patients in the laparoscopic pyelolithotomy group was 36.26 versus 41.29 years in the open group. Though urolithiasis can affect people of all ages and genders, it is more common in men than in women between the ages of 20 and 49,[16] with 50% of patients presenting between the ages of 30 and 50.[8]

The mean operative time in the laparoscopic pyelolithotomy group was significantly longer (117.66 minutes) than in

 

the open pyelolithotomy group (78.13 minutes). There was a statistically significant difference between the two groups. The operative time ranged from 60 to 150 minutes (mean: 117 minutes), which is less than what Al-Azaby's found (135 minutes)[17] but more than reported by Al-Hunayan et al (112.1 minutes).[18] Qin et al discovered a mean operative time of 96 minutes in retroperitoneal laparoscopic pyelolithotomy of 76 patients.[19] The long learning curve of retroperitoneal laparoscopic pyelolithotomy, as well as the time required for dissection of the renal pelvis, intracorporeal suturing in a smaller working space, and stone retrieval, were all contributing factors.

The operative blood loss was significantly lower in the laparoscopic group of patients than in the open group. The mean blood loss in the laparoscopic pyelolithotomy group was 62.12 mL compared with 92.07 mL in the open group, which was statistically significant. In the open group, 29.26% of patients developed a postoperative complication, whereas only 12.12% of patients had a postoperative complication with laparoscopy. All of the complications were handled conservatively and successfully. The findings of our study agree with those of Singal and Dhar 2018.[20] They discovered that the laparoscopic group lost significantly less blood than the open group (63 vs. 103 mL) and had significantly fewer postoperative complications ($p = 0.001$). Others discovered a blood loss of 20 to 400 mL with a mean of 80 mL in the retroperitoneal laparoscopic technique.[19]

In the laparoscopic group, the in-hospital stay was significantly shorter than in the open group (3.77 vs. 6.74 days). About 90.24% of our open group patients were discharged between the sixth and eighth day of admission, while 87.87% of our laparoscopic patients were discharged within 5 days. Our findings were comparable to those of Shamim and Iqbal[21] and Basiri et al.[22] Other published data support a 3 to 5-day hospital stay in laparoscopic pyelolithotomy.[23] All patients were seen in the outpatient department on a weekly basis for the first month, then monthly for the next 3 months. We observed a 100% stone-free rate at the end of 1 month in both the laparoscopic and open groups of patients. Stent removal was performed via cystoscopy 6 weeks after surgery. During the course of the study, none of our patients died.

## Conclusion

Laparoscopic pyelolithotomy is a promising alternative to open surgery and other endourological techniques, with encouraging results. In our study, we discovered that the laparoscopic technique is safe and results in better cosmesis, less intraoperative bleed, fewer complications, a shorter hospital stay, and an earlier return to activity. Although technically demanding, laparoscopy is an efficient option with high stone-free rates and minimal morbidity. It should be performed by an experienced and skilled surgeon. Because this study had a small sample size, more comparative studies are needed to define the role, feasibility, and indications of laparoscopic stone surgery in comparison to open techniques, to properly validate these conclusions.

**Authors' Contribution**
YH, AAR, AB, IAW, and HR were involved in conception and designing, data collection, writing, and critical review. We are taking responsibility for the authenticity and integrity of research process.

**Compliance with Ethical Standards**
None.

**Funding and Sponsorship**
None.

**Conflict of Interest**
None declared.

## References

1 Williams N, O'Connell PR, McCaskie A. 2018Bailey & Love's Short Practice of Surgery, 27th Edition: The Collector's edition. Chapter Kidneys and ureter. Page 1398. Accessed April 12, 2022 https://www.taylorfrancis.com/books/9781351617994
2 Matlaga BR, Assimos DG. Changing indications of open stone surgery. Urology 2002;59(04):490–493, discussion 493–494
3 Melissourgos ND, Davilas EN, Fragoulis A, Kiminas E, Farmakis A. Modified anatrophic nephrolithotomy for complete staghorn calculus disease – does it still have a place? Scand J Urol Nephrol 2002;36(06):426–430
4 Esen A, Kirkali Z, Güler C. Open stone surgery: is it still a preferable procedure in the management of staghorn calculi? Int Urol Nephrol 1994;26:247–253
5 Honeck P, Wendt-Nordahl G, Krombach P, et al. Does open stone surgery still play a role in the treatment of urolithiasis? Data of a primary urolithiasis center. J Endourol 2009;23(07):1209–1212
6 Moe OW. Kidney stones: pathophysiology and medical management. Lancet 2006;367(9507):333–344 [PubMed] [Google Scholar]
7 Fink HA, Wilt TJ, Eidman KE, et al. Medical management to prevent recurrent nephrolithiasis in adults: a systematic review for an American College of Physicians Clinical Guideline. Ann Intern Med 2013;158(07):535–543 [PubMed] [Google Scholar]
8 Williams NS, O'Connell PR, McCaskie A, Eds. Bailey & Love's Short Practice of Surgery, Chapter 76, Kidney and Ureters, 27th edition. CRC Press; USA; 2018:1398–1455
9 Heidenreich A, Desgrandschamps F, Terrier F. Modern approach of diagnosis and management of acute flank pain: review of all imaging modalities. Eur Urol 2002;41(04):351–362 [PubMed] [Google Scholar]
10 Kanno T, Kubota M, Sakamoto H, et al. The efficacy of ultrasonography for the detection of renal stone. Urology 2014;84(02):285–288 [PubMed] [Google Scholar]
11 Simforoosh N, Aminsharifi A. Laparoscopic management in stone disease. Curr Opin Urol 2013;23(02):169–174
12 Soltani MH, Simforoosh N, Nouralizadeh A, Sotoudeh M, Mollakoochakian MJ, Shemshaki HR. Laparoscopic pyelolithotomy in children less than two years old with large renal stones: initial series. Urol J 2016;13(05):2837–2840
13 Nouralizadeh A, Simforoosh N, Soltani MH, et al. Laparoscopic transperitoneal pyelolithotomy for management of staghorn renal calculi. J Laparoendosc Adv Surg Tech A 2012;22(01):61–65
14 Simforoosh N, Radfar MH, Valipour R, Dadpour M, Kashi AH. Laparoscopic pyelolithotomy for the management of large renal stones with intrarenal pelvis anatomy. Urol J 2020;18(01):40–44
15 Nouralizadeh A, Simforoosh N, Basiri A, Tabibi A, Soltani MH, Kilani H. Laparoscopic management of ureteropelvic junction obstruction by division of the aberrant vein and cephalad

 

relocation of the crossing artery: a long-term follow-up of 42 cases. J Endourol 2010;24(06):987–991
16 Edvardsson VO, Indridason OS, Haraldsson G, Kjartansson O, Palsson R. Temporal trends in the incidence of kidney stone disease. Kidney Int 2013;83(01):146–152 [PubMed] [CrossRef] [Google Scholar]
17 Al-Azaby H. Transperitoneal laparoscopic pyelolithotomy: initial experience. Benha Med J 2008;25:177–178
18 Al-Hunayan A, Abdulhalim H, El-Bakry E, Hassabo M, Kehinde EO. Laparoscopic pyelolithotomy: is the retroperitoneal route a better approach? Int J Urol 2009;16(02):181–186
19 Qin C, Wang S, Li P, et al. Retroperitoneal laparoscopic technique in treatment of complex renal stones: 75 cases. BMC Urol 2014; 14:16. Doi: 10.1186/1471-2490-14-16
20 Singal R, Dhar S. Retroperitoneal laparoscopic pyelolithotomy in renal pelvic stone versus open surgery - a comparative study. Clujul Med 2018;91(01):85–91
21 Shamim M, Iqbal SA. Open renal approach: comparative analysis of sub-costal incision versus trans-costal incision with excision of 12th rib. Pak J Med Sci 2009;25(04): 557–562
22 Basiri A, Tabibi A, Nouralizadeh A, et al. Comparison of safety and efficacy of laparoscopic pyelolithotomy versus percutaneous nephrolithotomy in patients with renal pelvic stones: a randomized clinical trial. Urol J 2014;11(06):1932–1937
23 Mujeeburahiman M, Vipin C. Laparoscopic pyelolithotomy as a monotherapy for the management of intermediate-sized renal pelvic stones. Urol Ann 2018;10(03):254–257

 