


# Implementation of a Bedside Point-of-Care Ultrasound Program in a Large Academic Neonatal Intensive Care Unit

Vidya V. Pai, MD, MS<sup>1</sup> Caroline Y. Noh, MD, MS<sup>2</sup>  Reedhi Dasani, BS<sup>2</sup>  
Shelby Vallandingham, NNP-BC, DNP<sup>2</sup> Christine Manipon, NNP<sup>2</sup> Bereketiab Haileselassie, MD<sup>4</sup>  
Jochen Profit, MD, MPH<sup>2,3</sup> Malathi Balasundaram, MD<sup>2</sup> Alexis S. Davis, MD, MS<sup>2</sup> Shazia Bhombal, MD<sup>2</sup>

<sup>1</sup> Division of Neonatology, UCSF Benioff Children's Hospital Oakland, Oakland, California

<sup>2</sup> Division of Neonatal and Developmental Medicine, Department of Pediatrics, Stanford University School of Medicine, Stanford, California

<sup>3</sup> California Perinatal Quality Care Collaborative, Stanford, California

<sup>4</sup> Division of Pediatric Critical Care, Department of Pediatrics, Stanford University School of Medicine, Stanford, California

**Address for correspondence** Shazia Bhombal, MD, 453 Quarry Rd, MC 5660, Palo Alto, CA 94304 (e-mail: sbhombal@stanford.edu).

Am J Perinatol

## Abstract

**Objective** In the adult and pediatric critical care population, point-of-care ultrasound (POCUS) can aid in diagnosis, patient management, and procedural accuracy. For neonatal providers, training in ultrasound and the use of ultrasound for diagnosis and management is increasing, but use in the neonatal intensive care unit (NICU) is still uncommon compared with other critical care fields. Our objective was to describe the process of implementing a POCUS program in a large academic NICU and evaluate the role of ultrasound in neonatal care during early adaptation of this program.

**Study Design** A POCUS program established in December 2018 included regular bedside scanning, educational sessions, and quality assurance, in collaboration with members of the cardiology, radiology, and pediatric critical care divisions. Core applications were determined, and protocols outlined guidelines for image acquisition. An online database included images and descriptive logs for each ultrasound.

**Results** A total of 508 bedside ultrasounds (76.8% diagnostic and 23.2% procedural) were performed by 23 providers from December 2018 to December 2020 in five core diagnostic applications: umbilical line visualization, cardiac, lung, abdomen (including bladder), and cranial as well as procedural applications. POCUS guided therapy and influenced clinical management in all applications: umbilical line assessment (26%), cardiac (33%), lung (14%), abdomen (53%), and cranial (43%). With regard to procedural ultrasound, 74% of ultrasound-guided arterial access and 89% of ultrasound-guided lumbar punctures were successful.

**Conclusions** Implementation of a POCUS program is feasible in a large academic NICU and can benefit from a team approach. Establishing a program in any NICU requires didactic opportunities, a defined scope of practice, and imaging review with quality assurance. Bedside clinician performed ultrasound findings can provide valuable information in the NICU and impact clinical management.

## Keywords

- ▶ bedside ultrasound
- ▶ POCUS
- ▶ program development
- ▶ ultrasound program

received  
November 26, 2021  
accepted after revision  
April 29, 2022

© 2022. Thieme. All rights reserved.  
Thieme Medical Publishers, Inc.,  
333 Seventh Avenue, 18th Floor,  
New York, NY 10001, USA

DOI <https://doi.org/10.1055/s-0042-1750118>.  
ISSN 0735-1631.

## Key Points

- Use of point-of-care ultrasound is increasing in neonatology and has been shown to improve patient care.
- Implementation of a point-of-care ultrasound program requires the definition of scope of practice and can benefit from the support of other critical care and imaging departments and providers.
- Opportunities for point-of-care ultrasound didactics, imaging review, and quality assurance can enhance the utilization of bedside ultrasound.

In critical care medicine, point-of-care ultrasound (POCUS) has been shown to provide rapid diagnostic capability, enhance patient care, and improve procedural accuracy.<sup>1</sup> POCUS is used readily in numerous medical specialties and as a result of growing utilization, ultrasound is now a key component of medical school curriculum and graduate medical education training programs in emergency medicine and critical care.<sup>2-4</sup> In neonatology, training in ultrasound and the use of ultrasound for diagnosis and management is increasing, but overall its use is still uncommon compared with other critical care fields.<sup>5,6</sup> A growing body of literature demonstrates the potential benefits of POCUS for several diagnostic and procedural applications in the neonatal intensive care unit (NICU). This includes rapid assessment of lung disease, cardiac function, and cranial pathology in neonates.<sup>7-10</sup> In addition, ultrasound can guide and confirm the placement of central lines and can improve the accuracy of arterial line placement and lumbar punctures.<sup>11-14</sup>

Given the numerous applications for POCUS in neonatology, the establishment of ultrasound programs in NICUs is increasing. Currently, no formal guidelines exist in neonatology for training, competency standards, or certification in POCUS. In this article, we report our initial efforts, structure, and progress in establishing a POCUS program in an academic NICU. We describe our training program and curriculum development, program structure, data management and quality assurance (QA) process, as well as the initial impact of POCUS on patient care.

## Materials and Methods

### Program Implementation and Structure

The NICU at Lucile Packard Children's Hospital (LPCH) is a Level IV regional center.<sup>15</sup> Experience with ultrasound in our NICU was initially limited to two faculty members with prior training in echocardiography (ECHO) and POCUS. An additional faculty member, one fellow and two neonatal nurse practitioners (NNP) received immersive bedside and hands-on training in bedside ultrasound at an intensive national course in November 2018. This group formed a core LPCH NICU POCUS team with the intent of establishing a program beginning in December 2018. The team eventually grew to include four faculty, two fellows, two NNPs, and one research data coordinator. The program received a grant in August 2019 from the Lucile Packard Foundation for Children's Health to support equipment, personnel, and training. The NICU received two ultrasound machines from other areas of the hospital and purchased a second more advanced machine

with ultrasound probes more applicable for the neonatal population in December 2019.

Prior to program initiation, we utilized a multidisciplinary approach to integrate bedside ultrasound into the unit. We collaborated with radiology and cardiology divisions to determine the scope of bedside ultrasound in our unit as an adjunct to clinical care. Both divisions agreed to assist in establishing guidelines and protocols for image acquisition and review images for QA. At our institution, bedside ultrasound was already readily utilized by providers in the pediatric critical care unit (PICU). Therefore, we collaborated to share resources, create a joint database, and establish educational and training opportunities for providers in both divisions. Team meetings occurred weekly and included discussion on program development, research opportunities, and imaging review for QA. At least one provider from the team was available in the NICU 3 days a week to serve as a resource to the clinical teams and be available for POCUS when needed.

### Training and Curriculum Development

Following the ultrasound course attended by the initial core team, which included education on basic ultrasound principles and terminology; didactic and hands-on training sessions on cardiac, lung, abdomen, spine and cranial diagnostic imaging; and ultrasound-guided procedures, the team began performing regular scans in the LPCH NICU. We established an ultrasound curriculum at our institution that included formal 2-day immersive ultrasound courses held at least annually, in addition to joint bimonthly didactic and hands-on training sessions with the PICU. The first formal immersive ultrasound course was held in June 2019 for NICU fellows, attendings, and NNPs with a goal of expanding the number of providers with knowledge of ultrasound basics and skills in bedside ultrasound. Faculty from radiology, cardiology, and PICU helped facilitate the course, in addition to neonatology providers. A second course was held for the first and second-year fellows in neonatal-perinatal medicine and pediatric critical care medicine in August 2020. Bimonthly didactic and bedside practical sessions were organized in conjunction with pediatric critical care faculty and focused primarily on training fellows.

NICU POCUS leadership met with the lead physician for the Stanford Hospital ultrasound program to understand what institutional precedents, criteria, and resources existed for establishing an equivalent program in the children's hospital. Based on their feedback, learners were expected to achieve competency through performing and interpreting

scans under the supervision of or reviewed by a core team member for diagnostic exams, based on recommendations from the American College of Emergency Physicians statement for diagnostic applications.<sup>16</sup> Learners are required to perform 25 scans in each core diagnostic application, including 10 required for bladder, before scans could be used to influence clinical management. Core team members were also available routinely on the unit or remotely to review scans and provide feedback on image acquisition and interpretation in real time.

### Neonatal Ultrasound Core Applications and Scanning Protocols

Based on the existing literature and experience in other critical care fields, diagnostic core applications for ultrasound use in the NICU were determined to include imaging for umbilical line assessment, cardiac, lung, cranial, and abdomen/bladder. Procedural applications included umbilical line placement, lumbar puncture, and vascular access. Bedside ultrasound was not intended to replace formal ultrasound or ECHO when otherwise indicated, and the specific application of POCUS in the NICU was discussed with cardiology and radiology divisions. The team established scanning protocols for each core application that included guidelines on how to obtain a complete study, including probe type, patient position, necessary views, and sample images for reference. These protocols provide a framework for standardization to ensure images are properly acquired. For each core application, indications were established to aid providers in targeting the scan to answer a defined question.

### Data Management and Quality Assurance

We initially tracked only ultrasound indication, interpretation, and impact before creating a secure, web-based database in October 2019 using Research Electronic Data Capture (REDCap) that was Health Insurance Portability and Accountability Act (HIPAA) compliant and Institutional Review Board approved. The Stanford REDCap platform (<http://redcap.stanford.edu>) is developed and operated by Stanford Medicine Research IT team. The REDCap platform services at Stanford are subsidized by a) Stanford School of Medicine Research Office, and b) the National Center for Research Resources and the National Center for Advancing Translational Sciences, National Institutes of Health, through grant UL1 TR001085. Indications for the ultrasound and other key metrics for each core application were predetermined and included in the datasheet (→Fig. 1). After each study, providers completed an online data sheet in REDCap that is accessed by a Quick Response code on the machines. Providers documented the type of image obtained, clinical questions, findings and interpretation, and what actions were taken based on the ultrasound findings. Along with the review of the images, the database serves to primarily aid in QA and data tracking. In addition, it assists in clinical research and program development, acting as a logbook to track an individual's ultrasound numbers.

Images from the ultrasound machines were acquired and archived on a HIPAA-compliant cloud storage service avail-

able through Stanford University. QA sessions with imaging review were held weekly, where the team reviewed all archived images and REDCap logs. Image sequences were reviewed for completeness and image quality based on predefined metrics from the protocols for each application. Sessions incorporated multiple disciplines including radiology faculty and other critical care faculty with ultrasound expertise. As part of the REDCap log, providers could request feedback regarding their images and interpretation.

### Statistical Analysis

The total number of ultrasounds performed in the NICU for clinical indications was evaluated from December 1, 2018 to December 30, 2020. We describe the ultrasounds performed in each core application, the types of providers performing the ultrasounds, and the indications for each scan. Finally, through reviewing the REDCap logs, based on two independent assessments, we evaluated whether the bedside ultrasound prompted a change in clinical management.

### Results

In addition to the core team of 6 providers initially trained in bedside ultrasound, an additional 22 providers attended the institutional 2-day POCUS course in June 2019. Sixteen neonatology and pediatric critical care providers attended the course in August 2020.

A total of 508 (76.8% diagnostic and 23.2% procedural) bedside ultrasounds were performed in the NICU on 290 patients from December 1, 2018 to December 31, 2020 by 4 attendings, 12 fellows, 4 NNPs, and 3 neonatal hospitalists. Scans were performed in five diagnostic applications: umbilical line visualization, cardiac, lung, abdomen (including bladder), and cranial. Procedural applications included ultrasound-guided umbilical line placement, vascular access, and lumbar puncture. The number of scans and their indications are detailed in →Table 1.

In our unit, bedside ultrasound was used both for surveillance of umbilical catheter tip position and during umbilical catheter placement. Of the 243 umbilical lines that were visualized as part of routine surveillance, 64 (26%) were identified to be in an inappropriate position, prompting line manipulation or removal. Based on the review of documentation in REDCap, 5 out of 15 (33%) cardiac, 10 out of 72 (14%) lung, 27 out of 48 (56%) bladder, 1 out of 5 (20%) abdominal (non-bladder), and 3 out of 7 (43%) cranial ultrasounds influenced clinical management. →Table 2 details examples of how POCUS within each of these applications impacted management. Ultrasound-guided peripheral vascular access was used for arterial catheter placement and resulted in successfully placed catheters in 35 out of 47 (74%) attempts. There were 31 scans done to evaluate spinal fluid, and in all scans lumbar puncture was either attempted (26) or deferred (5) based on the presence or absence of adequate fluid or presence of a hematoma. Successful lumbar puncture was performed in 23 out of 26 (89%) of patients who had spinal ultrasounds demonstrating adequate fluid. As we continued

Fig. 1 Example of REDCap online datasheet.

to train providers and provide bedside support, bedside ultrasound use increased over the 2-year period (→ Fig. 2).

## Discussion

This article describes our initial process of implementing a POCUS program in a large academic NICU. In a 2-year period, we performed 508 scans; expanded the number of providers performing ultrasound in our unit; and established an educational program, ultrasound image database, and QA regimen. Following our initial immersive course, we partnered with the PICU to enhance program development. Successful implementation of a POCUS program requires access to

educational programs and competency assessment, a defined scope of practice and established protocols, and imaging review with QA. In addition, collaboration with other fields that utilize bedside ultrasound, including critical care, radiology, and cardiology, is crucial to ensuring success.

We demonstrate that POCUS was able to influence clinical management, including as a prompt to obtain formal ultrasound or radiograph imaging in five core applications (umbilical line assessment, cardiac, lung, abdomen, and cranial). Although it is difficult to define the degree to which POCUS improved care and clinical outcomes, our data highlight clinical scenarios where POCUS can be a crucial diagnostic tool. For example, in an infant who has decreased urine



**Table 1** POCUS scans by core application and indication

Core application and indication	Number of scans (%)
Umbilical line assessment	283 (55.7%)
<i>Visualization</i>	243
<i>Placement and visualization<sup>o</sup></i>	40
Cardiac	15 (3.0%)
<i>Function</i>	8
<i>Inferior vena cava filling</i>	6
<i>Pericardial effusion</i>	4
<i>Other</i>	3
Lung	72 (14.2%)
<i>Effusion</i>	17
<i>Pneumothorax</i>	9
<i>Evaluation of lung pathology while on respiratory support (RDS and TTN)</i>	49
Cranial	7 (1.4%)
<i>IVH</i>	4
<i>Ventricular size assessment</i>	2
<i>Other (abnormal anatomy)</i>	2
Abdomen/Bladder	53 (10.4%)
<i>Bladder volume assessment</i>	45
<i>Urinary catheter visualization</i>	7
<i>Ascites</i>	2
<i>Other</i>	3
Lumbar puncture <sup>a</sup>	31 (6.1%)
Peripheral vascular access <sup>a</sup>	47 (9.2%)
Total	508

Abbreviations: IVH, Intraventricular hemorrhage; POCUS, point-of-care ultrasound; RDS, respiratory distress syndrome; TTN, transient tachypnea of the newborn.

<sup>a</sup>Procedural applications included ultrasound-guided umbilical line placement, lumbar puncture, and peripheral vascular access.

output, POCUS can quickly elucidate whether this is due to urinary retention or oliguria, and that information can guide whether a urinary catheter or fluid administration would be an appropriate intervention. Similarly, in an infant who is hemodynamically unstable, POCUS can identify pathology such as a pericardial effusion that would allow for rapid intervention. POCUS allows for more targeted interventions, can avoid unnecessary procedures and treatments, and can be used to provide rapid diagnostic information when formal imaging may not be immediately available.<sup>1,17–19</sup>

Despite the widespread use of bedside ultrasound in clinical medicine throughout the world, POCUS in neonatology is still in an early initiation phase in much of the United States. In Australia, New Zealand, and throughout Europe, training programs for comprehensive bedside cardiac ultrasound have been established and neonatologists regularly use ultrasound in their clinical practice.<sup>20–22</sup> In the United States, however, neonatologists report limited availability of

equipment and required skills to perform POCUS.<sup>10</sup> A recent survey of neonatologists in the United States found that although 90% of responders supported the introduction of POCUS in their clinical practice, several barriers prevented them from doing so.<sup>6</sup> A majority of neonatologists cited concerns about the lack of training guidelines, inadequate support from other services, and legal concerns. Additional barriers included skill maintenance, conflict of interest with radiology and cardiology services, and cost to purchase and maintain equipment.<sup>6</sup> In establishing our program, we were fortunate to obtain a grant that supported a program coordinator position, purchasing equipment, and time for faculty to devote to program development. We initiated a method for image archiving and review to ensure a robust QA process. We engaged multiple services early, including partnering with the PICU for joint educational sessions and QA. Our radiology and cardiology divisions were supportive of the use of POCUS, with several meetings prior to the initiation of our program to clarify the applications for POCUS in the NICU to ensure that it would not replace a formal ultrasound or ECHO when those would otherwise be clinically indicated.

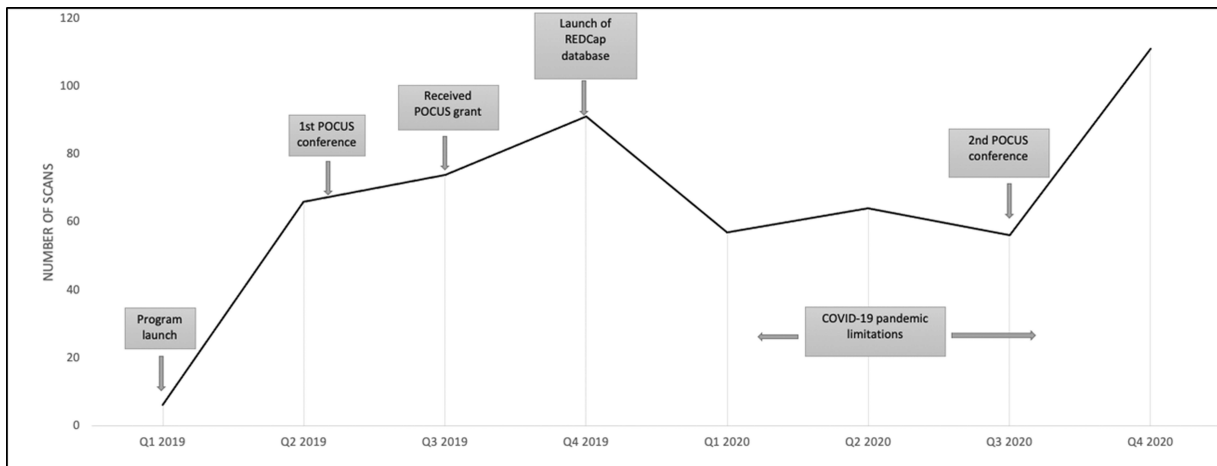
Neonatologists considering utilizing POCUS in their institution should first determine appropriate applications in their clinical setting. Large variability currently exists in bedside ultrasound application, training, and oversight in clinical neonatology practice. The Emergency Care Research Institute listed the lack of oversight regarding when and how to use POCUS as one of the top ten health technology hazards in 2020.<sup>23</sup> Many experts agree that as more NICUs invest in ultrasound equipment, it is important to develop evidence-based guidelines for use, develop standards for training, specify the scope of practice, and establish mechanisms for QA.<sup>24</sup> The European Society of Pediatric and Neonatal Intensive Care established an international POCUS working group that created evidence-based guidelines for bedside ultrasound use in the NICU and PICU for the following application: cardiac, lung, abdominal, cranial, and vascular access. These guidelines outline important features of structured POCUS applications in clinical practice, including the estimated level of training required for their use. For example, for those with basic lung POCUS training, there was agreement that POCUS may be helpful with differentiating between respiratory distress syndrome and transient tachypnea of the neonate, assessing for pneumothorax and pleural effusion, and providing guidance for thoracic procedures.<sup>25</sup> As our hospital has not yet implemented credentialing requirements for POCUS, the scanning protocols and REDCap datasheets that we created for our core applications correlate with these guidelines in anticipation of requiring medical staff privileges for POCUS in the future.

Although recently there have been more opportunities for training in POCUS, options for formal training remain limited and no universal curriculum or accreditation process exists. Establishing a scope of practice for an institution and utilizing existing guidelines are important when first implementing the use of POCUS and determining what training is required. All POCUS group members received initial bedside ultrasound experience through a 2-day intensive course and

**Table 2** Examples of POCUS scans in the NICU affecting management

	<b>Patient information and diagnosis</b>	<b>Study indication/clinical question</b>	<b>Interpretation</b>	<b>Intervention</b>
Umbilical line	35-wk infant with ectopic atrial tachycardia and umbilical venous catheter	Confirmation of tip location given arrhythmia while awaiting X-ray	Tip in the right atrium, measured 1.5 cm above the junction between the inferior vena cava (IVC) and right atrium (RA)	Line retracted under ultrasound guidance with resolution of arrhythmia before X-ray was able to be obtained
	27-wk infant with umbilical venous catheter	Catheter tip below diaphragm on recent X-ray, so POCUS done to confirm location	Tip visualized below IVC/RA junction in ductus venosus	Catheter removed and PICC line placed
Cardiac	Term infant with necrotizing fasciitis	Hypotension postoperative, assess cardiac function and filling and need for vasoactives versus volume	Poor cardiac function, ventricles not underfilled	Initiated pressor support, cardiology consult called for comprehensive echocardiogram
	Term infant with hypoxic respiratory failure on extracorporeal membrane oxygenation support with decreased near infrared spectroscopy values of unknown etiology	Assess cannula position	Large pericardial effusion	Formal ECHO obtained and multidisciplinary discussion regarding intervention
Lung	Term infant with congenital diaphragmatic hernia on extracorporeal membrane oxygenation support with new opacification on X-ray	Evaluate for effusion versus consolidation	Large effusion visualized	Formal ultrasound ordered to quantify fluid, surgical team notified and chest tube placed
Cranial	27-wk infant with anemia, acidosis, coagulopathy	Evaluate for hemorrhage	New large, intraparenchymal hemorrhage	Received several blood products. Formal head ultrasound confirmed bilateral intraparenchymal hemorrhages
Abdomen/Bladder	Term infant with intestinal perforation and bowel resection with purulent fluid at the incisional site Preterm infant with prenatally identified large ascites, compromised ventilation in the delivery room	Evaluate for abdominal fluid Evaluate for abdominal fluid prior to paracentesis	Fluid collection visualized Large volume of ascites visualized	Formal ultrasound obtained and surgical team notified Guided paracentesis performed in the delivery room with subsequent improvement in respiratory status
	Term infant with hypoxic ischemic encephalopathy, receiving therapeutic hypothermia and on morphine	Oliguria	Distended bladder visualized	Foley placed and 27-mL urine drained
	Term infant with esophageal atresia with foley in place but decreased urine output postoperatively	Oliguria	Bladder with low volume	Normal saline bolus given

Abbreviations: ECHO, echocardiography; IVH, intraventricular hemorrhage; NICU, neonatal intensive care unit; PICC, peripherally inserted central catheter; POCUS, point-of-care ultrasound; RDS, respiratory distress syndrome; TTN, transient tachypnea of the newborn.



**Fig. 2** Number of POCUS scans by quarter from December 2018 to December 2020.

gained hands-on experience under the guidance of two group members who had prior training in ECHO and POCUS. To introduce POCUS to a broader group of neonatologists, nurse practitioners, and trainees, we subsequently organized courses at our own institution while also soliciting external faculty experts in bedside ultrasound. In addition, we implemented regular didactic and hands-on training sessions in collaboration with PICU providers. Short POCUS courses offer an introduction to bedside ultrasound but regular hands-on training sessions and bedside implementation are necessary to truly master the skill. In implementing a POCUS program, both large and smaller NICUs may find it beneficial to start with a core group of providers who can be trained in POCUS and can subsequently expand the use of the skill to as many providers as is necessary and feasible. At our institution, we have continued to organize POCUS courses with our PICU colleagues to expand the use of POCUS in both academic and community settings in Northern California.

A collaborative approach with the involvement of other clinical imaging services and critical care fields is integral for POCUS implementation. Early acceptance and integration by PICU and emergency medicine providers are a resource for enhancing bedside ultrasound education and imaging review. Similarly, given the overlap that bedside ultrasound may have with the services provided by cardiology and radiology, it is important to define the scope of utilization with these departments and reinforce that bedside ultrasound is a specific tool to answer defined questions rather than a replacement for medical imaging performed or interpreted by cardiologists and radiologists. In particular, cardiac POCUS in neonates should be intended to answer acute and focused clinical questions, and given the possibility of congenital heart disease, a comprehensive ECHO must be performed to confirm normal heart anatomy.<sup>26</sup> Many community NICUs may not have access to other pediatric providers who already utilize POCUS; however, pediatric radiology and cardiology services are generally available and these providers can be valuable resources for education, imaging review, and QA.

Certain programs may require credentialing prior to use of POCUS, with pathway to the creation of a program including discussions with hospital administration to identify a credentialing pathway. Certification and credentialing are currently not established at our institution, but our program aims to develop internal guidelines for credentialing that will require completion of both didactic, hands-on, or simulation programs, as well as a successful demonstration of a requisite number of ultrasounds and interpretations for each application with oversight and assessment of competency through a QA program. Currently, no national or international standards to define competence or credentialing for POCUS in neonatology exist, but standardized pathways to credentialing, as emergency medicine has established, should be pursued.<sup>4,27,28</sup> Smalley et al outline a standardized POCUS credentialing initiative in a large health care system that demonstrated ability to credential community emergency medicine physicians, including providing educational courses, scanning and documenting educational exams in the electronic medical record, and reviewing images.<sup>29</sup> Mathews and Zwank describe the images necessary to obtain as the process for credentialing as well as the requirement to pass a final written and hands-on exam to assess competency prior to applying for POCUS credentialing. The timeline to achieve competency varied among providers.<sup>30</sup> Outlining a similar process in neonatology is needed to provide a framework and pathway to credentialing with QA processes as programs adopt POCUS in their units. POCUS in the NICU is becoming increasingly ubiquitous, with increasing applications providing further diagnostic tools to aid in the care of our neonatal population. For those in institutions who do not permit the use of POCUS without prior credentialing and certification, we recommend working with hospital administration and following a transparent and careful initiation, leveraging expertise from all areas of the hospital to establish a high quality, high fidelity program to advance the care of newborns. Without this, a mandate for prior credentialing amounts to circular logic that would prevent POCUS from being introduced into the NICU when established literature supports its use.

The development of a NICU POCUS program benefits from a team approach, encompassing educational opportunities and QA with interdisciplinary collaboration. Taking notes from our colleagues in fields with established POCUS standards, such as emergency medicine, POCUS in the NICU would benefit from standardization and guidance including scope of practice, training guidelines, credentialing, and quality assessment to enhance program development and create a mechanism for ensuring optimal roll out and use to impact patient care.

#### Conflict of Interest

None declared.

#### Acknowledgments

We would like to acknowledge the funding support for this program provided by the Lucile Packard Foundation for Children's Health. We would also like to acknowledge the Divisions of Neonatology, Cardiology, Radiology and Pediatric Critical Care Medicine at Stanford University School of Medicine for their support of this program. Finally, we acknowledge the NICU and PICU ultrasound program at the Children's Hospital of Philadelphia, specifically Drs. Thomas Conlon, Maria Fraga, Akira Nishisaki, and Jason Stoller who were some of the first in the United States to establish a POCUS program and an intensive national course in bedside ultrasound and who have provided guidance for program development and educational opportunities.

#### References

- Moore CL, Copel JA. Point-of-care ultrasonography. *N Engl J Med* 2011;364(08):749–757
- Dinh VA, Fu JY, Lu S, Chiem A, Fox JC, Blaivas M. Integration of ultrasound in medical education at United States medical schools: a national survey of directors' experiences. *J Ultrasound Med* 2016;35(02):413–419
- American College of Emergency Physicians. Emergency ultrasound guidelines. *Ann Emerg Med* 2009;53(04):550–570
- Marin JR, Lewiss RE American Academy of Pediatrics, Committee on Pediatric Emergency Medicine Society for Academic Emergency Medicine, Academy of Emergency Ultrasound American College of Emergency Physicians, Pediatric Emergency Medicine Committee World Interactive Network Focused on Critical Ultrasound. Point-of-care ultrasonography by pediatric emergency medicine physicians. *Pediatrics* 2015;135(04):e1113–e1122
- Nguyen J, Amirnovin R, Ramanathan R, Noori S. The state of point-of-care ultrasonography use and training in neonatal-perinatal medicine and pediatric critical care medicine fellowship programs. *J Perinatol* 2016;36(11):972–976
- Mirza HS, Logsdon G, Pulickal A, Stephens M, Wadhawan R. A national survey of neonatologists: barriers and prerequisites to introduce point-of-care ultrasound in neonatal ICUs. *Ultrasound Q* 2017;33(04):265–271
- Woods PL. Utility of lung ultrasound scanning in neonatology. *Arch Dis Child* 2019;104(09):909–915
- Liu J, Copetti R, Sorantin E, et al. Protocol and guidelines for point-of-care lung ultrasound in diagnosing neonatal pulmonary diseases based on international expert consensus. *J Vis Exp* 2019; (145):. Doi: 10.3791/58990
- de Boode WP, van der Lee R, Horsberg Eriksen B, et al; European Special Interest Group 'Neonatologist Performed Echocardiography' (NPE) The role of neonatologist performed echocardiography in the assessment and management of neonatal shock. *Pediatr Res* 2018;84(1, Suppl 1):57–67
- Evans N, Gournay V, Cabanas F, et al. Point-of-care ultrasound in the neonatal intensive care unit: international perspectives. *Semin Fetal Neonatal Med* 2011;16(01):61–68
- Jain A, McNamara PJ, Ng E, El-Khuffash A. The use of targeted neonatal echocardiography to confirm placement of peripherally inserted central catheters in neonates. *Am J Perinatol* 2012;29(02):101–106
- Katheria AC, Fleming SE, Kim JH. A randomized controlled trial of ultrasound-guided peripherally inserted central catheters compared with standard radiograph in neonates. *J Perinatol* 2013;33(10):791–794
- Fleming SE, Kim JH. Ultrasound-guided umbilical catheter insertion in neonates. *J Perinatol* 2011;31(05):344–349
- Liu L, Tan Y, Li S, Tian J. "Modified dynamic needle tip positioning" short-axis, out-of-plane, ultrasound-guided radial artery cannulation in neonates: a randomized controlled trial. *Anesth Analg* 2019;129(01):178–183
- Stark AR American Academy of Pediatrics Committee on Fetus and Newborn. Levels of neonatal care. *Pediatrics* 2004;114(05):1341–1347
- Ultrasound Guidelines. Ultrasound guidelines: emergency, point-of-care and clinical ultrasound guidelines in medicine. *Ann Emerg Med* 2017;69(05):e27–e54
- Kantor DB, Su E, Milliren CE, Conlon TW. Ultrasound guidance and other determinants of successful peripheral artery catheterization in critically ill children. *Pediatr Crit Care Med* 2016;17(12):1124–1130
- Escourrou G, De Luca D. Lung ultrasound decreased radiation exposure in preterm infants in a neonatal intensive care unit. *Acta Paediatr* 2016;105(05):e237–e239
- Fraga MV, Stoller JZ, Glau CL, et al. Seeing is believing: ultrasound in pediatric procedural performance. *Pediatrics* 2019;144(05):e20191401
- Singh Y, Roehr CC, Tissot C, et al; European Special Interest Group 'Neonatologist Performed Echocardiography' (NPE) Education, training, and accreditation of neonatologist performed echocardiography in Europe-framework for practice. *Pediatr Res* 2018;84(1, Suppl 1):13–17
- Roehr CC, Te Pas AB, Dold SK, et al. Investigating the European perspective of neonatal point-of-care echocardiography in the neonatal intensive care unit—a pilot study. *Eur J Pediatr* 2013;172(07):907–911
- Singh Y, Gupta S, Groves AM, et al. Expert consensus statement 'Neonatologist-performed Echocardiography (NoPE)-training and accreditation in UK. *Eur J Pediatr* 2016;175(02):281–287
- (ECRI) ECRI. Top 10 Health Technology Hazards for 2020. 2021 Accessed August 8, 2021 at: <https://www.ecri.org/landing-2020-top-ten-health-technology-hazards>
- Finan E, Sehgal A, Khuffash AE, McNamara PJ. Targeted neonatal echocardiography services: need for standardized training and quality assurance. *J Ultrasound Med* 2014;33(10):1833–1841
- Singh Y, Tissot C, Fraga MV, et al. International evidence-based guidelines on Point of Care Ultrasound (POCUS) for critically ill neonates and children issued by the POCUS Working Group of the European Society of Paediatric and Neonatal Intensive Care (ESPNIC). *Crit Care* 2020;24(01):65
- Mertens L, Seri I, Marek J, et al; Writing Group of the American Society of Echocardiography European Association of Echocardiography Association for European Pediatric Cardiologists. Targeted neonatal echocardiography in the neonatal intensive care unit: practice guidelines and recommendations for



- training. Writing Group of the American Society of Echocardiography (ASE) in collaboration with the European Association of Echocardiography (EAE) and the Association for European Pediatric Cardiologists (AEPC). *J Am Soc Echocardiogr* 2011;24(10):1057–1078
- 27 Hébert A, Lavoie PM, Giesinger RE, et al. Evolution of training guidelines for echocardiography performed by the neonatologist: toward hemodynamic consultation. *J Am Soc Echocardiogr* 2019;32(06):785–790
- 28 Boyd S, Kluckow M. Point of care ultrasound in the neonatal unit: applications, training and accreditation. *Early Hum Dev* 2019;138:104847
- 29 Smalley CM, Fertel BS, Broderick E. Standardizing point-of-care ultrasound credentialing across a large health care system. *Jt Comm J Qual Patient Saf* 2020;46(08):471–476
- 30 Mathews BK, Zwank M. Hospital medicine point of care ultrasound credentialing: an example protocol. *J Hosp Med* 2017;12(09):767–772