Article published online: 2022-09-19

Idiopathic Aneurysm of the Aortic Arch in an Infant

Tomislav Cvitkovic[1] Elena Petena[1] Samir Sarikouch[1] Lavinia Neubert[2] Philipp Beerbaum[3] Alexander Horke[1] Dmitry Bobylev[1]

[1] Department of Cardiothoracic, Transplantation and Vascular Surgery, Hannover Medical School, Hannover, Germany
[2] Institution of Pathology, Hannover Medical School, Hannover, Germany
[3] Department of Pediatric Cardiology and Intensive Care, Hannover Medical School, Hannover, Germany

Address for correspondence Dmitry Bobylev, MD, Hannover Medical School, Carl-Neuberg-Street 1, Hannover, Lower Saxony 30625, Germany (e-mail: bobylev.dmitry@mh-hannover.de).

Thorac Cardiovasc Surg Rep 2022;11:e54–e57.

Abstract

Congenital aortic aneurysms are rare disorders, usually associated with genetic aortic syndromes. Here, we describe the case of an idiopathic aortic arch aneurysm which had been diagnosed prenatally by fetal echocardiography. The diagnosis was confirmed after birth in the neonatal period and successful surgical resection of the aneurysm was performed at the age of 3 months. The idiopathic etiology of the aneurysm, its localization, and the early surgical resection render this case very unusual.

Keywords
- aortic arch
- aneurysm
- infant
- cardiovascular imaging

Introduction

Aortic aneurysms are rare in infancy or childhood. Most of them are associated with genetic aortic syndromes (connective tissue disorders or congenital bicuspid aortic valve), infection, trauma, or complications following umbilical artery catheterization.[1–3] In terms of localization, they can develop in different parts of the aorta; the most common are abdominal aneurysms, aneurysms of thoracoabdominal, or ascending aorta occurring less frequently.[4,5] The treatment of these potentially life-threatening conditions can be complex and challenging. We present a case of a congenital saccular aneurysm of the aortic arch requiring surgical resection due to the risk of rupture or possible thrombus formation.

Case Presentation

During fetal sonographic screening of a 39-year-old primigravida, a saccular aneurysm of the aortic arch of uncertain etiology was found. Based on this finding, a female baby (38 weeks of gestation, weighing 3,290 g) was uncomplicated delivered by caesarean section. Transthoracic echocardiography at birth confirmed the initial diagnosis. The aneurysm (~14 mm × 15 mm) was located in proximal aortic arch, in the area of the truncus brachiocephalicus. No signs of other dilatations at the other segments of the thoracic aorta were observed. The anatomy and the function of the heart were normal. The newborn was admitted to the Department of Pediatric Cardiology and Intensive Care. The patient's clinical status did not suggest any genetic aortic syndromes and the postnatal adaptation of the baby had been uneventful. The patient was discharged home and monitored in the department's outpatient clinic. However, indications suggesting growth of the aneurysm were observed and the patient was readmitted for surgical treatment. A preoperative computed tomography angiogram of the chest revealed a saccular aneurysm, localized at the proximal part of the aortic arch and measuring 15 mm × 16 mm × 25 mm, compared with a 9-mm ascending aorta and 6-mm transverse aortic arch. The truncus brachiocephalicus was arising from the posterior

received
February 22, 2022
accepted after revision
March 22, 2022

DOI https://doi.org/10.1055/s-0042-1750426.
ISSN 2194-7635.

© 2022. The Author(s).
This is an open access article published by Thieme under the terms of the Creative Commons Attribution-NonDerivative-NonCommercial-License, permitting copying and reproduction so long as the original work is given appropriate credit. Contents may not be used for commercial purposes, or adapted, remixed, transformed or built upon. (https://creativecommons.org/licenses/by-nc-nd/4.0/)

Georg Thieme Verlag KG, Rüdigerstraße 14, 70469 Stuttgart, Germany

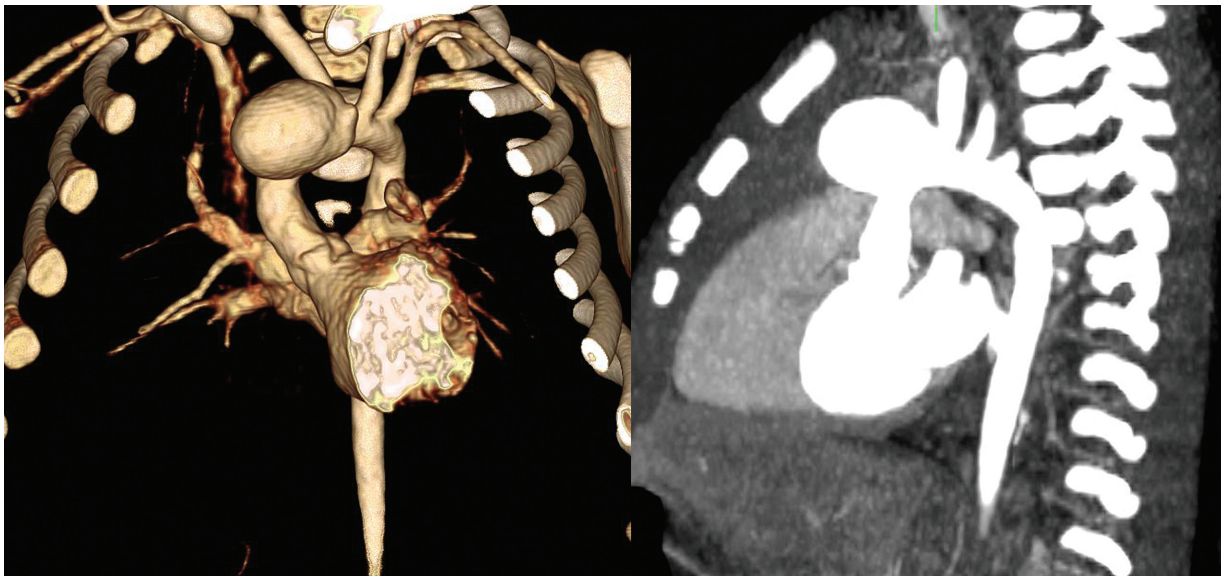

Fig. 1 The preoperative computed tomography angiogram demonstrates a large saccular aneurysm of the aortic arch with the truncus brachiocephalicus arising from the posterior part of aneurysm.

portion of the aneurysm (►**Fig. 1**). Due to the increasing size of aneurysm and related risk of rupture or possible thrombus formation, a surgical resection of the aneurysm was performed in the patient at age of 3 months.

After median sternotomy and resection of the thymus tissue, a pulsated protrusion of the pericardium was found. The pericardium was opened carefully and the saccular aneurysm in the proximal aortic arch was identified (►**Fig. 2A**). Extracorporeal circulation was established with aortic and right atrium cannulation. The left atrium was drained via the right upper pulmonary vein and the patient was cooled down to 20°C. The transverse aortic arch and its branches were mobilized. Cardiac arrest was achieved with antegrade cold blood cardioplegia. Perfusion flow was decreased, and aortic cannula were placed in the truncus brachiocephalicus for selective brain perfusion. The distal aortic arch and the aortic branches were clamped. The lumen of aneurysm was carefully opened and the orifice of the truncus brachiocephalicus inspected from inside (►**Fig. 2B**). The irregular tissue of aneurysm was carefully resected, and the aorta was reconstructed with a glutaraldehyde-treated autologous pericardial patch (►**Fig. 2C**). The postoperative course was uneventful. The patient was extubated on postoperative day 1 and discharged home on day 9. Histological examination revealed local degeneration of the aortic wall with partial loss of elastic fibers and deposition of mucopolysaccharides (►**Fig. 3A, B**).

Medication with acetylsalicylic acid was initiated for 3 months postoperatively and the baby was monitored for over 6 months at our outpatient clinic. At her most recent follow-up, the echocardiogram revealed no local recurrence or any other dilatation at the thoracic aorta (►**Fig. 4**).

Discussion

Prenatal diagnosis has led to a significant improvement in the chances of survival in children with congenital heart and

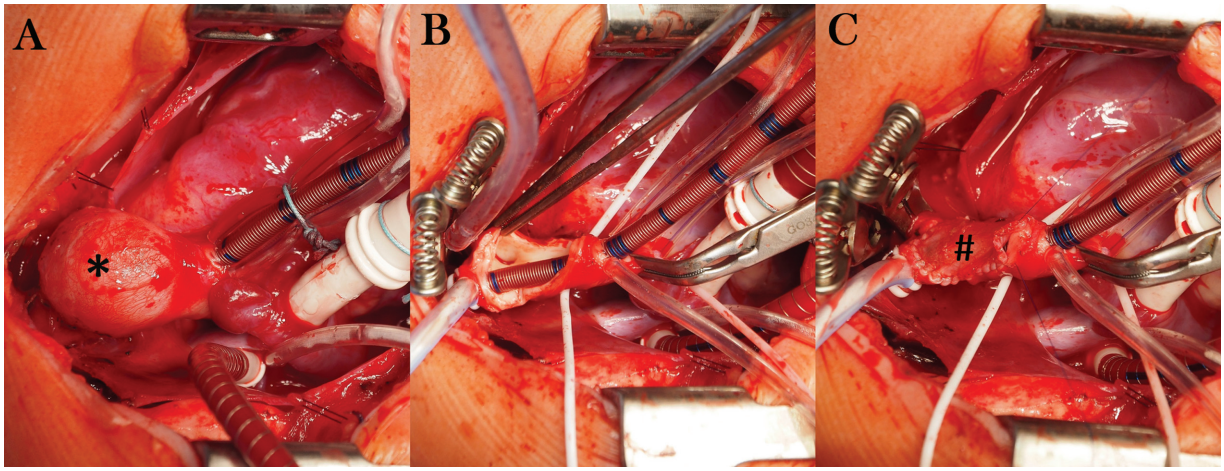

Fig. 2 Intraoperative photos of the situs from the surgeon's view. (**A**) (*) indicates the large saccular aneurysm of the proximal aortic arch. (**B**) The aneurysm tissue was completely resected. (**C**) The aorta was reconstructed with pericardial patch. (#) indicates the pericardial patch.

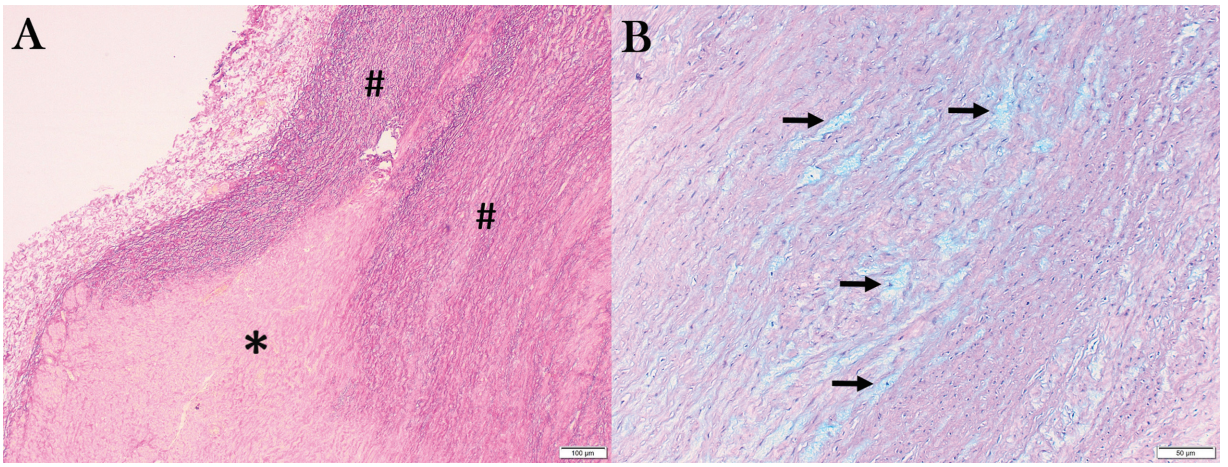

Fig. 3 Histopathology of aortic wall resected revealed partial loss of elastic fibers (**A**) Elastica van Gieson staining, ×20 magnification, (#) indicates elastic fibers, (*) indicates a loss of fibers, and deposition of mucopolysaccharides. (**B**) Alcian blue staining, ×100 magnification, arrows indicate deposits of mucopolysaccharides in the tunica media.

vascular diseases. As evidenced by our case, early diagnosis, particularly in the absence of symptoms, together with close interdisciplinary cooperation, were essential factors for a successful clinical course. Diagnostic tools, such as echocardiography and multidetector computed tomography angiography, are the gold standard in accurately identifying such disorders.

Diagnostics and approach for these patients can be even more difficult in cases of idiopathic disorders, as in our case. Usually, aneurysms' disorders are associated with genetic connective tissues abnormalities, resulting in the degeneration of the aortic wall and, subsequently, dilatation and aneurysm formation.[6] These are caused by degeneration of the median layer of the aorta and are usually detected later in young adulthood. The laboratory evaluation of our patient revealed no inflammatory markers indicating vasculitis. The absence of a positive family history, any maternal risk factors,

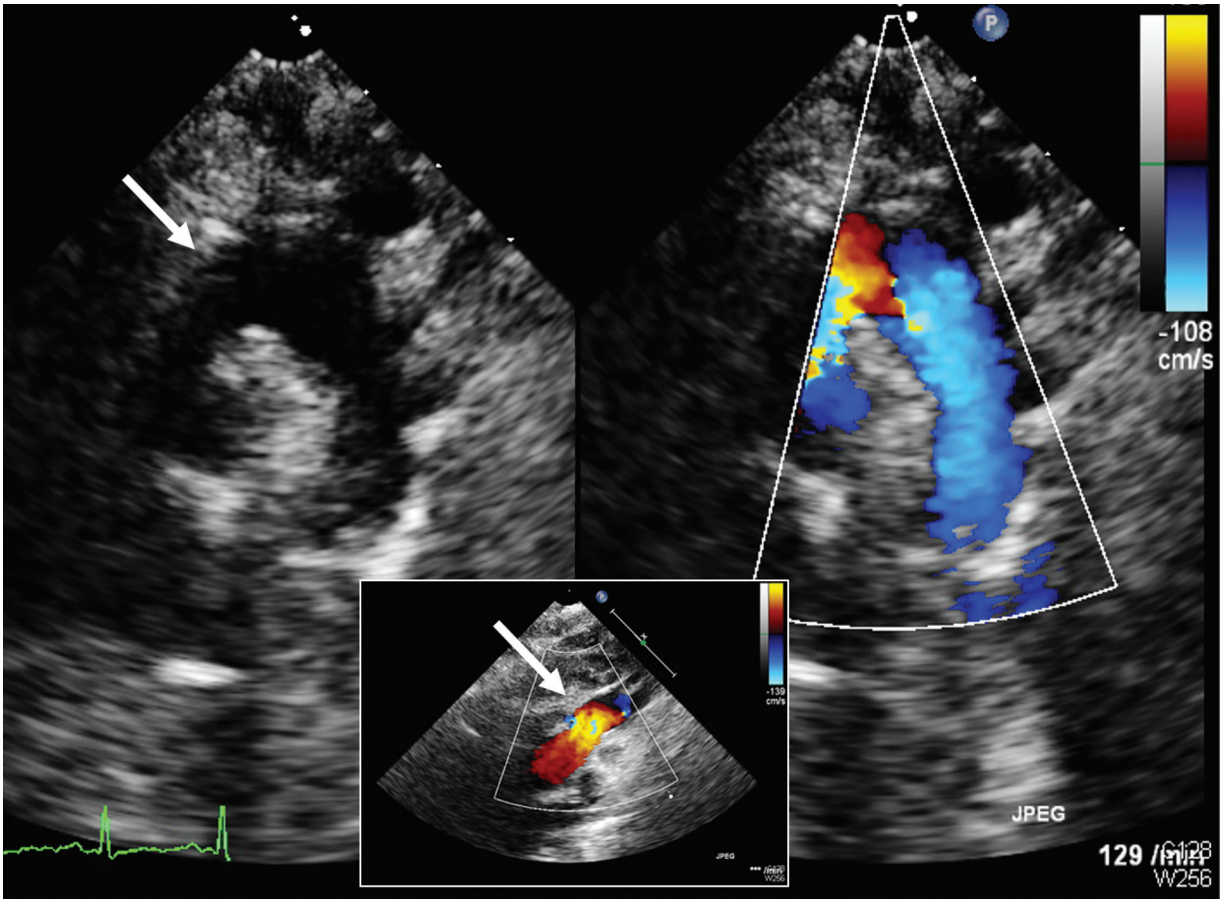

Fig. 4 Follow-up postoperative transthoracic echocardiographic image demonstrated the successful result of the aneurysm resection and repair of the aorta. The arrow and additional small image shows the area of pericardial patch in the reconstructed aorta with laminal blood flow.

or a pathological course in pregnancy make the idiopathic etiology in this case very likely.

Another challenging aspect in this case is the dearth of clear guidelines or recommendations for the treatment of aortic aneurysm in infants. The guidelines for adult patients with aortic aneurysm are unlikely to be applicable for pediatric or infant patients. There is also a lack of relevant information in the clinical recommendations for pediatric cardiology compared with the well-designed clinical practice guidelines for the management of visceral artery aneurysms.[7] We opted for resection of the aneurysm as opposed to observation, based on the dimensions, aortic arch localization, and progressive growth of aneurysm with the corresponding risk of rupture or thrombus formation with the potential for thromboembolic events.

Despite recent advances and the rapid development of endovascular treatment technology with reports of first successful embolization procedures for aortic aneurysms in newborns,[4] surgical treatment remains the standard of care in pediatric patients. The use of autologous materials for aortic repair, well-established protective strategies in neonatal surgery with extracorporeal circulation, and the possibility of histological examination of the resected obtained during the operation are instrumental to the success of the surgical approach. This is also evidenced by the uneventful postoperative period and early follow-up results observed in our case.

Conclusion

In conclusion, our case presented one of the rare reports documented in the literature requiring surgical resection of an idiopathic saccular aortic arch aneurysm in an infant.

Conflict of Interest

The authors declared no conflicts of interest with respect to the authorship and publication of this article.

Acknowledgments

We acknowledge support by the German Research Foundation (DFG) and the Open Access Publication Fund of Medical School (MHH). The authors also thank Nina McGuinness for editorial assistance.

References

1 Deshpande S, Alazraki A, Khoshnam N, et al. Four new cases of pediatric thoracic aortic aneurysm (TAA) with review of the molecular genetic basis, utilizing the newly published consensus nomenclature. Cardiovasc Pathol 2017;31:34–40
2 Roy N, Azakiea A, Moon-Grady AJ, Blurton DJ, Karl TR. Mycotic aneurysm of the descending thoracic aorta in a 2-kg neonate. Ann Thorac Surg 2005;80(02):726–729
3 Le-Nguyen A, Joharifard S, Côté G, Borsuk D, Ghali R, Lallier M. Neonatal microsurgical repair of a congenital abdominal aortic aneurysm with a cadaveric graft. European J Pediatr Surg Rep 2021;9(01):e23–e27
4 Ferrara SL, Kinney TB, Hall LD. Endovascular treatment of a congenital thoracic aortic aneurysm in a premature newborn. J Vasc Interv Radiol 2012;23(10):1330–1334
5 Tireli E, Polat TB, Oztas DM, Mamur Y, Omeroglu RE, Ugurlucan M. Giant Aneurysm of the ascending aorta requiring emergency repair in a newborn baby. Ann Thorac Surg 2019;107(02): e107–e109
6 von Kodolitsch Y, Kutsche K. Genetic diagnostics of inherited aortic diseases : medical strategy analysis. Herz 2017;42(05): 459–467
7 Chaer RA, Abularrage CJ, Coleman DM, et al. The Society for Vascular Surgery clinical practice guidelines on the management of visceral aneurysms. J Vasc Surg 2020;72(1S):3S–39S