



Hybrid Arch Repair with Supra-Aortic Debranching and Using Castor Stent-Graft

Xijie Gao¹ Guohong Liu² Jun Lu³ Jianbo Zhao⁴

¹Department of Interventional Radiology, The People's Hospital of Wanning County, Hainan, China

²The People's Hospital of Wanning County, Hainan, China

³Department of Cardiovascular Surgery, Southern Medical University Nanfang Hospital, Guangzhou, Guangdong, China

⁴Southern Medical University Nanfang Hospital, Guangzhou, Guangdong, China

Address for correspondence Jianbo Zhao, Southern Medical University Nanfang Hospital, No.1838 Guangzhoudadaobei Rd, Guangzhou 510515, China

(e-mail: zhaojianbohgl@163.com; gaioxijie2005@126.com).

Thorac Cardiovasc Surg Rep 2022;11:e30–e32.

Abstract

Keywords

- ▶ aortic disease
- ▶ aneurysm
- ▶ endovascular procedures/stents
- ▶ except PCI

Background The management of aortic lesions involving the aortic arch in patients who cannot tolerate thoracotomy is a challenge.

Case Description A 32-year-old woman who underwent a giant aneurysm at the proximal end of the descending aorta with significant vascular wall calcification. The patient underwent Castor single-branched stent-grafting in the brachiocephalic trunk combined with surgical supra-aortic debranching, which avoided surgical aortic arch replacement and stent fenestration reopening. The patient was followed up for 9 months, and surgery-related complications were not observed.

Conclusion Hybrid arch repair with supra-aortic debranching and using Castor single-branched stent can be used to treat aortic lesions involving the aortic arch.

Introduction

Application of the Castor single-branched stent-graft in thoracic endovascular procedure aortic repair partially overcomes the limitations of the earlier left subclavian artery reconstruction.^{1,2} Castor single-branched stent-graft has been approved by the Chinese Food and Drug Administration and it was the first domestic unibody branch stent-graft. Our department used the Castor single-branched stent-graft in the brachiocephalic trunk combined with surgical supra-aortic debranching to treat a patient with giant descending aortic aneurysm, which avoided surgical aortic arch replacement and stent fenestration reopening.

Case Description

A 32-year-old female who underwent kidney transplantation 18 years ago and started hemodialysis in 2008. On May 23, 2020, the patient was admitted to hospital due to poor flow of the long-term dialysis catheter in the right internal jugular vein. Laboratory examinations showed that the patient had a urea level of 31.6 mmol/L, creatinine of 1249 μmol/L, and serum phosphorus of 2.78 mmol/L. Computed tomography angiography (CTA) of the aorta revealed a fusiform dilatation at the descending part of the aortic arch, with a maximum diameter of 71 mm, which was consistent with an aortic aneurysm (▶ **Fig. 1**).

received

October 3, 2021

accepted after revision

March 22, 2022

DOI <https://doi.org/>

10.1055/s-0042-1750427.

ISSN 2194-7635.

© 2022. The Author(s).

This is an open access article published by Thieme under the terms of the Creative Commons Attribution-NonDerivative-NonCommercial-License, permitting copying and reproduction so long as the original work is given appropriate credit. Contents may not be used for commercial purposes, or adapted, remixed, transformed or built upon. (<https://creativecommons.org/licenses/by-nc-nd/4.0/>)

Georg Thieme Verlag KG, Rüdigerstraße 14, 70469 Stuttgart, Germany

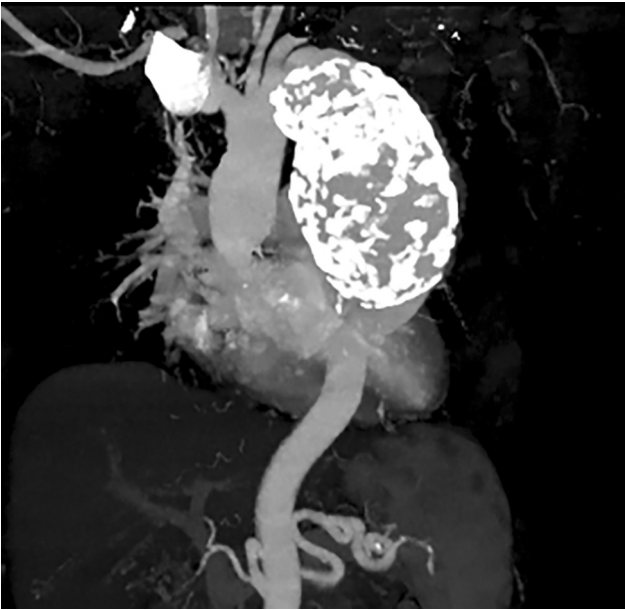


Fig. 1 Computed tomography angiography reconstruction showed a giant aneurysm of the descending aorta with obvious calcification at the aneurysm wall.

CTA showed that the aneurysm was 13 mm from the opening of the left subclavian artery and 19 mm from the brachiocephalic artery trunk. Because of our patient with severe anemia and cardiac insufficiency due to long-term hypertension, she could not tolerate aortic replacement surgery. The patient, therefore, underwent staged hybrid surgery. First, right common carotid artery–left common carotid artery–left axillary artery artificial vascular bypass was performed by the cardiology department, the proximal left common carotid artery was ligated, and a temporary blocking rubber tube was placed at the proximal left axillary artery to prevent blood flow, which could lead to slowing down of blood flow inside the artificial blood vessel and promote thrombosis.

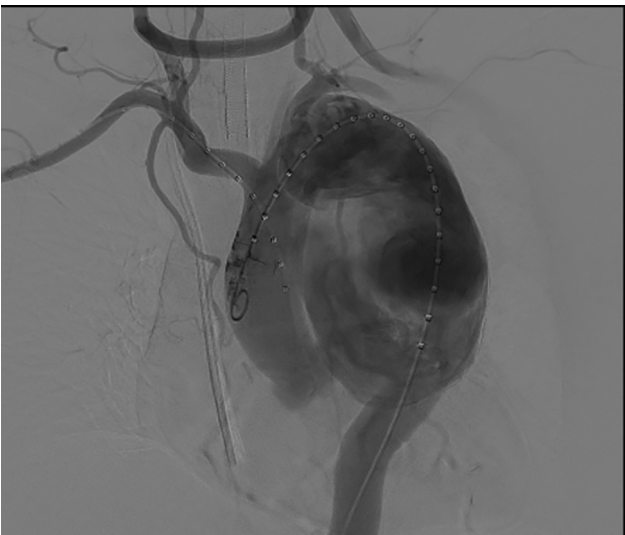


Fig. 2 Good blood flow was found in the artificial blood vessel after surgical supra-aortic bypass.

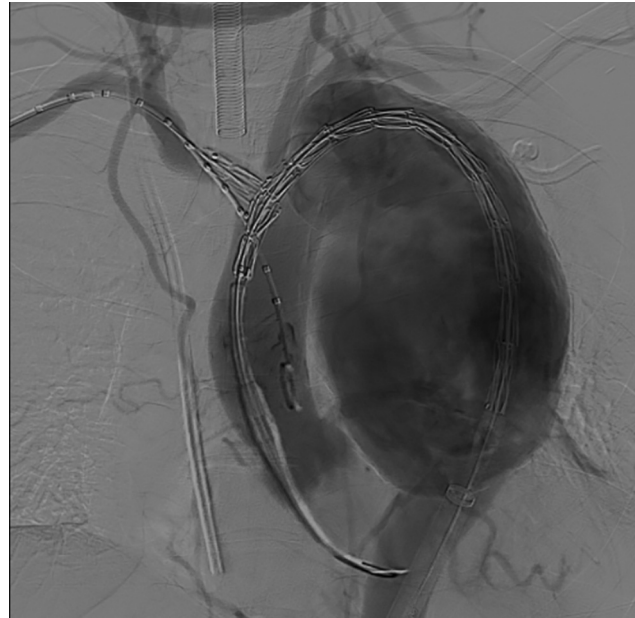


Fig. 3 During Castor stent implantation, the stent branch was introduced into the brachiocephalic artery.

Then, the angiography showed that the left common carotid artery and axillary artery were supplied with blood from the brachiocephalic trunk through the artificial blood vessel, with good blood flow (–**Fig. 2**). The right brachial artery and left femoral artery were punctured, and the catheter sheath was inserted. The guide catheter was led out of the catheter sheath from the right brachial artery to the left femoral artery. An ultra-hard guide wire was introduced through the catheter. A 34-mm–28-mm–200-mm Castor single-branched stent-graft (Castor, Shanghai Microport Endovascular MedTech, Shanghai, China) was introduced along the guide wire, and the stent branch (diameter 12 mm) was introduced into the brachiocephalic trunk (–**Fig. 3**). The patient underwent a second angiography to confirm that the location of the stent was satisfactory. The stent-graft and the branch stent were released rapidly after approximately 70 seconds of cerebral ischemia. Then, a 30-mm–24-mm–160-mm straight tubular aortic stent-graft (Hercules, Shanghai Microport Endovascular MedTech, Shanghai, China) was introduced to connect the main stent. The original blocking rubber tube at the proximal end of the left axillary artery was removed. The patient underwent angiography again, which showed that the thoracic aorta stent-graft was attached tightly, the blood flow in the supra-arch vessel was good, and a small amount of contrast agent regurgitation was detected in the left vertebral artery (–**Fig. 4**). The intraoperative fluoroscopy duration was approximately 28 minutes, with an X-ray dose of 860 mGy, which were both lower than those for triple fenestration of the aortic arch stent in our hospital (average fluoroscopy duration approximately 43.9 minutes, and X-ray dose 1,251 mGy).

The patient recovered well, with no complications, and was discharged 5 days after the surgery. The patient continued the dialysis treatment at a local hospital, and no obvious

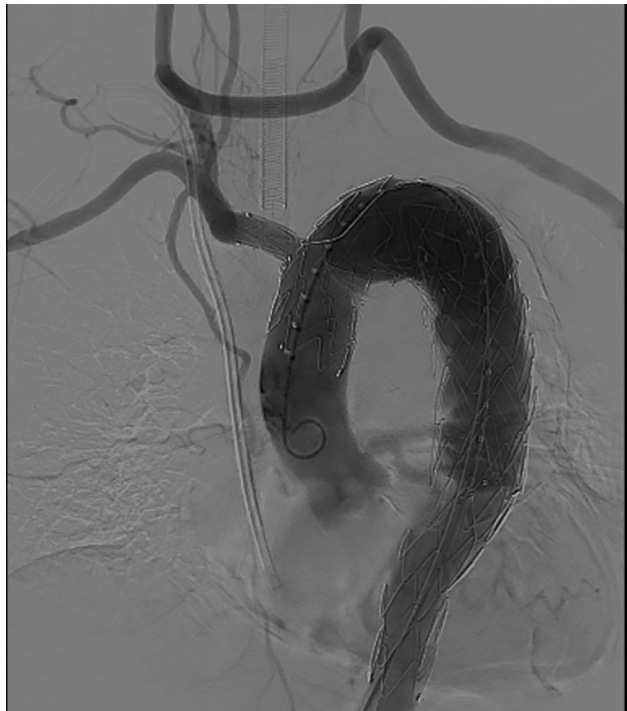

Fig. 4 Postoperative angiography showed that the aneurysm cavity had disappeared. There was no obvious endoleak, and the supra-arterial blood flow was smooth.

discomfort was noted during the telephone follow-up. The patient died of cerebral hemorrhage due to dialysis on February 1, 2021.

Discussion and Conclusion

In this case, if the patient had been subjected to surgical thoracotomy and undergone reconstruction of the aortic arch under selective cerebral perfusion protection, she would have needed deep hypothermia, extracorporeal circulation, and massive blood transfusion during the operation, and the postoperative recovery time in the intensive care unit would have been long.³ A previous study⁴ has shown that hybrid surgery can be performed for patients with Stanford type B aortic disease who have an anchoring area that is too small and cannot tolerate hypothermic circulatory arrest. We decided to use an aortic stent-graft to isolate the thoracic aneurysm combined with supra-arch vascular bypass, which was tolerated by the patient and minimized her cerebral ischemia time. The use of a traditional aortic stent-graft will inevitably be combined with fenestration and/or a chimney technique that will destroy the integrity and stability of the stent.⁵ Therefore, we decided to use the Castor branched stent-graft. After preoperative CTA measurements combined with a Castor stent model and placing the stent branch in the right brachiocephalic artery, in combination with supra-arch artificial vascular bypass, and this approach achieved satisfactory treatment effects.

A review of the patient's medical record showed that since 2002 at in the past 18 years, her long-term serum inorganic

phosphorus fluctuated between 2.0 and 2.78 mmol/L (normal adult blood phosphorus concentration is 0.97–1.61 mmol/L). The serum phosphorus level in patients with chronic renal diseases is 0.323 mmol/L more than that in healthy people, and their incidence of thoracic aortic calcification is approximately 33%.⁶ Deposition of calcium salt in the media of the aorta leads to a decrease in the elasticity of the aorta, which gradually expands under pressure to form an aneurysm.

Single-branched stent-grafting avoids any chimney, fenestration, or other such techniques and maintains the integrity and stability of the stent. However, the clinical application window is short, and there have been reports of complications using this technique.⁷ Its long-term effects need to be further verified.

The Castor branched aortic stent-graft system has obtained the regulatory approval from China Food and Drug Administration, formally entering the Chinese market since June 2017.

Castor Registration Certificate

Disclaimer

Castor single-branched stent-graft (Microport Medical, Shanghai, China) has been approved by the Chinese Food and Drug Administration and was the first domestic unibody branch stent-graft. Informed consent was obtained from the patient before the surgery.

Conflicts of Interest

The authors have no conflicts of interest to declare.

Acknowledgments

None.

References

- Jing Z, Lu Q, Feng J, et al. Endovascular repair of aortic dissection involving the left subclavian artery by castor stent graft: a multicentre prospective trial. *Eur J Vasc Endovasc Surg* 2020;60(06):854–861
- Fang C, Wang C, Liu K, Pang X. Early outcomes of left subclavian artery revascularization using castor single-branched stent-graft in the treatment of type B aortic dissection or intramural hematoma. *Ann Thorac Cardiovasc Surg* 2021;27(04):251–259
- Uchida K, Minami T, Cho T, et al. Results of ascending aortic and arch replacement for type A aortic dissection. *J Thorac Cardiovasc Surg.* 2020;S0022–5223(20):30531–6. Doi: 10.1016/j.jtcvs.2020.02.087
- Klocker J, Koell A, Erlmeier M, Goebel G, Jäschke W, Fraedrich G. Ischemia and functional status of the left arm and quality of life after left subclavian artery coverage during stent grafting of thoracic aortic diseases. *J Vasc Surg* 2014;60(01):64–69
- Mangialardi N, Serrao E, Kasemi H, Alberti V, Fazzini S, Ronchey S. Chimney technique for aortic arch pathologies: an 11-year single-center experience. *J Endovasc Ther* 2014;21(02):312–323
- Adeney KL, Siscovick DS, Ix JH, et al. Association of serum phosphate with vascular and valvular calcification in moderate CKD. *J Am Soc Nephrol* 2009;20(02):381–387
- Huang H, Jiao Y, Zhang Y, et al. Implantation of unibody single-branched stent graft for patients with type B aortic dissections involving the left subclavian artery: 1-year follow-up outcomes. *Cardiovasc Intervent Radiol* 2017;40(11):1678–1686