



Triple-Arterial Cannulation Approach for Whole-Body Perfusion in Infant Hypoplastic Aortic Arch and Coarctation Repair

Markus Liebrich¹ Marco Schweder¹ Joerg Seeburger¹ Vladimir Voth¹

¹Departement of Cardiac Surgery, Sana Herzchirurgie Stuttgart GmbH, Stuttgart, Baden-Württemberg, Germany

Address for correspondence Markus Liebrich, MD, Departement of Cardiac Surgery, Sana Cardiac Surgery Stuttgart, Herdweg 2, Stuttgart 70174, Germany (e-mail: markus.liebrich@gmx.net).

Thorac Cardiovasc Surg Rep 2022;11:e47–e49.

Abstract

Keywords

- ▶ hypoplastic transverse aortic arch
- ▶ beating heart
- ▶ cerebro-myocardial perfusion
- ▶ visceral perfusion

Organ and end-organ protection in aortic arch surgery represents a substantial challenge, especially in infants. Selective antegrade cerebral perfusion has been reported to improve organ function during this procedure. Visceral perfusion can be optimized by cannulation of the descending aorta during infant aortic arch surgery, leading to a decrease in end organ damage. However, it is associated with extensive surgical manipulation and subsequent risk of major vessel and potential organ damage. In this report, we describe a technique for distal body perfusion in an infant with hypoplastic aortic arch and isthmus stenosis by ultrasound-guided cannulation of the femoral artery using an intra-arterial vascular sheath establishing whole-body perfusion by triple cannulation.

Introduction

Organ and end-organ protection (cerebral, myocardial, and visceral) in aortic arch surgery represents a substantial challenge, especially in infants. Complex aortic surgery including deep hypothermic cardio-circulatory arrest is known to significantly increase operative morbidity.¹ In particular, selective antegrade cerebral perfusion has been reported to improve organ function and patient outcomes. Visceral perfusion can be optimized by cannulation of the descending aorta during infant aortic arch surgery.² Previous research has demonstrated that optimized perfusion techniques of the brain and body by cannulation of the descending aorta during infant and congenital aortic arch surgery can be used to guarantee visceral and renal perfusion.^{3–8} This

leads to a decrease in end organ damage. However, it is associated with extensive surgical manipulation and subsequent risk of major vessel damage, potential organ damage, and significantly increased operative times.^{6,8} To reduce cannulation of the descending aorta-associated risk factors, we induced peripheral, percutaneous femoral cannulation. This operative instruction tutorial presents a safe and simple technique for intrathoracic and peripheral cannulation to establish whole-body perfusion during complex aortic arch surgery in infants.

Case Description

The patient is a 16-months-old, 9 kg female infant with hypoplastic aortic arch and an aortic isthmus stenosis. Initial symptom was coughing. Examination revealed a systolic heart murmur. Indirect blood pressure measurements (Riva-Rocci) detected significant discrepancy with 150/90 mm Hg on the upper and no measurable blood pressure on the lower

Presented at the 49th Annual Meeting of the German Society for Thoracic and Cardiovascular Surgery, Wiesbaden, Germany, 29th February to 3rd March 2020

received
December 12, 2021
accepted after revision
April 4, 2022

DOI <https://doi.org/10.1055/s-0042-1750428>.
ISSN 2194-7635.

© 2022. The Author(s).

This is an open access article published by Thieme under the terms of the Creative Commons Attribution-NonDerivative-NonCommercial-License, permitting copying and reproduction so long as the original work is given appropriate credit. Contents may not be used for commercial purposes, or adapted, remixed, transformed or built upon. (<https://creativecommons.org/licenses/by-nc-nd/4.0/>)

Georg Thieme Verlag KG, Rüdigerstraße 14, 70469 Stuttgart, Germany

extremities. Transthoracic echocardiography revealed no cardiac pathology; however, computer tomography confirmed the presence of a hypoplastic transverse aortic arch and aortic isthmus stenosis and thus served as an indication for aortic arch surgery (►Video 1).

Video 1

Preoperative CT scan. Online content including video sequences viewable at: <https://www.thieme-connect.com/products/ejournals/html/10.1055/s-0042-1750428>.

Surgical Steps

1. *Percutaneous puncture of the femoral artery for distal perfusion:* After induction of general anesthesia, the arterial sheath was percutaneously introduced intra-arterially under direct visualization of the femoral artery by the ultrasound-guided cannulation technique. The size of the arterial sheath was determined according to the height and weight of the infant (►Video 2).
2. *Aortic arch preparation:* Preparation of the hypoplastic aortic arch and aortic isthmus stenosis was done with the supra-aortic vessels.
3. *Initial set-up of extracorporeal circulation:* Standard arterial and bicaval cannulation were established. Distal perfusion via the vascular sheath was established using a separate roller pump (►Fig. 1).
4. *Ligation and transection of the arterial duct:* Intersection of the arterial duct took place.
5. *Preparation of the hypoplastic aortic arch and isthmus stenosis:* Completion of the arch preparation and preservation of the phrenic nerve.
6. *Resected part of the aortic isthmus stenosis:* Stenotic segment of the proximal descending aorta (aortic isthmus stenosis) after excision.
7. *Situs before end-to-end anastomosis between proximal aortic arch and descending aorta:* Cross-clamping of the descending aorta and ascending aorta between the innominate artery and left common carotid artery and the previously resected aortic isthmus stenosis.
8. *End-to-end anastomosis:* End-to-end anastomosis between the native proximal descending aorta and the proximal aortic arch.
9. *Sewing of the patch:* Implementation of the patch by 6–0 Prolene running suture.
10. *Establishing the cerebro-myocardial perfusion:* By advancing the arterial cannula into the innominate artery and snaring with a silk suture positioning of a separate cannula (needle vent) in the proximal ascending aorta follows for separated cerebro-myocardial perfusion under cross-clamping of the ascending aorta distal to the needle vent. The cerebro-myocardial perfusion is established.
11. *Electrocardiogram (ECG) monitoring during cerebral, myocardial, and distal perfusion:* Continuous ECG-monitoring occurred during beating heart aortic arch reconstruction. Pressure monitoring in the right radial and femoral artery was done during triple-arterial cannulation with selective cerebral, myocardial, and additional distal perfusion via the femoral artery.
12. *Repositioning of the arterial cannula:* Aortic cannula is repositioned from the innominate artery into the ascending aorta and full body perfusion re-established.
13. *Situs after de-cannulation:* Situs established after aortic arch reconstruction with temporary pacemaker wires in place.

Video 2

Operative technique. Online content including video sequences viewable at: <https://www.thieme-connect.com/products/ejournals/html/10.1055/s-0042-1750428>.

Perfusion Management

Triple arterial perfusion was established by a combined flow- and pressure-controlled perfusion regime. Cerebral and myocardial perfusion were established by advancing the arterial cannula into the innominate artery and snaring with a silk suture (cerebral perfusion) and positioning of a separate cannula (needle vent) in the proximal ascending aorta under cross-clamping of the ascending aorta distal to the needle vent (myocardial perfusion) by one roller pump in a flow-controlled manner (►Video 2, Section 10). Changes in near-infrared spectroscopy or ECG resulted in an elevated flow rate/per minute. A separate roller pump and pressure measurement were instituted for distal perfusion via the right femoral artery—resulting in a pressure-controlled perfusion management (►Fig. 1). The flow rate was 150 to 250 mL/min with a pressure rate between 220 and 280 mm Hg. In this case, we used a 5F sheath (Terumo Deutschland GmbH, Eschborn, Germany). The sizes of the vascular sheaths (Terumo Deutschland GmbH, Eschborn, Germany) implanted ranged from 3F for children between 2 and 3.5 kg, a 4F vascular sheath was implanted in children between 3.6 and 5.5 kg, and a 5F sheath was utilized in children weighing between 5.5 and 9 kg.

Outcome

Triple-arterial cannulation for organ and end-organ perfusion was accomplished as presented. The perioperative course of the patient showed no significant increase in creatinine, liver enzymes, or lactate levels, and furthermore no signs of acute kidney injury, limb malperfusion, aggravation of myocardial function, or femoral vessel injury were detected. The intensive care unit stay was 24 hours and the child was discharged without complications on postoperative day 7.

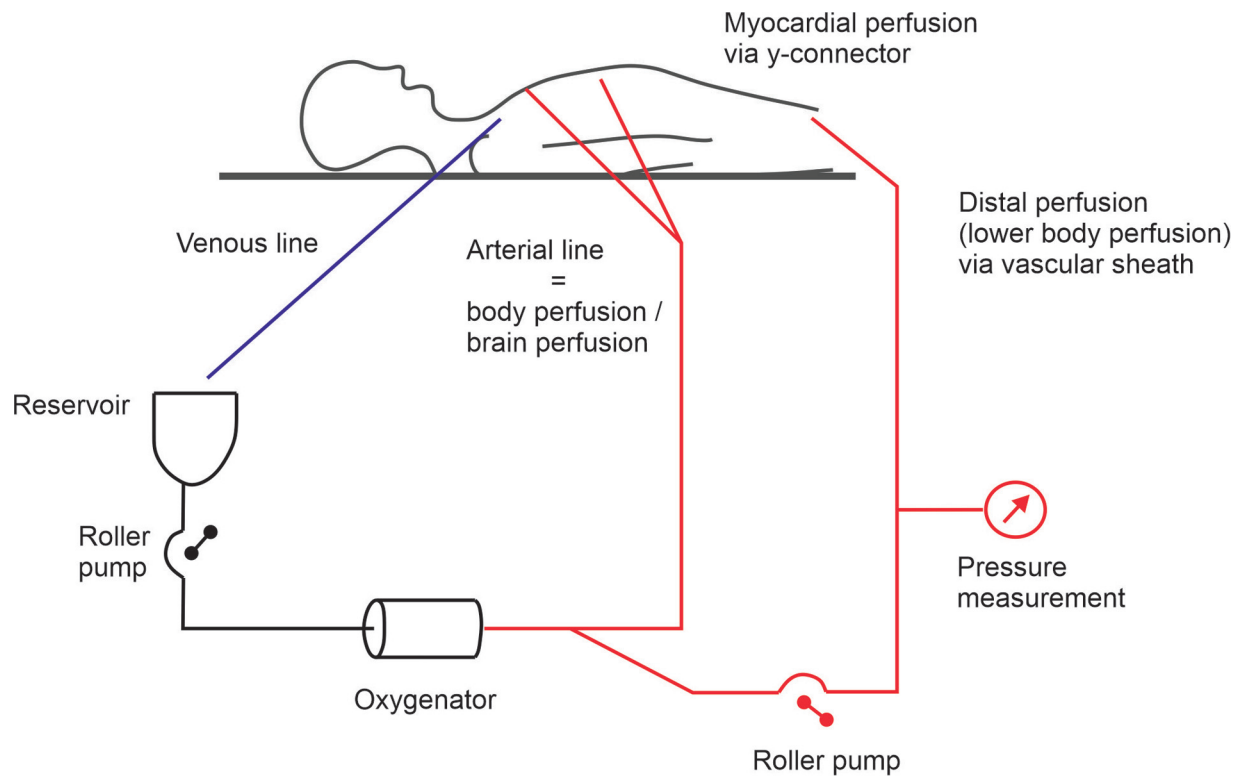


Fig. 1 Schematic drawing of extracorporeal circulation set-up during “beating heart” aortic arch reconstruction.

Discussion

Whole-body perfusion using triple-arterial cannulation approach (TACA) is feasible in infant aortic arch reconstruction. This approach enables continuous organ and end-organ perfusion and thus represents significant potential advantages compared with antegrade cerebral perfusion, arrested heart technique, and deep hypothermia without distal body perfusion. As intra- and perioperative results detected lower levels of ischemic end organ markers and shorter ventilation times compared with the conventional approach, it has yet to be determined whether this translates into improved clinical outcomes in a larger patient cohort.⁸

Conclusion

TACA enables organ and end-organ perfusion in infants undergoing complex aortic arch reconstruction.

Conflict of interest

None declared.

Acknowledgments

The authors are indebted to improving English grammar and style to Scott Milligan, PhD.

References

- 1 Newburger JW, Jonas RA, Wernovsky G, et al. A comparison of the perioperative neurologic effects of hypothermic circulatory arrest versus low-flow cardiopulmonary bypass in infant heart surgery. *N Engl J Med* 1993;329(15):1057–1064
- 2 Asou T, Kado H, Imoto Y, et al. Selective cerebral perfusion technique during aortic arch repair in neonates. *Ann Thorac Surg* 1996;61(05):1546–1548
- 3 Gil-Jaurena JM, González-López MT, Pita A, Pérez-Caballero R, Hervías M, Blanco D. Beating-heart aortic arch surgery in neonates and infants. *Interact Cardiovasc Thorac Surg* 2018;27(04):586–590
- 4 Hoxha S, Abbasciano RG, Sandrini C, et al. Selective cerebro-myocardial perfusion in complex neonatal aortic arch pathology: midterm results. *Artif Organs* 2018;42(04):457–463
- 5 Boburg RS, Rosenberger P, Kling S, Jost W, Schlensak C, Magunia H. Selective lower body perfusion during aortic arch surgery in neonates and small children. *Perfusion* 2020;35(07):621–625
- 6 Hammel JM, Deptula JJ, Karamlou T, Wedemeyer E, Abdullah I, Duncan KF. Newborn aortic arch reconstruction with descending aortic cannulation improves postoperative renal function. *Ann Thorac Surg* 2013;96(05):1721–1726, discussion 1726
- 7 Janssen C, Kellermann S, Münch F, Purbojo A, Cesnjevar RA, Rüffer A. Myocardial protection during aortic arch repair in a piglet model: beating heart technique compared with crystalloid cardioplegia. *Ann Thorac Surg* 2015;100(05):1758–1766
- 8 Cesnjevar RA, Purbojo A, Muench F, Juengert J, Rueffer A. Goal-directed-perfusion in neonatal aortic arch surgery. *Transl Pediatr* 2016;5(03):134–141