



# Catheter Lock Anchor Technique for Placement of Retrogradely Tunneled Implantable Ports

Dayananda Lingegowda<sup>1</sup> Bharat Gupta<sup>1</sup> Anisha Gehani<sup>1</sup> Saugata Sen<sup>1</sup> Priya Ghosh<sup>1</sup>

<sup>1</sup>Department of Radiology, Tata Medical Center, Kolkata, West Bengal, India

Address for correspondence Dayananda Lingegowda, MBBS, DNB, PDCC, Department of Radiology, Tata Medical Center, 14 Arterial Road, Newtown, Kolkata -700160, West Bengal, India (e-mail: dayanandal@gmail.com).

J Clin Interv Radiol ISVIR 2023;7:3–7.

## Abstract

**Purpose** Groshong valved catheters require retrograde tunneling and a port chamber needs to be attached to the catheter after trimming. During this process, working space constraints are generally faced by operators. We describe a novel technique to improve the comfort of the operator while working in a constrained space.

**Materials and Methods** The port catheter with the distal valve is retrogradely tunneled and trimmed. Thread from absorbable surgical suture is used to anchor the catheter lock. Anchored catheter lock is comfortably pushed over the catheter into the subcutaneous tunnel without it being migrated proximally. Once the port chamber is attached to the catheter, the catheter lock is retrieved back and moved to the locking position. We retrospectively analyzed implantable ports for smoothness of curves and outcomes in terms of catheter days.

**Results** Technical success was achieved in all patients. There were no periprocedural complications. Clinical success was achieved in 27/29 cases. Early port removal was done due to infection in one patient and for nonhealing of the wound in one patient.

**Conclusion** The catheter lock anchor is a safe and useful technique for the placement of valved ports. A satisfactory catheter-nut angle can be achieved with this technique.

## Keywords

- ▶ Groshong valved catheter
- ▶ retrograde tunneling
- ▶ implantable port

## Introduction

Retrograde port placement technique is required for port catheters that have distal valve.<sup>1</sup> The advantages of retrograde tunneling include accurate tip placement and the distal valve has the theoretical advantage of an antireflux mechanism.<sup>2,3</sup> Post-tunneling, the catheter is attached to the port chamber and the port chamber is placed in a subcutaneous pocket, without any kinking or angulations. While trimming the catheter length, a balance needs to be achieved between the operator comfort and avoiding the kink due to excess length. Maintaining the optimum length of the catheter to prevent angulations or kinks is essential to mitigate

long-term port dysfunction.<sup>4,5</sup> This is technically challenging because of the restricted working space at the pocket site. We describe a modified technique that gives more comfort to the operator during attaching the port to the catheter.

## Materials and Methods

This is a retrospective analysis of implantable ports that were placed using this technique. All of the procedures were performed in an interventional radiology suite. Informed consent was obtained before the procedure. The laboratory parameters like an international normalized ratio of < 1.5

article published online  
July 14, 2022

DOI <https://doi.org/10.1055/s-0042-1751034>.  
ISSN 2457-0214.

© 2022. Indian Society of Vascular and Interventional Radiology. All rights reserved.

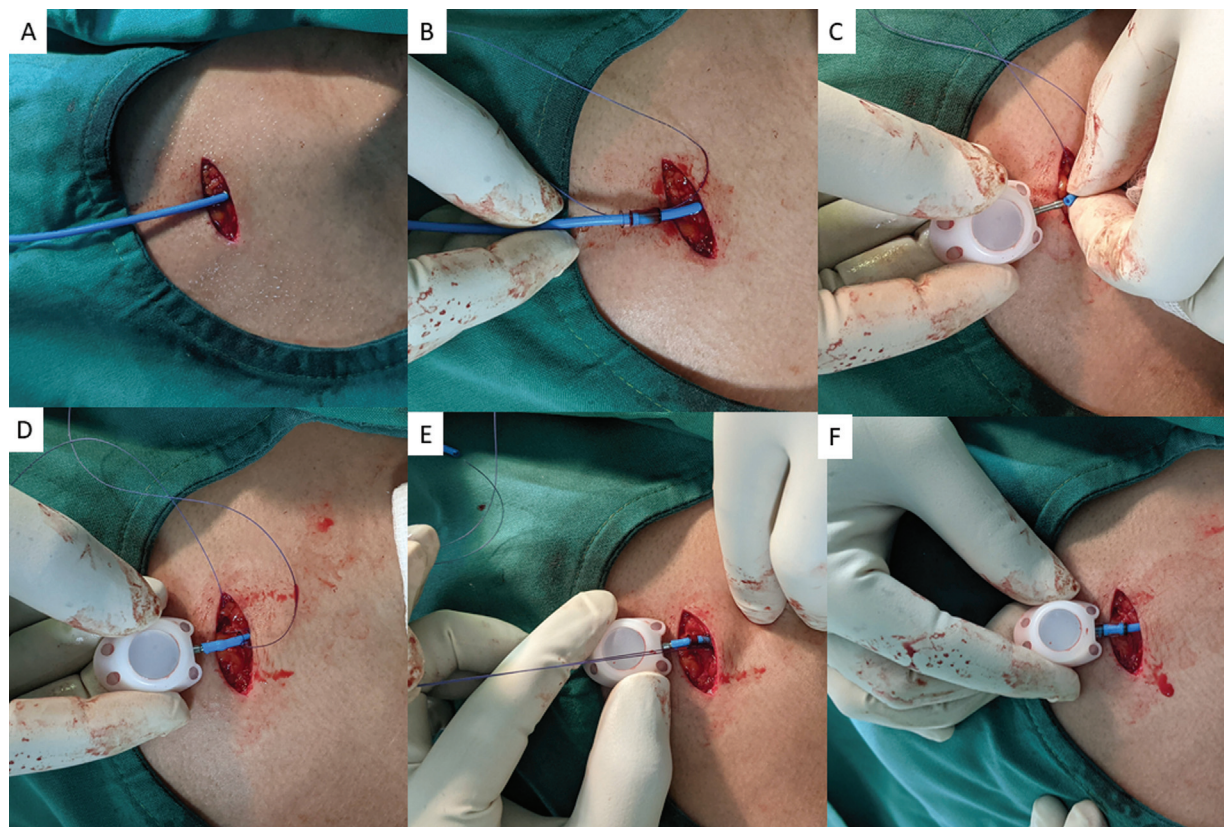
This is an open access article published by Thieme under the terms of the Creative Commons Attribution-NonDerivative-NonCommercial-License, permitting copying and reproduction so long as the original work is given appropriate credit. Contents may not be used for commercial purposes, or adapted, remixed, transformed or built upon. (<https://creativecommons.org/licenses/by-nc-nd/4.0/>)

Thieme Medical and Scientific Publishers Pvt. Ltd., A-12, 2nd Floor, Sector 2, Noida-201301 UP, India

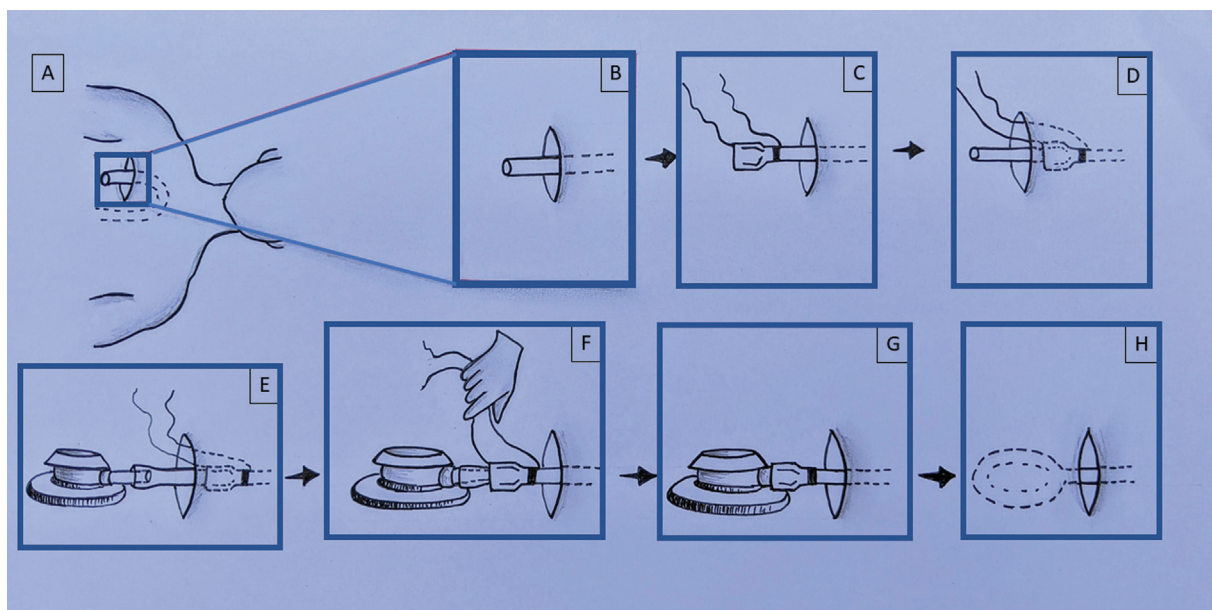
and a platelet count of more than 70,000 were desirable in all cases. Prophylactic antibiotics were administered 30 minutes before the procedure as per the hospital protocol. Groshong valved implantable port (X-port isp, BARD, single lumen venous catheter, 8F) was used in all cases. Undertaking all aseptic precautions, the internal jugular vein (IJV) was accessed under ultrasound (US) guidance. Right IJV was the preferred venous access. In cases where right chest wall malignancy or thrombosis/stenosis precluded right internal jugular access, left jugular access was selected. The patient is positioned supine with the head turned toward the opposite side of the catheter insertion site. A standard surgical scrub technique is performed in all cases. Skin is anesthetized with 1% lidocaine. IJV is punctured in its inferior part under real-time US guidance. After blood is aspirated to confirm the satisfactory position, a 0.035-inch guidewire was inserted into the right atrium then to inferior vena cava under fluoroscopic guidance. Adequate blunt dilation of the track was done before advancing the peel-apart sheath. Peel-away sheath and dilator assembly were advanced over the guidewire as a single unit. Once the peel-away sheath was adequately advanced, the dilator and J wire was removed. The port catheter with stiffener wire was then advanced over the peel-away sheath. The peel-away sheath is removed leaving the catheter in situ.

A subcutaneous pocket was created in the upper chest, preferably over the upper ribs. Pocket creation was made in the upper lateral quadrant to facilitate a smooth curve in the entire course of the port. Pocket size was made intentionally smaller so that the port would snugly fit into the pocket. Adequacy of the pocket size was checked by introducing the port inside the subcutaneous pocket. The port was removed from the subcutaneous pocket after checking the adequacy of the pocket size.

A subcutaneous tunnel was created from the port pocket to the venous access by advancing the metallic tunneler. The catheter stiffener is removed and the end of the catheter is attached to the tunneler barb with a twisting motion. Once the catheter end was mounted on the tunneler, the tunneler was pulled out at the port pocket side. Using fluoroscopy, the catheter was pulled back leaving the distal tip at the superior vena cava-right atrial junction. Excess catheter length on the tunneler side was trimmed. Suture thread (synthetic absorbable surgical suture, 3-0, 2 metrics, Vicryl, braided coated polyglactin 910 violets, Ethicon, Johnson & Johnson Private Limited) was passed into the catheter lock, and catheter lock was threaded over the catheter (► **Figs. 1 and 2**). The catheter lock was pushed back to the subcutaneous tunnel leaving adequate space for the attachment of the port. Port stem was advanced into the catheter after proper alignment. Once the



**Fig. 1** (A) Clinical radiograph of the catheter lock anchoring technique. Implantable port placement in progress. The tunneled port catheter is exiting from the chest wall incision. (B) The catheter lock is anchored with the suture and threaded over the catheter. (C) The port chamber is connected to the catheter after trimming. The catheter lock is pushed deep in the subcutaneous tunnel for creating better working space. (D) Position of catheter lock after the catheter is connected to port chamber. (E) The catheter lock is pulled out from the subcutaneous tunnel. (F) The suture thread is removed and the catheter lock is advanced into the final position.



**Fig. 2** (A) Pictorial illustration of the catheter lock anchoring technique. Implantable port placement in progress. The catheter is tunneled and trimmed. (B) Enlarged view of the operating area. (C) Catheter lock is anchored over the suture thread and mounted over the catheter. (D) The catheter lock is pushed back into the subcutaneous plane. (E) The catheter is connected to the port chamber stem. (F) The catheter lock is pulled back near the port chamber stem and the suture thread is removed. (G) The catheter lock is advanced to the final locking position. (H) The port chamber is pushed into the port pocket.

catheter tip is advanced up to midway of the port stem, the catheter lock was pulled back close to the stem using the suture loop. The thread loop was then removed after securing the lock. The catheter lock is advanced over the catheter toward the port and moved to the locked position. The port is now placed into a pocket created distal to incision. Stay sutures for the port base were not used.

Port functioning was assessed using a noncoring needle and a 10-mL syringe for free flow or leak. The port pocket was flushed with normal saline to clear out blood. Heparin lock solution was injected before removal of the noncoring needle. The incision site of the port chamber was closed in two layers using Ethicon Vicryl 2-0 absorbable sutures. The neck incision was closed with sutures.

A chest radiograph was taken to assess the catheter-nut angle. Catheter-nut angle is defined as the angle between the port stem to the catheter. Patients were followed up till the completion of treatment or till death with fully functional port (clinical success). Early port removal secondary to infection or port dysfunction were also noted, and if any, was also made note of (clinical failure)

**Post-port care:** The first dressing is changed after 48 hours and the second dressing is changed 1 week after the procedure. All patients were reviewed after 7 days of suture removal if not absorbed spontaneously. Nursing staff were advised to use a 10-mL syringe for flushing the port. The push and pause technique is recommended during flushing. After medication, flushing with 10 mL of normal saline and after every blood withdrawal flush with 20 mL of normal saline flush was suggested. When the port was not in use, a flush with 10 mL of normal saline every 4 weeks was suggested.

## Results

Total 29 patients underwent port placement with catheter lock anchor technique. Clinical success was achieved in 27/29 (93.1%) patients (i.e., port maintained till completion of treatment or death) (► **Table 1**). In one patient, the port was removed early after 30 days due to port site infection. In another patient, the port was removed due to the nonhealing of the wound. One patient reported withdrawal malfunction but was able to complete the treatment with no further intervention required. There were no periprocedural complications, and there have been no other late complications.

## Discussion

Many port-related complications can be avoided with good placement techniques.<sup>1</sup> The construction of gentle curves along the entire length of the implantable port and optimal tip positioning helps to prevent long-term problems. The port pocket should be made as small and as tight as possible to prevent movement of the port inside the patient.<sup>6-8</sup>

Trimming the length of the catheter is very important; otherwise, the excessive length may lead to kinks and abnormal catheter-nut angle.

When port pockets are made smaller, the working space during port placement is constrained especially for retrograde port placement, since the port chamber needs to be attached to the catheter toward the end of the procedure. The problem of limited space is more exaggerated after the lock is mounted over the stump of the catheter. The lock needs to be pushed into a subcutaneous tunnel to get an adequate working length to connect to the port chamber. There is

**Table 1** Summary of cases

|   |               |
|---|---------------|
| No of patients  | 29            |
| M: F  | 4:25          |
| Median  | 52 (21-75 yr) |
| <b>Diagnosis</b>  |               |
| Ca breast   | 17            |
| Ca ovary  | 2             |
| Ca lung   | 1             |
| Ca colon  | 5             |
| Ca pancreas   | 1             |
| Sarcoma   | 3             |
| <b>Site</b>   |               |
| Right IJV   | 27            |
| Left IJV  | 2             |
| <b>Catheter-nut angle</b>                                     |               |
| >170  | 29            |
| <170  | 0             |
| <b>Total catheter days</b>                                    | 12016         |
| <b>Average catheter days</b>                                  | 414 (11–1718) |
| <b>Patients died during follow up</b>                         | 4             |
| The patient completed treatment or maintained port till death | 27            |
| <b>Malfunction</b>  |               |
| Inability to draw blood samples                               | 1             |
| Inability to inject   | 0             |
| Complete Obstruction of the line                              | 0             |
| <b>Pinch-off syndrome</b>                                     | 0             |
| <b>Late catheter break-embolization</b>                       | 0             |
| <b>Dislocation</b>  | 0             |
| <b>Venous thrombosis</b>                                      | 0             |
| <b>Port infection</b>   |               |
| Cutaneous site infection                                      | 1             |
| Port-related bacteraemia plus pocket infection                | 0             |
| <b>Non-healing</b>  | 1             |
| <b>Leak</b>   | 0             |
| <b>Toddlers syndrome</b>                                      | 0             |

Abbreviations: Ca, cancer; IJV, internal jugular vein.

always the risk of migration and losing the catheter lock in the subcutaneous tunnel while working on attaching the port chamber to the catheter.

Our catheter lock anchor technique addresses this issue faced by operators during the placement of retrograde implantable ports. The lock which is anchored with suture thread can be pushed into the subcutaneous tunnel deeply to create working space for the port chamber attachment. This technique eliminates the fear of migration of lock deep inside the subcutaneous tunnel, during attachment of port chamber to the catheter in constrained space. Operators need not cut extra length to become comfortable during chamber attachment which may cause the abnormal catheter-nut angle.<sup>9</sup>

The catheter-nut angle in our series is below 170 degrees suggesting a smooth curve at the port chamber end.<sup>10</sup> In our series, it was possible to achieve this angle due to our

suture anchor technique. The suture anchor technique provides extra working space for port attachment, which otherwise requires extra catheter length. The extra length may cause the abnormal catheter-nut angle when the final port chamber is planted in a subcutaneous pocket. Because of the catheter lock technique, we never had to trim the extra length and did not encounter any kinks in our series. This modified technique is simple, cheap, and elegant.

Accurate placement of the catheter tip was achieved in all cases. No cases of leak, detachment, catheter damage, and toddler syndrome were noted in our series. One case of withdrawal dysfunction was noted, with maintained forward flow. This case was managed conservatively. One case of nonhealing of the wound was noted in an old patient. This was most likely due to patient-related comorbid factors and chemotherapy, rather than modified technique. She was treated with port removal and secondary suturing of the wound after refreshing wound edges.<sup>11</sup>

One case of infection was noted 1 month after the placement which resulted in port removal. We give prophylaxis intravenous antibiotics that are usually administered before the port placement.<sup>12</sup> Whenever possible chemotherapy is delayed for a week until the wound heals (7 days).<sup>13</sup> These might have contributed to good infection control in our series.

Open-ended catheters are generally preattached before antegrade tunneling. Hence, working space constraint is not a major issue with preattached open-ended catheters.

To the best of my knowledge, this technique has never been described in the literature.

## Conclusion

The catheter lock anchor technique is a safe and handy technique for the placement of the port requiring retrograde tunnelling. Excellent catheter-nut angle can be achieved with this technique.

### Ethical Approval

For this type of study formal consent is not required.

### Informed Consent

For this type of study informed consent is not required.

### Funding

This study was not supported by any funding.

### Conflict of Interest

None declared.

## References

- 1 Nishinari K, Wolosker N, Bernardi CV, et al. Totally implantable ports connected to valved catheters for chemotherapy: experience from 350 Groshong devices. *J Vasc Access* 2010;11:17–22
- 2 Davanzo WJ. Efficacy and safety of a retrograde tunnelled hemodialysis catheter: 6-month clinical experience with the Cannon Catheter chronic hemodialysis catheter. *J Vasc Access* 2005;6:38–44

- 3 Biffi R, Pittiruti M, Gillet JP, et al. Valved central venous catheter connected to subcutaneous port: a multicenter phase IV study based on a cohort of 50 oncology patients. *J Vasc Access* 2002; 3:147–153
- 4 Wu C-Y, Fu J-Y, Feng P-H, et al. Catheter fracture of intravenous ports and its management. *World J Surg* 2011;35(11):2403–2410
- 5 Wu C-Y, Hu H-C, Ko P-J, et al. Risk factors and possible mechanisms of superior vena cava intravenous port malfunction. *Ann Surg* 2012;255(05):971–975
- 6 Charles HW, Miguel T, Kovacs S, Gohari A, Arampulikan J, McCann JW. Chest port placement with use of the single-incision insertion technique. *J Vasc Interv Radiol* 2009;20(11):1464–1469
- 7 Mauro MA, Jaques PF. Radiologic placement of long-term central venous catheters: a review. *J Vasc Interv Radiol* 1993;4(01): 127–137
- 8 Simpson KR, Hovsepian DM, Picus D. Interventional radiologic placement of chest wall ports: results and complications in 161 consecutive placements. *J Vasc Interv Radiol* 1997;8(02): 189–195
- 9 Chou P-L, Fu J-Y, Cheng C-H, et al. Current port maintenance strategies are insufficient: View based on actual presentations of implanted ports. *Medicine (Baltimore)* 2019;98(44):e17757
- 10 Wu C-Y, Fu J-Y, Wu C-F, et al. Superior vena cava port catheter tip confirmation: quantified formula for intravascular catheter length versus anatomic landmark reference. *Ann Vasc Surg* 2019;60:193–202
- 11 Zawacki WJ, Walker TG, DeVasher E, et al. Wound dehiscence or failure to heal following venous access port placement in patients receiving bevacizumab therapy. *J Vasc Interv Radiol* 2009;20(05): 624–627, quiz 571
- 12 van de Wetering MD, van Woensel JBM. Prophylactic antibiotics for preventing early central venous catheter Gram positive infections in oncology patients. *Cochrane Database Syst Rev* 2003;(02): CD003295
- 13 Erinjeri JP, Fong AJ, Kemeny NE, Brown KT, Getrajdman GI, Solomon SB. Timing of administration of bevacizumab chemotherapy affects wound healing after chest wall port placement. *Cancer* 2011;117(06):1296–1301