



Compression of the Distal Common Bile Duct by Enlarged Inferior Pancreaticoduodenal Artery Branches in a Patient with Celiac Trunk Stenosis: A Case Report

Anıl Çolaklar¹ Diğdem Kuru Öz¹ Ayşe Erden¹

¹Department of Radiology, Ankara University School of Medicine, Ankara, Turkey

Address for correspondence Anıl Çolaklar, MD, Department of Radiology, Ankara University School of Medicine, Ankara 06230, Turkey (e-mail: anilcolaklar@gmail.com).

J Gastrointestinal Abdominal Radiol ISGAR 2023;6:58–61.

Abstract

Keywords

- ▶ common bile duct
- ▶ compression
- ▶ inferior pancreaticoduodenal artery
- ▶ magnetic cholangiopancreatography

Various benign and malignant pathologies/conditions can cause compression of the extrahepatic biliary system. Anatomical and/or topographic variations of the hepatic artery have long been recognized as a possible cause of the EBS compression. However, anatomical and/or topographic variations, other than the hepatic artery's, should also be considered during the evaluation of the EBS compression. We, herein, report a unique case of the distal common bile duct compression by tortuous and enlarged inferior pancreaticoduodenal artery branches due to severe stenosis of the celiac trunk orifice.

Introduction

Various benign and malignant pathologies/conditions can cause compression of the extrahepatic biliary system (EBS). Anatomical and topographic variations, especially those of vessels, are not infrequent in this region. Thus, anatomical and topographic variations should be given special consideration as a probable cause of the EBS compression, specifically in patients with no obvious etiology. Among these variations, the right hepatic artery was the first to be recognized as a possible cause of the EBS compression.¹ Hence, the authors proposed to name the condition as “right hepatic artery compression syndrome” in 1984.¹ Topographic variations in arterial anatomy neighboring EBS have been a matter of concern since then.

There is only one publication, of which we are aware, that describes the posterosuperior pancreaticoduodenal artery compressing the common bile duct (CBD).² To the best of our knowledge, this is the second case in the English literature where tortuous and enlarged inferior pancreaticoduodenal artery (IPdA) branches were suspected to result in impaired liver function tests.

Case Description

A 68-year-old man was referred to our abdominal imaging division for further diagnostic workup of impaired liver function tests. The patient did not have any specific symptoms on admission that could be attributed to the elevated liver function tests. He had a past medical history of

article published online
August 15, 2022

DOI <https://doi.org/10.1055/s-0042-1751254>.
ISSN 2581-9933.

© 2022. Indian Society of Gastrointestinal and Abdominal Radiology. All rights reserved.

This is an open access article published by Thieme under the terms of the Creative Commons Attribution-NonDerivative-NonCommercial-License, permitting copying and reproduction so long as the original work is given appropriate credit. Contents may not be used for commercial purposes, or adapted, remixed, transformed or built upon. (<https://creativecommons.org/licenses/by-nc-nd/4.0/>)

Thieme Medical and Scientific Publishers Pvt. Ltd., A-12, 2nd Floor, Sector 2, Noida-201301 UP, India

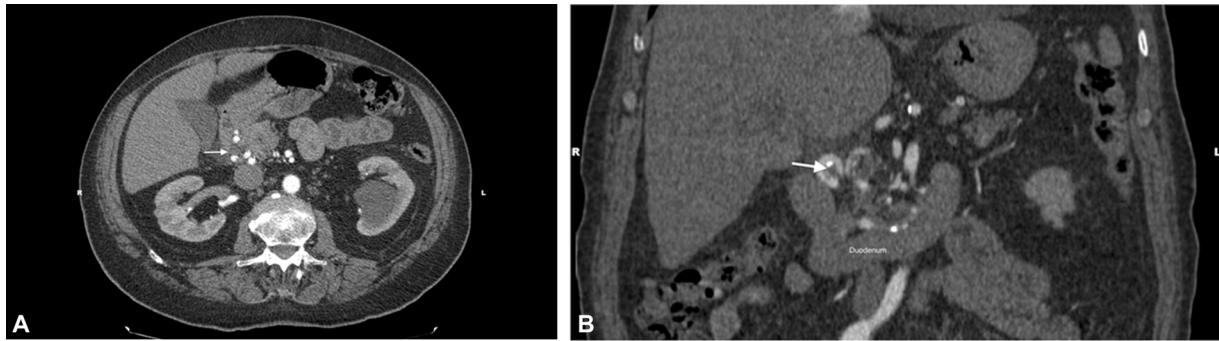


Fig. 1 Axial (A) and coronal (B) computed tomographic images showing the arterial compression onto the distal common bile duct (arrows) by tortuous and enlarged inferior pancreaticoduodenal artery branches.

hypertension, coronary artery disease, type 2 diabetes mellitus, and myasthenia gravis. His family history was unremarkable. Physical examination revealed no abnormal findings. No jaundice was observed. No palpable mass was noted in the right upper quadrant. Biochemical analyses of the liver functions on admission showed mildly increased alanine aminotransferase of 75 IU/L (normal range: 0–50 U/L), aspartate aminotransferase of 68 IU/L (normal range: 0–50 U/L), and gamma-glutamyl transferase of 116 IU/L (normal range: 0–55 U/L). Total bilirubin was 0.68 mg/dL (normal range: 0.3–1.2 mg/dL), conjugated bilirubin was 0.17 mg/dL (normal range: 0–0.2 mg/dL), and alkaline phosphatase was 99 IU/L (normal range: 30–120 U/L). The patient was tested negative for hepatitis B surface antigen and antihepatitis C virus. Alpha-fetoprotein level was within the normal range (0–9 ng/mL).

The hepatobiliary ultrasound (US) examination showed the increased echogenicity of the periportal regions as well as an echogenic nodular mass in segment 7 (not shown). Triphasic computed tomography (CT) of the liver was subsequently performed to specify the incidentally detected lesion further. And the CT displayed a hypodense nodular mass in segment 7 with a centripetal fill-in pattern on post-contrast consecutive images, characteristic of a hemangioma (not shown). Triphasic CT of the liver also revealed the arterial compression onto the distal CBD by tortuous and enlarged IPdA branches with complicating atheromatous changes adding to the described pathology (► **Figs. 1** and **2**). Further examination of the CT images established the severe stenosis of the celiac trunk orifice (► **Fig. 3A, B**). No benign nor malignant mass was noted in the periportal region. Meanwhile, magnetic cholangiopancreatography (MRCP) was performed to clarify the cause of the elevated liver enzymes, and showed the mild upstream dilation of the EBS, just cranial to the arterial compression site on the distal CBD (► **Fig. 4A–C**). When the findings of the CT and MRCP scans evaluated together, it was speculated that the distal CBD compression by tortuous and enlarged IPdA branches, namely anterior and posterior, might have been the underlying cause of impaired liver function tests.

Ursodeoxycholic acid was prescribed to relieve the bile passage. No intervention was considered, given the asymptomatic mild elevation in liver enzyme levels. The patient has been under hepatic surveillance, with no specific symptoms

regarding the hepatobiliary system at the time of this writing.

Discussion

The hypothesis that pulsatile arterial compression on extra-hepatic biliary passage might be responsible for cholestatic

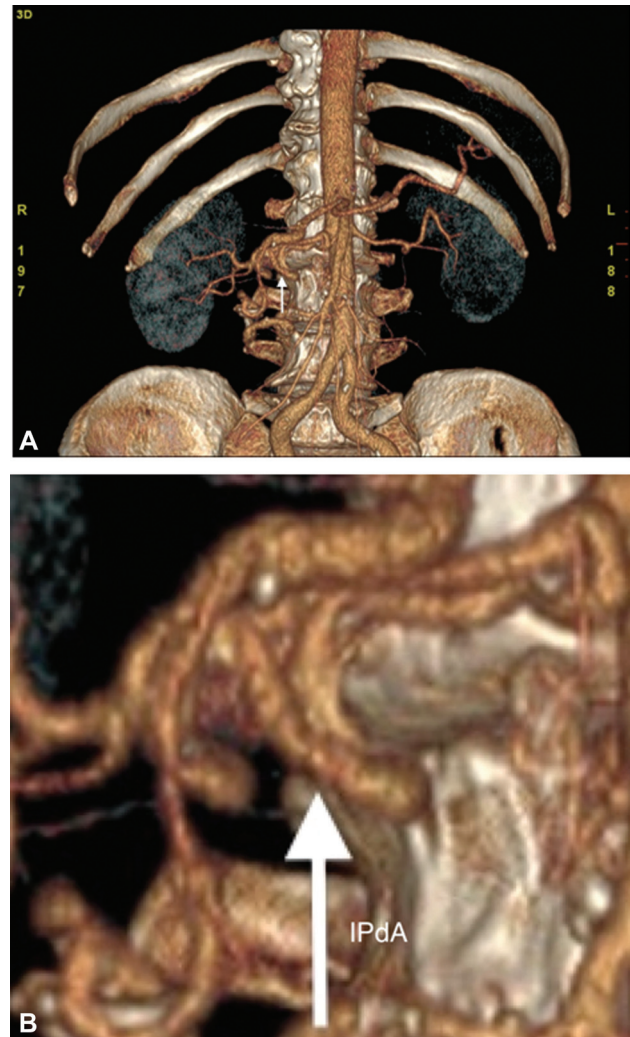


Fig. 2 Three-dimensional volume-rendered standard (A) and zoomed-in (B) computed tomographic images displaying the tortuous and enlarged inferior pancreaticoduodenal artery (IPdA; arrow).

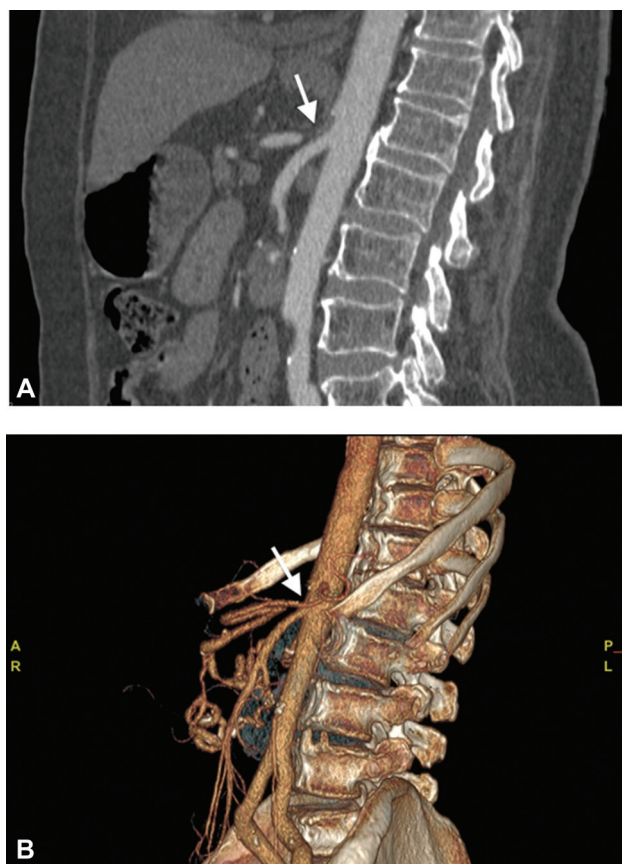


Fig. 3 Sagittal maximum-intensity projection (A) and volume-rendered (B) computed tomographic images showing severe stenosis of the celiac trunk orifice (arrow).

state in some patients was first raised in the 1960s.³ The first two cases were documented in 1984,¹ and several other cases have been added to the existing literature since then.²⁻⁷ Presenting symptoms in those cases were mainly jaundice, bile stone formation, and cholangitis, all of which could be attributed to cholestasis caused by the compression.¹⁻⁷ In other words, compression of the EBS leads to bile stasis, which may be further complicated by infection and/or hepatolithiasis.⁸

Compression of the EBS by the right hepatic artery was named as “right hepatic artery compression syndrome,” since, not surprisingly, the leading actor in those cases was the right hepatic artery. In a descriptive study, causative arteries were identified as the right hepatic artery, an unspecified branch of the common hepatic artery, gastroduodenal and cystic artery, and the proper hepatic artery, in decreasing order of frequency.⁹ In the same study, the most common site of compression was noted as the common hepatic duct, followed by the left hepatic duct, proximal CBD, and the right hepatic duct.⁹ Our case is unique in a way that the causative artery was the IPdA branches, and the compression site was the distal CBD. In our case, preocclusive stenosis of the celiac trunk led the way to the formation of enlarged anastomoses between the superior and the inferior PdAs, which are mainly supplied by the celiac trunk and the superior mesenteric artery, respectively. When these enlarged anastomoses were further complicated by severe

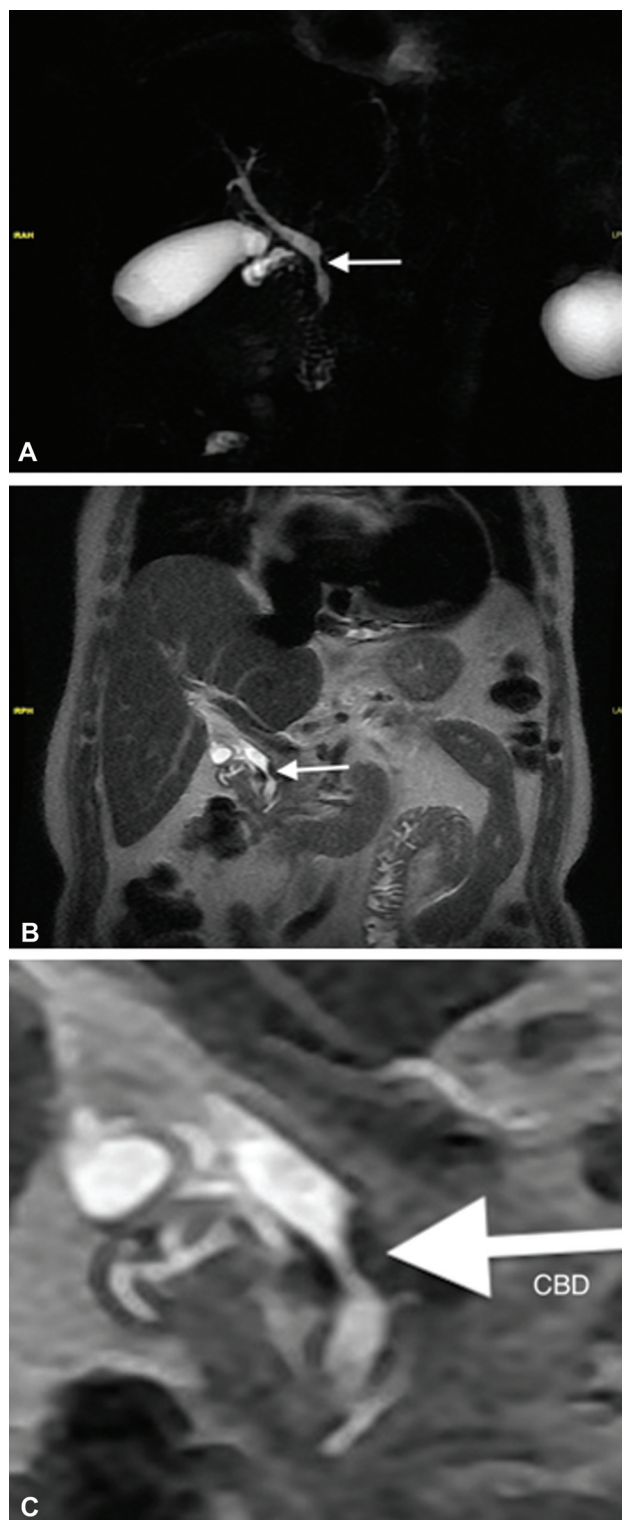


Fig. 4 Coronal thick-slab magnetic cholangiopancreatography image (A) with standard (B) and zoomed-in (C) T2-weighted images showing band-like impingement (arrow) of the distal common bile duct and resultant mild upstream dilation.

atherosclerosis, the distal CBD was somehow compressed, which might have been the underlying cause of the long-standing impaired liver function tests in our patient.

It is of utmost importance to rule out other pathologies that can be responsible for the compression of the EBS since

vascular compression syndrome is an exclusion diagnosis.⁷ US, CT, MRCP, and endoscopic retrograde cholangiopancreatography are the imaging modalities that can be used to accurately assess the presence, level, and cause of EBS compression.¹⁰ In suspicion of vascular compression syndrome, angiographic modalities should follow the aforementioned modalities.

The importance of this case report lies in the fact that vascular structures neighboring EBS should be thoroughly assessed, especially in the case of cholestatic state of unknown etiology. We, herein, propose an umbrella term for all these phenomena: “vascular compression syndrome.” The aim of this case report is to draw attention to the neighboring structures regarding EBS, which may shed light on some of the cases with cholestasis of unknown etiology.

In conclusion, anatomical and/or topographic variations, other than the hepatic artery's, should also be considered during the evaluation of the EBS compression.

Conflict of Interest

None declared.

References

- 1 Tsuchiya R, Eto T, Harada N, et al. Compression of the common hepatic duct by the right hepatic artery in intrahepatic gallstones. *World J Surg* 1984;8(03):321–326
- 2 Watanabe H, Iwase H, Sugitani M, Watanabe T. Compression of the common bile duct by the posterosuperior pancreaticoduodenal artery: case report. *Abdom Imaging* 2005;30(02):214–217
- 3 Bove V, Tringali A, Prades LF, Perri V, Barbaro B, Costamagna G. Right hepatic artery syndrome: report of three cases and literature review. *Scand J Gastroenterol* 2019;54(07):913–916
- 4 Bilanovic D, Zdravkovic D, Toskovic B, et al. Obstructive jaundice and cholangitis caused by an arterial ring of the proper hepatic artery around the common bile duct. *Med Sci Monit* 2011;17(08):CS91–CS93
- 5 Izuishi K, Toyama Y, Wakabayashi H, Usuki H, Maeta H. Compression of the common hepatic duct by the right hepatic artery. *Clin Imaging* 2005;29(05):342–344
- 6 Mendes VM, Nasser HA, Bou Nassif G, Choukr A. Prebiliary right hepatic artery resulting in common hepatic duct compression and subsequent intrahepatic stone formation: myth or reality? *Case Rep Med* 2014;2014:403104
- 7 Miyashita K, Shiraki K, Ito T, Taoka H, Nakano T. The right hepatic artery syndrome. *World J Gastroenterol* 2005;11(19):3008–3009
- 8 Beger HG, Schwarz A. Review article: Spectrum of biliary infections in the West and in the East. *HPB Surg* 1995;8(04):215–222
- 9 Watanabe Y, Dohke M, Ishimori T, et al. Pseudo-obstruction of the extrahepatic bile duct due to artifact from arterial pulsatile compression: a diagnostic pitfall of MR cholangiopancreatography. *Radiology* 2000;214(03):856–860
- 10 Cieszanowski A, Chomicka D, Andrzejewska M, Pruszyński B, Pawlak J, Mustafa AM. Imaging techniques in patients with biliary obstruction. *Med Sci Monit* 2000;6(06):1197–1202