Article published online: 2022-10-31

Unravelling the Imaging Conundrum of Rabies

Banupriya Ramakrishnan[1] Geethapriya Sivaramalingam[1] Bagyam Raghavan[1] Jayaraj Govindaraj[1]

[1] Department of Radiodiagnosis, Apollo Cancer Institute, Teynampet, Chennai, Tamil Nadu, India

Address for correspondence Banupriya Ramakrishnan, MBBS, DNB, 703 A1/1, Muthu Nagar, Kovilpatti, Thoothukudi 628501, Tamil Nadu, India (e-mail: banupriyacr11@gmail.com).

Indian J Radiol Imaging 2022;32:594–600.

Abstract

Rabies is a major disease burden worldwide, especially in Asia. Approximately, 59,000 human deaths per year occurs in over 150 countries due to rabies, with Africa and Asia contributing 95% of cases. It is a fatal infection of central nervous system (CNS) caused by rabies RNA virus via transmission through bite of an infected animal, aerosols, open wound, or organ transplantation. Magnetic resonance imaging helps in early detection of involvement of CNS and to differentiate rabies encephalitis from other conditions like Guillain-Barre syndrome, acute disseminated encephalomyelitis and other viral encephalitis.

Keywords
- rabies encephalitis
- atypical imaging
- restricted diffusion
- hemorrhage

Introduction

India accounts for almost 60% of rabies deaths in Asia and 35% globally.[1] Besides, the reported incidence is an underestimation as rabies is still not a notifiable disease in India. It is a fatal infection by rabies RNA virus affecting the central nervous system. The disease commonly transmits through bite of an infected animal. Diagnosis is based on the detection of rabies virus RNA by reverse-transcription polymerase chain reaction (RT-PCR) assay. There are two different forms of rabies—encephalitic/furious and paralytic. Encephalitic form is more common presenting with classical features of rabies. Paralytic form can present without the classical symptoms and often results in diagnostic dilemma. Due to rapid fulminant course of the disease, neurologic imaging is uncommon. Few typical imaging features have been recognized in previously published articles. We are hereby presenting a case of rabies with atypical imaging features.

Case Report

A 17-year-old young male presented in emergency room with hallucination, delirium, and altered behavior followed by aggression and sudden desaturation over a span of 2 days with suspicious drug abuse history and underwent endotracheal intubation elsewhere. Upon admission, the patient had low Glasgow Coma Scale (E3M5VT – 8T/15) with acute renal failure and there was rapid worsening of clinical symptoms with paralysis of bilateral upper and lower limbs. The patient underwent MRI brain on day 2 of admission that showed increased signal intensity in splenium of corpus callosum on T2-weighted imaging (T2WI) and fluid attenuated inversion recovery (FLAIR) sequences with restricted diffusion (►**Fig. 1**). Rest of the brain parenchyma was unremarkable.

In view of paralysis, viral encephalitis and Guillain-Barre syndrome were considered and a detailed history was further obtained. There was a history of hydrophobia and aerophobia; however, with no history of dog bite or recent vaccination, save for history of feeding stray dogs. No bite marks or open wounds were identified on physical examination. As the history and clinical picture were suspicious of rabies, a skin biopsy from nape of neck and sural nerve biopsy were performed that confirmed positive rabies RNA by reverse-transcription polymerase chain reaction (RT-PCR). Despite intense treatment, there was further worsening of symptoms with loss of brain stem reflexes. Magnetic resonance imaging (MRI) was performed on day 12 that showed bilateral symmetrical increased signal intensity on T2WI and FLAIR involving bilateral frontal, temporal, and parieto-

published online
October 31, 2022

DOI https://doi.org/10.1055/s-0042-1753465.
ISSN 0971-3026.

© 2022. Indian Radiological Association. All rights reserved.
This is an open access article published by Thieme under the terms of the Creative Commons Attribution-NonDerivative-NonCommercial-License, permitting copying and reproduction so long as the original work is given appropriate credit. Contents may not be used for commercial purposes, or adapted, remixed, transformed or built upon. (https://creativecommons.org/licenses/by-nc-nd/4.0/)
Thieme Medical and Scientific Publishers Pvt. Ltd., A-12, 2nd Floor, Sector 2, Noida-201301 UP, India

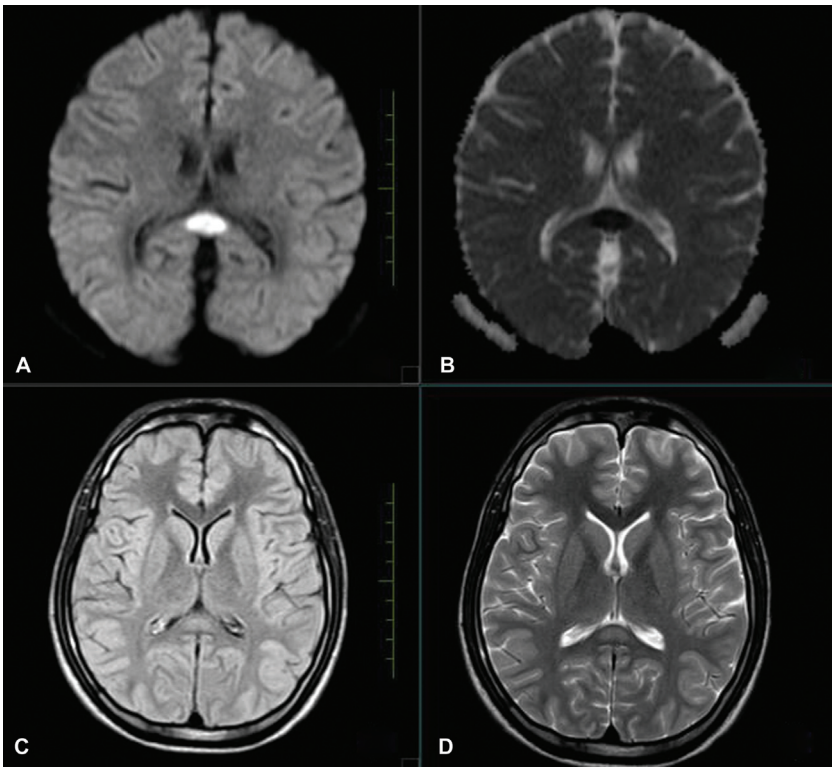

Fig. 1 On day 2, there is restricted diffusion in splenium of corpus callosum on diffusion-weighted imaging (**A**) with low apparent diffusion coefficient values (**B**). Increased signal intensity is seen on axial fluid attenuated inversion recovery (**C**) and T2-weighted imaging (**D**), suggestive of cytotoxic lesion of splenium of corpus callosum. Rest of the neuroparenchyma is normal.

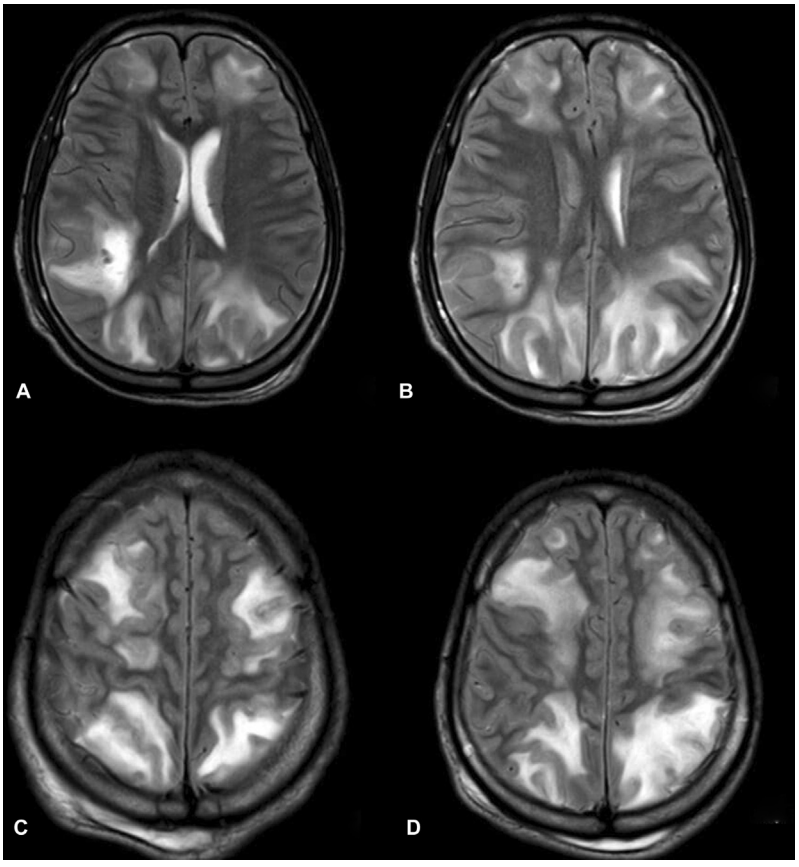

Fig. 2 (**A**–**D**) On day 12, axial T2-weighted imaging shows bilateral symmetrical increased signal intensity in gyri that is thickened and edematous with edema involving subcortical white matter.

 © 2022. Indian Radiological Association. All rights reserved.

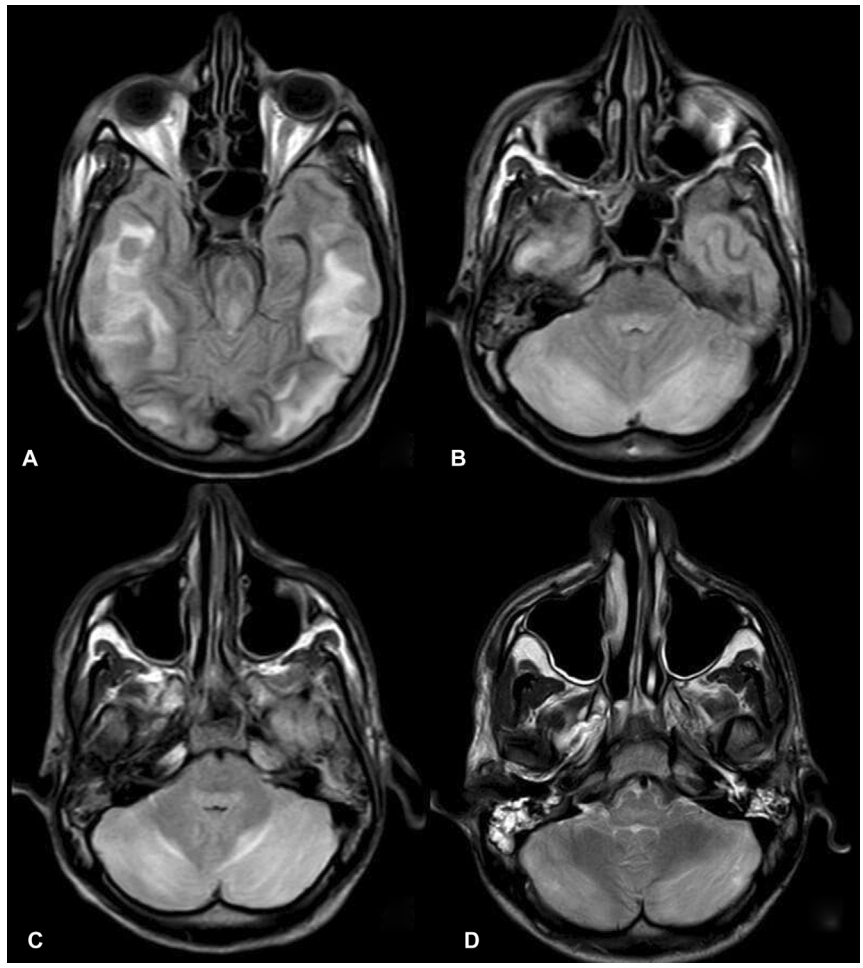

Fig. 3 On day 12, axial fluid attenuated inversion recovery (**A**–**C**) and T2-weighted imaging (T2WI) (**D**) shows increased signal intensity in brain stem (predominantly on the dorsal aspect) and cerebellar hemisphere. Note the fluid signal intensity in mastoid air cells on axial T2WI (**D**).

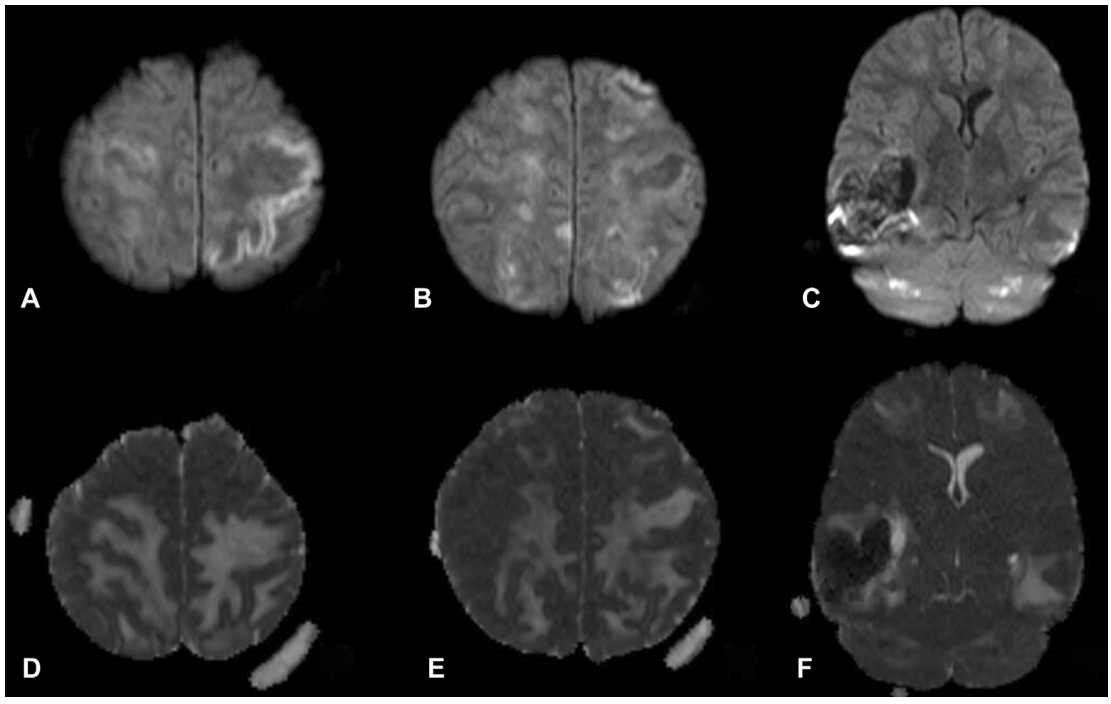

Fig. 4 On day 12, restricted diffusion is seen in thickened and edematous gyri (**A**, **B**) and cortices of bilateral cerebellar hemispheres (**C**) with corresponding low apparent diffusion coefficient values (**D**–**F**).

 © 2022. Indian Radiological Association. All rights reserved.

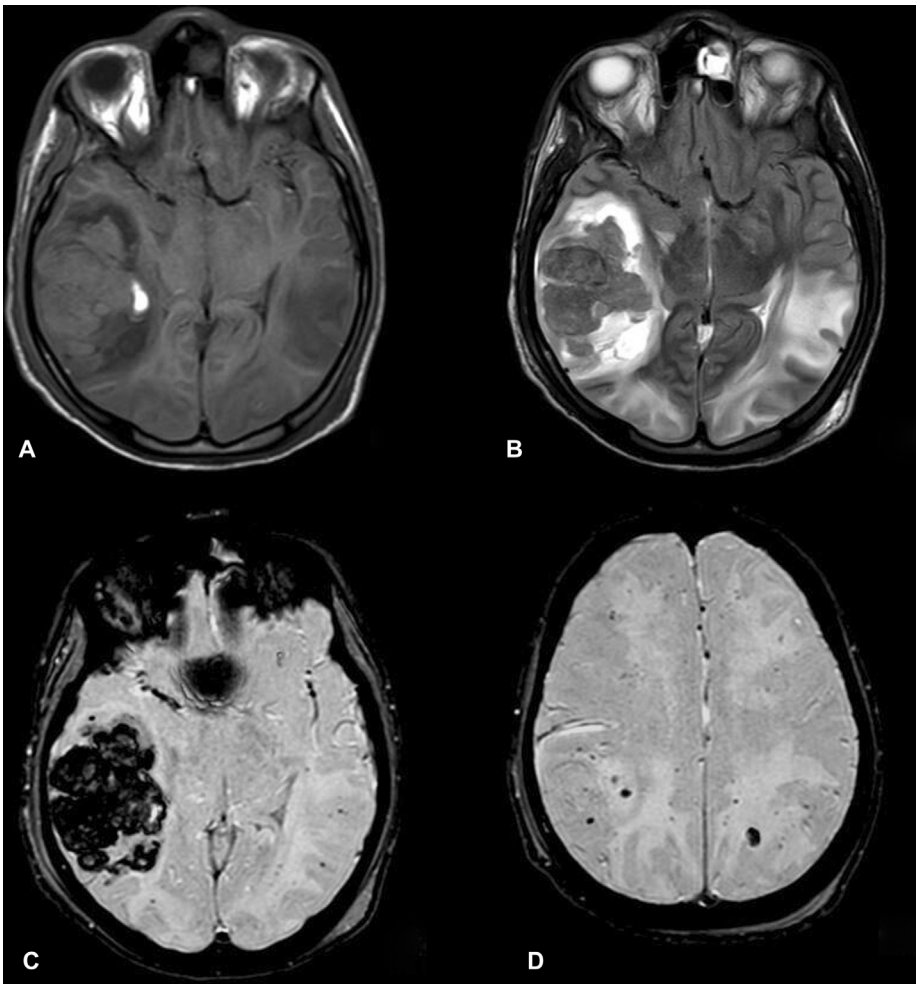

Fig. 5 On day 12, acute hemorrhage is seen in right temporoparietal cortex with mass effect that is predominantly isointense on axial T1-weighted imaging (T1WI) (**A**) and T2WI (**B**). Blooming and signal loss is seen on gradient imaging (**C**). Also note the focus of hyperintensity on T1WI (**A**) and edematous occipital gyri (**B**). Multiple foci of signal loss are also seen in bilateral frontal and parietal cortices on gradient imaging (**D**).

occipital gyri that appeared thickened and edematous (►**Fig. 2**). Restricted diffusion was seen in thickened and edematous gyri. Associated edema is seen extending to subcortical and periventricular white matter, corona radiata, and centrum semiovale. Increased signal intensity on T2WI and FLAIR imaging was also noted involving medulla, pons, midbrain predominantly along the dorsal aspect and bilateral cerebellar cortices (►**Figs. 3** and **4**). Acute hemorrhage was seen in right temporoparietal cortex with mass effect and midline shift (►**Fig. 5**). Multiple foci of hemorrhage are also seen in bilateral cerebral cortices. The features were suggestive of acute viral encephalitis with acute hemorrhage.

There was further progressive deterioration of symptoms with suspicion of brain death on day 16. Repeat MRI brain confirmed the same with sagging of brain stem, tonsillar and bilateral uncal herniation with no flow in intracranial arteries, and venous sinuses (►**Figs. 6** and **7**).

Discussion

Rabies is a fatal infection of central nervous system (CNS) caused by an RNA virus of the Rhabdoviridae family. The transmission commonly occurs through bite of an infected animal. However, transmission through aerosols, open wound, tissue, or organ transplantation has also been reported. Diagnosis is confirmed by RT-PCR based on the detection of rabies virus in saliva or skin biopsies, antigen in skin biopsies, antirabies antibodies in serum, or cerebrospinal fluid.[2]

There are two forms of rabies—encephalitic/furious and paralytic. Encephalitic form is more common and presents initially with fever, paresthesia at the site of bite, and pharyngitis followed by classical hydrophobia and aerophobia, paralysis, coma, and death. Paralytic form presents with ascending paralysis without the classical symptoms and often results in diagnostic dilemma.[3]

The virus from the site of infection comes in contact with the muscle and replicates. It infects the motor neurons that innervate the muscle and then propagates centripetally to the CNS via axonal transport. The rate of spread is 12 to 24 mm per day. After entry into the CNS, there is an initial tendency toward involvement of neurons and neuroglial cells in gray matter. Subsequently, there is rapid dissemination of the virus in CNS that leads to progressive encephalitis.[4,5]

 © 2022. Indian Radiological Association. All rights reserved.

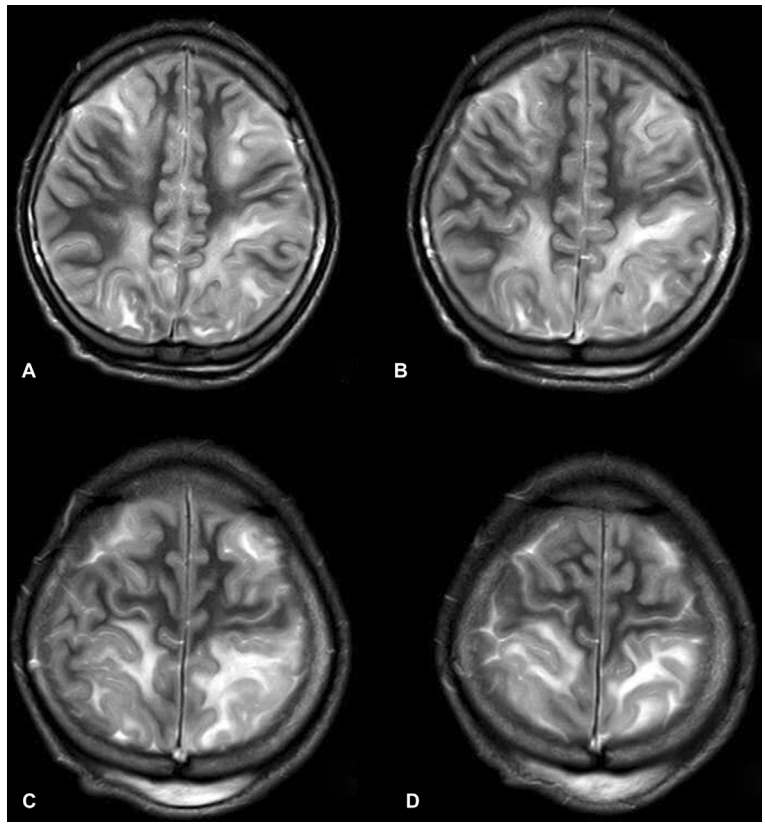

Fig. 6 (**A**–**D**) On day 16, thickened and edematous gyri with increased signal intensity seen on axial T2-weighted imaging is well appreciated and edema is seen in subcortical white matter.

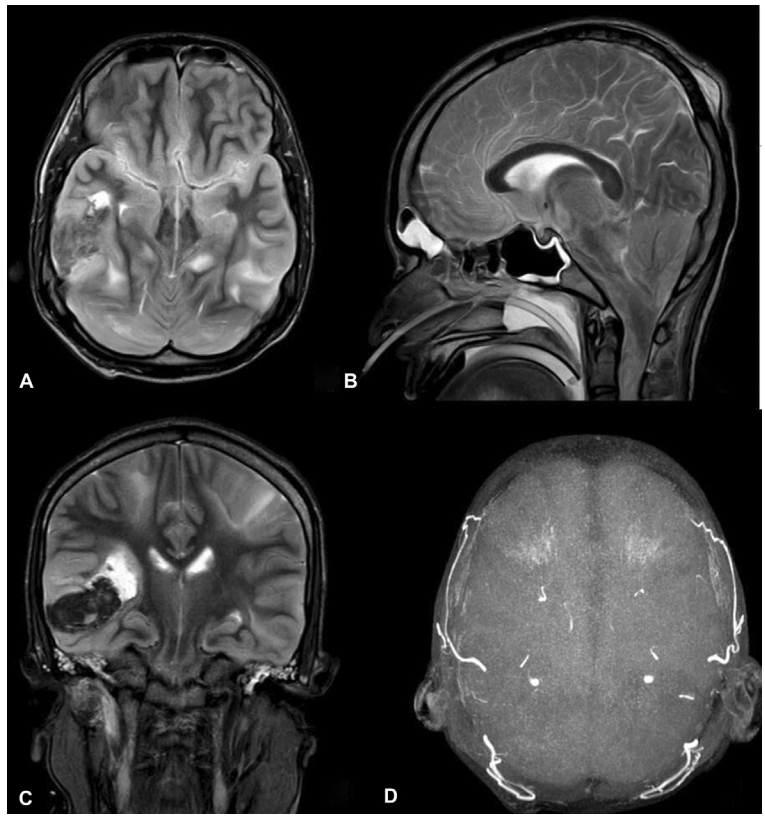

Fig. 7 On day 16, axial T2-weighted imaging (T2WI) (**A**) and sagittal T2WI (**B**) show sagging of brain stem and tonsillar herniation. Coronal T2WI (**C**) shows bilateral uncal herniation with hemorrhage in right temporoparietal cortex. Magnetic resonance angiography maximum intensity projection image (**D**) shows no flow in intracranial arteries. Features are suggestive of brain death.

 © 2022. Indian Radiological Association. All rights reserved.

Table 1 Atypical imaging features of our case in comparison with typical features of rabies encephalitis

Rabies encephalitis	
Typical imaging features	**Our case**
T2WI and FLAIR	
Encephalitic form: increased signal intensity in hippocampi, hypothalamus, basal ganglia, thalamus, dorsal brain stem, cortical gray matter and subcortical white matter[6,7]	Increased signal intensity in cerebral gray matter, brain stem and cerebellar hemispheres with sparing of hippocampus, basal ganglia and thalamus
Paralytic form: increased signal intensity in medulla and spinal cord[8]	
Other sequences (DWI, gradient)	
Restricted diffusion—rare[4,9] High ADC values[4,9] Hemorrhage—uncommon[3,9,10]	Restricted diffusion with low ADC values along the cortical margins Acute hemorrhage in bilateral cerebral cortices

Abbreviations: ADC, apparent diffusion coefficient; DWI, diffusion-weighted imaging; FLAIR, fluid attenuated inversion recovery; T2WI, T2-weighted imaging.

Table 2 Imaging features of rabies mimickers

Pathology	Involvement of gray/white matter	Involvement of basal ganglia, thalamus	Involvement of hippocampus	Involvement of brain stem, spinal cord	Restricted diffusion	Hemorrhage
Rabies encephalitis	Predominantly involves gray matter	Present	Present	Present	Rare	Rare
Guillain-Barre syndrome	Absent	Absent	Absent	Increased signal intensity and enhancement of nerve roots and cauda equina	Absent	Absent
Acute disseminated encephalomyelitis	Predominantly involves white matter	Predominantly involves thalamus	Uncommon	Uncommon	Present	Absent
Japanese B encephalitis	Present	Bilateral thalamic involvement—classic presentation	Absent	Present	Variable	Common

Due to rapid fulminant course of the disease, neurologic imaging is uncommon. Based on literature available on neuroimaging of rabies encephalitis, increased signal changes are seen in basal ganglia, thalamus, cerebral gray matter, hippocampus, dorsal brain stem, and gray matter of spinal cord on T2WI and FLAIR.[6,7] However, in encephalitic form there will be initial involvement of hippocampus and in paralytic form, often there is involvement of medulla and spinal cord.[8] In our patient, there was involvement of cerebral gray matter, brain stem (predominantly on dorsal aspect), and cerebellar hemispheres with sparing of hippocampus, basal ganglia, and thalamus. Lack of restricted diffusion and high apparent diffusion coefficient (ADC) values have been observed in patients with rabies encephalitis.[4,9] However, our patient had restricted diffusion with low ADC values in thickened and edematous gyri. Our patient also had acute hemorrhage that is rare in rabies encephalitis; as a matter of fact, it is used as a feature to differentiate from Japanese encephalitis.[3,9,10] (►**Table 1**)

MRI not only helps in early detection of involvement of CNS but also helps to differentiate rabies encephalitis from other conditions like Guillain-Barre syndrome, acute disseminated encephalomyelitis (ADEM), and other viral encephalitis. Guillain-Barre syndrome is an acute inflammatory demyelinating polyradiculoneuropathy that presents as ascending paralysis and the imaging findings are increased signal intensity and enhancement of nerve roots and cauda equina seen with sparing of brain.[4] ADEM occurs as an immune response to preceding viral illness or vaccination; on imaging there will be predominant involvement of white matter.[4,6] Japanese B encephalitis presents with bilateral thalamic and cortical involvement with foci of hemorrhage[3,9,10] (►**Table 2**).

Our patient initially had cytotoxic lesion of splenium of corpus callosum that could have been due to acute renal failure caused by rhabdomyolysis. Cytotoxic lesion of splenium of corpus callosum can also be due to early presentation of viral encephalitis.[11] Following which there was involvement of cerebral gray matter, brain stem, and cerebellar hemispheres with atypical sparing of hippocampus, basal ganglia, and thalamus that are the typical sites of involvement of rabies encephalitis. There were also

 © 2022. Indian Radiological Association. All rights reserved.

restricted diffusion and hemorrhage in our case that are uncommon findings in rabies encephalitis.

Conclusion

In conclusion, it is a case of biopsy-proven rabies with viral encephalitis having atypical imaging features on MRI. Radiologist's knowledge about these atypical imaging features will help in early diagnosis of rabies encephalitis that is expected to have a rapid fulminant course. Thereby, helping the clinicians to commence the intense supportive treatment as early as possible will improve the survival rate of the patients. MRI can also be used to differentiate it from other mimickers, such as Guillain-Barre syndrome, ADEM, and other viral encephalitis.

Prior Publication
None.

Support
None.

Permissions
None.

Conflicts of Interest
None.

References

1 World Health Organization | Epidemiology and burden of disease. 2018 https://www.who.int/rabies/epidemiology/en/ Accessed February 6, 2022
2 Jackson AC. Diabolical effects of rabies encephalitis. J Neurovirol 2016;22(01):8–13
3 Rao AS, Varma DR, Chalapathi Rao MV, Mohandas S. Case report: magnetic resonance imaging in rabies encephalitis. Indian J Radiol Imaging 2009;19(04):301–304
4 Co SJ, Mackenzie IR, Shewchuk JR. Rabies encephalitis. Radiographics 2015;35(01):235–238
5 Fishbein DB, Bernard KW. Rabies virus. In: Mandell GL, Bennett JE, Dolin R, eds. Principles and Practice of Infectious Diseases. 4th edition. New York: Churchill-Livingstone; 1995:1527–1541
6 Santhoshkumar A, Kalpana D, Sowrabha R. Rabies encephalomyelitis vs. ADEM: usefulness of MR imaging in differential diagnosis. J Pediatr Neurosci 2012;7(02):133–135
7 Mani J, Reddy BC, Borgohain R, Sitajayalakshmi S, Sundaram C, Mohandas S. Magnetic resonance imaging in rabies. Postgrad Med J 2003;79(932):352–354
8 Awasthi M, Parmar H, Patankar T, Castillo M. Imaging findings in rabies encephalitis. AJNR Am J Neuroradiol 2001;22(04):677–680
9 Bokade CM, Gajimwar VS, Meshram RM, Wathore SB. Survival of atypical rabies encephalitis. Ann Indian Acad Neurol 2019;22 (03):319–321
10 Laothamatas J, Hemachudha T, Mitrabhakdi E, Wannakrairot P, Tulayadaechanont S. MR imaging in human rabies. AJNR Am J Neuroradiol 2003;24(06):1102–1109
11 Starkey J, Kobayashi N, Numaguchi Y, Moritani T. Cytotoxic lesions of the corpus callosum that show restricted diffusion: mechanisms, causes, and manifestations. Radiographics 2017;37(02):562–576

 © 2022. Indian Radiological Association. All rights reserved.