



Radio Frequency Ablation for the Treatment of Appendicular Skeleton Chondroblastoma: Is It an Excellent Alternative? Systematic Review and Meta-Analysis

Sarmad Rasheed Khalil Sulaiman¹ Shadha Abobakr Mohammed Al-Zubaidi² Amal Abdelsattar Sakrana³

¹Department of Orthopaedic Surgery, King Salman Medical City, Al Madina Al Munawara Hospital, Medina, Saudi Arabia

²Department of Diagnostic Imaging, Madina Cardiac Centre, Medina, Saudi Arabia

³Department of Diagnostic and Interventional Radiology, Mansoura University Hospital, Mansoura, Egypt

Address for correspondence Sarmad Rasheed Khalil Sulaiman, Department of Orthopaedic Surgery, King Salman Medical City, Al Madina Al Munawara Hospital, 60, Mahzur, Medina 42319, Saudi Arabia (e-mail: sar.ortsursrm@gmail.com).

Indian J Radiol Imaging 2022;32:523–530.

Abstract

Radio frequency ablation (RFA) is a minimally invasive technique that has become recognized in clinical practice for treating chondroblastoma, although curettage with bone graft is the standard treatment. Chondroblastoma is a locally aggressive cartilaginous bone tumor, representing nearly 5% of benign bone tumors. Chondroblastoma shows a preference toward the epiphysis or apophysis of long bones, but it was also reported in vertebrae and flat bones. The management of chondroblastoma could be challenging due to the risk to injure the epiphyseal plate or difficult location. The aim of this study was to determine if RFA is a suitable alternative to curettage with bone graft for the treatment of chondroblastoma. Moreover, there will be an evaluation of RFA's effectiveness in terms of symptoms relief; we also define the proper size of the lesion to be treated with RFA, and discuss the complications after the procedure, including the recurrence rate. Furthermore, we review the best imaging method to evaluate the therapeutic response of RFA and for the detection of residual disease early after the ablation. A comprehensive PubMed and Google Scholar search followed the Preferred Reporting Items for Systematic Review and Meta-Analysis 2020 checklist guidelines. Ninety-seven patients were identified after reviewing the available full texts of nine articles. The results of the current review provide further evidence to support the use of RFA as an alternative option to surgery.

Keywords

- ▶ chondroblastoma
- ▶ cartilaginous
- ▶ cartilage
- ▶ bone tumor
- ▶ radio frequency ablation

published online
August 30, 2022

DOI <https://doi.org/10.1055/s-0042-1755248>.
ISSN 0971-3026.

© 2022. Indian Radiological Association. All rights reserved.
This is an open access article published by Thieme under the terms of the Creative Commons Attribution-NonDerivative-NonCommercial-License, permitting copying and reproduction so long as the original work is given appropriate credit. Contents may not be used for commercial purposes, or adapted, remixed, transformed or built upon. (<https://creativecommons.org/licenses/by-nc-nd/4.0/>)
Thieme Medical and Scientific Publishers Pvt. Ltd., A-12, 2nd Floor, Sector 2, Noida-201301 UP, India

Introduction and Background

Chondroblastoma was mentioned for the first time in the literature by Kolodny in 1927 as cartilage comprising giant cell tumor (GCT). Codman, in 1931, described it as an epiphyseal chondromatous GCT affecting mainly the proximal humerus and was referred to as Codman tumor.¹ Jaffe and Lichtenstein conducted a comprehensive review in 1942 and concluded that chondroblastoma is a benign tumor of the bone with a different and distinct entity from GCT.²

Chondroblastoma exemplifies around 5% of benign bone tumors and 1 to 2% of all primary bone tumors.^{1,3} Most patients affected are less than 20 years of age, though chondroblastoma was reported in patients aged 2 to 73 years.^{1,3} The male-to-female ratio is nearly 2:1.^{1,3,4} The femur is the most involved, followed by the humerus and tibia.^{1,4,5} Chondroblastoma prefers the long bones' epiphysis and the apophysis, like the apophysis in the talus and the calcaneus.^{1,3-6}

While a few epiphyseal chondroblastomas will traverse the growth plate and overrun the metaphyseal region, genuine metaphyseal and diaphyseal lesions are rare but reported.¹ Chondroblastoma can arise in flat bones and vertebrae.^{1,7} Chondroblastoma is considered stage 2 (i.e., active) or 3 (i.e., aggressive) according to the Enneking benign bone tumor classification.¹

Chondroblastoma is generally presented insidiously with mild to considerable pain, soft-tissue mass, or pathological fracture,^{1,3} though the presence of a palpable mass is unusual.^{1,3,8} Pain with local tenderness in the affected bone and the nearby joint is the most frequent complaint, followed by a reduced range of motion.^{1,4} The onset of symptoms to the diagnosis varies from less than a month to years.^{1,3}

On a radiograph, chondroblastoma appeared as a well-defined eccentric oval or round lytic lesion with a sharp sclerotic margin involving the epiphysis adjacent to an open growth plate; the lesion might be fuzzy or mottled or include areas of calcification, especially in skeletally immature patients, and it is uncommon to find periosteal bone formation.¹ The lesion size varies, with most being less than four centimeters.^{1,9}

Chondroblastomas may be associated with a secondary aneurysmal bone cyst, and these sometimes lead to confusion in the diagnosis on the radiograph. A computed tomography (CT) scan can help define the distance of the lesion to the growth plate and their relation and shows the calcification of the cartilaginous matrix when present. Besides, CT helps delimit subchondral fractures not visible on plain radiographs.^{1,7} Magnetic resonance imaging (MRI) leads to misdiagnosis or overestimating the tumor aggressiveness.¹ Bone scan displays increased uptake but is seldom needed for the diagnosis.¹⁰

Chondroblastoma has recurrence rates ranging from 10 to 35% after surgical curettage.⁴ Chondroblastoma rarely develops lung metastases, and these metastases commonly have an indolent course. There is no registered relation of metastasis to surgical/nonsurgical treatment, patient age, or tumor location.¹¹ The reported time for metastases from the initial

diagnosis to clinical manifestation varies from 5 months to 33 years (8 years on average); the prognosis is better when the metastases are resectable.¹² Chemotherapy has no reported benefit.¹²

Chondroblastoma does not regress spontaneously, and the traditional treatment is surgical curettage despite the recognized complications of damaging the growth plate or the articular cartilage, which may lead to growth disturbance or early-onset osteoarthritis, respectively.^{4,13,14} Subsequently, this makes radio frequency ablation (RFA) a potentially desirable alternative.

As far as we know, there are no prospective, randomized controlled trials, given the low number of individuals affected with chondroblastoma. In the literature, small, retrospective studies have been released and are often liable to a high degree of bias, and the numbers are too small for valuable statistical analysis. Therefore, a systematic review is required to search for and summarize the available evidence.

The purpose of this current literature review is to determine if RFA is a suitable alternative to curettage with bone graft for the treatment of chondroblastoma. Moreover, there will be an evaluation of the RFA effectiveness in terms of symptoms relief; we also define the proper size of the lesion to be treated with RFA, and discuss the complications after the procedure, including the recurrence rate. Furthermore, we review the best imaging method to evaluate the therapeutic response of RFA and for the detection of residual disease early after the ablation.

Review

Methods

The primary objective of this study was to judge the effectiveness of RFA for appendicular skeleton chondroblastoma treatment as an alternative to surgery.

This literature review was performed on April 20, 2021, following Preferred Reporting Items for Systematic Review and Meta-Analysis (PRISMA) 2020 checklist guidelines. Types of studies included were: randomized controlled trials, observational studies, case reports, systematic reviews, longitudinal cohorts, retrospective studies, prospective studies, and case series aimed to evaluate the efficacy of RFA for chondroblastoma treatment as an alternative to curettage with bone graft. The authors independently screened all abstracts and excluded those irrelevant to the scope of this study. Studies were included when they met the following inclusion criteria: (1) published articles written only in English between 2000 and 2021; (2) published articles with full text availability written only for the human species; (3) the assessment is only for RFA; (4) studies related to chondroblastoma only; (5) any age population studies; and (6) at least 6 months of clinical follow-up after treatment. Exclusion criteria included: (1) results of other techniques rather than RFA results; (2) results of combined techniques with RFA; (3) lesions in the axial skeleton; and (4) case reports with less than two patients.

The literature was reviewed by a comprehensive PubMed and Google Scholar search. The summary of the results using

Table 1 PubMed search results using keywords

Keyword	Database	Total results after inclusion/exclusion criteria
Chondroblastoma	PubMed	524 results
Cartilaginous	PubMed	53,202 results
Cartilage	PubMed	51,871 results
Bone Tumor	PubMed	111,414 results
Radio frequency Ablation	PubMed	31,470 results

keywords and medical subject heading (MeSH) terms is shown in ►Tables 1–3.

We cross-matched the keyword RFA with the other keywords and applied the inclusion/exclusion criteria; 617 articles appeared. After that, we scanned the reference first by titles and published abstracts; 548 articles were removed in addition to 53 nonrelevant articles (►Table 4). Further, seven articles were removed due to duplication.

Results

Nine original articles met the selection criteria; subsequently, we reviewed the available full texts and identified 97 patients. The summary of this search process is documented in the PRISMA flow chart in ►Fig. 1.

The data from each article were compiled into a standardized table (►Table 5), which included: study information (authors, date of publication, sample size), patient age, lesion

Table 2 Google Scholar search results using keywords

Keywords	Database	Total results after inclusion/exclusion criteria
Chondroblastoma	Google Scholar	7,400 results
Cartilaginous	Google Scholar	37,000 results
Cartilage	Google Scholar	1,070,000 results
Bone tumor	Google Scholar	1,600,000 results
Radio frequency Ablation	Google Scholar	154,000 results

Table 3 PubMed search results using medical subject heading (MeSH) terms

MeSH terms	Database	Total results after inclusion/exclusion criteria
((“Radiofrequency Ablation/therapeutic use” [MeSH] OR “Radiofrequency Ablation/therapy” [MeSH])) AND “Chondroblastoma/therapy” [MeSH]	PubMed	2 results
((“Radiofrequency Ablation/therapeutic use” [MeSH] OR “Radiofrequency Ablation/therapy” [MeSH])) AND “Cartilage, Articular” [MeSH]	PubMed	13 results
((“Radiofrequency Ablation/therapeutic use” [MeSH] OR “Radiofrequency Ablation/therapy” [MeSH])) AND “Cartilage/therapy” [MeSH]	PubMed	15 results
((“Radiofrequency Ablation/therapeutic use” [MeSH] OR “Radiofrequency Ablation/therapy” [MeSH])) AND “Bone Neoplasms/therapy” [MeSH]	PubMed	59 results
	Total	79 results

information (location, average size, largest lesion size, pre-operative diagnosis), procedure information (imaging guidance, anesthesia, type of electrode, heating temperature, heating time, heating number, total time of RFA), complications (early, late, subchondral collapse, growth plate disturbance, recurrence), need for surgery after RFA, need to repeat RFA, follow-up (duration, imaging), resolution of symptoms, and success rate for initial pain relief. In addition, data that were not available or unspecified from the full text were indicated with “not available” in the table.

Discussion

RFA implementation and thermal influences on tissue were illustrated by d’Arsonval in 1891. It was first merged into the current medicine with the Bovie knife in 1928, which was used for tissue cutting and cauterization.¹⁵ Tissue ablation was performed for liver tumors early in 1992 with a modified Bovie knife.¹⁵

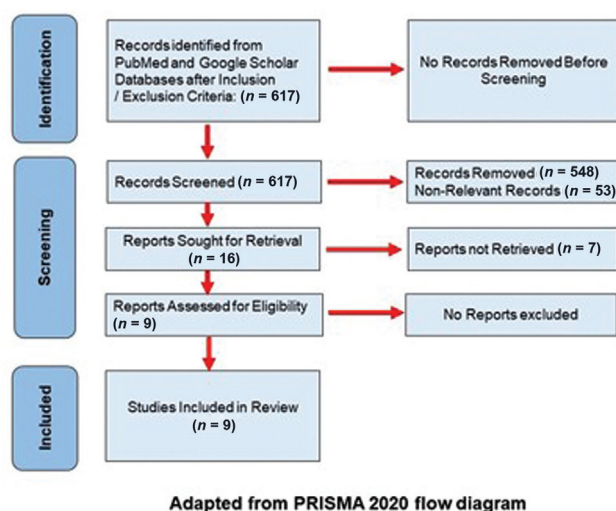
RFA induces coagulative necrosis of the tissues due to high temperature; at 55°C, tissue death results within 2 seconds, while at 100°C, tissue death is immediate as vaporization occurs.^{15–17} When the temperatures reach greater than 105°C promptly, boiling, evaporation, and charring have resulted, reducing the energy transmission and subsequently decreasing the ablation size. Therefore, the idea is to heat the tissues between 50 and 100°C for 4 to 6 minutes without causing charring or vaporization.^{15,18}

When the lesion is adjacent to a blood vessel, the blood flow cooling effect alters the RFA temperature leading to heat loss (heat sink). This heat sink phenomenon near the vessel wall possibly leaves residual nonablated tumors behind, increasing the chance of local recurrence.^{15,18} Nevertheless, chondroblastomas contain relatively less vascularity, and the occurrence of the heat sink is limited.¹⁸ In addition, the cortical bone is an electrical and thermal insulator; hence, an intact shell of the bone surrounding the chondroblastoma reduces the risk of further thermal damage to the adjacent tissues; this insulating property is significantly reduced with thinning and expansion of the cortical bone.^{17,18} However, the cortical bone covering chondroblastomas may not always be intact.

On purpose, radio frequency ablates a margin of normal tissue equivalent to the surgical resection margin

Table 4 PubMed and Google Scholar cross-match keywords search results

Cross-match keywords	Database	Total results after inclusion/exclusion criteria	Removed results	Nonrelevant	Selected articles
“Radiofrequency Ablation” AND “Chondroblastoma”	PubMed	9	2	1	6
“Radiofrequency Ablation” AND “Cartilaginous”	PubMed	5	3	2	0
“Radiofrequency Ablation” AND “Cartilage”	PubMed	24	21	2	1
“Radiofrequency Ablation” AND “Bone tumor”	PubMed	31	28	3	0
“Radiofrequency Ablation” AND “Chondroblastoma”	Google Scholar	548	494	45	9
Total		617	548	53	16

**Fig. 1** Summary of this search process is documented in the PRISMA—Preferred Reporting Items for Systematic Review and Meta-Analysis—flow chart.

surrounding the tumor; such margin must be 0.5 to 1.0 cm in width.^{15,19}

Over two decades ago, RFA was introduced into the orthopaedic field and became the main standard for treating osteoid osteoma, with primary and secondary success rates of 79 to 96% and 97 to 100%, respectively.^{16–18,20–22} RFA has proven to be safe, minimally invasive, relatively inexpensive, and precise treatment tool for other bony lesions such as chondroblastoma and metastases.^{16,23} The first application of RFA for chondroblastoma appears to be unplanned, when a lesion thought to be an osteoid osteoma was treated with RFA without complication during the follow-up period that extended to 2 years.¹⁸

This current review reveals a success rate of 100% initial pain relief in most cases after RFA. A complete resolution of symptoms occurs between immediate and up to 12 weeks, as demonstrated in the summary table (►Table 5). Furthermore, early resumption of regular activity in comparison to surgery was observed.

The authors determined that subchondral collapse as a late complication occurred in 7.2% of the cases (7 out of 97) included in this review.^{14,18,21,23} Two cases of the seven already had subchondral fracture and collapse before the RFA.^{14,18} Also, the subchondral collapse occurred in one case when RFA was applied after postcurettage recurrence and in another case with insufficient RFA.^{18,21} Consequently, caution must be paid to the lesion location and size; when a large lesion is adjacent to the articular cartilage or in the weight-bearing joints, there is a significant risk of mechanical bone weakness leading to subchondral collapse and cartilage damage.^{17,18,21} This is attributed to the RFA's considerable volume of thermal energy transmitted over a prolonged period through the adjacent cartilage tissue.^{17,18,21}

Additionally, the insulating property of the cortical bone is substantially reduced, and the lack of bone replacement after successful RFA increases the subchondral collapse risk.^{17,18,21} Therefore, cartilage damage must be assumed, and this drawback should be balanced against the risk of the standard curettage.^{18,21} Hence, with those such lesions, a period of a nonweight bearing should be advised.¹⁸

We realized that no mechanical bone failure occurred in three studies despite some lesions with dimensions equal to 2.5 cm.^{13,17,22} This could be attributed to the less time spent during the heating cycle and the type of radio frequency electrode used. A multitined expandable electrode was utilized in 80% of the cases complicated with the subchondral collapse (►Table 5).^{13,14,18,22}

Technically, the multitined expandable electrode is more demanding and requires careful planning and a certain skill for probe positioning.¹⁸ In addition, the energy deposition with the multitined expandable electrode can deliver a power of more than 100 Watt compared with a few Watts with the single-tined electrode, consequently creating a greater ablation zone than the single electrode, potentially increasing the risk of damaging the nearby tissue.^{13,18} Therefore, based on the successful cases, we recommend using a single electrode to cover the affected area properly.

Table 5 Summary of the literature review of chondroblastomas treated with radio frequency ablation

Publication date	2001	2005	2008	2009	2012	2013	2014	2015	2021
Authors	Erickson et al ²⁰	Tins et al ¹⁸	Christie-Large et al ²²	Rybak et al ²¹	Rajalakshmi et al ¹⁷	Dharia et al ³⁰	Lalam et al ¹⁴	Xie et al ¹³	Kulkarni et al ²³
No. of cases	3	4	4	17	3	6	8	25	27
Average patients' age (in years)	17.6 (10–26)	14.8 (13–16)	13 (9–16)	17.3 (10–30)	27 (12–55)	18.4	17 (13–19)	14 (9–18)	Data not available
Lesion location	FH, PTE, FC	GTH, 2PTE, FC	2FH, 2PTE	3FH, 4PTE, 3FC, 7PH	3PTE	PH, 2PTE, 2FH, FC	GTH, FH, PTE, FC	8PTE, 7FH, 4PH, 3FC, DTE, DR, T	6PH, 8PTE, 6FH, 5FC, AC, L
Average lesion size	1.4 cm	3.3 cm	1.8 cm	1.4 cm	2.2 cm	Mean volume 2.25 mL	2.7 cm	2.0 cm	Data not available
Largest lesion size	1.8 × 1.9 cm	4.6 × 4.8 × 1.8 cm	2 × 2.5 cm	2.5 × 2.0 × 2.1 cm	2.5 × 2.1 × 2.0 cm	Data not available	4.6 × 4.8 × 1.8 cm	Not mentioned	Data not available
Preoperative diagnosis based on:	Biopsy for 1 patient	Not clear	Biopsy for 2 patients	Typical imaging and clinical features	Typical imaging and clinical features	Data not available	Biopsy	Typical imaging and clinical features	Data not available
Diagnostic biopsy time to RFA	1 Before, 2 at RFA	Not clear	2 Before, 2 at RFA	At time of RFA	At time of RFA	Data not available	Before RFA	At time of RFA	Not clear
Imaging guidance	CT	CT	CT	CT	CT	CT	CT	CT	Data not available
Anesthesia	General	General	General	General	General	Data not available	General	General	Data not available
Type of electrode	Single tined	Multitined expandable	Single tined	Single tined	Single tined	Single tined, multitined expandable	Multitined expandable	Single tined	Data not available
Heating temperature	90°C	90°C	90°C	90°C	Not mentioned	Data Not Available	90°C	90°C	Data not available
Time in minutes per heating	6	5	3	6	Not mentioned	Data not available	5	6	Data not available
No. of heating	1–7	1–4	4–16	1–12	2–3	Data not available	1–4	1–12	Data not available
Total time of RFA (in minutes)	6–37	5–20	12–48	Mean 17.6 (6–72)	Not mentioned	Data not available	5–20	6–72	Data not available
Follow-up period (in months)	24–48	12–22	5–18	4–134	17–21	6	8–59	Mean 49	Minimum 12
Follow-up imaging	Radiograph, CT	Radiograph, CT, MRI	MRI	CT, MRI	Radiograph, CT	MRI, FDG-PET-CT	CT, MRI	MRI	Data not available
Patient lost in follow-up	0	0	0	3	0	0	0	0	0
Symptoms resolution after RFA	Immediate	Immediate	Complete in 2–6 weeks	1 day	1–2 days, except one patient	Complete in 2–6 weeks	Complete	1 week	6 weeks
	100%	100%	100%	100%	75%	100%	100%	100%	100%

(Continued)

Table 5 (Continued)

Publication date	2001	2005	2008	2009	2012	2013	2014	2015	2021
Initial pain relief success rate									
Need to repeat RFA	0	0	0	0	1	0	0	1	0
Need surgery after RFA	0	0	0	2	0	0	0	2	0
Early complication after RFA	0	0	0	0	0	0	0	0	0
Late complication after RFA	0	2	0	2	1	0	2	3	2
Subchondral collapse	0	2	0	1	0	0	2	0	2
Growth plate disturbance	0	0	0	0	0	0	0	0	0
Recurrence	0	0	0	1	1	0	0	3	0

Abbreviations: AC, acromion process; °C, degree Celsius; cm, centimeter; CT, computed tomography; DR, distal radius; DTE, distal tibia epiphysis; FC, femoral condyle; FDG-PET-CT, fluorine-18 fluorodeoxyglucose positron emission tomography computed tomography; FH, femoral head; GTH, greater tuberosity humerus; L, lumate; mL, milliliter; MRI, magnetic resonance imaging; PH, proximal humerus; PTE, proximal tibia epiphysis; RFA, radio frequency ablation; T, talus.

In one study, core biopsy, RFA, and curettage were applied during the same sitting, enabling bone grafts insertion at the lesion site.¹⁶ The insertion of bone grafts accelerated the healing process and decreased the anticipated bone weakness and collapse after RFA.¹⁶ In another technique, percutaneous RFA and cementation were applied.²⁴ None of the patients in both procedures developed articular cartilage failure when combined with bone augmentation or cementation. Thus, these techniques could be the solution to approach the large subchondral lesions and are worth studying with longer follow-up to establish the longstanding result.

Alternatively, after a surgical curettage, a significant disruption in the anatomy at the operative site is expected, resulting in more complexity with surgical revision, most likely when the lesion is close to the articular surfaces or in patients with open physis.^{4,14,25,26} Furthermore, the lesions could be difficult to treat surgically, especially when small and epiphyseal locations commonly require an intraarticular approach for appropriate visualization.

On the other hand, the current review showed a recurrence rate of 5.1% (5 out of 97) after RFA.^{13,17,21} The anatomical complexity of the ablated areas led to incomplete ablation and, consequently, tumor recurrence.¹³ Moreover, local changes post curettage led to underestimating the tumor recurrence behind the margins and, therefore, insufficient RFA when needed.¹³ Additionally, recurrence developed in lesions has dimensions equal to or greater than 2.5 cm.^{13,17,21} With surgery, the recurrence rates can vary between 10 and 35% reported in several surgical series, and some patients suffer from two to three recurrences.^{4,14,17,25} Revision of surgery after recurrence is more difficult than RFA, and annual follow-up for a minimum of 5 years is recommended to monitor the recurrence.^{4,25,26} Chondroblastoma could recur within 10 months of treatment; a larger study with a longer follow-up is required to assess the risk of recurrence following RFA.²⁵

The successful surgical treatment of a tumor could be validated histopathologically by the evidence of tumor-free margins of the removed sample. However, with RFA, there is a requirement to use certain imaging techniques to verify the completeness and the adequacy of the therapeutic response and early detection of residual pathology.

Most of the studies in this current review used MRI and/or CT to evaluate the response after RFA (► **Table 5**). Both showed a reduction in the lesion's size; moreover, MRI demonstrated a significant decrease in the intensity of perilesional edema and final resolution of the joint effusion when present. Subsequently, a rim of high signal established around the lesion's periphery and began to fill into the lesion, almost certainly signifying a progressive fatty consolidation of the lesion as the healing process started.^{13,22} Despite that, it is difficult with CT or MRI to differentiate between the residual disease and the post-ablation tissue changes.^{27,28}

RFA causes local hyperemia and inflammation in the periphery of the ablated zone, which results in contrast enhancement on CT or MRI that subsides with time.^{27,29}

However, the contrast enhancement early after RFA can obscure residual disease detection, making it difficult to differentiate between the typical postablation responses and the residual disease. So, local treatment failures after RFA could not be identified easily except at a late stage.²⁷

The combination of CT and fluorine-18 fluorodeoxyglucose (FDG) positron emission tomography (PET) is a valuable tool for evaluating the therapeutic response along with the anticipation of disease recurrence.^{27,30}

FDG-PET helps to assess the cellular glucose metabolism and its early changes; it has been used successfully to evaluate the early reaction of tumors in the course of treatment.²⁷ Heating induces coagulative necrosis in the cells associated with cellular failure to concentrate FDG in the ablated zone; this lack of FDG uptake indicates an adequate and complete tumor ablation.²⁷ However, within 2 to 3 days after RFA, inflammation and tissue regeneration start in the necrotic area's periphery and produce peripheral, uniform, and low-to-moderate intensity FDG uptake. Consequently, it is essential to perform the FDG-PET study early before these changes begin to detect the residual disease, in which the uptake is seen as a nodular and irregular focus in the ablated zone.²⁷

Moreover, follow-up monitoring by gadolinium-enhanced magnetic resonance imaging (G-MRI) may efficiently meet these requirements. G-MRI was utilized to detect residual atypical chondrosarcoma after RFA.²⁸ By comparing the results of G-MRI and histopathology, G-MRI is 91% sensitive to detecting residual tumors.²⁸ The application of the G-MRI study for the follow-up after chondroblastoma ablation is worth the material for future research. More research should be conducted to evaluate G-MRI accuracy in detecting residual chondroblastoma after RFA.

Limitations

The authors believe that the anticipated advantages of using RFA have all been verified by the current study, though there are various limitations in this literature review. The number of cases was small because of the rarity of chondroblastoma, and most of the follow-up periods in the studies were less than 5 years. Thus, it is not easy to accumulate considerable clinical experience. The authors could not be certain of the appropriate size of chondroblastoma to be treated with RFA. Therefore, it is essential to conduct a combined randomized, statistically significant study with larger cases and longer follow-up comparing RFA with surgery and to ascertain the applicable size of chondroblastoma for RFA.

Conclusion

The results of the current review provide further evidence to support the use of RFA as an alternative option to surgery with several advantages.

Currently, the location and size of chondroblastomas are the most important predictors of success. Lesions smaller than 2.5 cm have been demonstrated with encouraging outcomes. However, large lesions should be dealt with caution to reduce the probability of damage to the articular surface.

Subchondral collapse and local recurrence are minimal compared with surgery; even with recurrences, repeated RFA has limited morbidity.

It is difficult with MRI and CT to differentiate between the residual disease and the postablation tissue changes. However, the combination of CT and FDG-PET is valuable in evaluating the therapeutic response along with the expectation of disease recurrence.

Funding

This research did not receive any specific grant from funding agencies in the public, commercial, or not-for-profit sectors.

Conflict of Interest

The authors declare that they have no known competing financial interests or personal relationships that could have appeared to influence the work reported in this paper.

Authors' Contributions

Dr. Sulaiman conceived and designed the study and wrote the initial draft of the article. Dr. Al-Zubaidi and Dr. Sakrana collected, organized, analyzed, and interpreted the data. Dr. Sulaiman provided critical revision and wrote the final draft of the article. All authors critically reviewed and approved the final draft and are responsible for the content and similarity index of the manuscript.

References

- De Mattos CB, Angsanuntsukh C, Arkader A, Dormans JP. Chondroblastoma and chondromyxoid fibroma. *J Am Acad Orthop Surg* 2013;21(04):225–233
- Jaffe HL, Lichtenstein L. Benign chondroblastoma of bone: a reinterpretation of the so-called calcifying or chondromatous giant cell tumor. *Am J Pathol* 1942;18(06):969–991
- Chen W, DiFrancesco LM. Chondroblastoma: an update. *Arch Pathol Lab Med* 2017;141(06):867–871
- Sailhan F, Chotel F, Parot RSOFOP. Chondroblastoma of bone in a pediatric population. *J Bone Joint Surg Am* 2009;91(09):2159–2168
- Springfield DS, Capanna R, Gherlizoni F, Picci P, Campanacci M. Chondroblastoma. A review of seventy cases. *J Bone Joint Surg Am* 1985;67(05):748–755
- Konishi E, Nakashima Y, Mano M, et al. Chondroblastoma of extra-craniofacial bones: clinicopathological analyses of 103 cases. *Pathol Int* 2017;67(10):495–502
- Ilaslan H, Sundaram M, Unni KK. Vertebral chondroblastoma. *Skeletal Radiol* 2003;32(02):66–71
- Kirchhoff C, Buhmann S, Mussack T, et al. Aggressive scapular chondroblastoma with secondary metastasis—a case report and review of literature. *Eur J Med Res* 2006;11(03):128–134
- de Silva MC, Reid R. Chondroblastoma: varied histologic appearance, potential diagnostic pitfalls, and clinicopathologic features associated with local recurrence. *Ann Diagn Pathol* 2003;7:205–213
- Maheshwari AV, Jelinek JS, Song AJ, Nelson KJ, Murphey MD, Henshaw RM. Metaphyseal and diaphyseal chondroblastomas. *Skeletal Radiol* 2011;40(12):1563–1573
- Lu C, Ramirez D, Hwang S, et al. Histone H3K36M mutation and trimethylation patterns in chondroblastoma. *Histopathology* 2019;74(02):291–299

- 12 Kyriakos M, Land VJ, Penning HL, Parker SG. Metastatic chondroblastoma. Report of a fatal case with a review of the literature on atypical, aggressive, and malignant chondroblastoma. *Cancer* 1985;55(08):1770–1789
- 13 Xie C, Jeys L, James SL. Radiofrequency ablation of chondroblastoma: long-term clinical and imaging outcomes. *Eur Radiol* 2015;25(04):1127–1134
- 14 Lalam RK, Cribb GL, Tins BJ, et al. Image guided radiofrequency thermo-ablation therapy of chondroblastomas: should it replace surgery? *Skeletal Radiol* 2014;43(04):513–522
- 15 Hong K, Georgiades C. Radiofrequency ablation: mechanism of action and devices. *J Vasc Interv Radiol* 2010;21(8 Suppl):S179–S186
- 16 Petsas T, Megas P, Papathanassiou Z. Radiofrequency ablation of two femoral head chondroblastomas. *Eur J Radiol* 2007;63(01):63–67
- 17 Rajalakshmi P, Srivastava DN, Rastogi S, Julka PK, Bhatnagar S, Gamanagatti S. Bipolar radiofrequency ablation of tibialchondroblastomas: a report of three cases. *World J Radiol* 2012;4:335–340
- 18 Tins B, Cassar-Pullicino V, McCall I, Cool P, Williams D, Mangham D. Radiofrequency ablation of chondroblastoma using a multi-tined expandable electrode system: initial results. *Eur Radiol* 2006;16(04):804–810
- 19 Goldberg SN, Gazelle GS, Compton CC, Mueller PR, Tanabe KK. Treatment of intrahepatic malignancy with radiofrequency ablation: radiologic-pathologic correlation. *Cancer* 2000;88(11):2452–2463
- 20 Erickson JK, Rosenthal DI, Zaleske DJ, Gebhardt MC, Cates JM. Primary treatment of chondroblastoma with percutaneous radiofrequency heat ablation: report of three cases. *Radiology* 2001;221(02):463–468
- 21 Rybak LD, Rosenthal DI, Wittig JC. Chondroblastoma: radiofrequency ablation—alternative to surgical resection in selected cases. *Radiology* 2009;251(02):599–604
- 22 Christie-Large M, Evans N, Davies AM, James SL. Radiofrequency ablation of chondroblastoma: procedure technique, clinical and MR imaging follow up of four cases. *Skeletal Radiol* 2008;37(11):1011–1017
- 23 Kulkarni SS, Shetty NS, Gala KB, et al. Percutaneous radiofrequency ablation of appendicular skeleton chondroblastoma—an experience from a tertiary care cancer center. *J Vasc Interv Radiol* 2021;32(04):504–509
- 24 Ruiz Santiago F, Castellano García MdelM, Guzmán Álvarez L, Martínez Montes JL, Ruiz García M, Tristán Fernández JM. Percutaneous treatment of bone tumors by radiofrequency thermal ablation. *Eur J Radiol* 2011;77(01):156–163
- 25 Ramappa AJ, Lee FY, Tang P, Carlson JR, Gebhardt MC, Mankin HJ. Chondroblastoma of bone. *J Bone Joint Surg Am* 2000;82(08):1140–1145
- 26 Atalar H, Basarir K, Yildiz Y, Ereku S, Saglik Y. Management of chondroblastoma: retrospective review of 28 patients. *J Orthop Sci* 2007;12(04):334–340
- 27 Purandare NC, Rangarajan V, Shah SA, et al. Therapeutic response to radiofrequency ablation of neoplastic lesions: FDG PET/CT findings. *Radiographics* 2011;31(01):201–213
- 28 Rivas R, Overbosch J, Kwee T, et al. Radiofrequency ablation of atypical cartilaginous tumors in long bones: a retrospective study. *Int J Hyperthermia* 2019;36(01):1189–1195
- 29 Antoch G, Vogt FM, Veit P, et al. Assessment of liver tissue after radiofrequency ablation: findings with different imaging procedures. *J Nucl Med* 2005;46(03):520–525
- 30 Dharia TP, Kulkarni SS, Shetty N, et al. Abstract No. 421 - Role of radiofrequency (RF) ablation as minimally invasive management of chondroblastoma. *J Vasc Interv Radiol* 2013;24(04):S178