Article published online: 2022-09-13

Gastrointestinal Emergencies and the Role of Endoscopy

Vinod Kumar Dixit[1] Manoj Kumar Sahu[2] Vybhav Venkatesh[2] Varanasi Yugandhar Bhargav[3] Vinod Kumar[1] Mayank Bhushan Pateriya[1] Jayanthi Venkataraman[3]

[1] Department of Gastroenterology, Institute of Medical Sciences, Banaras Hindu University, Varanasi, Uttar Pradesh, India
[2] Department of Gastroenterology and Hepatobiliary Sciences, Institute of Medical Sciences and SUM Hospital, Siksha 'O' Anusandhan (SOA) University, Bhubaneswar, Odisha, India
[3] Department of Hepatology, Sri Ramachandra Institute of Higher Education and Research, Chennai, Tamil Nadu, India

Address for correspondence Manoj Kumar Sahu, MD, DM, Department of Gastroenterology and Hepatobiliary Sciences, Institute of Medical Science and SUM Hospital, SOA University, Bhubaneswar, Odisha, India (e-mail: manojsahu427@gmail.com).

J Digest Endosc 2022;13:179–192.

Abstract

Many gastrointestinal (GI) disorders present to the emergency room with acute clinical presentations, some even life threatening. Common emergencies encountered that require urgent endoscopic interventions include GI hemorrhage (variceal and non-variceal), foreign body ingestion, obstructive jaundice, postprocedure-related complications such as postpolypectomy bleed or perforation, etc. A major advantage of emergency endoscopy is that it is cost effective and, on many occasions, can be life-saving. The present review will highlight a practical approach on various endoscopic modalities and their use in the GI emergencies.

Keywords
- endoscopy
- gastrointestinal hemorrhage
- foreign body
- obstructive jaundice

Acute Gastrointestinal Bleed

Acute upper gastrointestinal bleeding (UGIB) is a common medical emergency. In a fraction of the patients, the bleeding stops spontaneously.[1–3] However, in a subset, the bleed persists or recurs after initial control. These high-risk patients have significant mortality rates which can be reduced by the emergency endoscopic interventions. The cost effectiveness of the endoscopy and its related interventions have been shown by few researchers.[4,5]

There are several prognostic indices for UGIB that help the clinician for the purpose of patient stratification and management. While the popular Rockall score incorporates clinical parameters and endoscopy findings to predict mortality, the Glasgow-Blatchford score (GBS) is a pre-endoscopy score that predicts the need for any blood transfusion, endoscopy, or surgery. The Rockall score includes five components—age, shock, comorbidities, source of bleed, and stigmata of recent hemorrhage (SRH); while the GBS includes hemoglobin, blood urea nitrogen, systolic blood pressure, pulse rate, and presence or absence of comorbidities. The AIMS65 (albumin, international normalized ratio [INR], mental state, systolic blood pressure) score predicts the timing for endoscopy and mortality.[6] An international multicenter study involving 3,012 patients with UGIB compared the performance three pre-endoscopic scores to predict various outcomes.[7] In this study, a GBS $\leq$ 1 was best for directing patients to outpatient management and had a sensitivity of 98.6% with specificity of 34.6% for predicting survival without intervention. With a sensitivity of 80% and specificity of 57%, a GBS $\geq$ 7 was best to predict the need for endoscopic treatment. AIMS65 score of $\geq$ 2 and clinical

DOI https://doi.org/10.1055/s-0042-1755303.
ISSN 0976-5042.

© 2022. Society of Gastrointestinal Endoscopy of India. All rights reserved.
This is an open access article published by Thieme under the terms of the Creative Commons Attribution-NonDerivative-NonCommercial-License, permitting copying and reproduction so long as the original work is given appropriate credit. Contents may not be used for commercial purposes, or adapted, remixed, transformed or built upon. (https://creativecommons.org/licenses/by-nc-nd/4.0/)
Thieme Medical and Scientific Publishers Pvt. Ltd., A-12, 2nd Floor, Sector 2, Noida-201301 UP, India

Rockall score of ≥ 4 were optimal at predicting death, with sensitivities of 65.8 to 78.6% and specificities of 65.0 to 65.3%. The 10-point Progetto Nazionale Emorragia Digestiva (PNED) score proposed by the Italian group was found to have high discriminant capability and superior to Rockall score in predicting mortality in patients with nonvariceal UGIB, with PNED score > 8 having a positive likelihood ratio for mortality of 16.05.[8] The most recent one is the ABC (age, blood test, comorbidity) score to predict the 30-day mortality of patients with upper or lower GI bleed (LGIB; area under the receiver operating characteristic 0.81–0.84). A score of ≤ 3 was considered low risk, 4 to 7 as medium risk, and ≥ 8 as high-risk.[9] Studies on the utility of these scores in Indian patients are limited. In a study among 300 patients with UGIB (55.3% with variceal bleed) by Chandnani et al,[10] Rockall score was superior to others in predicting mortality (score ≥ 3 had sensitivity of 90% and specificity of 35%), while the PNED (score ≥ 1 had sensitivity of 91% and specificity- of 22%) was better for predicting rebleeding, and GBS was better for predicting need for blood transfusions or interventions (score of 2 had 98% sensitivity, 20% specificity for transfusion need; and score of 3 had 97% sensitivity with 31% specificity for predicting the need of interventions). Other Indian studies showed that these scoring systems perform well in patients with nonvariceal UGIB.[11,12]

General Considerations in the Management

Initial immediate assessment of hemodynamic status is of utmost importance followed by the prompt intravascular volume replacement. Placement of a nasogastric tube has limited diagnostic and prognostic value. Restrictive red blood cell transfusion strategy aims for a target hemoglobin between 7 and 9 g/dL. A randomized control trial (RCT) involving 921 patients with acute UGIB compared this restrictive versus liberal transfusion strategies and concluded that those in the restrictive group had less rebleeding rates (10% vs. 16%; hazard ratio [HR] 0.68, 95% confidence interval [CI]: 0.47–0.98) and better 6-week survival (95% vs. 91%: HR 0.55; 95% CI: 0.33–0.92).[13] Liberal red blood cell transfusion strategy (target hemoglobin of 9–11 g/dL or more) was reported to have poor outcomes in few studies.[14–16] A recent meta-analysis which included 1,965 participants reported that restrictive transfusion was associated with lower risk of all-cause mortality and rebleeding.[17] Most of the guidelines also recommend the use of restrictive transfusion strategy and imply that a higher threshold for transfusion should be considered in patients with comorbidities like ischemic heart disease. The data regarding this specific patient population is limited. A single RCT provided the subgroup analysis data on UGIB patients with and without cardiovascular disease which concluded that there was no difference between restrictive (hemoglobin threshold 8 g/dL) versus liberal transfusion (hemoglobin threshold 10 g/dL) with regards to mortality and rebleeding.[18] A recent international consensus guidelines recommend a higher threshold for transfusion ($<$ 8 g/dL) in UGIB patients with cardiovascular disease.[19] Endotracheal intubation is recommended in those requiring an upper GI endoscopy (UGIE) for ongoing active hematemesis, those agitated, or in a state of hepatic encephalopathy. Patients who are on antithrombotic therapy (-antiplatelet/anticoagulants) should be carefully assessed and the risk–benefit ratio should be taken into account regarding the decisions on continuation of therapy. The European Society for Gastrointestinal Endoscopy (ESGE) guidelines recommend to withhold aspirin temporarily and restart after 5 days if it was given for primary cardiovascular prophylaxis. If aspirin was started as monotherapy or in combination for secondary cardiovascular prevention, many guidelines recommend to continue its usage.[19–21] It is recommended that endoscopy should not be delayed in patients on anticoagulants, and coagulopathy should be corrected. In a study by Nagata et al, anticoagulant interruption did not affect risks and early endoscopy was found to be safe.[22] The recommendation from the ESGE guidelines state that all the anticoagulants need to be stopped temporarily and can be resumed within 1 week of hemostasis and can be bridged with heparin in patients with high risk of thromboembolism. Reversal of anticoagulation using vitamin K, prothrombin complex concentrates, or fresh frozen plasma and reversal agents for direct oral anticoagulants should be considered in case of hemodynamic instability.[20]

Upper GI Bleed

UGIB can be variceal or nonvariceal. This can be a life-threatening emergency carrying the risk of rebleed and mortality despite standard pharmacological and endoscopic management. In contrast to literature from northern and western India where variceal bleed is the most common cause of UGIB,[23–25] latest studies from eastern and southern India have shown peptic ulcer disease to be the leading cause of UGIB followed by variceal bleed, esophagogastric malignancy, erosive gastroduodenitis, and others.[26–28] The overall rebleed rates are high in the first 6 weeks.

Urgent versus Early Endoscopy

UGIE within 24 hours is referred to as early endoscopy (urgent, within 6 hours) and that performed beyond 24 hours is termed delayed/elective endoscopy. The GBS is suitable to triage patients for an urgent endoscopy. Those with higher score require early endotherapy and those with low GBS can be managed as outpatients. In a recent randomized trial among patients with acute UGIB at high risk for further bleeding or death (GBS $\geq$ 12), no difference in 30-day mortality was observed between urgent (within 6 hours) and early (within 6–24 hours) endoscopy groups (mortality rate 8.9% vs. 6.6%, $p = 0.34$).[29]

Nonvariceal Bleed

Gastric/Duodenal Ulcer

Patients should be initiated on high-dose intravenous proton-pump inhibitors, while awaiting UGIE. Intravenous metoclopramide or erythromycin (single dose, 250 mg given 30–120 minutes prior to UGIE) in those with severe or ongoing, active UGIB improves endoscopic visualization.

 © 2022. Society of Gastrointestinal Endoscopy of India. All rights reserved.

Forrest (F) classification is used in patients with peptic ulcer hemorrhage; management is based on the type of bleeding ulcer.[19] F1a or F1b ulcers are independent risk factors for persistent bleed or rebleed. In addition, large-size ulcer (> 2 cm), large-size nonbleeding visible vessel, presence of blood in the gastric lumen, and ulcer location on the posterior duodenal wall or the proximal lesser curvature of the stomach are other endoscopic features that predict adverse outcomes and/or endoscopic treatment failure.[30–32]

Management: For F1a and F1b ulcers, epinephrine injection is combined with a second hemostatic modality like contact thermal, mechanical therapy, or injecting a sclerosant. A Cochrane review concluded that combination of a second modality with epinephrine injection is superior to epinephrine monotherapy alone to reduce the risk of rebleeding (relative risk [RR] 0.53; 95% CI: 0.35–0.81) and the need for emergency surgery (RR 0.57, 95% CI: 0.43–0.76).[33] This review included 12 studies which compared epinephrine versus epinephrine plus second injected agent (like thrombin, fibrin glue, ethanolamine, ethanol, sodium tetradecyl sulfate, and polidocanol), 3 studies which compared epinephrine versus epinephrine plus thermal therapy (heat probe, bipolar electrocautery, and laser photocoagulation) and 4 studies that compared epinephrine versus epinephrine plus mechanical methods (band ligation and hemoclips). Through the scope (TTS) clips were specifically developed for use in endoscopic hemostasis of GI tract lesions and have been in use for many years. A meta-analyses by Baracat et al[34] looked at various RCTs which studied hemoclips versus other therapies for endoscopic hemostasis of peptic ulcer bleeding and concluded that hemoclip was superior to injection therapy in terms of rebleeding. Although TTS clips are relatively easy to use, clipping of large defects and access to the proper position are difficult at times. The cap-mounted clips or over the scope (OTS) clip (OSTC) are rescue/salvage options for uncontrolled bleed which were initially developed for endoscopic closure of GI perforations and fistulae. Compared with TTS clips, cap-mounted clips are able to compress a larger amount of tissue and hence can offer better hemostasis. Many prospective studies evaluated the role of OTSC as a primary hemostatic modality in nonvariceal UGIB with promising results and it was found to be useful in those with comorbidities like cardiovascular diseases or undergoing antithrombotic therapy.[35–39] A multicenter RCT (STING trial) comparing OTSC versus standard endoscopic therapy with TTS concluded that OTSC was superior to TTS clips in patients with recurrent peptic ulcer bleeds.[40] OTSC is usually recommended in ulcers > 2 cm, ulcers with a large visible vessel > 2 mm, or ulcers located in high-risk vascular area (gastroduodenal and gastric arteries). The hemospray is an inorganic mineral powder that binds to sites which are actively bleeding to achieve hemostasis and is washed away within 12 to 24 hours. It is found to be useful and cost effective in managing nonvariceal UGIB.[41] A systematic review of observational data found an immediate hemostasis rate of 90% but high rebleeding rates after therapy with hemospray. Another recent meta-analysis by Mutneja et al[42] included 11 prospective studies and found that the pooled immediate hemostasis rate was 93% and rebleeding rate was 14.4% with hemospray. If there is failure to control bleed by any of the methods hitherto mentioned, one may have to resort to transcatheter vascular embolization or even surgery. The endoscopic methods of hemostasis are summarized in ►**Table 1** and the Forrest classification-based management with rebleed rates is summarized in ►**Table 2**.[20,43]

Dieulafoy's Lesion

It is an uncommon cause of obscure UGIB (1–2%) which can be life threatening.[44] The most common site (80–95%) is along the lesser curve of the stomach within 6 cm of the gastroesophageal junction. The high prevalence along lesser curve is related to the vessel arising directly from the artery and not from the submucosal plexus that are seen in the rest of the stomach. The persistent artery has a width of 1 to 3 mm and has a tortuous course within the submucosa. The lesion protrudes through a small mucosal defect that is approximately 2 to 5 mm. A typical patient is an elderly male with multiple comorbidities, on drugs like warfarin and aspirin presenting with massive and/or recurrent GI bleed. The first line of evaluation is performing an UGIE. Occasionally, repeat endoscopy may be indicated in 16 to 20%.[15] For lesions beyond the stomach, enteroscopy, wireless capsule endoscopy (therapeutic intervention not possible), or a per-operative enteroscopy are the alternatives. Findings at endoscopy include a protruding vessel surrounded by normal mucosa, no associated ulcer, spurting or oozing of blood from the pin point defect (< 3 mm), or a clot without an ulcer. Endoscopic methods of hemostasis include combination of any of the two following modalities: *thermal coagulation*: electrocoagulation, heat probe coagulation, and argon plasma coagulation (APC); *local injection*: epinephrine or sclerotherapy; and *mechanical*: banding or placement of a hemoclip. Endoscopic hemostasis is effective in more than 90% instances and significantly reduces the mortality rate. Endoscopic ultrasound (EUS)-guided procedure ablates the aberrant vessel under direct vision and absence of blood flow confirms the success of the procedure.[45] Tattooing of the lesion is important in case of rebleeding and if surgery is contemplated.

Mallory-Weiss Tear

Repeated retching can cause a significant bleed and at times will require an emergency endoscopy. The bleed is best managed by mechanical therapy or thermal coagulation. The commonly used endoscopic methods for control of bleeding in Mallory-Weiss tear are injection therapy, APC, hemoclip placement, and band ligation.[46] Miscellaneous causes of bleed due to vascular ectasia, esophago-gastroduodenitis, or due to malignancy seldom requires an emergency intervention.

Post-Sphincterotomy Bleed

Complications following endoscopic sphincterotomy (ES) during endoscopic retrograde cholangiopancreatography (ERCP) include pancreatitis, bleeding, perforation, cholangitis, and adverse cardiopulmonary events with incidence

 © 2022. Society of Gastrointestinal Endoscopy of India. All rights reserved.

Table 1 Modalities of endoscopic hemostasis: mechanism and indications for use

Serial no.	Modality	Specifics	Mechanism of action	Indications for use
1.	Diluted epinephrine	1:10 000 or 1:20 000 with normal saline injected in 0.5–2-mL aliquots in and around the ulcer base	It has a local tamponade effect and produces local vasoconstriction	Gastric/duodenal ulcers, Mallory-Dieulafoy lesion, post-sphincterotomy bleed, diverticular bleeding, post-polypectomy bleeds
2.	Sclerosing agents	Absolute ethanol, ethanolamine, polidocanol	Produce hemostasis by causing direct tissue injury and thrombosis. The volume injected should be small because of concerns on tissue necrosis, perforation, pancreatitis	Gastric/duodenal ulcers, variceal bleeds
3.	Tissue adhesives	Thrombin, fibrin, cyanoacrylate glues	Endoscopic injection of these agents creates a primary seal at the site of bleed	Gastric/duodenal ulcers, variceal bleeds
4.	Thermal therapy	Contact: heater probes and bipolar electrocautery probes Noncontact: argon plasma coagulation (APC)	Heat generated from these devices leads to edema, coagulation of tissue proteins, contraction of vessels, and indirect activation of the coagulation cascade, resulting in a hemostatic bond	Gastric/duodenal ulcers, Dieulafoy's lesion, tumor bleeds, gastric antral vascular ectasia (GAVE), angiectasia, radiation proctitis
5.	Mechanical therapy	Through-the-scope (TTS) and over-the-scope (OTS) clips, band ligation devices	Endoscopic clips are deployed directly onto a bleeding site and typically slough off within days to weeks after placement. Hemostasis is achieved by mechanical compression of the bleeding site	Gastric/duodenal ulcers, Mallory-Weiss tear, Dieulafoy's lesion, diverticular bleeding, postpolypectomy bleeds
6.	Topical therapy	TC-325 (Hemospray)	Inorganic, absorbent powder that rapidly concentrates clotting factors at the bleeding site, forming a coagulum	Gastric/duodenal ulcers, tumor bleeds, post-endoscopic variceal ligation (EVL) ulcers, post-sphincterotomy bleeds

rates varying from 0.1 to 2%.[47] Post-ES bleed can be immediate (during the procedure) or delayed (postprocedure few hours to several days), and insignificant or life threatening. Immediate bleeding is more frequent than delayed bleeding. Risk factors for post-ES bleeding include coagulopathy, anticoagulation within 3 days of ES, cholangitis before ERCP, and bleeding during initial ES. Bleed rates are high in cirrhosis, periampullary diverticulum, precut sphincterotomy, and large bile duct stones.[48] Most bleeding episodes are managed successfully by prompt and appropriate resuscitative measures and management of comorbid conditions without the need for endotherapy. Preventive methods to reduce post-ES bleed include use of newer electrosurgical generators that incorporate feedback control (endo-cut), and prevents zipper cutting, performing balloon sphincteroplasty in patients with coagulopathy, maintaining a platelet count of $>50{,}000$ cells/mm^3 and an INR ≤ 1.5 in cirrhotic patients, and use of fresh frozen plasma in those on anticoagulants.

The options for endoscopic hemostasis mirror those techniques adopted for peptic ulcer bleed and include injection, thermal, and mechanical methods (endoclips), either alone or in combination. Thermal coaptive coagulation can be performed using bipolar or heater probe devices.[47,49]

Table 2 Endoscopic modalities according to Forrest classification

Stage	Rebleed without therapy	Endoscopic hemostasis technique	Initial hemostasis	Rebleed after therapy
Ia- Spurting Ib- Oozing	20–95%	Epinephrine injection + second modality (thermal/ mechanical therapy)	90–100%	0–30%
IIa- Nonbleeding visible vessel	30–50%	Thermal/ mechanical therapy, or injection of a sclerosing agent, each as monotherapy or in combination with epinephrine injection	90–100%	5–30%
IIb- Adherent clot	25–50%	Controversial: Clot removal followed by endoscopic hemostasis or medical management	90–100%	5–20%
IIc- Flat/pigmented spot III- Clean base ulcer	3–10%	Low risk No endoscopic hemostasis required	–	–

 © 2022. Society of Gastrointestinal Endoscopy of India. All rights reserved.

Injection of dilute epinephrine into and around the sphincterotomy site is the simplest and ideal. Caution must be exerted in patients with underlying coronary artery disease or cardiac arrhythmias. There are limited data on the use of clips for post-ES hemostasis. Balloon tamponade is a commonly employed modality to control post-ES bleed.[47,50] The use of self-expanding metal stents to control refractory bleeds has provided another tool in the armamentarium.[47] With the availability of various endoscopic modalities of intervention, the mortality rate of post-ES bleeding, is currently < 0.1%.

Hemobilia

This refers to extravasated gross blood in the biliary system from venous or arterial source and is an important cause of massive UGIB, requiring an emergency intervention. It is an important differential for obscure GI bleed. Common causes are iatrogenic, trauma, gallbladder and bile duct stones, and biliary neoplasia.[51,52] The classic presentation of hemobilia is jaundice, right upper quadrant abdominal pain, and UGIB. Post-ERCP hemobilia presents either immediately or within few days after the inciting duct injury (e.g., sphincterotomy or stricturoplasty). Primary endoscopic interventions aim at achieving hemostasis and maintaining bile flow. Patients presenting with minor hemobilia are managed conservatively with intravenous fluids and correction of coagulopathy. Major hemobilia requires hemodynamic stabilization and institution of urgent advanced endoscopic, interventional radiologic, or surgical intervention. UGIE with direct visualization of blood or clot emerging from the biliary tract confirms the diagnosis. ERCP offers therapeutic intervention, especially removal of the blood clots that appear as amorphous, tubular, or cast-like filling defects within the bile duct. Blood clots within the biliary tree predisposes to obstructive jaundice, cholangitis, cholecystitis, and pancreatitis. EUS is complementary and assists in evaluation of vascular aneurysms, portal biliopathy-related bleed in addition to identifying blood clots in the biliary tree when ERCP findings are equivocal.

Endoscopic techniques to achieve hemostasis depend on the site of bleed. For bleed at the level of ampulla (e.g., post-sphincterotomy hemobilia), treatment options include spraying diluted epinephrine over the area of hemorrhage, or any of the hemostatic modalities already mentioned. Bleed occurring proximally (e.g., perihilar bleed), requires extraction of intraductal clots using extraction balloon catheters and retrieval baskets followed by stent deployment. Stents, especially fully covered self-expanding metallic stents (SEMS) achieve a tamponade effect, maintain luminal patency and bile flow, and serve as a salvage therapy to interventional radiology or surgery.

Variceal Bleed

Esophageal Variceal Bleed

This is a major complication of portal hypertension with high morbidity and mortality. The risk of bleeding depends on the size, presence of red color signs (RCS), and the degree of liver dysfunction. Esophageal varices are classified as small (< 5 mm) and low-risk (without RCS) or large (> 5 mm) and high-risk (with RCS).[53] The recent classification has reclassified fundal varices as lesser curve, cardio-fundal, and distal gastric varices.[54] Bleeding within 5 days of presentation is considered as an acute variceal bleeding (AVB) episode and is due to a rise in hepatic venous pressure gradient (HVPG), an independent predictor of variceal bleed, which persists up to 5 days after endotherapy. Rebleed is defined as the bleeding after 5 days of the index episode.

Management: Maintenance of airway, breathing, circulation, and assessment of severity are very important for the management of AVB. Restrictive blood transfusion strategy is recommended for all UGIB including variceal bleed.[13] Endoscopic management along with pharmacotherapy is the standard of care for managing AVB. Current recommendation is combining vasoactive drugs (terlipressin/octreotide/somatostatin) for 2 to 5 days,[55] prophylactic antibiotics, and endoscopic procedures (►**Fig. 1**). Early endoscopy is recommended for AVB within 12 hours, once resuscitation is adequate. Endoscopic variceal ligation (EVL) is the preferred modality (►**Fig. 2A**), and endoscopic sclerotherapy is reserved when EVL is not technically feasible. HVPG has a good predictive value for rebleed after initial control and is ideal to guide further therapy. Salvage procedures include early transjugular intrahepatic portosystemic shunt (TIPS) in those with high risk of variceal bleed (HVPG > 20 or active bleeding during endoscopy). In desperate situations, Sengstaken-Blakemore tube can be used and kept for a maximum of 24 to 48 hours. Fully covered SEMS (Ella Danis) is increasingly being used with the same indication.[56] Hemostatic powders have been used for post-EVL ulcers, and currently are used as a bridging therapy until definitive endoscopy is possible.[57] The only validated option when hemospray is not available, is injection of cyanoacrylate beneath the ulcer base in conjunction with pharmacotherapy. TIPS is considered the definitive rescue for failure of endoscopic therapy to control variceal bleeding.

Gastric Variceal Bleeding

Gastric variceal bleeding (GVB) tends to be more severe, requires more transfusions, and is associated with higher mortality. The current management strategies include pharmacotherapy, endotherapy, TIPS, balloon-occluded retrograde transvenous obliteration (BRTO), and surgical intervention. Endoscopic therapy mainly consists of cyanoacrylate injection to achieve hemostasis.[58] When this fails, TIPS or BRTO may be considered. Both are safe and effective interventional treatments in the management of GVB. EUS-guided coiling with or without cyanoacrylate injection may also be useful, but needs more evidence.[59,60]

Lower GI Bleed

LGIB accounts for 20 to 30% of cases of GI bleed, and in majority, the bleed stops spontaneously.[61] While diverticular bleeding is the most common cause of LGIB in Western countries, colorectal polyps/malignancies and colitis are the

 © 2022. Society of Gastrointestinal Endoscopy of India. All rights reserved.

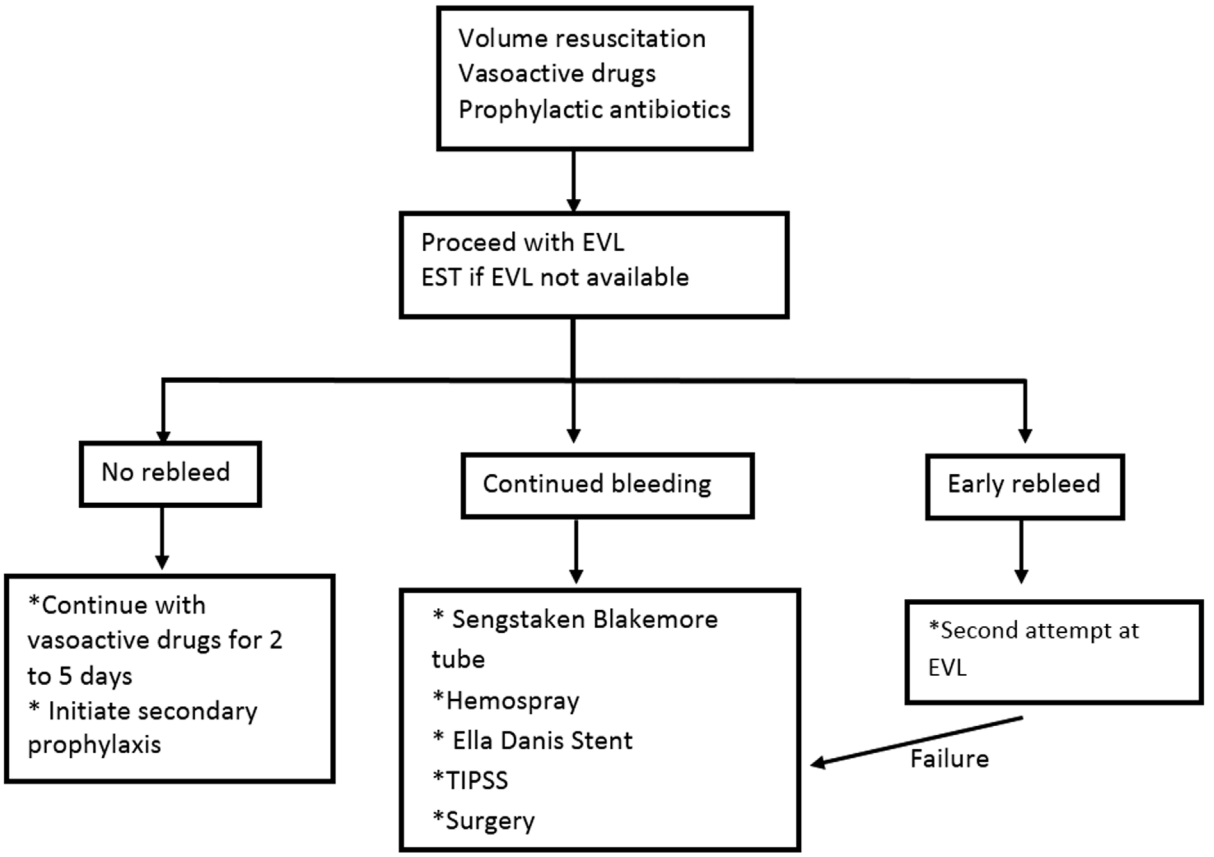

Fig. 1 Approach to suspected variceal bleed.

common causes in tropical countries.[61] The general principles of initial management and resuscitation apply for LGIB as well. In contrast to UGIB, the risk stratification scores are not well validated in patients with LGIB. Patients with a shock index (heart rate/systolic blood pressure) of > 1 are classified as having unstable LGIB as per the British guidelines and the index also predicts extravasation of contrast on angiography in patients with LGIB and can identify patients with active bleed.[62] A recently proposed and validated Oakland score[63,64] includes variables like age, gender, previous hospital admission with LGIB, blood on digital rectal examination, heart rate, systolic blood pressure, and hemoglobin. A cutoff of 8 points in Oakland score can help in triaging patients with LGIB (≤ 8, minor bleed–can be discharged, > 8, major bleed–requires hospitalization and evaluation). Few guidelines recommend that those with high-risk clinical features (such as hemodynamic instability at presentation, comorbid illnesses, age > 60 years, a history of diverticulosis or angiectasia, elevated creatinine) and signs of ongoing bleed should undergo early colonoscopy.[61,62,65] Nevertheless, the need for urgent colonoscopic evaluation should be decided on case-to-case basis. The optimal timing of colonoscopy remains controversial. The results from recent RCTs and meta-analyses show that though that early colonoscopy (within 24 hours) improves the identification of the bleeding source, there is no clear evidence that it reduces important rebleeding rates or mortality compared with elective colonoscopy (after 24 hours).[66–69]

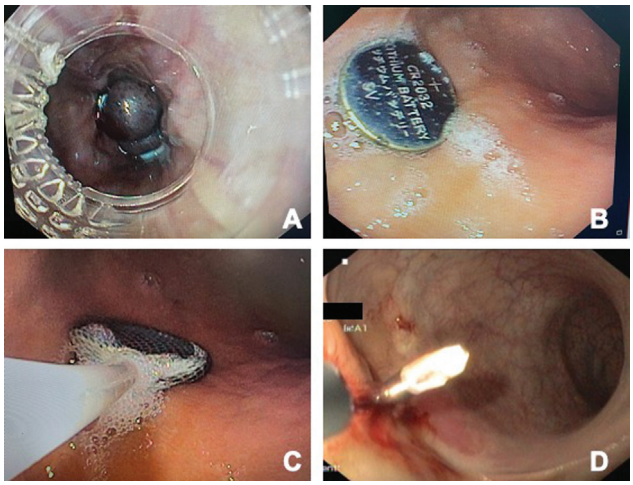

Fig. 2 Endoscopy in some gastrointestinal (GI) emergencies. (**A**) Endoscopic variceal ligation (EVL) in a case of upper GI bleed. (**B**) Disk battery in stomach. (**C**) Retrieval using Roth net. (**D**) Clipping in a case of postpolypectomy bleed.

Colonic Diverticular Bleed

Colonic diverticular bleeding is the most common cause of overt LGIB in adults. In most cases, the bleed stops spontaneously. However, if the bleeding persists, endoscopic intervention may be required. Hematochezia due to colonic diverticulosis is often an acute-onset painless bleed. Evaluation includes a detailed history and physical examination,

 © 2022. Society of Gastrointestinal Endoscopy of India. All rights reserved.

details of medication, comorbid states (chronic kidney disease, cirrhosis, hypertension, diabetes), and baseline laboratory tests. Rebleed rates and risk of thromboembolism are high in those on antiplatelet or anticoagulants.

All patients with acute LGIB due to colonic diverticular disease who either have continuous or rebleed after admission need to be triaged to either endotherapy, arterial embolization, or colectomy. Bowel preparation with oral lavage is recommended before the colonoscopic procedure. Cecal intubation is low in those with an unprepared colon. Most diverticula bleed either from the base or neck of the diverticulum due to damage to the vasa recti. Right-sided visualization of the colon is important as most lesions that bleed are from the wide-mouthed diverticulum.[70] Colonoscopy evidence of active bleed or stigmata of recent hemorrhage (nonbleeding vessels, underlying adherent clot, and their combinations) require endoscopic hemostasis. Rebleed rates are high if hemostasis is not achieved by endoscopic or radiological maneuvers. The yield of picking up SRH improves by doing colonoscopy within 24 hours, ensuring adequate preparation with oral colonic lavage and using endoscopic water jet attached to the scope. Endoscopic hemostasis is the first-line treatment for colonic diverticular bleeding and the methods include epinephrine injection, coagulation, clipping, and ligation (endoscopic band ligation and detachable snare ligation) and more recently the use of OTS system.[71] Epinephrine injection is indicated when the opening is small and the base is large and eversion of the diverticulum is difficult. Epinephrine on its own increases rebleed rate and hence given as a combination with other tamponade procedures like ligation. Coagulation current is not recommended when bleeding occurs from the base of the diverticulum. Clipping can be either closure of the mouth of diverticula or direct clipping of the vasa recta. It is indicated when the diverticulum opening is wide. Alternative to clipping is achieving mechanical ligation by either direct endoscopic band ligation or use of a detachable snare ligation and these are also indicated for rebleeds.[72,73] Anticoagulant and platelet therapy that has been discontinued temporarily is to be resumed within 7 days; thereby reducing the risk of thromboembolism. It can be initiated when bleed is controlled. Arterial embolization is indicated when endoscopic methods fail, when bleed is massive, and failure to achieve hemostasis. Overall, while initial hemostasis and rebleed rates are similar between the hemostatic procedures, conversion to arterial embolization/surgery is least after ligation and highest in those after coagulation therapy. Perforation is common after ligation while clipping results in a high percentage of septicemia.[70,71,74]

Postpolypectomy Bleed

Bleed following polypectomy occurs either immediately or several hours to weeks after the procedure due to either sloughing of the eschar or widening areas of necrosis due to thermal injury. The bleed can be significant due to an arterial spurt or can present as a minor ooze. Depth of injury can occasionally extend even into the submucosal layer. The risk of delayed bleed is higher in those with polyps > 2 cm, polyps located in the right side of the colon, and on drugs (warfarin, aspirin, etc.). Significant bleed with hemodynamic instability requires hospitalization, prompt resuscitation with blood transfusion, correction of coagulopathies, and an urgent endoscopic intervention.

Emergency colonoscopy after a polyethylene glycol preparation is recommended in those with ongoing bleed. Most bleeds can be controlled endoscopically. The role of prophylactic clipping is debatable and should be individualized taking the risk factors into account.[75–77] A multicenter RCT comparing the use of prophylactic clipping versus endoloop found no differences in bleeding rates.[78] A recent multicenter retrospective analysis concluded that prophylactic endoloop application was high likely to inhibit immediate bleeding with polyp size $\geq$ 15 mm.[79] For immediate bleeds (occurring during or soon after the procedure), injection of diluted adrenaline and placement of a hemoclip is preferred (►**Fig. 2D**).[80] For postpolypectomy bleed (PPB) in a pedunculated polyp, the residual pedicle is grasped with a snare and pressure is applied for approximately 5 minutes (tamponade effect). Failure to control bleed necessitates submucosal injection of diluted adrenaline followed by hemoclip, that is applied directly over the bleeding site or of the residual stalk. In those with no stalk postpolypectomy or those with PPB from a sessile polyp, thermocoagulation (heater probe, tip of polypectomy snare) should be considered with or without injection of epinephrine. Other methods include APC and band ligation. Delayed PPB is managed on similar lines as early bleed with the use of hemoclips, thermocoagulation with or without the need for submucosal adrenaline injection, or a hemospray. The injected adrenaline often undergoes dilution due the inflammatory response following polypectomy and hence may not be effective in maintaining hemostasis. Hemospray can be used as monotherapy or in combination with other methods.

Small Bowel Bleed

Small bowel bleed (SBB) is relatively uncommon accounting for 5 to 10% of all GI bleeds and indicates that the source of bleeding is anatomically situated distal to ampulla of Vater till the proximal ileocecal valve.[81] It can be occult (insidious, iron deficiency anemia $\pm$ positive fecal occult blood test) or overt (melena, hematemesis, hematochezia) and the causes include angiectasia/angiodysplasia, Dieulafoy's lesion, inflammatory bowel disease, neoplasia, nonsteroidal anti-inflammatory drug-induced ulcers, polyposis syndromes, blue rubber bleb syndrome, among others. A detailed description of SBB is beyond the scope of this review and hence only salient points are discussed and a simplified approach is depicted in ►**Fig. 3**. Localization of SBB might be a tedious process but with the availability of different endoscopic modalities like double-balloon enteroscopy (DBE), single-balloon enteroscopy (SBE), video capsule endoscopy (VCE), and spiral enteroscopy (SE) the diagnosis could be achieved in most of the cases. A second-look endoscopy should be done as it is observed that 15 to 20% of patients have an upper or lower GI source of bleeding which could have been missed

 © 2022. Society of Gastrointestinal Endoscopy of India. All rights reserved.

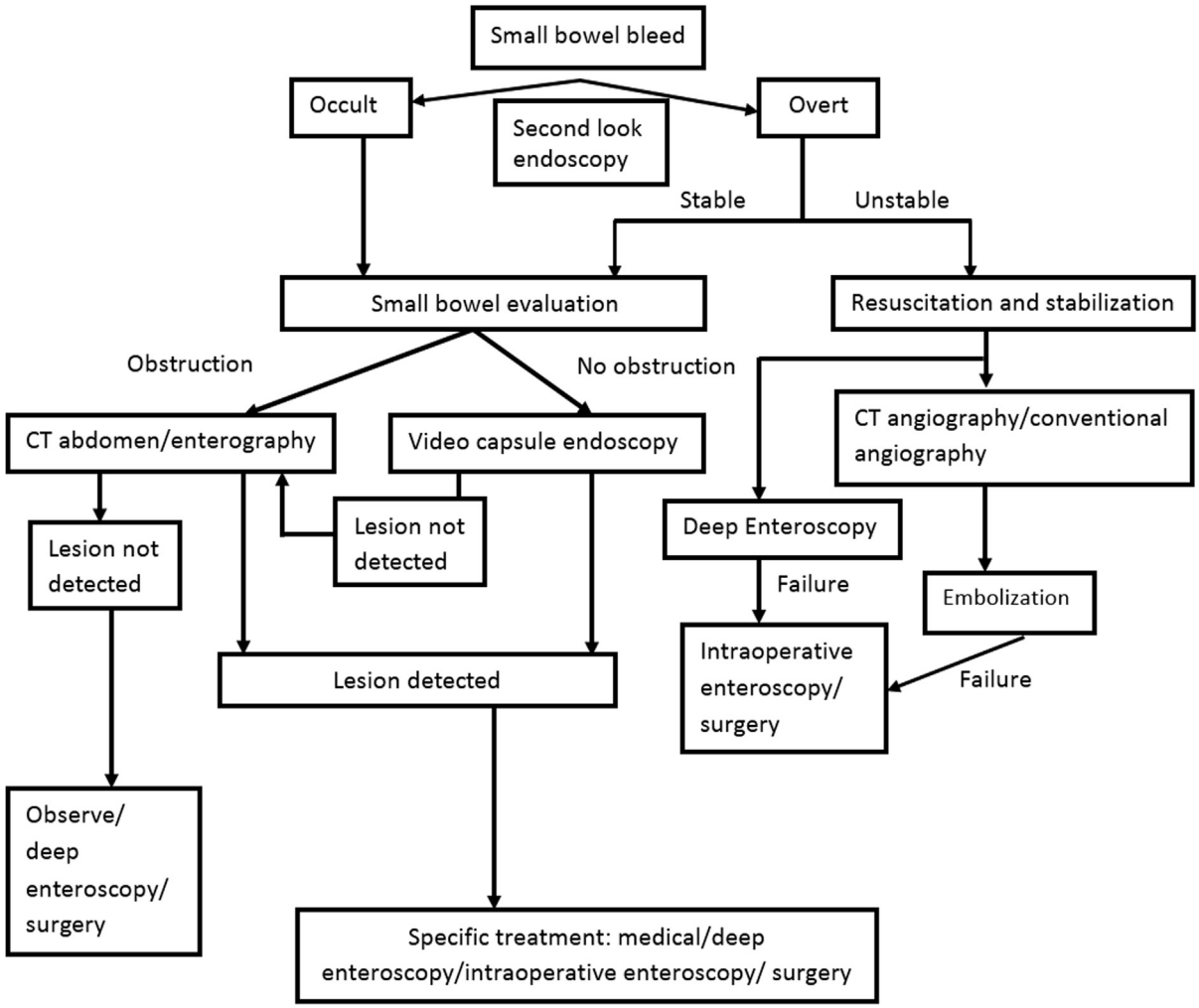

Fig. 3 Approach to small bowel bleed.

in the initial endoscopy evaluation.[82] VCE allows noninvasive evaluation of the entire small bowel in 79 to 90% of patients, with a diagnostic yield of 38 to 83% in patients with suspected small bowel bleeding.[81] It is very well tolerated by patients and the main complication is capsule retention in a fraction. A meta-analysis of 14 studies comparing the yield of VCE with push enteroscopy for evaluation of SBB reported higher diagnostic yield for VCE (63% vs. 28%, $p < 0.01$) and it had a higher yield for detection of vascular and inflammatory lesions than tumors.[83] Radiographic investigations commonly used in the evaluation of SBB include computed tomography (CT) enterography and CT angiography. CT enterography can be performed in patients with negative VCE because of higher sensitivity for the detection of mural-based small bowel masses and should also be considered prior to VCE in patients with suspected obstruction/stenosis (inflammatory bowel disease, prior radiotherapy, previous bowel surgery). In a meta-analysis of 18 studies, CT enterography had a pooled yield of 40% compared with 53% for VCE.[84] CT angiography is usually performed to detect the site of active bleeding in cases of acute overt bleeding and was reported to detect bleeding rates as slow as 0.3 mL/min. In a meta-analysis of 9 studies with 198 patients showed CT angiography had a pooled sensitivity of 89% and specificity of 85% in diagnosing acute GI bleeding.[85] The major limitation of CT angiography is that therapeutic intervention cannot be performed on identification of lesion which can be overcome using the newer endoscopic techniques. DBE, SBE, and SE are deep enteroscopy techniques which allow for the better visualization of small bowel that require an overtube for the scope advancement, and allow to perform therapeutic procedures at the same time. The diagnostic yield of these endoscopic techniques ranges from 60 to 80%.[81,86–88] More recently, a novel motorized SE technique with a diagnostic yield of 66% for evaluation of small bowel disease was described by Ramchandani et al.[89]

Cholangitis

The most common cause for cholangitis is choledocholithasis. The prevalence of common bile duct stones (CBDS) in patients with symptomatic gallstones is 10 to 20% and less than 5% in asymptomatic individuals.[90,91] Complications of CBDS are potentially life threatening and include pain, partial

 © 2022. Society of Gastrointestinal Endoscopy of India. All rights reserved.

or complete biliary obstruction leading to obstructive jaundice, cholangitis, hepatic abscesses, pancreatitis, and rarely secondary biliary cirrhosis. Small CBDS (< 5 mm) pass spontaneously into the duodenum.

The effective treatment for CBDS is therapeutic ERCP. Biliary drainage, preferably endoscopic in settings of acute cholangitis should be elective in mild, within 48 to 72 hours in moderate, and as soon as possible (within 12 hours) in severe cases of acute cholangitis.[92,93] Failure of biliary drainage is an ominous sign, particularly in severe cases and one may have to resort to percutaneous drainage. For large CBDS, endoscopic papillary balloon dilatation with balloon > 10 mm in diameter is safe and effective technique.[94] The procedure is completed with balloon stone extraction and/or mechanical lithotripsy at a later date. ES with stone extraction is successful in 80 to 90% of cases. In hemodynamically stable patients presenting with cholangitis, balloon and basket catheters are used for CBDS removal. In situations when the CBDS cannot be completely removed, plastic stent is deployed to facilitate adequate biliary drainage. Studies have shown that an indwelling stent may reduce the volume and number of stones possibly by streamlining friction between plastic stent and stones.[95] ES and balloon dilation reduces the need for mechanical lithotripsy by approximately 30 to 50% in comparison with ES alone.[96] For patients above 70 years of age, those with comorbidities like coronary artery disease on anticoagulants and antiplatelets, biliary stenting alone is recommended and endoscopic stone extraction is done when general condition stabilizes. A quarter of patients experience recurrent cholangitis during follow-up. Difficult CBDS are those which are > 1.5 cm in diameter, unusual shape or location (intrahepatic or cystic duct), anatomical factors such as narrow CBD distal to stone, sigmoid shape CBD, stone impaction, shorter length of distal CBD, or acute distal CBD angulation (< 135°).[97]

Acute Gallstone Pancreatitis

The duration of bile duct obstruction is a critical factor contributing to the severity of pancreatitis. Pancreatic necrosis occurs when the duration of obstruction exceeds 48 hours. Magnetic resonance cholangiopancreatography is a useful modality in the diagnosis of biliary obstruction. EUS is an ideal alternative especially for microliths and small CBDS (< 5 mm). In the recent prospective, multicenter, randomized superiority trial in which 232 patients with predicted severe gallstone pancreatitis were assigned to undergo urgent ERCP with biliary sphincterotomy (≤ 24 hours after presentation) or conservative therapy (on-demand ERCP for cholangitis or for persistent cholestasis or retained bile duct stones after recovery from the initial pancreatitis). The primary endpoint was a composite of mortality or major complications (new-onset persistent organ failure, cholangitis, bacteremia, pneumonia, pancreatic insufficiency, or pancreatic parenchymal necrosis) within 6 months. There was no difference in the primary endpoint in patients who underwent urgent ERCP or conservative therapy (38% vs. 44%; $p = 0.37$). Urgent ERCP is an ideal, less invasive method to clear the bile duct and is usually indicated in severe gallstone pancreatitis with deranged liver function test and signs of cholangitis, and failure of the patient's condition to improve within 48 hours despite adequate therapy.[98] There are several guidelines that serve the physicians as a guide toward an emergency ERCP.[98–100]

Foreign Body Removal

Foreign body (FB) in the GI tract can be a true FB or a food bolus impaction. FB ingestion accounts for approximately 4% of all urgent endoscopies. True FB ingestion is commonly encountered in pediatric population, whereas food bolus impaction is mostly seen in adults. Most ingested FBs pass spontaneously, 10 to 20% require endoscopic removal (►**Fig. 2B, C**), and less than 1% need surgical intervention.[101] UGIE is performed under conscious sedation and general anesthesia with endotracheal intubation is required in difficult cases to ensure airway protection. Double-channel endoscopes, small-caliber endoscopes, and enteroscopes are required in specific settings. Numerous retrieval devices are available which are wisely chosen depending on FB characteristics. Timing of endoscopic removal is *emergent* (immediate) for esophageal obstruction due to disk battery and sharp-pointed objects in the esophagus, *urgent* (within 24 hours) for esophageal objects that are not sharp and pointed, magnets within endoscopic reach, esophageal food impaction without complete obstruction, and objects > 6 cm at or above the duodenum, and *nonurgent* for coins, objects in the stomach > 2.5 cm in diameter.[102,103] Special equipment (overtube, hood, transparent distal cap) can be used to protect the airways and the mucosa in case of sharp, pointed, or bulky FBs. When the food bolus is in view, extraction is favored over pushing blindly into the stomach. En bloc or piecemeal extraction, using the most appropriate device available, is the recommended technique.[104] If the pushing technique is attempted, then pressure on the central part of the bolus is the safer way. Pushing is contraindicated due to the risk of perforation and stent migration in cases of food bolus impaction in a stent. FBs larger than 2 to 2.5 cm in diameter or longer than 5 to 6 cm must be extracted before they pass the pylorus as the risk of perforation is high (15–35%). Endoscopic extraction of body packing of drugs is not recommended because the rupture of the package which can lead to fatal overdose and surgery is recommended.[105] Perforation, obstruction, infection, hemorrhage, fistula, and FB migration through the digestive wall can occur in 1 to 5% of cases of which esophageal perforation is the most frequent complication.

Corrosive Ingestion

Corrosive ingestion (strong alkalis and acids) at times can be devastating and requires aggressive emergency management which ultimately determines the patient outcome. The determinants of degree of injury include the physical form (solid or liquid), quantity ingested, and whether taken accidently or with suicidal intent. Massive ingestion of either acids and alkalis causes extensive necrosis of the GI tract.

 © 2022. Society of Gastrointestinal Endoscopy of India. All rights reserved.

Endoscopy is the mainstay of management algorithms following caustic ingestion when CT details are not available or there is uncertainty on degree of necrosis. The rationale behind endoscopy is to evaluate the severity of tissue damage, detect prognosis, and indicate management plans. While the patient should undergo endoscopy within 24 hours of ingestion, early endoscopy, within < 6 hours following ingestion, may not demonstrate the full picture of injury, and late endoscopy, after 4 days of exposure, increases the risk of perforation.

Perforations

Esophagus is a common site for perforation. Spontaneous esophageal perforation (Boerhaave syndrome) accounts for 15% of esophageal perforations and is located along the left border of the lower third of the thoracic esophagus and the size of the defect ranges from 3 to 8 cm.[106] Most perforations are iatrogenic in origin (60%) and occur during a diagnostic or therapeutic endoscopic procedure. Uncommon causes include FBs, caustic injury, postoperative, external injury, and rarely malignancy. An emergency endoscopy is indicated when CT is nonconfirmative and diagnosis is uncertain. Endoscopy should be done with caution not to increase the size of perforation and contaminate the surrounding space. Endoscopic treatment is the first line of management for closing esophageal perforation that is identified during the procedure.[107] Use of endoscopic clips, covered metal stents, and endoluminal vacuum therapy have significantly reduced the morbidity and mortality.[108] Endoscopic clip placement is currently the standard method for closing small (< 2 cm) luminal perforations.[109] Endoscopic stents (partially or fully covered SEMS, self-expandable plastic stents) can be used to cover larger defects or complete an unsatisfactory clip closure.[110] While endoscopy remains the definitive procedure, radiological or surgical intervention is required in those with pnemo-/hydrothorax or pleural effusion. Endoluminal vacuum therapy is a promising alternative treatment for esophageal perforation.[111]

Miscellaneous

GI tumor-related bleeds account for 12 to 15% of cases of acute GI bleed. Endoscopically, these cases might be difficult to manage because of large, oozing bleeds from fragile vessels caused by neoangiogenesis.[112] Clips are of limited value because the fragility of the tumoral tissue. Thermal therapy including APC, endoloops, and injection therapy have all been tried with limited success rates in achieving initial hemostasis and high rebleeding rates. Hemostatic sprays have been used in the recent times with promising results from few studies.[113–115] Endoscopic decompression has been utilized in managing patients with volvulus and the recent guidelines[116] recommend nonoperative detorsion with flexible sigmoidoscopy with or without placement of a decompression tube as a first-line therapy in the management of uncomplicated sigmoid volvulus. However, the recurrence rates are as high as 80% after successful endoscopic decompression.[116] For those with perforation, peritonitis, recurrence, or unsuccessful nonoperative decompression, surgical management is warranted. In cases of acute colonic pseudo-obstruction, limited data suggest that colonoscopic decompression might be superior to neostigmine.[117,118] Colonic stenting is a modality which can be used in acute malignant colonic obstructions as a bridge to surgery or palliative therapy. In a RCT involving 98 patients, colonic stenting was found to have no decisive clinical advantages over emergency surgery in patients with acute left-sided malignant colonic obstruction.[119] However, an updated meta-analysis which included a total of 448 patients found that colonic stenting as a bridge to surgery appears to be a safe approach to malignant large bowel obstruction.[120] Laparoscopic cholecystectomy is now considered the standard approach for treatment of acute calculus cholecystitis. In patients unfit for surgery, nonoperative management is typically advised with antibiotic therapy and gallbladder drainage. EUS-guided gallbladder drainage using self-expandable stents is an emerging modality which can be used in this set of patients and found to have similar clinical success rates and adverse events compared with percutaneous drainage.[121,122]

To summarize, endoscopy and related interventions hold an important place in management of many GI emergencies. Endoscopy has already become an indispensable tool for managing common GI disorders. In the recent years, emergency endotherapy has surpassed many of the earlier more invasive surgeries for complications like massive GI bleed, perforations, etc., and today remains as the mainstay in major GI and hepatobiliary pancreatic complications.

Authors' Contributions
V.K.D. - data curation, writing-original draft, writing-editing and review; M.K.S. - concept, methodology, data curation, methodology, formal analysis, writing-original draft, writing-editing and review, resources, supervision, administration; V.V. - methodology, investigation, writing-original draft, writing-editing and review; B.V.Y., V.K., M.B.P., and J.V. - data curation, investigation, resources, and writing-editing and review.

Funding
None.

Conflict of Interest
None declared.

References

1 Peter DJ, Dougherty JM. Evaluation of the patient with gastrointestinal bleeding: an evidence based approach. Emerg Med Clin North Am 1999;17(01):239–261, x
2 Manning-Dimmitt LL, Dimmitt SG, Wilson GR. Diagnosis of gastrointestinal bleeding in adults. Am Fam Physician 2005; 71(07):1339–1346
3 Gralnek IM, Dumonceau JM, Kuipers EJ, et al. Diagnosis and management of nonvariceal upper gastrointestinal hemorrhage: European Society of Gastrointestinal Endoscopy (ESGE) Guideline. Endoscopy 2015;47(10):a1–a46

 © 2022. Society of Gastrointestinal Endoscopy of India. All rights reserved.

4 Lee JG, Turnipseed S, Romano PS, et al. Endoscopy-based triage significantly reduces hospitalization rates and costs of treating upper GI bleeding: a randomized controlled trial. Gastrointest Endosc 1999;50(06):755–761
5 Barkun AN. Emergency endoscopy cover: cost and benefits? Gut 2010;59(08):1012–1014
6 Hyett BH, Abougergi MS, Charpentier JP, et al. The AIMS65 score compared with the Glasgow-Blatchford score in predicting outcomes in upper GI bleeding. Gastrointest Endosc 2013;77(04): 551–557
7 Stanley AJ, Laine L, Dalton HR, et al; International Gastrointestinal Bleeding Consortium. Comparison of risk scoring systems for patients presenting with upper gastrointestinal bleeding: international multicentre prospective study. BMJ 2017;356:i6432
8 Marmo R, Koch M, Cipolletta L, et al; Italian registry on upper gastrointestinal bleeding (Progetto Nazionale Emorragie Digestive–PNED 2) Predicting mortality in non-variceal upper gastrointestinal bleeders: validation of the Italian PNED Score and Prospective Comparison with the Rockall Score. Am J Gastroenterol 2010;105(06):1284–1291
9 Laursen SB, Oakland K, Laine L, et al. ABC score: a new risk score that accurately predicts mortality in acute upper and lower gastrointestinal bleeding: an international multicentre study. Gut 2021;70(04):707–716
10 Chandnani S, Rathi P, Sonthalia N, et al. Comparison of risk scores in upper gastrointestinal bleeding in western India: a prospective analysis. Indian J Gastroenterol 2019;38(02):117–127
11 Sharma V, Jeyaraman P, Rana SS, et al. Utility of clinical and complete Rockall score in indian patients with upper gastrointestinal bleeding. Trop Gastroenterol 2016; 37(04):276–282
12 Rout G, Sharma S, Gunjan D, Kedia S, Nayak B, Shalimar . Comparison of various prognostic scores in variceal and non-variceal upper gastrointestinal bleeding: a prospective cohort study. Indian J Gastroenterol 2019;38(02):158–166
13 Villanueva C, Colomo A, Bosch A, et al. Transfusion strategies for acute upper gastrointestinal bleeding. N Engl J Med 2013;368 (01):11–21
14 Restellini S, Kherad O, Jairath V, Martel M, Barkun AN. Red blood cell transfusion is associated with increased rebleeding in patients with nonvariceal upper gastrointestinal bleeding. Aliment Pharmacol Ther 2013;37(03):316–322
15 Hearnshaw SA, Logan RFA, Lowe D, Travis SPL, Murphy MF, Palmer KR. Acute upper gastrointestinal bleeding in the UK: patient characteristics, diagnoses and outcomes in the 2007 UK audit. Gut 2011;60(10):1327–1335
16 Marik PE, Corwin HL. Efficacy of red blood cell transfusion in the critically ill: a systematic review of the literature. Crit Care Med 2008;36(09):2667–2674
17 Odutayo A, Desborough MJR, Trivella M, et al. Restrictive versus liberal blood transfusion for gastrointestinal bleeding: a systematic review and meta-analysis of randomised controlled trials. Lancet Gastroenterol Hepatol 2017;2(05):354–360
18 Jairath V, Kahan BC, Gray A, et al. Restrictive versus liberal blood transfusion for acute upper gastrointestinal bleeding (TRIGGER): a pragmatic, open-label, cluster randomised feasibility trial. Lancet 2015;386(9989):137–144
19 Barkun AN, Almadi M, Kuipers EJ, et al. Management of non-variceal upper gastrointestinal bleeding: guideline recommendations from the international consensus group. Ann Intern Med 2019;171(11):805–822
20 Gralnek IM, Stanley AJ, Morris AJ, et al. Endoscopic diagnosis and management of nonvariceal upper gastrointestinal hemorrhage (NVUGIH): European Society of Gastrointestinal Endoscopy (ESGE) Guideline - Update 2021. Endoscopy 2021;53(03): 300–332
21 Mujtaba S, Chawla S, Massaad JF. Diagnosis and management of non-variceal gastrointestinal hemorrhage: a review of current guidelines and future perspectives. J Clin Med 2020;9(02): E402
22 Nagata N, Sakurai T, Moriyasu S, et al. Impact of INR monitoring, reversal agent use, heparin bridging, and anticoagulant interruption on rebleeding and thromboembolism in acute gastrointestinal bleeding. PLoS One 2017;12(09):e0183423
23 Anand D, Gupta R, Dhar M, Ahuja V. Clinical and endoscopic profile of patients with upper gastrointestinal bleeding at tertiary care center of North India. J Digest Endosc 2014;05(04): 139–143
24 Anand CS, Tandon BN, Nundy S. The causes, management and outcome of upper gastrointestinal haemorrhage in an Indian hospital. Br J Surg 1983;70(04):209–211
25 Rathi P, Abraham P, Rajeev J, Pai N. Spectrum of upper gastrointestinal bleeding in Western India. Indian J Gastroenterol 2001; 20(Suppl 2):A37
26 Singh SP, Panigrahi MK. Spectrum of upper gastrointestinal hemorrhage in coastal Odisha. Trop Gastroenterol 2013;34 (01):14–17
27 Parvez MN, Goenka MK, Tiwari IK, Goenka U. Spectrum of upper gastrointestinal bleed: an experience from Eastern India. J Digest Endosc 2016;7(02):55–61
28 Simon EG, Chacko A, Dutta AK, Joseph AJ, George B. Acute nonvariceal upper gastrointestinal bleeding–experience of a tertiary care center in southern India. Indian J Gastroenterol 2013;32(04):236–241
29 Lau JYW, Yu Y, Tang RSY, et al. Timing of endoscopy for acute upper gastrointestinal bleeding. N Engl J Med 2020;382(14): 1299–1308
30 Bratanic A, Puljiz Z, Ljubicicz N, et al. Predictive factors of rebleeding and mortality following endoscopic hemostasis in bleeding peptic ulcers. Hepatogastroenterology 2013;60(121): 112–117
31 Camus M, Jensen DM, Kovacs TO, Jensen ME, Markovic D, Gornbein J. Independent risk factors of 30-day outcomes in 1264 patients with peptic ulcer bleeding in the USA: large ulcers do worse. Aliment Pharmacol Ther 2016;43(10):1080–1089
32 Lolle I, Møller MH, Rosenstock SJ. Association between ulcer site and outcome in complicated peptic ulcer disease: a Danish nationwide cohort study. Scand J Gastroenterol 2016;51(10): 1165–1171
33 Vergara M, Bennett C, Calvet X, Gisbert JP. Epinephrine injection versus epinephrine injection and a second endoscopic method in high-risk bleeding ulcers. Cochrane Database Syst Rev 2014; (10):CD005584
34 Baracat F, Moura E, Bernardo W, et al. Endoscopic hemostasis for peptic ulcer bleeding: systematic review and meta-analyses of randomized controlled trials. Surg Endosc 2016;30(06):2155–2168
35 Manno M, Mangiafico S, Caruso A, et al. First-line endoscopic treatment with OTSC in patients with high-risk non-variceal upper gastrointestinal bleeding: preliminary experience in 40 cases. Surg Endosc 2016;30(05):2026–2029
36 Goenka MK, Rai VK, Goenka U, Tiwary IK. Endoscopic management of gastrointestinal leaks and bleeding with the over-the-scope clip: a prospective study. Clin Endosc 2017;50(01): 58–63
37 Asokkumar R, Soetikno R, Sanchez-Yague A, Kim Wei L, Salazar E, Ngu JH. Use of over-the-scope-clip (OTSC) improves outcomes of high-risk adverse outcome (HR-AO) non-variceal upper gastrointestinal bleeding (NVUGIB). Endosc Int Open 2018;6(07): E789–E796
38 Wedi E, von Renteln D, Gonzalez S, et al. Use of the over-the-scope-clip (OTSC) in non-variceal upper gastrointestinal bleeding in patients with severe cardiovascular comorbidities: a retrospective study. Endosc Int Open 2017;5(09):E875–E882
39 Lamberts R, Koch A, Binner C, et al. Use of over-the-scope clips (OTSC) for hemostasis in gastrointestinal bleeding in patients

 © 2022. Society of Gastrointestinal Endoscopy of India. All rights reserved.

under antithrombotic therapy. Endosc Int Open 2017;5(05): E324–E330
40 Schmidt A, Gölder S, Goetz M, et al. Over-the-scope clips are more effective than standard endoscopic therapy for patients with recurrent bleeding of peptic ulcers. Gastroenterology 2018; 155(03):674–686.e6
41 Barkun AN, Adam V, Lu Y, Chen YI, Martel M. Using hemospray improves the cost-effectiveness ratio in the management of upper gastrointestinal nonvariceal bleeding. J Clin Gastroenterol 2018;52(01):36–44
42 Mutneja H, Bhurwal A, Go A, Sidhu GS, Arora S, Attar BM. Efficacy of hemospray in upper gastrointestinal bleeding: a systematic review and meta-analysis. J Gastrointestin Liver Dis 2020;29(01): 69–76
43 Kovacs TOG, Jensen DM. Endoscopic therapy for severe ulcer bleeding. Gastrointest Endosc Clin N Am 2011;21(04):681–696
44 Baxter M, Aly EH. Dieulafoy's lesion: current trends in diagnosis and management. Ann R Coll Surg Engl 2010;92(07):548–554
45 Lee YT, Walmsley RS, Leong RWL, Sung JJY. Dieulafoy's lesion. Gastrointest Endosc 2003;58(02):236–243
46 Kim HS. Endoscopic management of Mallory-Weiss tearing. Clin Endosc 2015;48(02):102–105
47 Chandrasekhara V, Khashab MA, Muthusamy VR, et al; ASGE Standards of Practice Committee. Adverse events associated with ERCP. Gastrointest Endosc 2017;85(01):32–47
48 Freeman ML. Complications of endoscopic retrograde cholangiopancreatography: avoidance and management. Gastrointest Endosc Clin N Am 2012;22(03):567–586
49 Ferreira LEVVC, Baron TH. Post-sphincterotomy bleeding: who, what, when, and how. Am J Gastroenterol 2007;102(12):2850–2858
50 Okano N, Ito K, Takuma K, Hara S, Igarashi Y. Prevention and management of ERCP-related complications. Mini-invasive Surg 2021; 5:29
51 Murugesan SD, Sathyanesan J, Lakshmanan A, et al. Massive hemobilia: a diagnostic and therapeutic challenge. World J Surg 2014;38(07):1755–1762
52 Cathcart S, Birk JW, Tadros M, Schuster M. Hemobilia: an uncommon but notable cause of upper gastrointestinal bleeding. J Clin Gastroenterol 2017;51(09):796–804
53 de Franchis RBaveno VI Faculty. Expanding consensus in portal hypertension: report of the Baveno VI Consensus Workshop: stratifying risk and individualizing care for portal hypertension. J Hepatol 2015;63(03):743–752
54 Henry Z, Patel K, Patton H, Saad W. AGA clinical practice update on management of bleeding gastric varices: expert review. Clin Gastroenterol Hepatol 2021;19(06):1098–1107.e1
55 Wells M, Chande N, Adams P, et al. Meta-analysis: vasoactive medications for the management of acute variceal bleeds. Aliment Pharmacol Ther 2012;35(11):1267–1278
56 Jain M, Balkrishanan M, Snk C, Cgs S, Ramakrishnan R, Venkataraman J. SX-Ella Danis stent in massive upper gastrointestinal bleeding in cirrhosis - a case series. Clin Exp Hepatol 2018;4(02): 97–99
57 Ibrahim M, El-Mikkawy A, Abdalla H, Mostafa I, Devière J. Management of acute variceal bleeding using hemostatic powder. United European Gastroenterol J 2015;3(03):277–283
58 Ríos Castellanos E, Seron P, Gisbert JP, Bonfill Cosp X. Endoscopic injection of cyanoacrylate glue versus other endoscopic procedures for acute bleeding gastric varices in people with portal hypertension. Cochrane Database Syst Rev 2015;(05):CD010180
59 Bazarbashi AN, Wang TJ, Thompson CC, Ryou M. Endoscopic ultrasound-guided treatment of gastric varices with coil embolization and absorbable hemostatic gelatin sponge: a novel alternative to cyanoacrylate. Endosc Int Open 2020;8(02):E221–E227
60 Mukkada RJ, Antony R, Chooracken MJ, et al. Endoscopic ultrasound-guided coil or glue injection in post-cyanoacrylate gastric variceal re-bleed. Indian J Gastroenterol 2018;37(02):153–159
61 Aoki T, Hirata Y, Yamada A, Koike K. Initial management for acute lower gastrointestinal bleeding. World J Gastroenterol 2019; 25(01):69–84
62 Oakland K, Chadwick G, East JE, et al. Diagnosis and management of acute lower gastrointestinal bleeding: guidelines from the British Society of Gastroenterology. Gut 2019;68(05): 776–789
63 Oakland K, Jairath V, Uberoi R, et al. Derivation and validation of a novel risk score for safe discharge after acute lower gastrointestinal bleeding: a modelling study. Lancet Gastroenterol Hepatol 2017;2(09):635–643
64 Oakland K, Kothiwale S, Forehand T, et al. External validation of the Oakland score to assess safe hospital discharge among adult patients with acute lower gastrointestinal bleeding in the US. JAMA Netw Open 2020;3(07):e209630
65 Strate LL, Gralnek IM. ACG clinical guideline: management of patients with acute lower gastrointestinal bleeding. Am J Gastroenterol 2016;111(04):459–474
66 van Rongen I, Thomassen BJW, Perk LE. Early versus standard colonoscopy: a randomized controlled trial in patients with acute lower gastrointestinal bleeding: results of the BLEED study. J Clin Gastroenterol 2019;53(08):591–598
67 Niikura R, Nagata N, Yamada A, et al. Efficacy and safety of early vs elective colonoscopy for acute lower gastrointestinal bleeding. Gastroenterology 2020;158(01):168–175.e6
68 Tsay C, Shung D, Stemmer Frumento K, Laine L. Early colonoscopy does not improve outcomes of patients with lower gastrointestinal bleeding: systematic review of randomized trials. Clin Gastroenterol Hepatol 2020;18(08):1696–1703.e2
69 Anvari S, Lee Y, Yu J, Doumouras AG, Khan KJ, Hong D. Urgent versus standard colonoscopy for management of acute lower gastrointestinal bleeding: a systematic review and meta-analysis of randomized controlled trials. J Clin Gastroenterol 2020;54 (06):493–502
70 Nagata N, Ishii N, Manabe N, et al. Guidelines for colonic diverticular bleeding and colonic diverticulitis: Japan Gastroenterological Association. Digestion 2019;99(Suppl 1):1–26
71 Ishii N, Omata F, Nagata N, Kaise M. Effectiveness of endoscopic treatments for colonic diverticular bleeding. Gastrointest Endosc 2018;87(01):58–66
72 Nagata N, Ishii N, Kaise M, et al. Long-term recurrent bleeding risk after endoscopic therapy for definitive colonic diverticular bleeding: band ligation versus clipping. Gastrointest Endosc 2018;88(05):841–853.e4
73 Akutsu D, Narasaka T, Wakayama M, et al. Endoscopic detachable snare ligation: a new treatment method for colonic diverticular hemorrhage. Endoscopy 2015;47(11):1039–1042
74 Takahashi S, Inaba T, Tanaka N. Delayed perforation after endoscopic band ligation for treatment of colonic diverticular bleeding. Dig Endosc 2016;28(04):484
75 Inoue T, Ishihara R, Nishida T, et al. Prophylactic clipping not effective in preventing post-polypectomy bleeding for < 20-mm colon polyps: a multicenter, open-label, randomized controlled trial. J Gastroenterol Hepatol 2021;36(02):383–390
76 Spadaccini M, Albéniz E, Pohl H, et al. Prophylactic clipping after colorectal endoscopic resection prevents bleeding of large, proximal polyps: meta-analysis of randomized trials. Gastroenterology 2020;159(01):148–158.e11
77 Boumitri C, Mir FA, Ashraf I, et al. Prophylactic clipping and post-polypectomy bleeding: a meta-analysis and systematic review. Ann Gastroenterol 2016;29(04):502–508
78 Ji JS, Lee SW, Kim TH, et al. Comparison of prophylactic clip and endoloop application for the prevention of postpolypectomy bleeding in pedunculated colonic polyps: a prospective, randomized, multicenter study. Endoscopy 2014;46(07):598–604
79 Tagawa T, Yamada M, Minagawa T, et al. Endoscopic characteristics influencing postpolypectomy bleeding in 1147

 © 2022. Society of Gastrointestinal Endoscopy of India. All rights reserved.

consecutive pedunculated colonic polyps: a multicenter retrospective study. Gastrointest Endosc 2021;94(04):803–811.e6
80 Hong SP. How do I manage post-polypectomy bleeding? Clin Endosc 2012;45(03):282–284
81 Gerson LB, Fidler JL, Cave DR, Leighton JA. ACG clinical guideline: diagnosis and management of small bowel bleeding. Am J Gastroenterol 2015;110(09):1265–1287, quiz 1288
82 Murphy B, Winter DC, Kavanagh DO. Small bowel gastrointestinal bleeding diagnosis and management-a narrative review. Front Surg 2019;6:25
83 Triester SL, Leighton JA, Leontiadis GI, et al. A meta-analysis of the yield of capsule endoscopy compared to other diagnostic modalities in patients with obscure gastrointestinal bleeding. Am J Gastroenterol 2005;100(11):2407–2418
84 Wang Z, Chen JQ, Liu JL, Qin XG, Huang Y. CT enterography in obscure gastrointestinal bleeding: a systematic review and meta-analysis. J Med Imaging Radiat Oncol 2013;57(03): 263–273
85 Wu LM, Xu JR, Yin Y, Qu XH. Usefulness of CT angiography in diagnosing acute gastrointestinal bleeding: a meta-analysis. World J Gastroenterol 2010;16(31):3957–3963
86 Aniwan S, Viriyautsahakul V, Rerknimitr R, et al. Urgent double balloon endoscopy provides higher yields than non-urgent double balloon endoscopy in overt obscure gastrointestinal bleeding. Endosc Int Open 2014;2(02):E90–E95
87 Marques M, Santos-Antunes J, Coelho R, et al. Single-balloon enteroscopy efficacy and degree of concordance with noninvasive evaluation of small bowel. Endosc Int Open 2017;5(02): E96–E102
88 Gu Y, Shi X, Yang Y, et al. Single-balloon and spiral enteroscopy may have similar diagnostic and therapeutic yields to double-balloon enteroscopy: results from a meta-analysis of randomized controlled trials and prospective studies. WJAM 2020;8 (02):153–162
89 Ramchandani M, Rughwani H, Inavolu P, et al. Diagnostic yield and therapeutic impact of novel motorized spiral enteroscopy in small-bowel disorders: a single-center, real-world experience from a tertiary care hospital (with video). Gastrointest Endosc 2021;93(03):616–626
90 Tazuma S. Gallstone disease: epidemiology, pathogenesis, and classification of biliary stones (common bile duct and intrahepatic). Best Pract Res Clin Gastroenterol 2006;20(06): 1075–1083
91 Chen H, Jorissen R, Walcott J, Nikfarjam M. Incidence and predictors of common bile duct stones in patients with acute cholecystitis: a systematic literature review and meta-analysis. ANZ J Surg 2020;90(09):1598–1603
92 Parikh MP, Wadhwa V, Thota PN, Lopez R, Sanaka MR. Outcomes associated with timing of ERCP in acute cholangitis secondary to choledocholithiasis. J Clin Gastroenterol 2018;52(10):e97–e102
93 Du L, Cen M, Zheng X, Luo L, Siddiqui A, Kim JJ. Timing of performing endoscopic retrograde cholangiopancreatography and inpatient mortality in acute cholangitis: a systematic review and meta-analysis. Clin Transl Gastroenterol 2020;11(03): e00158
94 Kim TH, Kim JH, Seo DW, et al. International consensus guidelines for endoscopic papillary large-balloon dilation. Gastrointest Endosc 2016;83(01):37–47
95 Horiuchi A, Nakayama Y, Kajiyama M, et al. Biliary stenting in the management of large or multiple common bile duct stones. Gastrointest Endosc 2010;71(07):1200–1203.e2
96 Li G, Pang Q, Zhang X, et al. Dilation-assisted stone extraction: an alternative method for removal of common bile duct stones. Dig Dis Sci 2014;59(04):857–864
97 Lee SH, Park JK, Yoon WJ, et al. How to predict the outcome of endoscopic mechanical lithotripsy in patients with difficult bile duct stones? Scand J Gastroenterol 2007;42(08):1006–1010
98 Gastroenterology BPGL and BS of UK guidelines for the management of acute pancreatitis. Gut 2005;54(Suppl 3):iii1–iii9
99 Forsmark CE, Baillie JAGA Institute Clinical Practice and Economics Committee AGA Institute Governing Board. AGA institute technical review on acute pancreatitis. Gastroenterology 2007; 132(05):2022–2044
100 Wada K, Takada T, Kawarada Y, et al. Diagnostic criteria and severity assessment of acute cholangitis: Tokyo Guidelines. J Hepatobiliary Pancreat Surg 2007;14(01):52–58
101 Eisen GM, Baron TH, Dominitz JA, et al; American Society for Gastrointestinal Endoscopy. Guideline for the management of ingested foreign bodies. Gastrointest Endosc 2002;55(07): 802–806
102 Li ZS, Sun ZX, Zou DW, Xu GM, Wu RP, Liao Z. Endoscopic management of foreign bodies in the upper-GI tract: experience with 1088 cases in China. Gastrointest Endosc 2006;64(04): 485–492
103 Birk M, Bauerfeind P, Deprez PH, et al. Removal of foreign bodies in the upper gastrointestinal tract in adults: European Society of Gastrointestinal Endoscopy (ESGE) Clinical Guideline. Endoscopy 2016;48(05):489–496
104 Diehl DL, Adler DG, Conway JD, et al; Asge Technology Committee. Endoscopic retrieval devices. Gastrointest Endosc 2009;69 (06):997–1003
105 Ikenberry SO, Jue TL, Anderson MA, et al; ASGE Standards of Practice Committee. Management of ingested foreign bodies and food impactions. Gastrointest Endosc 2011;73(06):1085–1091
106 Chirica M, Kelly MD, Siboni S, et al. Esophageal emergencies: WSES guidelines. World J Emerg Surg 2019;14(01):26
107 Gomez-Esquivel R, Raju GS. Endoscopic closure of acute esophageal perforations. Curr Gastroenterol Rep 2013;15(05):321
108 Watkins JR, Farivar AS. Endoluminal therapies for esophageal perforations and leaks. Thorac Surg Clin 2018;28(04):541–554
109 Voermans RP, Le Moine O, von Renteln D, et al; CLIPPER Study Group. Efficacy of endoscopic closure of acute perforations of the gastrointestinal tract. Clin Gastroenterol Hepatol 2012;10(06): 603–608
110 Persson S, Rouvelas I, Irino T, Lundell L. Outcomes following the main treatment options in patients with a leaking esophagus: a systematic literature review. Dis Esophagus 2017;30(12): 1–10
111 Still S, Mencio M, Ontiveros E, Burdick J, Leeds SG. Primary and rescue endoluminal vacuum therapy in the management of esophageal perforations and leaks. Ann Thorac Cardiovasc Surg 2018;24(04):173–179
112 Ofosu A, Ramai D, Latson W, Adler DG. Endoscopic management of bleeding gastrointestinal tumors. Ann Gastroenterol 2019;32 (04):346–351
113 Shin J, Cha B, Park JS, et al. Efficacy of a novel hemostatic adhesive powder in patients with upper gastrointestinal tumor bleeding. BMC Gastroenterol 2021;21(01):40
114 Arena M, Masci E, Eusebi LH, et al. Hemospray for treatment of acute bleeding due to upper gastrointestinal tumours. Dig Liver Dis 2017;49(05):514–517
115 Pittayanon R, Prueksapanich P, Rerknimitr R. The efficacy of Hemospray in patients with upper gastrointestinal bleeding from tumor. Endosc Int Open 2016;4(09):E933–E936
116 Naveed M, Jamil LH, Fujii-Lau LL, et al. American Society for Gastrointestinal Endoscopy guideline on the role of endoscopy in the management of acute colonic pseudo-obstruction and colonic volvulus. Gastrointest Endosc 2020;91(02): 228–235
117 Tsirline VB, Zemlyak AY, Avery MJ, et al. Colonoscopy is superior to neostigmine in the treatment of Ogilvie's syndrome. Am J Surg 2012;204(06):849–855, discussion 855
118 Peker KD, Cikot M, Bozkurt MA, et al. Colonoscopic decompression should be used before neostigmine in the treatment of

 © 2022. Society of Gastrointestinal Endoscopy of India. All rights reserved.

Ogilvie's syndrome. Eur J Trauma Emerg Surg 2017;43(04): 557–566
119 van Hooft JE, Bemelman WA, Oldenburg B, et al; collaborative Dutch Stent-In study group. Colonic stenting versus emergency surgery for acute left-sided malignant colonic obstruction: a multicentre randomised trial. Lancet Oncol 2011;12(04):344–352
120 Allievi N, Ceresoli M, Fugazzola P, Montori G, Coccolini F, Ansaloni L. Endoscopic stenting as bridge to surgery versus emergency resection for left-sided malignant colorectal obstruction: an updated meta-analysis. Int J Surg Oncol 2017;2017:2863272
121 Kedia P, Sharaiha RZ, Kumta NA, et al. Endoscopic gallbladder drainage compared with percutaneous drainage. Gastrointest Endosc 2015;82(06):1031–1036
122 James TW, Baron TH. EUS-guided gallbladder drainage: a review of current practices and procedures. Endosc Ultrasound 2019; 8(Suppl 1):S28–S34

 © 2022. Society of Gastrointestinal Endoscopy of India. All rights reserved.