Article published online: 2022-09-13

Endoscopic Full Thickness Resection: A Systematic Review

Partha Pal[1] Mohan Ramchandani[1] Pradev Inavolu[1] Duvvuru Nageshwar Reddy[1] Manu Tandan[1]

[1] Department of Interventional Endoscopy, Asian Institute of Gastroenterology, Hyderabad, Telangana, India

J Digest Endosc 2022;13:152–169.

Address for correspondence Mohan Ramchandani, MD, DM, Department of Interventional Endoscopy, AIG Hospitals, Asian Institute of Gastroenterology, No 136, Plot No 2/3/4/5 Survey, 1, Mindspace Rd, Gachibowli, Hyderabad, Telangana 500032, India (e-mail: ramchandanimohan@gmail.com).

Abstract

Background Endoscopic full thickness resection (EFTR) is an emerging therapeutic option for resecting subepithelial lesions (SELs) and epithelial neoplasms. We aimed to systematically review the techniques, applications, outcomes, and complications of EFTR.

Methods A systematic literature search was performed using PubMed. All relevant original research articles involving EFTR were included for the review along with case report/series describing novel/rare techniques from 2001 to February 2022.

Results After screening 7,739 citations, finally 141 references were included. Non-exposed EFTR has lower probability of peritoneal contamination or tumor seeding compared with exposed EFTR. Among exposed EFTR, tunneled variety is associated with lower risk of peritoneal seeding or contamination compared with non-tunneled approach. Closure techniques involve though the scope (TTS) clips, loop and clips, over the scope clips (OTSC), full thickness resection device (FTRD), and endoscopic suturing/plicating/stapling devices. The indications of EFTR range from esophagus to rectum and include SELs arising from muscularis propria (MP), non-lifting adenoma, recurrent adenoma, and even early gastric cancer (EGC) or superficial colorectal carcinoma. Other indications include difficult locations (involving appendicular orifice or diverticulum) and full thickness biopsy for motility disorders. The main limitation of FTRD is feasibility in smaller lesions (<20–25 mm), which can be circumvented by hybrid EFTR techniques. Oncologic resection with lymphadencetomy for superficial GI malignancy can be accomplished by hybrid natural orifice transluminal endoscopic surgery (NOTES) combining EFTR and NOTES. Bleeding, perforation, appendicitis, enterocolonic fistula, FTRD malfunction, peritoneal tumor seeding, and contamination are among various adverse events. Post OTSC artifacts need to be differentiated from recurrent/residual lesions to avoid re-FTRD/surgery.

Conclusion EFTR is safe and effective therapeutic option for SELs, recurrent and non-lifting adenomas, tumors in difficult locations and selected cases of superficial GI carcinoma.

Keywords
- endoscopic full thickness resection
- full thickness resection device
- sub-epithelial lesions
- over the scope clips

DOI https://doi.org/10.1055/s-0042-1755304.
ISSN 0976-5042.

Thieme Medical and Scientific Publishers Pvt. Ltd., A-12, 2nd Floor, Sector 2, Noida-201301 UP, India

Introduction

Endoscopic resection has evolved from simple polypectomy to endoscopic mucosal resection (EMR) and endoscopic submucosal dissection (ESD) for en-bloc removal of large tumors. ESD for non-lifting lesions arising from MP (e.g., gastrointestinal stromal tumor [GIST]) carries high risk of perforation and subsequently closure can be difficult in collapsed lumen.[1] Hence, laparoscopic endoscopic cooperative surgery (LECS) was introduced to maintain continuity of the gastrointestinal (GI) tract and to allow traction during dissection. More recently, non-exposed technique of EFTR by "close first and cut later " strategy can help mitigate the challenges of exposed EFTR (cut first and close later strategy). This can be achieved by endoscopic suturing, full thickness resection device (FTRD) or novel robotic endoscopic platform.[1,2]

Search Strategy

For the purpose of the review, we searched the PubMed using keywords "EFTR" or "FTRD." We screened total 7,740 citations and 350 were identified. Finally 144 citations were included for our review excluding case reports/series/original articles with small sample size (other than describing novel technique or a unique complication)/letter to editor/editorials (►**Fig. 1**) and including relevant articles with specific searches and selected cross references.

Details of Technique

History of EFTR: Experimental Studies on Animal Model

Both ex-vivo and in-vivo (live) models showing feasibility of en-bloc/ R0 resection in stomach/colorectum form the basis of current EFTR techniques.[3] First prototype and the modern FTRD device for colorectal EFTR were developed in 2001 and 2015, respectively by Schurr et al.[4,5] Among several techniques performed in animal models (►**Table 1**),[5–17] some made it to clinical practice.

Techniques of EFTR

EFTR techniques can be divided into exposed and non-exposed EFTR. In exposed EFTR, resection is followed by defect closure (peritoneum exposed). In non-exposed EFTR, the lesion is invaginated into the lumen to allow serosa-to-serosa apposition followed by resection.[2] Exposed EFTR can be further divided into non-tunneled and tunneled EFTR. In the former, the lesion is dissected through the MP like ESD using soft translucent cap and various knives (Flush knife, Dual knife and hybrid knife allow simultaneous injection and cutting).[18] After dissection, EFTR is performed.[2]

Tunneled exposed EFTR is similar to submucosal tunnel endoscopic resection (STER) in which mucosal incision is made followed by dissection through MP to create a tunnel through which the enucleated lesion is brought out.[19,20] Tunneled EFTR does not warrant full thickness closure as only mucosal closure ensures wall integrity. It is applicable only for subepithelial lesions (SELs) and hence it is better with respect to infection control compared with other exposed EFTR techniques. This is feasible for lesions <4 cm particularly in the distal esophagus and gastric cardia.[2]

Closure Techniques

Though the Scope Clip Closure

Though the scope (TTS) clips (designed for hemostasis) achieve only mucosal and submucosal apposition.[21] However, post

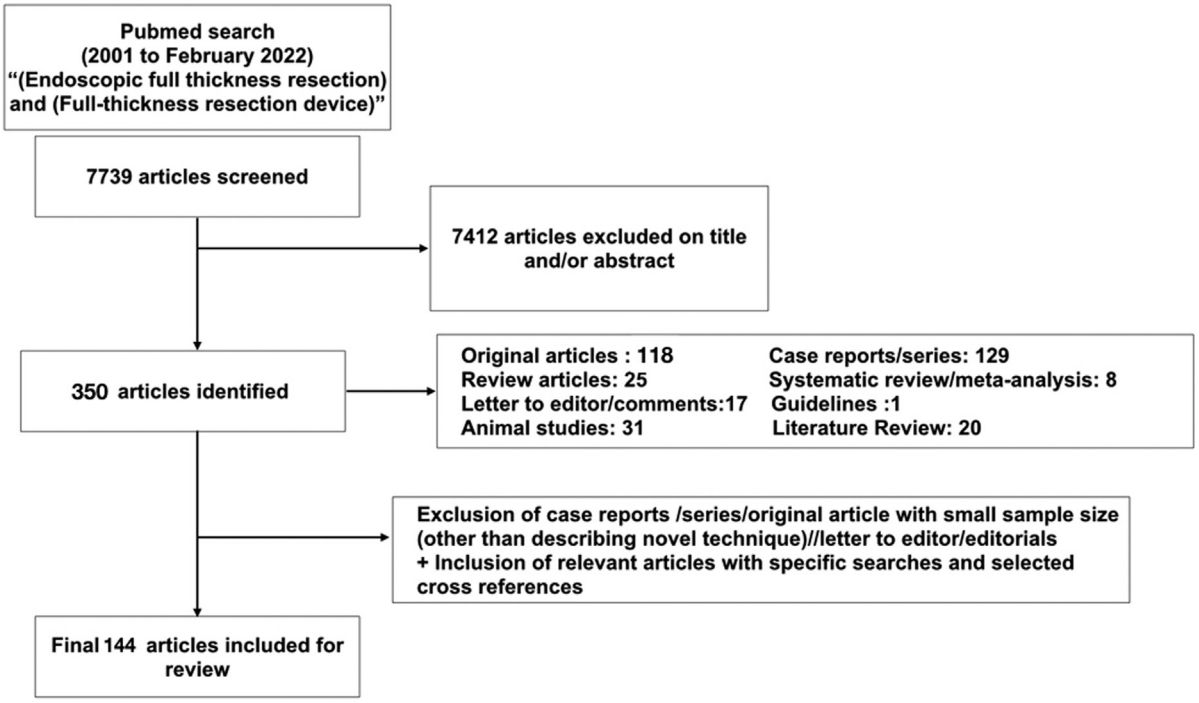

Fig. 1 Search strategy for systematic review.

Table 1 Experimental studies on endoscopic full thickness resection (EFTR)

Author	Year	Animal model	Part of GI tract	Technique
Schurr and Gottwald	2018	Porcine	Colorectal	First prototype FTRD device with combined stapling and cutting apparatus, technical development with experimental animal studies
Rajan et al	2002	Porcine	Colorectal	First prototype FTRD device with combined grasping, stapling and cutting apparatus, Porcine survival analysis
Ikeda et al	2005	Porcine	Stomach	Defect closure by suturing, locking, and thread-cutting device (T- tags)
Kaehler et al	2006	Porcine model and human exenterates	Stomach	Gastric EFTR with SurgAssist flexible stapling device
Elmunzer et al	2010	Porcine	Stomach	Grasp and snare EFTR technique, tissue lifting and snare
Goto et al[145]	2011	Porcine	Stomach	Non-exposed endoscopic wall-inversion surgery (NEWS) for gastric submucosal tumors and node negative early gastric cancer
Mori et al	2015	Porcine	Stomach	Non-exposed gastric EFTR using flexible endoscopes to invert the gastric lesion followed by double arm bar suturing system (DBSS) use
Schurr et al	2015	Porcine	Colorectal	First prototype of modern FTRD device
Guo et al	2016	Porcine	Stomach	Endoscopic puncture suture device compared with metallic clip closure, lower procedure time with former
Sun et al	2016	Porcine	Stomach	Endoscopic ultrasound (EUS)-guided puncture suture device was compared with metal clip for gastric defect closure, shorter procedure time, and less immunologic response in EUS-guided technique
Goto et al	2018	Porcine (ex vivo and live model)	Stomach	Third space EFTR for small gastric sub-epithelial tumors
Huberty et al	2019	Porcine	Stomach	EFTR using Endomina platform
Morita et al	2019	Porcine in vivo model	Stomach	Laparoendoscopic resection of gastric sub-epithelial tumors
Kitakata et al	2019	Porcine ex vivo model	Stomach	Sealed EFTR for resecting gastric tumor, serosal sealing with silicone sheet to prevent leak of gastric juice
Kamba et al	2020	Porcine	Stomach	Gastric EFTR using automatic carbon dioxide insufflating system (SPACE) vs. manual insufflation to control intra-abdominal pressure
Kobara et al	2021	Canine model	Stomach	Traction-assisted endoscopic full-thickness resection followed by full-thickness closure using O-ring and OTSC closure using exposed EFTR

EFTR defect closure has been reported successfully with TTS clips.[21] Peristalsis and radial force of large defects can compromise the integrity of gut wall apposition achieved with TTS clips leading to delayed perforation and bleeding. A "side to center" method is preferred when the diameter of the defect is less than the clip. For defects larger than TTS clip, a "suction-clip suture" technique or "omental patch closure" (e.g., sucking the omentum into the defect) can be done.[22,23] This is operator dependent and foreign body forceps through a dual channel endoscope can reduce the procedure time.[24]

Endoloop Clip-Assisted Closure Method

Endoloop-assisted closure of post EFTR defects has been described which reinforces TTS clip closure. However, it cannot achieve closure of muscularis/serosa. Currently, endoscopic purse-string suture (EPSS) technique is most popular for endoloop clip closure, in which the defect is closed by tightening of endoloop after application of TTS clips circumferentially along defect margins anchoring the endoloop.[25,26] This requires a double-channel scope, however, the use of a novel endoloop has enabled closure by single channel endoscope.[27] The peritoneal exposure can be reduced by pre-EPSS method, in which one endoloop is applied distal to resection margin and another around lesion to make the lesion intraluminal following which the lesion is resected with immediate closure.[28]

Cap Mounted Clip Closure

Unlike TTS clips, cap mounted clips like over the scope clips (OTSC) and Padlock clip are designed for full thickness closure.[29] The edges of the defect are drawn into transparent cap by help of twin graspers following which OTSC is released to achieve full thickness closure. OTSC can close only defects <2 to 2.5 cm (due to small internal diameter)

and cannot be repositioned once deployed.[30] After incomplete EFTR, OTSC removal by dedicated bipolar device is required before re-intervention. Though expensive (c.f. TTS clips), OTSC clips can significantly reduce hospital stay and procedure time.[22]

Combined Full Thickness Resection and Closure

FTRD (Ovesco Endoscopy) (►**Fig. 2**) has an integrated closure and resection device and consists of a transparent cap (outer diameter 21 mm) with modified OTSC (14 mm) (which can be mounted over colonoscope/endoscope 11.5–13.2 mm diameter and a working channel diameter of ≥3.2 mm), a tissue grasper and a 13-mm monofilament hot snare preloaded in the tip of the cap running on outer surface of the scope under a transparent plastic sheath (►**Fig. 2**).[2] The depth of the FTRD cap is 23 mm compared with 6 mm in conventional OTSC system to accommodate more tissue. It can be used in upper GI tract after bougie or balloon dilation of the lower esophageal sphincter (LES) up to 20 mm.[31] After marking the lesion with integrated electrocautery, OTSC is applied after pulling the lesion with tissue grasper followed by resection with snare. The entire procedure is complete using a single device.

Endoscopic Suturing System

The limitation of OTSC in closing larger defects is overcome by dedicated flexible endoscopic suturing device (OverStitch endoscopic suturing system, Apollo Endosurgery, Austin, Texas, United States) or endoscopic puncture suture device using T-tags. Although technically demanding and costly, ESS can achieve full thickness "surgical closure" in a cost which is much lesser than conventional surgery.[22] Preliminary reports have shown its safety and efficacy.[13,32]

Endoscopic Plicating Devices

The full thickness plicator device (NDO Surgical Inc., Mansfield, Massachusetts, United States) with polytetrafluoroethylene-pledgeted sutures originally designed for anti-reflux therapy has been used for EFTR of gastric SELs.[33] As this is currently unavailable, another anti-reflux device with a hydraulic closure mechanism: GERDX (G-Surg, Seeon, Germany) is being used for gastric SELs.[34] The large diameter and limited manipulation have restricted its use to gastric lesions only.

Endoscopic Stapling Devices

SurgASSIST system (Power Medical Interventions Deutschland GmbH, Hamburg, Germany) with 20-mm linear stapling device can be passed co-axially along with endoscope and has been used to resect gastric SELs and superficial carcinoma. The large size and limited manipulative capacity increases risk of perforation with device passage.

The initial prototype FTRD had a semicircular stapler along with tissue grasper and a scalpel. The use was limited to the left colon due to its large size and currently no longer manufactured.[4]

Traction

The use of distal transparent cap to expose the incision level during ESD may not be feasible in positions like fundus of stomach. Dental floss-assisted or metallic clip and rubber band-assisted pulley traction has been used to promote dissection for large mucosal lesions/SELs in different locations.[35] The advantages are reduced operative time, better tumor/vessels exposure with prevention of tumor falling into the abdominal cavity.[35]

Comparison between Post EFTR Closure Techniques

There is scarcity of comparative literature among post EFTR closure techniques with regard to complications except for animal studies. However, TTS or clip and loop cannot achieve full thickness closure in true sense. OTSC and suturing/plicating devices can achieve full thickness closure and hence can prevent delayed bleeding and perforation better than clips/clips and loops. A limitation of OTSC is its limited internal diameter. However the cost effectivity of these newer closure techniques needs to be studied in future.

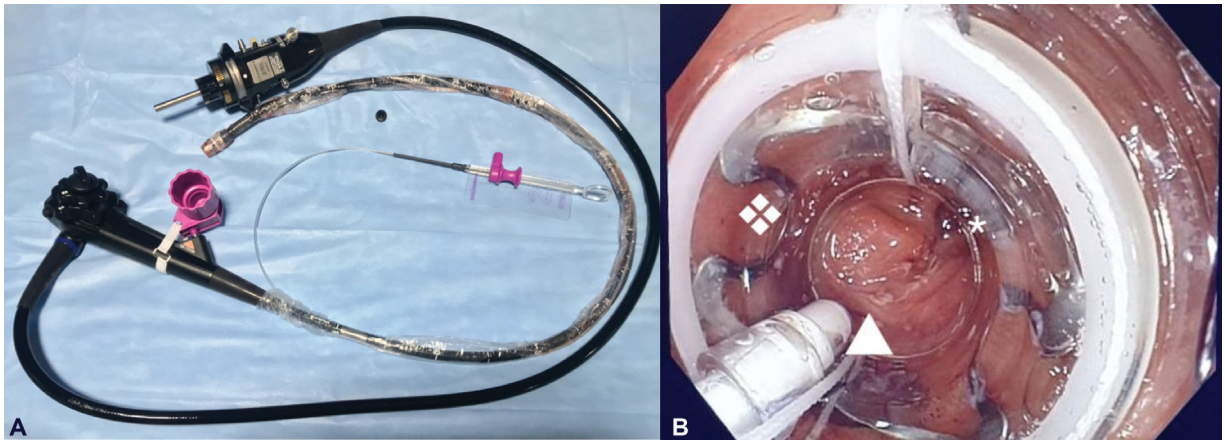

Fig. 2 The full thickness resection device (FTRD). (**A**) The FTRD assembly: over the scope clip (OTSC) over transparent cap loaded on the tip of therapeutic endoscope, monofilament hot snare preloaded in the tip of the cap running on outer surface of the scope under a transparent plastic sheath. (**B**) Parts of FTRD during full thickness resection (* transparent cap, ▲ tissue grasper, ❖ OTSC).

Current Status of EFTR: Various Applications with Outcomes

EFTR in the Esophagus

Esophageal SELs originating from the MP can be resected using EFTR.[36] Clinical cases are limited to case reports. A case of recurrent esophageal leiomyoma originating from MP which was operated twice, was treated with STER and muscle excision preserving adventitia followed by clip closure.[20] ESD with closure of ulcer floor with clips has been described.[37] Endoscopic submucosal excavation (ESE) with LeCamp endoloop closure with single channel endoscope has been described.[38]

EFTR Stomach

EFTR of stomach is done for gastric GIST, other SELs (►**Fig. 3**), adenomas, and early carcinoma. The latter could be restricted to only small (<2 cm) adenocarcinoma with mucosal/limited submucosal involvement (<0.5 mm) without high-risk features (lymphovascular invasion/intestinal subtype).[39] EFTR of gastric metastasis from malignant melanoma has also been described.[40] Although FTRD insertion needs prior dilation of LES for gastro-duodenal lesions, it can be technically successful in 93% cases with up to 68% R0 resection rates and minimal recurrence (3%) on short term follow-up (median 3 months).[31]

EFTR Duodenum

Earlier reports of duodenal EFTR were on conventional EMR with laparoscopic closure of defect and inadvertent EFTR after EMR closed by hemoclips[41–43] We have summarized studies specifically evaluating duodenal EFTR in ►**Table 2** (►**Figs. 4** and **5**). Duodenal EFTR was described with colonic FTRD device, modified FTRD loaded on endoscope (14 mm OTSC), OTSC-based multistep EFTR, flat-based OTSC (Padlock clips) and ESD with clip/loop/Overstitch closure.[29,44–47] Indications included SELs and adenomas (non-lifting, recurrent, and residual lesion after failed ESD). Technical success ranged from 85 to 100%, R0 resection rates were 63.2 to 100%. Adverse events were minor bleeding (most common), followed by perforation and peritonitis.[29,44–47] FTRD in duodenum was particularly effective for lesions <20 mm.[47]

EFTR in Small Bowel (Other Than Duodenum)

Single and double balloon enteroscopy-guided EFTR of mid ileal endometriosis and Meckel's diverticulum, respectively with conventional loop and snares have been described.[48,49] Resection of non-lifting adenoma with FTRD device has been described in ileal pouch in a postoperative case of familial adenomatous polyposis.[50]

EFTR Colorectum

Traditional methods of colorectal tumor resection have limitations like steep learning curve (ESD) and high recurrence rate (up to 15% for EMR). SELs, recurrent/non-lifting adenomas with scarring, deep invading lesions, and adenomas near appendix/diverticulum not amenable to EMR/ESD can be candidates for EFTR (►**Table 3**). Dedicated FTRD device enables one step resection after pre-closure with OTSC. It has shorter learning curve although larger lesions may not be amenable which warrant hybrid techniques. Pooled technical success, R0 resection rate, adverse events, and recurrence are 87.6, 78.8, 12.2, and 12.6%, respectively according to recent meta-analysis of colorectal EFTR (total 1,936 patients). Lesions >2 cm have lower R0 resection and adverse event rates.[51] R0 resection did not differ based on indication (difficult adenoma, early carcinoma, and SELs) or location (proximal, distal colon, and rectum).[52] Two meta-analyses evaluating only FTRD have shown that success of insertion to target lesion, technical success, R0 resection, total complication rates were 96.1%, 89 to 90, 78 to 82, and 8 to 10%, respectively. Major bleeding, perforation, and need for emergent surgery occurred in roughly 1% cases whereas post-polypectomy syndrome was noted in 2%.[52,53]

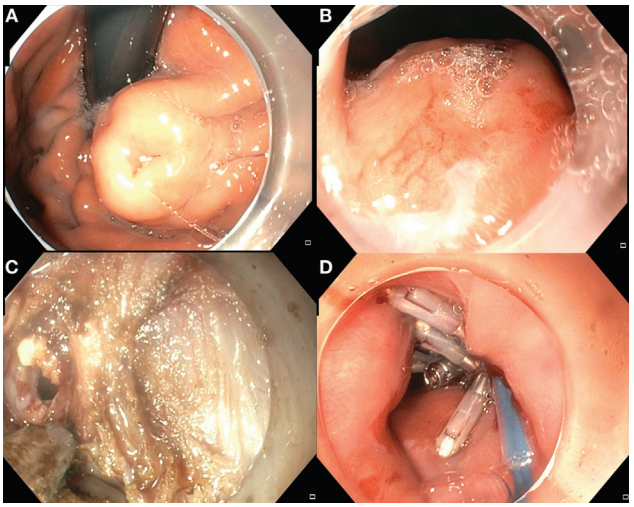

Fig. 3 Endoscopic full thickness resection (EFTR) for sub-epithelial lesion just below gastroesophageal junction. (**A**) Retroverted view from stomach, (**B**) view from esophagus, (**C**) endoscopic submucosal dissection, (**D**) loop and clip-assisted closure.

EFTR for Early Colorectal Cancer (CRC)

EFTR using FTRD device or EFTR with endoscopic lymphadenectomy has been described for superficial CRC. While many techniques are limited to case reports/series, 156 cases of adenocarcinoma detected incidentally on histology after resection using FTRD were described by Kuellmer et al.[54] The R0 resection rate was lower in non-lifting lesion (61%) as compared with polypoidal lesion (87.5%). Given the suboptimal rate of R0 resection for lesions ≥20 mm with FTRD, the role is limited given the fact that submucosal invasive cancer (SMIC, <1,000 µm submucosal invasion) in <20 mm lesion is found in ≤1%.[55] So, ESD could still be preferable for lesions >20 mm if deep SMIC (≥1,000 µm) is not likely based on image-enhanced endoscopic characterization. However, FTRD can have a role in non-surgical candidates. Retrospective analyses of Dutch EFTR registry have shown a curative resection rate of 23.7% in T1 CRC and 60.8% excluding high risk features (deep SMIC). Full thickness histological assessment after EFTR with FTRD can help in avoiding oncologic resection in low risk patients.[56]

Table 2 Endoscopic full thickness resection (EFTR) for duodenal lesions

Author	Year	Location in duodenum	N	Indication	Technique	Max Diameter (mm)	Operative time (average, Range)	Hospital stay	Technical success	R0 resection	Adverse events	Recurrence
Schmidt et al	2015	First to third part	20	Non-lifting adenoma, Sub-epithelial lesions (SEL) including neuroendocrine tumor (NET)	Modified FTRD device loaded on endoscope	22–40	50–85	4–6	100%	75%	50% minor bleeding	None at 3 mo follow-up
Bauder et al	2018	Entire duodenum	20	Adenoma, non-lifting adenoma, SEL, adenocarcinoma	Colonic FTRD device after esophageal and pyloric CRE dilatation (20 mm)	5–35	61 (25–130 min)	–	85%	63.2%	15.8% minor bleeding	$n = 2$, re-EFTR
Ren et al[146]	2019	First and second part	32	Non-ampullary duodenal SEL (GIST-14, NET-4, Pancreatic rest -11, Leiomyoma-2, Lipoma-1)	ESD followed by clip and /or loop or Overstitch closure	5–30	68 (17–186 min)	6.2 2–19	100%	100%	Perforation closed by Laparoscopy,[1] Peritonitis,[1] Fall in saturation[1]	None, at 38 mo 14–73
Kappelle et al	2018	Proximal to ampulla	6	SELs	Flat-based OTSC (Padlock clip)	5–13	35 ± 10	7 (2–14)	100%	83%	Perforation,[1] micro-perforation,[3] hemorrhage[1]	–
Wei et al	2021	Not specified	13	Adenomas, SELs	OTSC assisted multistep EFTR	10–32	38.7 ± 14.6	2–3 d post-operative	100%	92.3%	None	None

Abbreviations: FTRD, full thickness resection device; GIST, gastrointestinal stromal tumor; NET, neuroendocrine tumor.

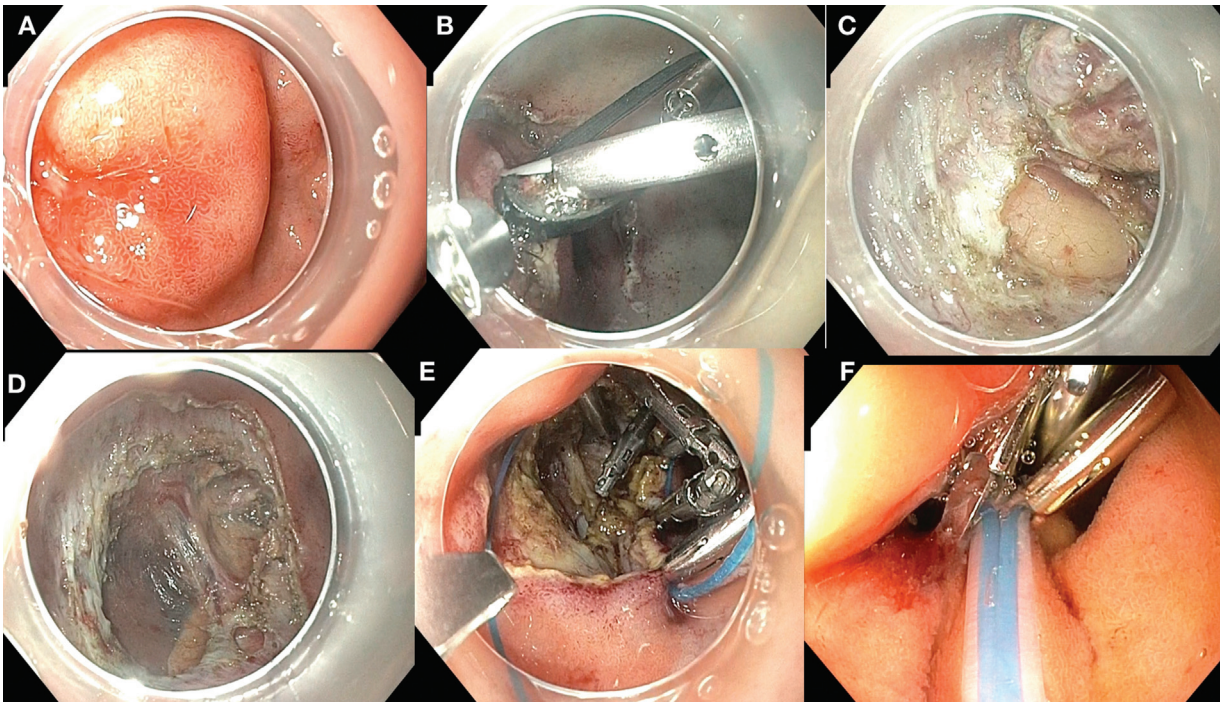

Fig. 4 Endoscopic full thickness resection (EFTR) of duodenal neuroendocrine tumor (NET). (**A**) Duodenal NET situated in anterior wall of D1, (**B**) clip and band-assisted traction used for dissection, (**C**) endoscopic submucosal dissection, (**D**) post EFTR defect. (**E**) Defect closed with loop and clip technique. (**F**) Loop closed with complete closure of defect.

However, recurrence can occur even up to 54 months post-resection.[55] Current studies have evaluated recurrence (0.5–6%) only in short term (3 months).[54,56] Delayed perforation in this settings can significantly increase morbidity and decrease chance of cure after FTRD.[55]

EFTR near Appendicular Orifice

Studies on EFTR using dedicated FTRD device has been summarized in ►**Table 4.**–[57–59] Technical success was 89 to 100%. R0 resection ranged from 64 to 93%.[57–59] Recurrence was nearly 12%.[59] Most of the resected lesions are

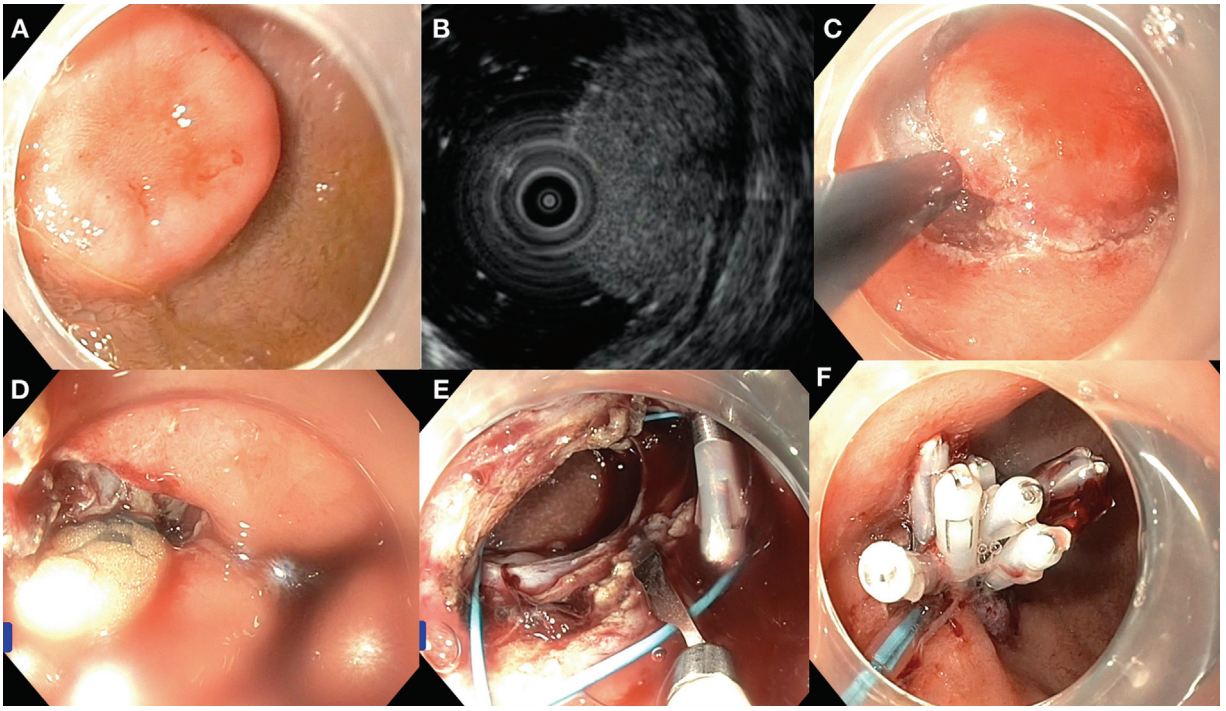

Fig. 5 Endoscopic full thickness resection (EFTR) of duodenal neuroendocrine tumor (NET) involving superficial layer of muscularis propria. (**A**) Endoscopic view, (**B**) EUS evaluation, (**C**) endoscopic submucosal dissection (ESD), (**D**) defect post ESD-peritoneum seen, (**E**) loop and clip closure, (**F**) post defect closure.

Table 3 Studies on endoscopic full thickness resection (EFTR) in the colorectum

Author	Year	*N*	EFTR technique	Diameter (mm)	Time	Target lesion reached	En bloc resection	Pathology	R0 resection	Length hospital stay	Adverse events	Time to follow-up	Recurrence
Andrisani et al.[147]	2019	20 (rectal-10, Colonic-10)	FTRD	20 (6–42)	50 min	100%	91%	Adenoma, SEL, T1 carcinoma	90%	–	10%	3 mo	6.4%
Aepli et al[148]	2018	33 (R- 12, C-21)	FTRD	27 (18–42)	63 (26–150)	97%	88%	Adenoma, carcinoma, Polyp, NET	88%	3.1 (2–6) mo	13%	–	–
Albrecht et al[149]	2019	70 (R-19, C-48)	FTRD	19 (5–37)	95.5 (48–143)	100%	97%	Adenoma, SEL, T1 carcinoma	90.8%		12.9%	3 mo	6% for a denoma
Andrisani et al[150]	2017	20	FTRD	26 (10–42 mm)	–	100%	100%	Superficial colorectal neoplasms (T1 carcinoma, HGD)	100%	–	5%	3 mo	0%
Bauermeister et al[151]	2022	17	Hybrid EMR-FTRD	30 (18–50 mm)	35–160 min	100%	94.1%	Large colorectal adenomas	76.4%	–	23.5%- minor; no perforation/major bleeding	–	16.6%
Bulut et al[152]	2022	26	FTRD	23 (10–35 mm)	69 (30–162) min	89%	81%	Adenoma and adenocarcinoma	86%	–	11.5%	3–12 mo	10%
Xu et al[95]	2013	19	FTRD	18 (12–30 mm)	67 (45–130 min)	100%	94%, laparoscopic closure in 2/18	Colonic SEL originating from MP (<3 cm)	94%		16.7%	18 (6–36 mo)	0%
Fähndrich et al[153]	2015	17	Inoue Cap and OTSC ($n=16$), FTRD ($n=1$)	10–25 mm		100%	94%	Adenoma, carcinoma, NET	100%	–	0%	–	0%
Falt et al[125]	2021	52	FTRD	8–30 mm	16–65 min	100%	92%	Colorectal lesions $\leq$ 30 mm (adenoma, SET)	85%	1–7 d	13%	–	12%
Ichkhanian et al[154]	2021	95	FTRD	15.5 ± 6.4 mm	59.7 ± 31.8 min	98%	84.2%	Adenoma, carcinoma, SELs	82.7%	Mean 1.3 d	5.3%	61.7 ± 82.3 d	2.5%
Mão de-Ferro et al[155]	2019	9	FTRD	14–28 mm	Mean 55 min	100%	100%	Adenoma, NET	100%	1–2 d	0% major complications	4–12 mo	0%
Meier et al[106]	2017	10	EMR + FTRD	30–50 mm	65–140 min	100%	100%	Adenoma	100%	–	0%	3 mo	0%
Rushfeldt et al[156]	2021	10, all rectum	ESD+ TTS/ OTSC closure	30 (9–35 mm)	65–191 min	100%	100%	Adenoma, carcinoma, Polyp, NET	60%	1–3 d	20% delayed bleed	3–29 mo	20%
Schmidt et al[157]	2015	24	FTRD	24 (12–40 mm)	50 (10–177 min)	95.8%	83.3%	Adenoma, adenocarcinoma, SEL, suspected Hirschprung's disease	75%	4 (1–12 d)	4% minor bleed, 8% postpolypectomy syndrome	1.5–12 mo	20%
Schmidt et al[133]	2018	181	FTRD	15 (2–30 mm)	50 (3–190) min	100%	89.5%	Difficult adenoma, adenocarcinoma, SELs	76.9%	–	9.9%	3 mo	15.35
Valli et al[158]	2018	60	FTRD	24 (10–35 mm)	60 (15–177 min)	97%	91.4%	Adenoma, carcinoma, SELs	79%	–	7%	15 (2–54 mo)	0% for R0 resection
Van der Spek et al[159]	2018	51	FTRD ($n=48$), EMR + FTRD ($n=2$)	12.2 (2–30 mm)	–	88%	86%	Adenoma, carcinoma, NET	80%	–	13%	4 mo	10%
Velegraki et al[160]	2019	17	FTRD	12.7 (5–30 mm)	30 (10–90 min)	100%	82.3%	Adenoma, carcinoma, SELs	82.3%	1–3 d	17.6%	3 mo	0%
Vitali et al[161]	2018	13	FTRD	17 ± 4 mm	68 ± 35 min	100%	100%	Adenoma and adenocarcinoma	83.3%	2.5 ± 1.2 d	15.4%, postpolypectomy syndrome	Up to 12 mo	27%
Von Helden et al[162]	2019	30	FTRD	25 (14–33 mm)	34.5 (11–120 min)	93.3%	80%	Adenoma and adenocarcinoma	80%	–	19%, 6% serious-delayed perforation	Not mentioned	8% with R0 resection

Abbreviations: EMR, endoscopic mucosal resection; FTRD, full thickness resection device; HGD, high grade dysplasia; MP, muscularis propria; NET, neuroendocrine tumor; OTSC, over the scope clips; SELs, subepithelial lesions.

Table 4 Studies on endoscopic full thickness resection (EFTR) using full thickness resection device (FTRD) for peri-appendicular lesions

Author	Year	*N*	Technique	Diameter (mm)	Technical success	R0 resection	Adverse events	Recurrence
Bronzwaer et al	2018	7	Dedicated FTRD device	5–20 mm (all <20 mm)	100%	85.7%	1 abscess (post appendectomy), 1 appendicitis	–
Schmidbaur et al	2021	50	Dedicated FTRD device	Mean-18.3, SD-10.6	96%	64%	14% appendicitis, 2% perforation	–
Ichkhanian et al	2022	66	Dedicated FTRD device	Mean-14.5, SD-6.2	89%	93% for neoplastic lesions	17% appendicitis	12%

<20 mm.[57–59] For larger laterally spreading tumor (LST) (≤4 cm), ESD followed by EFTR with FTRD has been shown to be successful.[60,61] The main complication is appendicitis (14–17%).[57–59] Lesions involving >75% of the circumference have lower risk of appendicitis post-EFTR due to chronic obstruction.[62] Enterocolonic fistula due to small bowel entrapment has been reported.[63,64] Translation of adenoma tissue extramurally is reported in only an isolated case.[65,66] EFTR of intussuscepted appendix resected with conventional snare and clip has been described.[67]

EFTR for NET

EFTR of rectal and duodenal NETs is described mostly in case reports. Earlier reports described laparoscopy-assisted EFTR using EMR/ESD or inadvertent EFTR after duodenal EMR.[41–43] Resection of incompletely resected rectal NETs with OTSC-based EFTR and ESD followed by Overstitch was described later.[68,69] Use of FTRD device for rectal NETs was first reported in 2016.[70–72] A novel band ligation-assisted EFTR using the OTSC device has been described in animal model which could be helpful if FTRD device is unavailable.[17,73] Padlock clip-assisted resection of duodenal NET has been reported.[74] A study comparing transanal endoscopic microsurgery (TEM) with FTRD found that FTRD was equally effective with similar R0 resection rates with less operative time (19 minutes vs. 49 minutes) for small rectal NETs.[75]

FTRD for GIST and Other Subepithelial Lesions

Most of the earlier reports described endoscopic resection and laparoscopic defect closure.[76,77] Robotic laparoscopy-assisted EFTR was described recently.[78] EFTR has similar operating time and R0 resection rates compared with laparoscopy and was shown to be equivalent for GIST <2 cm.[79,80] A 100% R0 resection rate without any recurrence was shown in a series of 69 patients with GIST originating from MP resected with ESD and loop-clip closure.[81] Clip in line traction method, cap-assisted technique (in small GIST < 1.5 cm) and direct EFTR (for gastric fundal SELs with intraluminal growth pattern) can reduce the operating time.[82–85] Snare-assisted EFTR was shown to be cost effective compared with band ligation-assisted or ESD-assisted EFTR with similar efficacy and complication rates.[86] Omental patch, suturing device, or endoscopic loop ligation can be used for defect closure.[26,87–89] EFTR was shown to be equally effective as STER for gastric GISTs.[90]

Pre-closure techniques help maintain luminal insufflation during EFTR. Non-exposed EFTR for gastric GIST can be performed with full thickness plicator device or suturing platform.[13,33,91,92] EFTR of colonic GIST with FTRD device was also reported.[93] Technical difficulty of FTRD insertion into stomach can be overcome by prior use of sizing cap.[94]

Apart from stomach, there are reports of EFTR for SELs in esophagus, duodenum, and colon ►**Table 5**.[37,46,95,96] Lesions >35 mm, large extramural component, systemic spread, GI surgery or stenosis impeding insertion of EFTR device are contraindications of non-exposed EFTR for SELs.[97]

EFTR of Adenomas Arising at Diverticulum

Endoscopy resection of adenoma arising at diverticulum carries the high risk of perforation due to lack of muscle layer in diverticulum.[98] EFTR of inverted diverticulum can be done with "ligate and let go" technique whereas adenomas arising at diverticulum can be resected using OTSC-assisted EFTR with or without dedicated FTRD device.[99–101]

Diagnosis of Gastrointestinal Motility Disorders

Surgical full-thickness biopsy is essential to diagnose motility disorders such as Hirschsprung's disease and chronic intestinal pseudo-obstruction. A case series including four patients and a case report have shown the feasibility and safety of EFTR using FTRD.[102,103] The technical success was achieved in all patients with mean diameter of specimen and mean procedure time being 20 mm and 21 minutes, respectively.[102]

Hybrid EFTR

The limitations of various techniques of EFTR can be circumvented by combining two methods of EFTR. The major limitation of FTRD is inability to perform EFTR in large lesions (>20–25 mm). Hence, initially snare polypectomy/EMR/ESD/endoscopic variceal ligation (EVL) to reduce the size of the lesion for completion of EFTR by FTRD/endoscopic suturing has been described.[73,91,104–110]

Hybrid NOTES

NOTES is usually performed through natural orifice like mouth or anus, however, combining percutaneous laparoscopy with

Table 5 Studies on endoscopic full thickness resection (EFTR) for gastric sub-epithelial lesions (SELs)

Author	Year	*N*	Dissection technique	Closure technique	Diameter (mm)	Time	En bloc resection	Pathology	R0 resection	Length hospital stay	Adverse events	Time to follow-up	Recurrence
Zhou et al	2011	26	ESD	TTS Clips	28 mm (12–45 mm)	105 min (60–145)	100%	All SELs (GIST, glomus, schwannoma, leiomyoma)	85.7%	5.5 d (3–8)	None	8 mo	0%
Ye et al[163]	2014	51	ESD	TTS Clip and endoloop	24 mm (13–35 mm)	52 (30–125 min)	98%	SELs arising from MP (Leiomyoma, GIST)	–	3.9 d (3–9)	None	22.4 mo	0%
Shi et al[164]	2013	20	ESD	Endoloop and TTS clips	0.4–3 cm	100 min Suture time 8–20 min	100%	SELs arising from MP (GIST, Leiomyoma, Schwannoma, Leiomyoma, GCT, Pancreatic rest)	–	1–7 d	5 had fever and pain abdomen	2–13 mo	0%
Wang et al[165]	2022	21	ESD	Endoscopic Nylon loop ligation	23 mm (19–25 mm)	Closure time 9 min (6–15)	100%	SELs from MP (GIST, Leiomyoma)	–	5 d (3–6)	1 with peritonism, treated conservatively	6–24 mo	0%
Tang et al[24]	2016	34	ESD	TTS Clips	1–5 cm	50–100 min	100%	SELs from MP (Mainly spindle cell tumors)	–	3–5 d	1 pneumoperitoneum	5–23 mo	0%
Jung et al[166]	2021	8	ESD	TTS Clips	1–2.7 cm	25–96 min	100%	GIST	50%	5–18	1 bleeding	5–50 mo	0%
Huang et al[167]	2018	46	ESD	TTS Clips	1.2–4.5 cm	56–188 min	100%	GIST from MP, Leiomyoma	100%	4–11	None	Mean 6 mo	0%
Huang et al	2014	35	ESD	TTS Clips	2–4.5 cm	60–155 min	100%	GIST, Leiomyoma, Schwannoma	100%	4–10	None	Mean 6 mo	0%
Guo et al[30]	2015	23	ESD	OTSC	0.6–2 cm	16–104 min; closure time 2–12 min	100%	SELs from M*p* <2 cm (GIST, Leiomyoma)	100%	2–5	Post-operative fever -3, Localized peritonitis-2	1–6 mo	0%
Feng et al[23]	2014	52	ESD	TTS Clips	0.5–4.8 cm	30–270 min	100%	GIST, Leiomyoma, Schwannoma	100%	4–7	No severe complication, distension in 5	2–24 mo	0%
Li et al[168]	2021	37	ESD	TTS Clips (ZIP technique)	0.5–2.5 cm	30–120 min (closure 5–20 min)	100%	GIST, Leiomyoma, Schwannoma, Pancreatic rest	–	–	Peritonitis 1, pain and fever in nearly half	6–22 mo	0%
Meier et al[169]	2020	29	Gastric FTRD	Dedicated FTRD-OTSC	0.5–1.5 cm	24–90 min	89.7%	SELs <2 cm (GIST, Leiomyoma)	76%	–	31% minor bleed	3 mo	0%
Schlag et al[170]	2013	20	Twin grasper and snare	OTSC or laparoscopic	0.7–3 cm	19–95 min	100%	SELs <3 cm	85%	–	None	3 mo	0%
Shichijo et al[171]	2019	8	ESD	TTS cup and endoloop/ TTS only/ OTSC only	1–3.5 cm	50–166 min	100%	GIST with intraluminal growth pattern	37.5%, rest were indeterminate	4–11 d	No serious adverse events	–	–
Sun et al[81]	2018	69	ESD	TTS Clip and endoloop	0.6–6 cm	17–600 min; mean 128 min	100%	SELs (GIST, leiomyoma, hemangioma, and schwannoma)	100%	–	7.25%	7–84 mo	0%
Yang et al[172]	2015	41	ESD	TTS clips (86%) and OTSC (14%)	16.34 ± 5.89	78.82 ± 46.44 min (*higher with more size and greater curvature)*	100%	SELs	100%	5.39 ± 1.14	22%	–	–

Abbreviations: ESD, endoscopic submucosal dissection; FTRD, full thickness resection device; GCT, granulose cell tumor; GIST, gastrointestinal stromal tumor; MP, muscularis propria; OTSC, over the scope clips; SELs, sub-epithelial lesions; TTS, through the scope.

EFTR is known as hybrid NOTES.[111] These include: LAEFR-laparoscopy-assisted endoscopic full thickness resection (EFTR), NEWS-non-exposed endoscopic wall-inversion surgery, NESS-EFTR: non-exposure simple suturing EFTR with or without lymphadenectomy in gastric SELs/EGC/duodenal NET, etc. (►**Table 6**).[41,42,77,112–114] Modified laparoscopic intragastric surgery in which resection is performed under endoscopic vision by laparoscopic instruments has been described for gastric GIST.[115] NESS-EFTR has the advantage of preventing peritoneal seeding in EGC[114] (►**Fig. 6**). Sentinel lymph node dissection under laparoscopic guidance using Tc-99m-phytate and indocyanine green is feasible as shown in SENORITA 3 pilot study.[114] Direct endoscopic visualization can reduce excessive gastric resection and can avoid gastrectomy in majority. Manual suture or linear stapler is used for suturing.[116] Postoperative leak and stasis are the adverse events.[117]

Competing Technologies

EFTR can be performed by ESD, FTRD, Hybrid NOTES, hybrid EFTR, and transanal endoscopic microsurgery (TEMS) for rectal tumors. The major limitation of FTRD is the maximum size of the lesion that can be treated. This can be overcome by hybrid EFTR. Hybrid NOTES techniques could be useful for oncologic resection of EGC and for SELs. For small SELs, EFTR is a better option than hybrid NOTES. Large rectal tumors can be resected in full thickness by TEMS as a primary therapy after FTRD failure.[118,119]

Comparative Studies between Different Techniques of EFTR

Studies have compared EFTR modalities with different levels of invasiveness: surgery, laparoscopy-assisted EFTR, TEMS, ESD, STER, and FTRD, etc. Laparoscopic resection and EFTR showed comparable en bloc resection rates, operating time, hospital stay and complications.[120] For GIST <2 cm, EFTR was associated with lower complication rates with comparable R0 resection rates compared with LECS.[80] For gastric SELs with MP involvement, EFTR was associated with lower cost, faster postoperative recovery compared with surgery with higher en bloc resection rates with surgery for tumors >3 cm.[121] Recent studies comparing non-exposed EFTR and laparoscopy-assisted EFTR showed higher procedure time (110 vs. 189 minutes; p <0.0001) with the lower rate of tumor seeding with the former.[122]

EFTR was shown to be equally effective compared with TEMS for rectal NETs with shorter operating time.[75] Cap-assisted EFTR was shown to be particularly helpful for small GIST (<1.5 m) shorter operating time with lower complication rates. Dental floss traction can reduce the operating time with lower incidence of electrocoagulation syndrome for gastric fundal SELs originating from MP.[35,123] A study comparing STER with EFTR for gastric GIST showed similar R0 resection rates, operating time, and complication rates whereas suture time and clip requirement were lower with STER.[90] However, STER can be technically difficult in areas like stomach and rectum where tunnelling can be challenging.[124] Another study comparing ESD and EFTR for colonic neoplasia <3 cm showed higher technical success

Table 6 Summary of studies evaluating hybrid endoscopic full thickness resection (EFTR) and hybrid natural orifice trans-luminal endoscopic surgery (NOTES)

Author	Year	Diagnosis	Method	Number	Tumor size (mean, mm)	Complete reaction rate (%)	Closure method	Lymphadenectomy	Conversion to gastrectomy	Complications
Abe et al	2009	Early gastric cancer (EGC)	LAEFR	1	30	100	Manual suture	Yes, Indocyanine green	0%	None
Abe et al	2009	Gastric SET	LAEFR	4	37	100	Manual suture	No	0%	None
Cho et al[173]	2011	EGC	Hybrid NOTES	14	26	100	Linear stapler plus manual suture	Yes, laparoscopic	35.7%	Leak ($n = 1$)
Mori et al	2015	Gastric GIST	Hybrid EFTR	16	28.3	100%	Suture	No	0%	0%
Kwon et al[174]	2015	SET	GIST close to EGJ	6	31	100%	Manual suture	No	0%	0
Eom et al	2020	EGC	NESS-EFTR	18	16.5	83.3%	Laparoscopic suturing with endoscopic loop closure	Sentinel lymph node	5.6%	Leak ($n = 1$)
Mahawongkajit et al[175]	2020	Upper GI SETs	LCES,[10] NEWS[6]	16	56 (LECS), 21 (NEWS)	100%	Staple or suture	No	0%	0

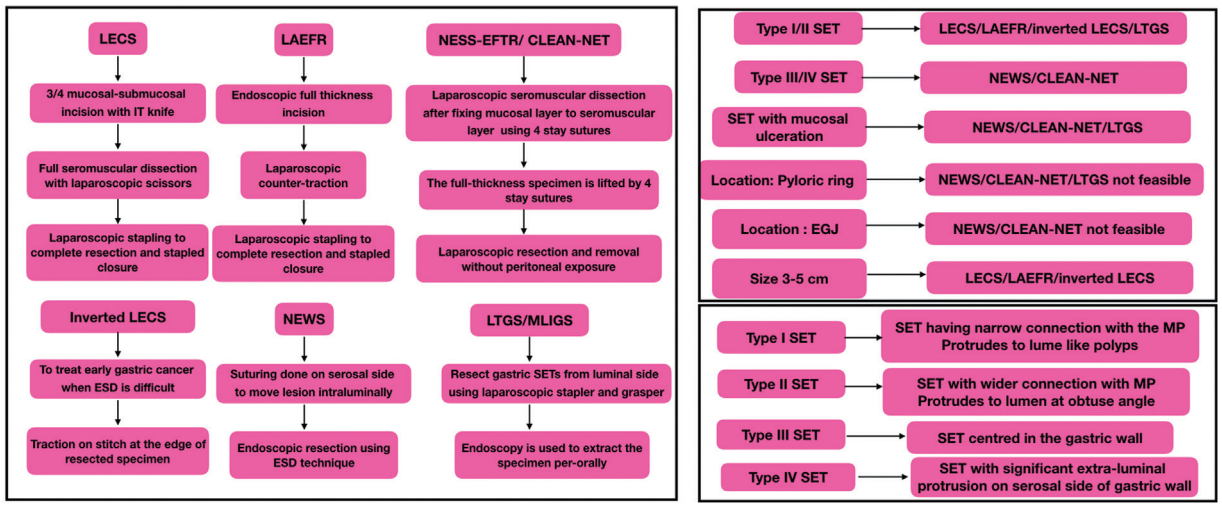

Fig. 6 Schematic representation of different hybrid natural orifice transluminal endoscopic surgery (NOTES) techniques, their specific indications, and classification of gastric subepithelial tumors (SETs). CLEAN-NET, combination of laparoscopic and endoscopic approaches for treatment of neoplasia with a non-exposure technique; EGJ- esophagogastric junction; ESD, endoscopic submucosal dissection; LAEFR, laparoscopy-assisted endoscopic full thickness resection; NEWS, non-exposed endoscopic wall-inversion surgery; LECS, laparoscopy endoscopic co-operative surgery; LTGS, laparoscopic transgastric surgery; MLIGS, modified laparoscopic intra-gastric surgery; NESS-EFTR, non-exposure simple suturing EFTR.

Table 7 Advantages and limitations of various endoscopic full thickness resection (EFTR) techniques

Method	Dissection technique	Closure technique	Advantages	Disadvantages
Exposed EFTR				
Non-tunneling techniques	ESD	Loop and clip, OTSC, endoscopic suturing device	Higher technical success and R0 resection	High risk of perforation, peritoneal seeding and technically challenging closure in collapsed stomach
Tunneling technique	STER:Submucosal tunnelling and tumor dissection	Mucosal closure	Low risk of peritoneal contamination and tumor seeding	Feasible for lesions <4 cm and mainly distal esophageal and gastric cardia lesions, may not be feasible to create tunnel in all anatomical locations
Non-exposed EFTR				
FTRD	Snare fitted with FTRD device	OTSC clip	High technical and en bloc resection rates, enables full thickness biopsy, useful for recurrent and non-lifting lesions and difficult locations; shorter procedure time	Not feasible for large tumors (>25 mm), risk of appendicitis, small bowel entrapment and resultant enterocolonic fistula
Non-exposed endoscopic wall-inversion surgery (NEWS)	Excision using ESD technique after tumor inversion into lumen using laparoscopic guidance	Laparoscopic suturing prior to resection followed by endoscopic suturing after resection	Low risk of peritoneal contamination and tumor seeding	Applicable for small lesions as tumor is retrieved endoscopically
Hybrid NOTES	Dissection using endoscopic and laparoscopic technique	Laparoscopic stapling device	Anatomic and functional preservation of gut by precise definition of tumor boundary, can allow oncologic resection with lymphadenectomy for superficial GI carcinoma	Risk of peritoneal contamination and tumor seeding
Hybrid EFTR	EMR/ESD/Band ligation followed by OTSC and final resection	OTSC closure with or without additional TTS clip closure	Complete endoscopic full thickness resection can be performed for large lesions	May not be technically feasible for all lesions, tumor removed piecemeal, cannot exclude possibility of lymph nodal dissemination

Abbreviations: ESD, endoscopic submucosal dissection; FTRD, full thickness resection device; OTSC, over the scope clips; STER, submucosal tunnelling and endoscopic resection; TTS, through the scope.

and R0 resection with lower complications and operating time with EFTR although risk of residual neoplasia is higher.[125] Pre-resection closure with OTSC followed by snare was shown to be faster with lower complications compared with ESD followed by post-resection OTSC closure.[126]

A recent cost-effectiveness analysis showed that EFTR is cost effective not only with respect to surgery but also other minimally invasive endoscopic techniques for complex colorectal lesions.[127]

Limitations and Other Potential

Advantages and limitations of various EFTR techniques have been described in ►**Table 7**.

EFTR has been used in other settings as anecdotal reports as in endoscopic transgastric fenestration for pancreatic walled off necrosis, EFTR of ectopic splenic nodules, EFTR of Dieulafoy's lesion and in special situations (post liver transplant scenario and on anticoagulation).[128–132]

Complications

Apart from well-known complications of EFTR like perforation and bleeding (immediate or delayed), post-polypectomy syndrome, appendicitis (occlusion of appendicular orifice),[133] other unique adverse events have been described with EFTR. Overall complications occur in 12% of the patients.[51] Colonic obstruction by OTSC clip and delayed perforation post-EFTR in suspected gastroparesis due to over-distension have been reported.[134,135] Fracture of FTRD device snare wire warranting additional snare resection and/or TEMS are among other adverse events.[118,136] The risk of tumor seeding during EFTR of EGC can be minimized by non-exposure technique.[137] Enterocolonic fistula with small bowel intussusception causing peritonitis and mortality have been described following OTSC closure after resection of rectal LST.[138]

Contraindications

Contraindications to EFTR include locally (nodal or extraluminal vascular invasion) or systematically advanced tumor and tumors with malignant potential (e.g., GIST) larger than 5 cm. Tumors greater than 3 to 4 cm in shortest diameter are often difficult to extract per orally without piecemeal removal.[139]

Learning Curve

EFTR being a relatively new modality, there are no validated objective tool to assess competency in EFTR. Moreover, the learning curve and style may vary with each trainee. Hence specific feedback from the mentor is essential at least in the initial phase. It is important to recognize that device-assisted EFTR (e.g., FTRD) has shorter learning curve compared with conventional EFTR.[140]

Post OTSC Clip Artifact

It is important to recognize different forms of post clipping artifact post-OTSC which can range from central depression, central erosion, semi pedunculated polypoidal lesions, and even leiomyoma like mesenteric cell proliferation due to its bear claw configuration and transmural tissue capture.[141–144] Examination of the surface pattern on white light/narrow band imaging is thus important to differentiate artifacts from recurrent/residual lesion which may warrant aggressive procedures like re-FTRD or surgery.[143]

Conclusion

Exposed and non-exposed EFTRs are emerging techniques for the resection of non-lifting or recurrent adenoma associated with fibrosis, SELs with deeper invasion, and superficial GI neoplasia. Newer dissection, traction, and closure devices have revolutionized the techniques of EFTR. Novel methods like hybrid EFTR, hybrid NOTES, and novel robotic EFTR have the potential of expanding the indications of EFTR in future and enable even oncologic resection. Technological technical advances can further improve clinical outcomes in EFTR.

Authors' Contribution
M.R. and P.P. did the conceptualization, literature review, and wrote the original draft. P.I. and M.R. worked on illustrations and images. M.T., M.R., P.P., D.N.R., and P.I. did the proof reading and critical review. M.R., P.P., P.I., D. N.R., and M.T. approved the final manuscript.

Funding
None.

Conflict of Interest
None declared.

Acknowledgment
None.

References

1 Kaan HL, Ho KY. Endoscopic full thickness resection for gastrointestinal tumors—challenges and solutions. Clin Endosc 2020; 53(05):541–549
2 Aslanian HR, Sethi A, Bhutani MS, et al;ASGE Technology Committee. ASGE guideline for endoscopic full-thickness resection and submucosal tunnel endoscopic resection. VideoGIE 2019;4 (08):343–350
3 Rajan E, Gostout CJ, Burgart LJ, et al. First endoluminal system for transmural resection of colorectal tissue with a prototype full-thickness resection device in a porcine model. Gastrointest Endosc 2002;55(07):915–920
4 Full thickness resection device (FTRD) for endoluminal removal of large bowel tumours: development of the instrument and related experimental studies. Minim Invasive Ther Allied Technol 2001;10(06):301–309
5 Schurr MO, Baur FE, Krautwald M, et al. Endoscopic full-thickness resection and clip defect closure in the colon with the new FTRD system: experimental study. Surg Endosc 2015;29(08): 2434–2441
6 Ikeda K, Fritscher-Ravens A, Mosse CA, Mills T, Tajiri H, Swain CP. Endoscopic full-thickness resection with sutured closure in a porcine model. Gastrointest Endosc 2005;62(01):122–129
7 Kaehler GF, Langner C, Suchan KL, Freudenberg S, Post S. Endoscopic full-thickness resection of the stomach: an experimental approach. Surg Endosc 2006;20(03):519–521

8 Elmunzer BJ, Waljee AK, Taylor JR, et al. Endoscopic full-thickness resection of gastric lesions using a novel grasp-and-snare technique: evaluation in a porcine survival model. Surg Endosc 2010;24(07):1573–1580
9 Goto O, Mitsui T, Fujishiro M, et al. New method of endoscopic full-thickness resection: a pilot study of non-exposed endoscopic wall-inversion surgery in an ex vivo porcine model. Gastric Cancer 2011;14(02):183–187
10 Mori H, Rafiq K, Kobara H, et al. Development of pure endoscopic full-thickness resection with mechanical countertraction and double-armed bar suturing systems. Gastrointest Endosc 2014; 79(01):24–25
11 Sun B, Guo J, Ge N, et al. Endoscopic ultrasound-guided puncture suture device versus metal clip for gastric defect closure after endoscopic full-thickness resection: a randomized, comparative, porcine study. Endosc Ultrasound 2016;5(04):263–268
12 Guo J, Sun B, Sun S, et al. Endoscopic puncture-suture device to close gastric wall defects after full-thickness resection: a porcine study. Gastrointest Endosc 2017;85(02):447–450
13 Huberty V, Leclercq L, Hiernaux M, et al. Endoscopic full-thickness resection using an endoluminal-suturing device: a proof-of-concept study. Endosc Int Open 2019;7(11): E1310–E1315
14 Kitakata H, Itoh T, Kinami S, et al. Sealed endoscopic full-thickness resection for gastric cancer: a pilot study in an ex vivo and in vivo porcine model. Endosc Int Open 2019;7(01): E36–E42
15 Morita FHA, Sakai CM, Kawamoto FM, de Moura EGH, Sakai P. An innovative laparoscopic and endoscopic technique in an animal model: combined gastric full-thickness tumor resection. Endosc Int Open 2019;7(04):E440–E445
16 Kamba S, Kobayashi M, Koizumi A, et al. Intra-abdominal pressure during endoscopic full-thickness resection comparing manual and automatic control insufflation: a block-randomized porcine study. Surg Endosc 2020;34(04):1625–1633
17 Kobara H, Nishiyama N, Fujihara S, et al. Traction-assisted endoscopic full-thickness resection followed by O-ring and over-the-scope clip closure in the stomach: an animal experimental study. Endosc Int Open 2021;9(01):E51–E57
18 Visrodia K, Sethi A. How to learn and perform endoscopic submucosal dissection and full-thickness resection in the colorectum in the United States. Gastrointest Endosc Clin N Am 2019; 29(04):647–657
19 Lee CK, Lee SH, Chung IK, et al. Endoscopic full-thickness resection of a gastric subepithelial tumor by using the submucosal tunnel technique with the patient under conscious sedation (with video). Gastrointest Endosc 2012;75(02):457–459
20 Donatelli G, Fuks D, Pourcher G, et al. Submucosal tunneling endoscopic resection (STER) with full-thickness muscle excision for a recurrent para-aortic esophageal leiomyoma after surgery. Endoscopy 2017;49(S01):E86–E87
21 Zhou PH, Yao LQ, Qin XY, et al. Endoscopic full-thickness resection without laparoscopic assistance for gastric submucosal tumors originated from the muscularis propria. Surg Endosc 2011;25(09):2926–2931
22 Granata A, Martino A, Ligresti D, et al. Closure techniques in exposed endoscopic full-thickness resection: overview and future perspectives in the endoscopic suturing era. World J Gastrointest Surg 2021;13(07):645–654
23 Feng Y, Yu L, Yang S, et al. Endolumenal endoscopic full-thickness resection of muscularis propria-originating gastric submucosal tumors. J Laparoendosc Adv Surg Tech A 2014;24(03):171–176
24 Tang AL, Liao XQ, Shen SR, Xiao DH, Yuan YX, Wang XY. Application of clips assisted with foreign body forceps in defect closure after endoscopic full-thickness resection. Surg Endosc 2016;30(05):2127–2131
25 Zhang Y, Fan Z, Wu J, Huang X, Miao L, Wang X. Endoscopic purse-string suture for the gastric wall defect after full-thickness resection. Zhonghua Wei Chang Wai Ke Za Zhi 2015;18(02): 150–154
26 Inayat F, Aslam A, Grunwald MD, Hussain Q, Hurairah A, Iqbal S. Omental patching and purse-string endosuture closure after endoscopic full-thickness resection in patients with gastric gastrointestinal stromal tumors. Clin Endosc 2019;52(03): 283–287
27 Shi D, Li R, Chen W, et al. Application of novel endoloops to close the defects resulted from endoscopic full-thickness resection with single-channel gastroscope: a multicenter study. Surg Endosc 2017;31(02):837–842
28 Wu N, Liu S, Chen M, et al. The prepurse-string suture technique for gastric defect after endoscopic full-thickness resection (with video). Medicine (Baltimore) 2018;97(36):e12118
29 Kappelle WFW, Backes Y, Valk GD, Moons LMG, Vleggaar FP. Endoscopic full-thickness resection of gastric and duodenal subepithelial lesions using a new, flat-based over-the-scope clip. Surg Endosc 2018;32(06):2839–2846
30 Guo J, Liu Z, Sun S, et al. Endoscopic full-thickness resection with defect closure using an over-the-scope clip for gastric subepithelial tumors originating from the muscularis propria. Surg Endosc 2015;29(11):3356–3362
31 Hajifathalian K, Ichkhanian Y, Dawod Q, et al. Full-thickness resection device (FTRD) for treatment of upper gastrointestinal tract lesions: the first international experience. Endosc Int Open 2020;8(10):E1291–E1301
32 Granata A, Martino A, Amata M, Ligresti D, Traina M. Gastrointestinal exposed endoscopic full-thickness resection in the era of endoscopic suturing: a retrospective single-center case series. Wideochir Inne Tech Malo Inwazyjne 2021;16(02):321–328
33 Walz B, von Renteln D, Schmidt A, Caca K. Endoscopic full-thickness resection of subepithelial tumors with the use of resorbable sutures (with video). Gastrointest Endosc 2011;73 (06):1288–1291
34 Schmidt A, Bauder M, Riecken B, von Renteln D, Muehleisen H, Caca K. Endoscopic full-thickness resection of gastric subepithelial tumors: a single-center series. Endoscopy 2015;47(02): 154–158
35 Shi Q, Li B, Qi ZP, et al. Clinical values of dental floss traction assistance in endoscopic full-thickness resection for submucosal tumors originating from the muscularis propria layer in the gastric fundus. J Laparoendosc Adv Surg Tech A 2018;28(10): 1261–1265
36 Fritscher-Ravens A, Cuming T, Jacobsen B, et al. Feasibility and safety of endoscopic full-thickness esophageal wall resection and defect closure: a prospective long-term survival animal study. Gastrointest Endosc 2009;69(07):1314–1320
37 Muramoto T, Sakai E, Ohata K. Endoscopic full-thickness resection for esophageal submucosal tumor. Dig Endosc 2020;32(03): e43–e44
38 Zhu S, Lin J, Huang S. Successful en bloc endoscopic full-thickness resection of a giant cervical esophageal leiomyoma originating from muscularis propria. J Cardiothorac Surg 2019;14(01):16
39 Roberts JR, Koro K, Yeh MM, Saunders MD, Templeton AW. Endoscopic resection of gastric adenocarcinoma by use of a full-thickness resection device. VideoGIE 2018;3(08):244–246
40 Kratt T, Kueper M, Boesmueller H, Koenigsrainer A, Goetz M. Endoscopic full-thickness resection of gastric metastasis from malignant melanoma by use of a novel over-the-scope device. Gastrointest Endosc 2016;84(02):368
41 Tsujimoto H, Ichikura T, Nagao S, et al. Minimally invasive surgery for resection of duodenal carcinoid tumors: endoscopic full-thickness resection under laparoscopic observation. Surg Endosc 2010;24(02):471–475
42 Abe N, Takeuchi H, Shibuya M, et al. Successful treatment of duodenal carcinoid tumor by laparoscopy-assisted endoscopic full-thickness resection with lymphadenectomy. Asian J Endosc Surg 2012;5(02):81–85

43 Hatogai K, Oono Y, Fu KI, et al. Unexpected endoscopic full-thickness resection of a duodenal neuroendocrine tumor. World J Gastroenterol 2013;19(26):4267–4270
44 Schmidt A, Meier B, Cahyadi O, Caca K. Duodenal endoscopic full-thickness resection (with video). Gastrointest Endosc 2015;82(04):728–733
45 Bauder M, Schmidt A, Caca K. Endoscopic full-thickness resection of duodenal lesions-a retrospective analysis of 20 FTRD cases. United European Gastroenterol J 2018;6(07):1015–1021
46 Ren Z, Lin SL, Zhou PH, et al. Endoscopic full-thickness resection (EFTR) without laparoscopic assistance for nonampullary duodenal subepithelial lesions: our clinical experience of 32 cases. Surg Endosc 2019;33(11):3605–3611
47 Wei Y, Zhou Q, Ji M, Zhang S, Li P. Over-the-scope clip-assisted endoscopic full-thickness resection has potential to treat complex nonampullary duodenal lesions: a single-center case series. BMC Gastroenterol 2021;21(01):476
48 Konomatsu K, Kuwai T, Yamaguchi T, et al. Endoscopic full-thickness resection for inverted Meckel's diverticulum using double-balloon enteroscopy. Endoscopy 2017;49(S 01):E66–E67
49 Jiang B, Wang LM, Ong P, Ang TL. Gastrointestinal: a case of mid-ileum endometriosis presenting as small bowel intussusception treated by single-balloon enteroscopy with endoscopic full-thickness resection. J Gastroenterol Hepatol 2022;37(07):1211
50 Snauwaert C, Jouret-Mourin A, Piessevaux H. Endoscopic full-thickness resection of a nonlifting adenoma in an ileal pouch using an over-the-scope full-thickness resection device. Endoscopy 2015;47(Suppl 1 UCTN):E344–E345
51 Dolan RD, Bazarbashi AN, McCarty TR, Thompson CC, Aihara H. Endoscopic full-thickness resection of colorectal lesions: a systematic review and meta-analysis. Gastrointest Endosc 2022;95(02):216–224.e18
52 Fahmawi Y, Hanjar A, Ahmed Y, et al. Efficacy and safety of full-thickness resection device (FTRD) for colorectal lesions endoscopic full-thickness resection: a systematic review and meta-analysis. J Clin Gastroenterol 2021;55(04):e27–e36
53 Wannhoff A, Meier B, Caca K. Systematic review and meta-analysis on effectiveness and safety of the full-thickness resection device (FTRD) in the colon. Z Gastroenterol 2022;60(05):741–752
54 Kuellmer A, Mueller J, Caca K, et al;FTRD study group. Endoscopic full-thickness resection for early colorectal cancer. Gastrointest Endosc 2019;89(06):1180–1189.e1
55 Shahidi N, Bourke MJ. Endoscopic full-thickness resection for invasive colorectal neoplasia: hype or here to stay? Gastrointest Endosc 2019;89(06):1190–1192
56 Zwager LW, Bastiaansen BAJ, van der Spek BW, et al.Dutch eFTR Group. Endoscopic full-thickness resection of T1 colorectal cancers: a retrospective analysis from a multicenter Dutch eFTR registry. Endoscopy 2022;54(05):475–485
57 Bronzwaer MES, Bastiaansen BAJ, Koens L, Dekker E, Fockens P. Endoscopic full-thickness resection of polyps involving the appendiceal orifice: a prospective observational case study. Endosc Int Open 2018;6(09):E1112–E1119
58 Schmidbaur S, Wannhoff A, Walter B, et al. Risk of appendicitis after endoscopic full-thickness resection of lesions involving the appendiceal orifice: a retrospective analysis. Endoscopy 2021;53(04):424–428
59 Ichkhanian Y, Barawi M, Seoud T, et al. Endoscopic full-thickness resection of polyps involving the appendiceal orifice: a multicenter international experience. Endoscopy 2022;54(01):16–24
60 Lupu A, Jacques J, Rivory J, et al. Hybrid endoscopic submucosal dissection using a full-thickness resection device allows en bloc resection of a large adenoma deeply invading the appendix. Endoscopy 2018;50(10):E296–E298
61 Andrisani G, Di Matteo F. Endoscopic resection of a large adenocarcinoma involving the appendix using a full-thickness resection device. Endoscopy 2019;51(12):1181–1182
62 Bronswijk M. Endoscopic full-thickness resection and post-procedural appendicitis: every advantage has its disadvantage. Endoscopy 2021;53(05):561
63 Biswas S, Gerges C, Kandler J, Neuhaus H, Beyna T. Endoscopic full-thickness resection: an unexpected juncture (with video). Gastrointest Endosc 2020;91(06):1406–1408
64 Vargas JI, Rowsell C, Mosko JD. Enterocolonic fistula after endoscopic full-thickness resection of a peri-appendiceal orifice adenoma. Gastrointest Endosc 2020;91(06):1405–1406
65 Dumoulin FL, Gorris DG, Berger S, Hildenbrand R, Sido B. Full-thickness resection with an over-the-scope device: possible translocation of adenoma tissue in a case of an incomplete resection at the appendix. Endosc Int Open 2018;6(05):E622–E624
66 Schurr M, Gottwald T. Comment on Dumoulin FL et al. Full-thickness resection with an over-the-scope device: possible translocation of adenoma tissue in a case of an incomplete resection at the appendix. Endosc Int Open 2018;6(10):E1264–E1265
67 Hammoud GM, Quick J, Samiullah S, Rao D, Ibdah JA. Endoscopic full-thickness resection of a long intussuscepted appendix by use of a colonoscope. VideoGIE 2018;4(01):34–36
68 Azzolini F, Cecinato P, Iori V, De Marco L, Sassatelli R. Endoscopic full-thickness resection for suspected residual rectal neuroendocrine tumor and closure of the defect with a new suturing system. Endoscopy 2015;47(Suppl 1):E556–E557
69 Klare P, Burlefinger R, Neu B, et al. Over-the-scope clip-assisted endoscopic full-thickness resection after incomplete resection of a rectal neuroendocrine tumor. Endoscopy 2015;47(suppl 1 UCTN):E47–E48
70 Grauer M, Gschwendtner A, Schäfer C, Neumann H. Resection of rectal carcinoids with the newly introduced endoscopic full-thickness resection device. Endoscopy 2016;48(Suppl 1):E123–E124
71 Tashima T, Nonaka K, Ryozawa S. Successful endoscopic en bloc full-thickness and complete resection for two adjacent rectal neuroendocrine tumors. Dig Endosc 2019;31(05):592
72 Cortez-Pinto J, Mão de Ferro S, Castela J, Claro I, Chaves P, Dias Pereira A. Duodenal neuroendocrine tumour resection with a new duodenal full-thickness resection device. GE Port J Gastroenterol 2020;27(04):290–292
73 Kobara H, Nishiyama N, Fujihara S, Masaki T. Ligation-assisted endoscopic full-thickness resection with over-the-scope clip targeted for neuroendocrine tumors. Ann Gastroenterol 2020;33(04):436
74 Sonthalia N, Shah BB, Goenka MK. Padlock clip-assisted endoscopic full-thickness resection of a duodenal neuroendocrine tumour: a safe alternative to endoscopic submucosal dissection. Endoscopy 2022 Jul;54(07):E391–E393
75 Brand M, Reimer S, Reibetanz J, Flemming S, Kornmann M, Meining A. Endoscopic full thickness resection vs. transanal endoscopic microsurgery for local treatment of rectal neuroendocrine tumors—a retrospective analysis. Int J Colorectal Dis 2021;36(05):971–976
76 Mori H, Kobara H, Fujihara S, et al. Establishment of the hybrid endoscopic full-thickness resection of gastric gastrointestinal stromal tumors. Mol Clin Oncol 2015;3(01):18–22
77 Willingham FF, Reynolds P, Lewis M, Ross A, Maithel SK, Rocha FG. Hybrid push-pull endoscopic and laparoscopic full thickness resection for the minimally invasive management of gastrointestinal stromal tumors: a pilot clinical study. Gastroenterol Res Pract 2015;2015:618756
78 Saumoy M, Guenthart B, Madanat L, Afaneh C, Kahaleh M. Robotic-assisted endoscopic full-thickness resection of a gastrointestinal stromal tumor: the tip of the iceberg. Endoscopy 2018;50(08):E216–E217
79 Huang LY, Cui J, Lin SJ, Zhang B, Wu CR. Endoscopic full-thickness resection for gastric submucosal tumors arising from the

muscularis propria layer. World J Gastroenterol 2014;20(38): 13981–13986
80 Wang H, Feng X, Ye S, et al. A comparison of the efficacy and safety of endoscopic full-thickness resection and laparoscopic-assisted surgery for small gastrointestinal stromal tumors. Surg Endosc 2016;30(08):3357–3361
81 Sun M, Song J, Song X, Liu B. Endoscopic full-thickness resection for gastric subepithelial tumors originating from the muscularis propria: a 69-case series. Surg Laparosc Endosc Percutan Tech 2018;28(01):e12–e17
82 Tian X, Shi B, Chen WQ. Modified endoscopic full-thickness resection of gastric stromal tumor originating from the muscularis propria layer. J Gastrointest Oncol 2020;11(02):461–466
83 Fukuda H, Uedo N, Shichijo S. Traction-assisted endoscopic full-thickness resection for extraluminal type gastrointestinal stromal tumor. Endosc Int Open 2021;9(08):E1243–E1245
84 Yang J, Ni M, Jiang J, et al. Comparison of endoscopic full-thickness resection and cap-assisted endoscopic full-thickness resection in the treatment of small ($\leq$1.5 cm) gastric GI stromal tumors. Gastrointest Endosc 2022;95(04):660–670.e2
85 Hu J, Ge N, Wang S, et al. Direct endoscopic full-thickness resection for submucosal tumors with an intraluminal growth pattern originating from the muscularis propria layer in the gastric fundus. BMC Gastroenterol 2020;20(01):70
86 Ge N, Hu JL, Yang F, Yang F, Sun SY. Endoscopic full-thickness resection for treating small tumors originating from the muscularis propria in the gastric fundus: an improvement in technique over 15 years. World J Gastrointest Oncol 2019;11(11):1054–1064
87 Xu MM, Angeles A, Kahaleh M. Endoscopic full-thickness resection of gastric stromal tumor: one and done. Endoscopy 2018;50 (02):E42–E43
88 Kerdsirichairat T, Vosoughi K, Ichkhanian Y, et al. Endoscopic full-thickness resection with omental patch closure for a gastric stromal tumor in the gastric cardia. Endoscopy 2019;51(10): E278–E279
89 Sachdev AH, Iqbal S, Ribeiro IB, de Moura DTH. Use of omental patch and endoscopic closure technique as an alternative to surgery after endoscopic full thickness resection of gastric intestinal stromal tumors: a series of cases. World J Clin Cases 2020;8(01):120–125
90 Tan Y, Tang X, Guo T, et al. Comparison between submucosal tunneling endoscopic resection and endoscopic full-thickness resection for gastric stromal tumors originating from the muscularis propria layer. Surg Endosc 2017;31(08):3376–3382
91 von Renteln D, Riecken B, Walz B, Muehleisen H, Caca K. Endoscopic GIST resection using FlushKnife ESD and subsequent perforation closure by means of endoscopic full-thickness suturing. Endoscopy 2008;40(Suppl 2):E224–E225
92 von Renteln D, Rösch T, Kratt T, Denzer UW, El-Masry M, Schachschal G. Endoscopic full-thickness resection of submucosal gastric tumors. Dig Dis Sci 2012;57(05):1298–1303
93 Probst A, Schaller T, Messmann H. Gastrointestinal stromal tumor of the colon—endoscopic treatment by full-thickness resection. Endoscopy 2015;47(Suppl 1 UCTN):E460–E461
94 Perbtani Y, Gupte A, Draganov PV, Esnakula A, Yang D. Endoscopic full-thickness resection of a stomach gastrointestinal stromal tumor using a dedicated full-thickness resection device. VideoGIE 2020;5(10):470–472
95 Xu M, Wang XY, Zhou PH, et al. Endoscopic full-thickness resection of colonic submucosal tumors originating from the muscularis propria: an evolving therapeutic strategy. Endoscopy 2013;45(09):770–773
96 Salerno R, Gherardi G, Paternò E, Ardizzone S. Endoscopic full-thickness resection of a submucosal right colon lesion. Endoscopy 2016;48(S 01):E376–E377
97 Bauder M, Schmidt A, Caca K. Non-exposure, device-assisted endoscopic full-thickness resection. Gastrointest Endosc Clin N Am 2016;26(02):297–312
98 Yang J, Kalloo AN, Gonzalez-Velez E, Ngamruengphong S. Modified over-the-scope clip with telescope endoscopic full-thickness resection for colonic adenoma involving diverticulum. VideoGIE 2018;3(10):316–318
99 Valli PV, Kaufmann M, Vrugt B, Bauerfeind P. Endoscopic resection of a diverticulum-arisen colonic adenoma using a full-thickness resection device. Gastroenterology 2014;147(05): 969–971
100 Pinho R, Oliveira M, Mascarenhas-Saraiva M. Endoscopic full-thickness resection of an inverted colonic diverticulum with intraepithelial neoplasia using the ligate-and-let-go technique. Clin Gastroenterol Hepatol 2015;13(13):A33–A34
101 Jimenez-Garcia VA, Romero-Castro R, Yamada M, Segura-Sanchez J, Alcazar-Guijo J, Neumann H. Successful endoscopic full-thickness resection of intramucosal cancer with Aurora rings arising in a diverticulum. Endoscopy 2020;52(06):E200–E201
102 Valli PV, Pohl D, Fried M, Caduff R, Bauerfeind P. Diagnostic use of endoscopic full-thickness wall resection (eFTR)-a novel minimally invasive technique for colonic tissue sampling in patients with severe gastrointestinal motility disorders. Neurogastroenterol Motil 2018;30(01):
103 Martínez-Alcalá A, Martínez-Alcalá García F, Mönkemüller K, Neumann H, Martínez-Alcalá F Endoscopic full-thickness resection for diagnosis of Hirschsprung's disease. Endoscopy 2018;50 (10):E281–E283
104 Agrawal D, Chak A, Champagne BJ, Marks JM, Delaney CP. Endoscopic mucosal resection with full-thickness closure for difficult polyps: a prospective clinical trial. Gastrointest Endosc 2010;71(06):1082–1088
105 Fischer A, Knoop RF, Walker C, Thimme R, Richter-Schrag HJ. Resection of a large rectal polyp with the simultaneous combination of snare polypectomy and full-thickness resection device resection. Endoscopy 2015;47(Suppl 1):E607–E608
106 Meier B, Caca K, Schmidt A. Hybrid endoscopic mucosal resection and full-thickness resection: a new approach for resection of large non-lifting colorectal adenomas (with video). Surg Endosc 2017;31(10):4268–4274
107 Ghersi S, Bassi M, Landi S, Binda C, Dabizzi E, Cennamo V. One-session combined technique for a recurrent rectal polyp: submucosal dissection and endoscopic full-thickness resection. Endoscopy 2019;51(05):E120–E121
108 Andrisani G, Di Matteo FM. Hybrid resection with endoscopic submucosal dissection and full-thickness resection device of a large cecal laterally spreading tumor involving the appendix. VideoGIE 2020;5(08):372–374
109 Chua JS, Dang H, Zwager LW, et al;Dutch eFTR Working Group. Hybrid endoscopic mucosal resection and full-thickness resection for large colonic polyps harboring a small focus of invasive cancer: a case series. Endosc Int Open 2021;9(11):E1686–E1691
110 Mahadev S, Vareedayah AA, Yuen S, Yuen W, Koller KA, Haber GB. Outcomes of a hybrid technique using EMR and endoscopic full-thickness resection for polyps not amenable to standard techniques (with video). Gastrointest Endosc 2021;94(02):358–367.e1
111 Kim HH, Uedo N. Hybrid NOTES: combined laparo-endoscopic full-thickness resection techniques. Gastrointest Endosc Clin N Am 2016;26(02):335–373
112 Abe N, Takeuchi H, Yanagida O, et al. Endoscopic full-thickness resection with laparoscopic assistance as hybrid NOTES for gastric submucosal tumor. Surg Endosc 2009;23(08):1908–1913
113 Mitsui T, Goto O, Shimizu N, et al. Novel technique for full-thickness resection of gastric malignancy: feasibility of nonexposed endoscopic wall-inversion surgery (news) in porcine models. Surg Laparosc Endosc Percutan Tech 2013;23(06): e217–e221
114 Eom BW, Kim CG, Kook MC, et al. Non-exposure simple suturing endoscopic full-thickness resection with sentinel basin dissection in patients with early gastric cancer: the SENORITA 3 Pilot Study. J Gastric Cancer 2020;20(03):245–255

115 Dong HY, Wang YL, Jia XY, Li J, Li GD, Li YQ. Modified laparoscopic intragastric surgery and endoscopic full-thickness resection for gastric stromal tumor originating from the muscularis propria. Surg Endosc 2014;28(05):1447–1453
116 Wada AM, Hashiba K, Otoch JP, et al. Full-thickness endoscopic gastric resection using a stapler and gastrostomy: a feasibility study. Arq Bras Cir Dig 2018;31(03):e1386
117 Kim CG. Endoscopic full-thickness resection combined with laparoscopic surgery. Clin Endosc 2018;51(01):33–36
118 Valdés-Hernández J, Cano A, Rodriguez-Tellez M, Gómez-Rosado JC, Mompean FO. Transanal minimally invasive surgery after incomplete resection of a rectal polyp using a full-thickness resection device. Endoscopy 2021;53(02):E46–E47
119 Yamamoto Y, Uedo N, Abe N, et al. Current status and feasibility of endoscopic full-thickness resection in Japan: results of a questionnaire survey. Dig Endosc 2018;30(Suppl 1):2–6
120 Wu CR, Huang LY, Guo J, et al. Clinical control study of endoscopic full-thickness resection and laparoscopic surgery in the treatment of gastric tumors arising from the muscularis propria. Chin Med J (Engl) 2015;128(11):1455–1459
121 Liu S, Zhou X, Yao Y, Shi K, Yu M, Ji F. Resection of the gastric submucosal tumor (G-SMT) originating from the muscularis propria layer: comparison of efficacy, patients' tolerability, and clinical outcomes between endoscopic full-thickness resection and surgical resection. Surg Endosc 2020;34(09):4053–4064
122 Eom BW, Kim CG, Kook MC, et al. Feasibility of non-exposure simple suturing endoscopic full-thickness resection in comparison with laparoscopic endoscopic cooperative surgery for gastric subepithelial tumors: results of two independent prospective trials. Cancers (Basel) 2021;13(08):1858
123 Li B, Shi Q, Qi ZP, et al. The efficacy of dental floss and a hemoclip as a traction method for the endoscopic full-thickness resection of submucosal tumors in the gastric fundus. Surg Endosc 2019; 33(11):3864–3873
124 Dellatore P, Bhagat V, Kahaleh M. Endoscopic full thickness resection versus submucosal tunneling endoscopic resection for removal of submucosal tumors: a review article. Transl Gastroenterol Hepatol 2019;4:45
125 Falt P, Zapletalova J, Urban O. Endoscopic full-thickness resection versus endoscopic submucosal dissection in the treatment of colonic neoplastic lesions $\leq$30 mm-a single-center experience. Surg Endosc 2022;36(03):2062–2069
126 Wang W, Li P, Ji M, et al. Comparison of two methods for endoscopic full-thickness resection of gastrointestinal lesions using OTSC. Minim Invasive Ther Allied Technol 2019;28(05):268–276
127 Kuellmer A, Behn J, Beyna T, et al. Endoscopic full-thickness resection and its treatment alternatives in difficult-to-treat lesions of the lower gastrointestinal tract: a cost-effectiveness analysis. BMJ Open Gastroenterol 2020;7(01):e000449
128 Asif S, Lakhtakia S, Reddy N. Endoscopic full-thickness resection for pancreatic fluid collection drainage: not yet there. Gastrointest Endosc 2021;94(05):1017–1018
129 Knoop RF, Richer-Schrag HJ, Thimme R, Fischer A. Use of the full-thickness resection device (FTRD) to prevent bleeding after colonic polypectomy in a patient with a left ventricular assist device. Endosc Int Open 2017;5(08):E749–E753
130 Xie M, Rao W, Zhang P, Zhao Q, Tian Z. Endoscopic full-thickness resection for a gastrointestinal stromal tumor in a liver transplant recipient: a case report. Medicine (Baltimore) 2019;98 (31):e16669
131 Yu S, Wang XM, Chen X, et al. Endoscopic full-thickness resection to treat active Dieulafoy's disease: a case report. World J Gastroenterol 2020;26(30):4557–4563
132 Zheng L, Li D, Wang W. Endoscopic full-thickness resection of gastric ectopic splenic nodules. BMC Gastroenterol 2020;20(01): 388
133 Schmidt A, Beyna T, Schumacher B, et al. Colonoscopic full-thickness resection using an over-the-scope device: a prospective multicentre study in various indications. Gut 2018;67(07): 1280–1289
134 Choong WKK, Bhamidipaty M, Johnston MJ. Large bowel obstruction from a full-thickness resection device clip: rare complication of a novel technique. ANZ J Surg 2020;90(11):2370–2372
135 Coman RM, Yang D, Draganov PV. Endoscopic full-thickness resection with use of the over-the-scope clip: a word of caution!. Gastrointest Endosc 2017;86(04):749–750
136 Maheshwari P, Farman M, Palaniappan SK, Doyle B, Patchett S, Cheriyan D. Snare resection after full-thickness resection device malfunction. Endoscopy 2019;51(03):E45–E46
137 Goto O, Shimoda M, Sasaki M, et al. Potential for peritoneal cancer cell seeding in endoscopic full-thickness resection for early gastric cancer. Gastrointest Endosc 2018;87(02):450–456
138 Oliviero G, Gagliardi M, Napoli M, et al. Fatal outcome consequent to an endoscopic full thickness resection of a colonic lateral spreading tumor: a case report. Am J Case Rep 2020;21: e922855
139 Friedel D, Zhang X, Modayil R, Stavropoulos SN. Endoscopic full-thickness resection. Tech Gastrointest Endosc 2019;21(01): 19–25
140 Bazarbashi AN, Thompson CC. Training and development in endoscopic full thickness resection. Tech Gastrointest Endosc 2019;21(01):38–42
141 Zimmer V, Eltze E. Granulation polyp arising in a former device-assisted full-thickness resection site: another kind of clip artifact? Gastrointest Endosc 2019;89(04):893–894
142 Al-Taee A, Ghoulam E, Alkaade S. Polypoid growth of benign tissue after endoscopic full-thickness resection. ACG Case Rep J 2020;7(02):e00312
143 Currais P, Roseira J, Castela J, Mão-de-Ferro S, Pereira AD. Heterogeneity of endoscopic full-thickness resection scars. Gastrointest Endosc 2020;92(02):433–434
144 Zimmer V, Emrich K. Leiomyoma-like mesenchymal proliferation arising in a device-assisted full-thickness resection site. GE Port J Gastroenterol 2021;28(04):292–293
145 Goto O, Sasaki M, Akimoto T, et al. Feasibility and safety of third-space endoscopic full-thickness resection in ex vivo and in vivo porcine models.. Endosc Int Open 2019 Apr;7(04): E471–E476
146 Ren Z, Lin SL, Zhou PH, et al. Endoscopic full-thickness resection (EFTR) without laparoscopic assistance for nonampullary duodenal subepithelial lesions: our clinical experience of 32 cases. Surg Endosc 2019 Nov; 33(11):3605–3611. Doi: 10.1007/s00464-018-06644-3. Epub 2019 Jun 25. PMID: 31240477
147 Andrisani G, Soriani P, Manno M, et al. Colo-rectal endoscopic full-thickness resection (EFTR) with the over-the-scope device (FTRD®): A multicenter Italian experience. Dig Liver Dis 2019 Mar;51(03):375–381
148 Aepli P, Criblez D, Baumeler S, Borovicka J, Frei R. Endoscopic full thickness resection (EFTR) of colorectal neoplasms with the Full Thickness Resection Device (FTRD): Clinical experience from two tertiary referral centers in Switzerland. United European Gastroenterol J 2018 Apr;6(03):463–470
149 Albrecht H, Raithel M, Braun A, et al. Endoscopic full-thickness resection (EFTR) in the lower gastrointestinal tract. Tech Coloproctol 2019 Oct;23(10):957–963
150 Andrisani G, Pizzicannella M, Martino M, et al. Endoscopic full-thickness resection of superficial colorectal neoplasms using a new over-the-scope clip system: A single-centre study. Dig Liver Dis 2017 Sep;49(09):1009–1013
151 Bauermeister M, Mende M, Hornoff S, Faiss S. Hybrid resection of large colorectal adenomas combining EMR and FTRD. Scand J Gastroenterol 2021 Aug;56(08):978–983
152 Bulut M, Buch N, Knuhtsen S, Gögenur I, Bremholm L. Endoscopic full-thickness resection of benign and malignant colon lesions with one-year follow up in a Danish cohort. Scand J Gastroenterol 2022 Mar;57(03):377–383

153 Fähndrich M, Sandmann M. Endoscopic full-thickness resection for gastrointestinal lesions using the over-the-scope clip system: a case series. Endoscopy 2015 Jan;47(01):76–9
154 Ichkhanian Y, Vosoughi K, Diehl DL, et al. A large multicenter cohort on the use of full-thickness resection device for difficult colonic lesions. Surg Endosc 2021 Mar;35(03):1296–1306
155 Mão de-Ferro S, Castela J, Pereira D, Chaves P, Dias Pereira A. Endoscopic Full-Thickness Resection of Colorectal Lesions with the New FTRD System: Single-Center Experience. GE Port J Gastroenterol 2019 Jul;26(04):235–241
156 Rushfeldt CF, Nordbø M, Steigen SE, Dehli T, Gjessing P, Norderval S. Endoscopic full-thickness dissection (EFTD) in the rectum: a case series. Tech Coloproctol 2022 Mar;26(03):187–193
157 Schmidt A, Bauerfeind P, Gubler C, Damm M, Bauder M, Caca K. Endoscopic full-thickness resection in the colorectum with a novel over-the-scope device: first experience. Endoscopy 2015 Aug;47(08):719–25
158 Valli PV, Mertens J, Bauerfeind P. Safe and successful resection of difficult GI lesions using a novel single-step full-thickness resection device (FTRD®). Surg Endosc 2018 Jan;32(01):289–299
159 van der Spek B, Haasnoot K, Meischl C, Heine D. Endoscopic full-thickness resection in the colorectum: a single-center case series evaluating indication, efficacy and safety. Endosc Int Open 2018 Oct;6(10):E1227–E1234
160 Velegraki M, Trikola A, Vasiliadis K, et al. Endoscopic full-thickness resection of colorectal lesions with the full-thickness resection device: clinical experience from two referral centers in Greece. Ann Gastroenterol 2019 Sep-Oct;32(05):482–488
161 Vitali F, Naegel A, Siebler J, Neurath MF, Rath T. Endoscopic full-thickness resection with an over-the-scope clip device (FTRD) in the colorectum: results from a university tertiary referral center. Endosc Int Open 2018 Jan;6(01):E98–E103
162 von Helden A, Hildenbrand R, Sido B, Dumoulin FL. Endoscopic full-thickness resection using an over-the-scope device for treatment of recurrent / residual colorectal neoplasia: a single-center case series. BMC Gastroenterol 2019 Jul 10;19(01):121
163 Ye LP, Yu Z, Mao XL, Zhu LH, Zhou XB. Endoscopic full-thickness resection with defect closure using clips and an endoloop for gastric subepithelial tumors arising from the muscularis propria. Surg Endosc 2014 Jun;28(06):1978–83
164 Shi Q, Chen T, Chen T, et al. Complete closure of large gastric defects after endoscopic full-thickness resection, using endoloop and metallic clip interrupted suture. Endoscopy 2013;45(05):329–34
165 Wang G, Xiang Y, Miao Y, Wang H, Xu M, Yu G. The application of endoscopic loop ligation in defect repair following endoscopic full-thickness resection of gastric submucosal tumors originating from the muscularis propria layer. Scand J Gastroenterol 2022 Jan;57(01):119–123
166 Jung AL, Park SW, Hong GY, Moon HC, Eun SJ. Endoscopic Full-Thickness Resection for Gastric Subepithelial Lesions Arising from the Muscularis Propria. Clin Endosc 2021 Jan;54(01):131–135
167 Huang J, Xian XS, Huang LY, Zhang B, Wu CR, Cui J. Endoscopic full-thickness resection for gastric gastrointestinal stromal tumor originating from the muscularis propria. Rev Assoc Med Bras (1992) 2018 Nov;64(11):1002–1006
168 Li Y, Cui Z, Yu J, Bao X, Wang S. Do we need to conduct full-thickness closure after endoscopic full-thickness resection of gastric submucosal tumors? Turk J Gastroenterol 2020 Dec;31(12):942–947
169 Meier B, Schmidt A, Glaser N, et al. Endoscopic full-thickness resection of gastric subepithelial tumors with the gFTRD-system: a prospective pilot study (RESET trial). Surg Endosc 2020 Feb;34(02):853–860
170 Schlag C, Wilhelm D, von Delius S, Feussner H, Meining A. EndoResect study: endoscopic full-thickness resection of gastric subepithelial tumors. Endoscopy 2013;45(01):4–11
171 Shichijo S, Uedo N, Yanagimoto Y, et al. Endoscopic full-thickness resection of gastric gastrointestinal stromal tumor: a Japanese case series. Ann Gastroenterol 2019 Nov-Dec;32(06):593–599
172 Yang F, Wang S, Sun S, et al. Factors associated with endoscopic full-thickness resection of gastric submucosal tumors. Surg Endosc 2015 Dec;29(12):3588–93
173 Cho WY, Kim YJ, Cho JY, et al. Hybrid natural orifice transluminal endoscopic surgery: endoscopic full-thickness resection of early gastric cancer and laparoscopic regional lymph node dissection —14 human cases. Endoscopy 2011 Feb;43(02):134–9
174 Kwon OK, Yu W. Endoscopic and Laparoscopic Full-Thickness Resection of Endophytic Gastric Submucosal Tumors Very Close to the Esophagogastric Junction. J Gastric Cancer 2015 Dec;15(04):278–85
175 Mahawongkajit P, Chanswangphuvana P. Laparoscopy-assisted endoscopic full-thickness resection of upper gastrointestinal subepithelial tumors: A single-center early experience. Mol Clin Oncol 2020 May;12(05):461–467

