



Unusual Pattern of Osteochondral Marginal Impaction in Acetabular Fractures. A Report of Two Cases

Padrão incomum de impacto marginal osteocondral em fraturas acetabulares. Um relatório de dois casos

Bahaaeldin Ibrahim^{1,2} Mahmoud Badran¹ Ahmed A. Khalifa^{1,3} Hossam Abubeih¹
Osama Farouk¹

¹ Orthopaedic Department, Assiut University, Assiut, Egypt

² Orthopaedic Department, Al-Azhar University, Assiut, Egypt

³ Orthopaedic Department, Qena Faculty of Medicine and University Hospital, South Valley University, Qena, Egypt

Address for correspondence Ahmed A. Khalifa, MD, FRCS, MSc, Kilo 6 Qena-Safaga highway, Orthopedic Department, Qena University Hospital, South Valley University, Qena, Egypt
(e-mail: ahmed_adel0391@med.svu.edu.eg)

Rev Bras Ortop

Abstract

Introduction Acetabular fractures could be accompanied by articular impaction injuries, affecting the outcomes if missed or treated less than optimally. Marginal impaction detected either in preoperative or intraoperatively imaging studies should be anatomically reduced using the femoral head as a template and augmenting the defect with bone graft if needed. The impacted segment articular surface looks enface during surgery, which is the classic description of such injuries.

Case presentation In the present report, we describe an unusual pattern of marginal impaction injuries appearance in two patients, in which the impacted fragment articular surface is facing toward the joint cavity, which is the reverse of the classic description, alluding to the probable mechanism of its occurrence, the technique for reduction, and the consequences of missing such injuries.

Conclusion Marginal impaction injuries should be diagnosed and treated correctly to preserve joint congruency; however, the surgeon should be aware of the possibility of an unusual pattern of marginal impaction in which the fragment could be reversed, and keeping this possibility in mind would make its diagnosis and management easier.

Keywords

- ▶ acetabulum
- ▶ osteonecrosis
- ▶ fractures, bone
- ▶ hip fractures

Resumo

Introdução As fraturas acetabulares podem ser acompanhadas por lesões de impacto articular, afetando os desfechos se não vistas ou tratadas de modo incompleto. A impaction marginal detectada em estudos de imagem pré- ou intraoperatórios deve ser reduzida anatomicamente usando a cabeça femoral como modelo e aumentando o defeito com enxerto ósseo, se necessário. A superfície articular do segmento

Work developed at Assiut University Hospital, Assiut, Egypt.

received
March 27, 2022
accepted
June 14, 2022

DOI <https://doi.org/10.1055/s-0042-1755347>.
ISSN 0102-3616.

© 2022. Sociedade Brasileira de Ortopedia e Traumatologia. All rights reserved.

This is an open access article published by Thieme under the terms of the Creative Commons Attribution-NonDerivative-NonCommercial-License, permitting copying and reproduction so long as the original work is given appropriate credit. Contents may not be used for commercial purposes, or adapted, remixed, transformed or built upon. (<https://creativecommons.org/licenses/by-nc-nd/4.0/>)

Thieme Revinter Publicações Ltda., Rua do Matoso 170, Rio de Janeiro, RJ, CEP 20270-135, Brazil

impactado parece voltada para a frente durante a cirurgia, que é a descrição clássica de tais lesões.

Apresentação do caso No relatório atual, descrevemos um padrão incomum de aparecimento de lesões de impacto marginal em dois pacientes, onde a superfície articular do fragmento impactado está voltado para a cavidade articular, sendo o inverso da descrição clássica, aludindo ao mecanismo provável de sua ocorrência, à técnica de redução e às consequências de ignorar tal lesão.

Conclusão Lesões de impacto marginal devem ser diagnosticadas e tratadas corretamente para preservar a congruência articular; no entanto, o cirurgião deve estar ciente da possibilidade de um padrão incomum de impacto marginal no qual o fragmento poderia ser revertido; manter esta possibilidade em mente facilitaria seu diagnóstico e manejo.

Palavras-chave

- ▶ acetábulo
- ▶ fraturas do quadril
- ▶ fraturas ósseas
- ▶ osteonecrose

Introduction

An isolated posterior wall fracture (elementary type according to the Letournel-Judet system) is one of the most commonly occurring types, representing ~ 20 to 35% of acetabular fractures.¹⁻³ However, this fracture pattern is not as simple to treat as it seems, with variable prognosis and outcomes, which could be influenced by various factors, including the characteristics of the fracture.^{4,5}

One of these characteristics is a concomitant “marginal impaction” injury, which, if missed, could lead to less than optimal outcomes.^{5,6} Judet et al. described this injury as a rotated impacted fracture segment with depression of osteochondral fragments into the underlying cancellous bone, which occurs in conjunction with a pure posterior fracture-dislocation or as part of complex acetabular fractures and in ~ 30% of posterior wall fractures.^{1,5}

In the present case report, we describe two cases presented with an unusual (reversed) pattern of marginal impaction injury associated with acetabular fractures, alluding to the possible explanations of its occurrence, diagnosis, and management.

Presentation of the Cases

The present article was part of a study that was approved by the ethical committee of our institution (IRB no.: 17200019). Informed verbal and written consent was obtained from the patients to use their clinical data and images to publish the present case report.

Two patients, 43 (patient-A) and 19 (patient-B) years old, presented after a motor car accident. After stabilization of their general condition, the initial plain anteroposterior (AP) pelvis radiograph showed fracture-dislocation of the hip in both patients, who were treated by closed reduction under anesthesia and traction. Secondary surveys to investigate acetabular injuries (plain radiograph [AP and Judet views] and pelvis computed tomography [CT] scan). Patient-A had a transverse type with posterior wall fracture, and patient-B had a posterior column fracture. A marginal impaction injury was detected in the CT scan in both patients.

Surgical Details and Injury Description

Open reduction and internal fixation through the Kocher-Langenbeck approach were performed intraoperatively after joint distraction; we noticed that the orientation of the impacted fragment is reversed compared with the usual marginal impaction appearance, meaning that, instead of having the articular surface of the impacted fragment presented enface (the surgeon having a clear look at the shining articular cartilage of the impacted segment [▶Fig. 1A]), it seemed reversed (the articular surface is looking toward the joint cavity hinged on its inner attachment to the acetabular articular cartilage and the surgeon is looking at the cancellous surface of the impacted segment [▶Fig. 1B]). After re-evaluating the preoperative CT of both patients, we found that the marginal osteochondral impacted fragment is looking toward the acetabulum articular cavity instead of the classic appearance description (▶Figs. 2 and 3).

The impacted fragment was first disimpacted using an osteotome; then, it was manipulated to its bed, keeping its inner hinge as intact as possible and using the femoral head as a template to ensure perfect reduction. Autogenous bone graft from the greater trochanter was used to support the reduced fragment and to fill the void created by the impaction. Lastly, reduction of the main fracture element and fixation using plate and screws were performed (▶Fig. 2 and 3).

Postoperative Protocol

Immediate postoperative plain radiograph series (AP and Judet views) were taken to assess the quality of fracture reduction and the position of the implants. Patients were allowed to mobilize using two axillary crutches with strict nonweight bearing on the operated side. At 6 weeks and after obtaining a follow-up radiograph, the patients were allowed to start partial weight-bearing.

Discussion

The aims of surgical management of acetabular fractures are mainly to obtain anatomical reduction and to restore the articular congruity for the sake of proper outcomes and to

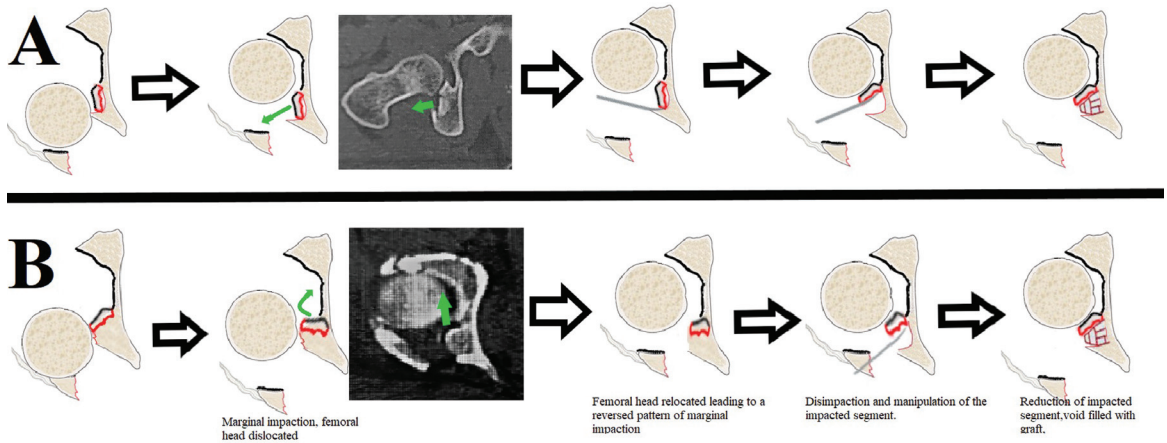


Fig. 1 A schematic diagram showing the differences between, (A) the commonly described marginal impaction pattern, and (B) the unusual pattern we described in the current report.

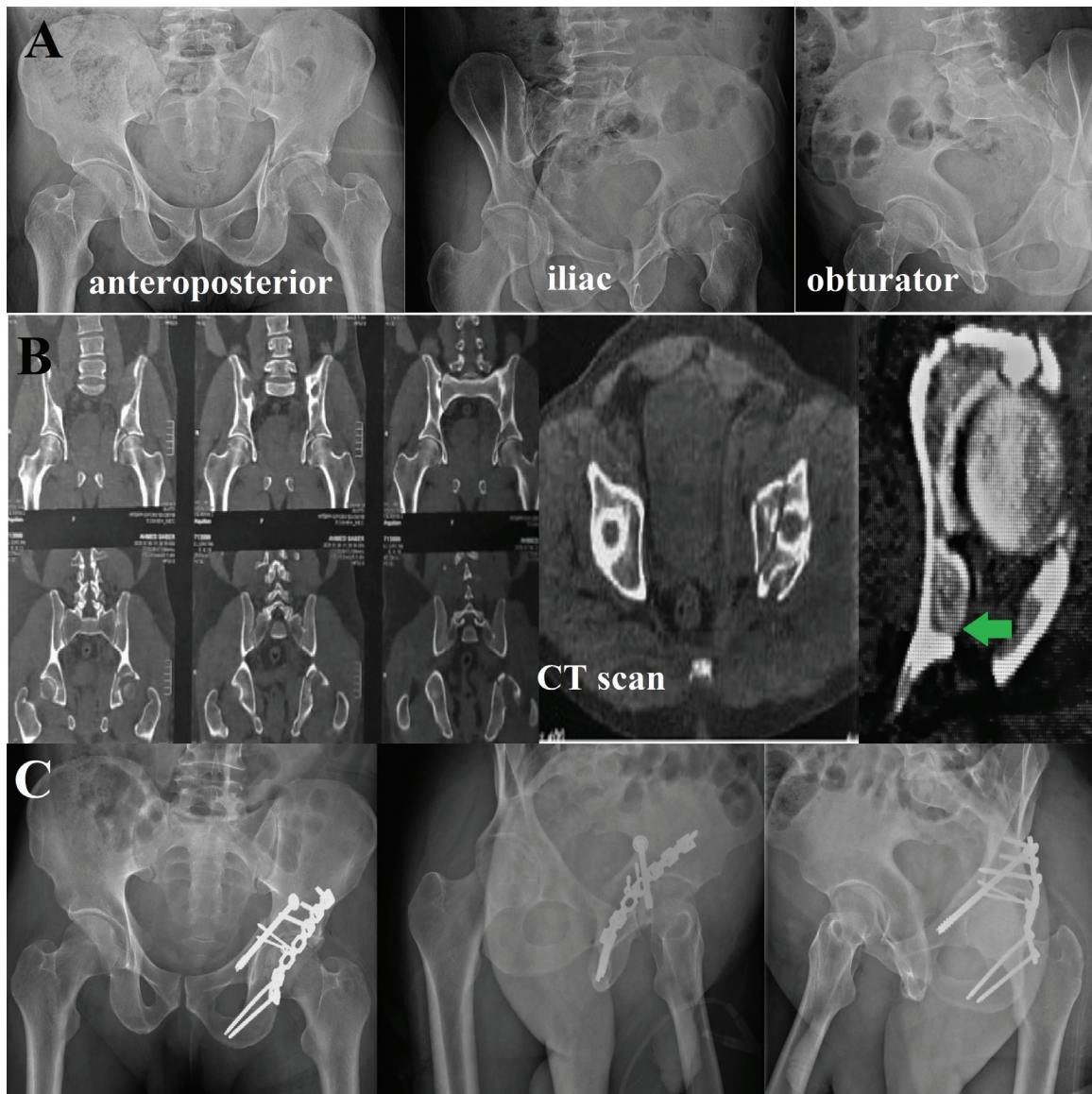


Fig. 2 Patient A: Diagnosed as transverse type acetabulum fracture with posterior wall fracture. (A and B) Preoperative plain radiographs and computed tomography scans (green arrowhead points to the impacted segment). (C) Postoperative pelvis plain radiographs.

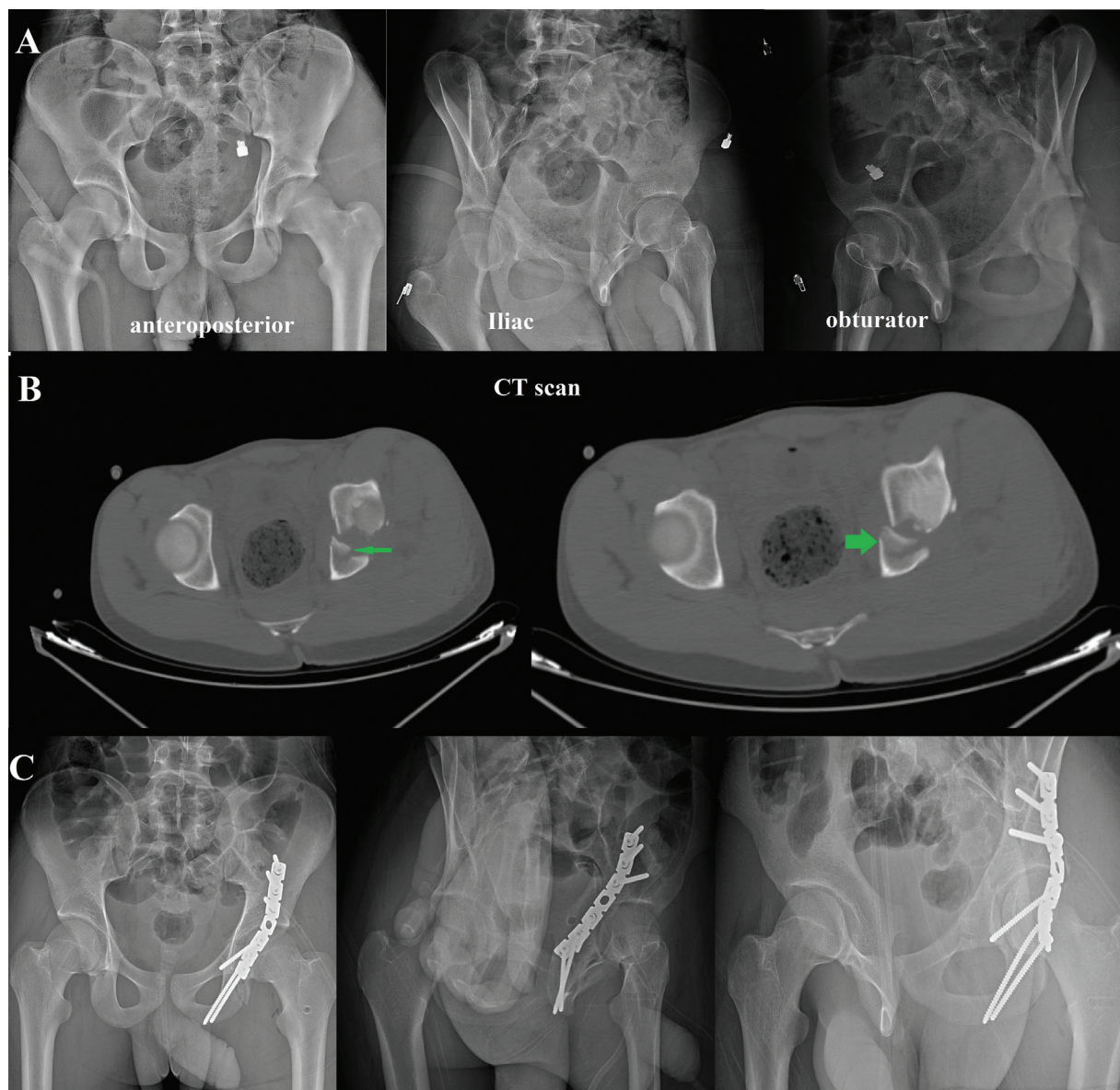


Fig. 3 Patient B: Diagnosed as a posterior column fracture. (A and B) Preoperative plain radiographs and computed tomography scans (green arrowhead points to the impacted segment). (C) Postoperative pelvis plain radiographs.

reduce the chance of complications, since fracture malreduction creates articular incongruity leading to hip joint instability and early arthritis.^{2,5-7}

Although posterior wall fractures could be complicated by the presence of comminution or an associated osteochondral marginal impaction, which usually needs disimpaction that might create a void that should be filled by a bone graft, failure to define associated injuries and to manage them properly precipitates less than optimal outcomes.⁴⁻⁷

Specific preoperative radiographic signs, such as the seagull sign, help diagnosing a marginal impaction injury; however, in a study by Souza et al., the authors reported 36 patients diagnosed intraoperatively with a marginal impaction injury; however, none of the preoperative radiological reports of these patients mentioned such injury, indicating that this finding could be easily missed in the routine plain radiograph evaluation.¹ Hence, it is essential to evaluate the

preoperative CT scan and to confirm the findings intraoperatively.^{1,8}

The findings of the present report stressed the importance of carefully evaluating the preoperative CT images for the possibility of an unusual pattern like what we have described so that the surgeon would anticipate the technique for its reduction and fixation.

Patient-A was transferred to our hospital after failed closed reduction attempts in another center; the patient presented a CT scan while the hip was dislocated. Based on the appearance of the injury in the CT scan, we hypothesized that this pattern could occur while reducing the hip since the femoral head could hit the outer edge of the impacted fragment, leading to its elevation from its bed and with further femoral head reduction into the joint cavity leading to the flipping of the fragment to be located toward the joint cavity (→ Fig. 4).

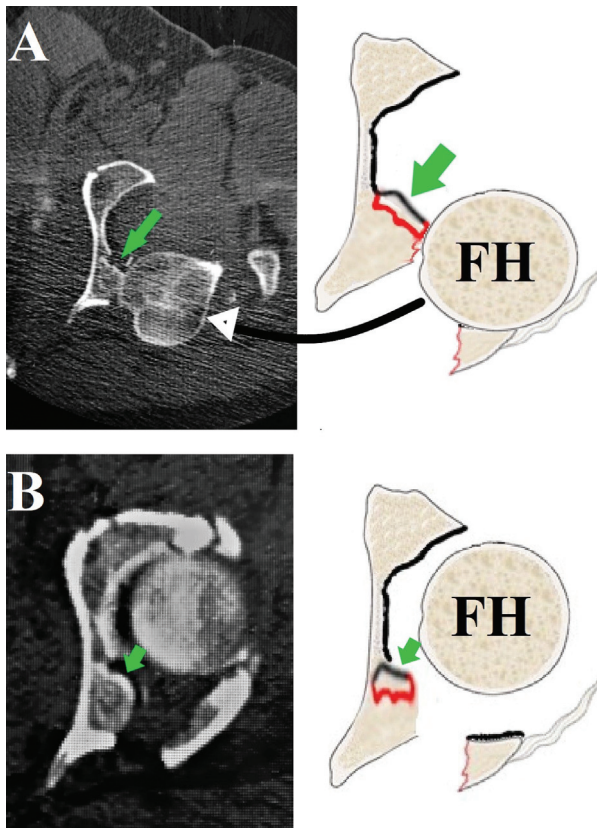


Fig. 4 Schematic diagram and computed tomography scan images showing the probable mechanism of injury leading to this unusual pattern of marginal impaction injury. (A) The head is dislocated, which pushes the marginal impaction segment (green arrowhead) while it is being relocated. (B) The final picture after relocating the femoral head with the articular surface of the marginally impacted segment facing the joint cavity.

Optimal identification, reduction, and stabilization of marginal impaction remain a vital surgical intervention component. Several studies have demonstrated that articular step-offs are poorly tolerated in acetabular fracture surgery.⁹

Hence, the importance of detecting such an unusual pattern lies in first: the surgeon might consider this a loose fragment that, if removed, could affect the joint articular surface. Second: if the surgeon suspects such injury, careful joint distraction is needed to help in reducing this fragment to its bed with caution to preserve the inner hinge where the fragment is attached to the articular cartilage. Third: if this injury was missed intraoperatively, the surgeon might mal-reduce the posterior wall fracture into the bed of the impacted fragment, leading to joint incongruity and volume reduction.

Marginal impaction injuries should be diagnosed correctly in the preoperative imaging studies; proper reduction would help preserve the joint congruency, leading to accept-

able outcomes. The surgeon should be aware of an unusual pattern of marginal impaction where the fragment could be reversed; keeping this possibility in mind would make its diagnosis and management easier.

Contributions of the Authors

Each author contributed individually and significantly to the development of the present article: Ibrahim B., Abu-beih H., and Farouk O. conceived the case report and performed the surgeries. Khalifa A. A. and Badran M. performed data acquisition, assessment, literature search, and prepared the images. Khalifa A. A., Ibrahim B., and Badran M. drafted the manuscript. Farouk O. and Abubeih H. did the critical revision. All authors read, discussed, and approved the final manuscript.

Financial Support

The present research did not receive any specific grant from funding agencies in the public, commercial, or not-for-profit sectors.

Conflict of interests

The authors have no conflict of interests to declare.

References

- Martins e Souza P, Giordano V, Goldszajn F, Siciliano AA, Grizendi JA, Dias MV. Marginal impaction in posterior wall fractures of the acetabulum. *AJR Am J Roentgenol* 2015;204(04):W470-4
- Eastman JG, Fennessy JH, Deafenbaugh B, Chip Routh ML Jr. Cortical impaction in posterior wall acetabular fractures. *J Orthop Trauma* 2019;33(05):229-233
- Judet R, Judet J, Letournel E. Fractures of the acetabulum: classification and surgical approaches for open reduction. preliminary report. *J Bone Joint Surg Am* 1964;46:1615-1646
- Kim HT, Ahn JM, Hur JO, Lee JS, Cheon SJ. Reconstruction of acetabular posterior wall fractures. *Clin Orthop Surg* 2011;3(02):114-120
- Giannoudis PV, Kanakaris NK, Delli Sante E, Morell DJ, Stengel D, Prevezas N. Acetabular fractures with marginal impaction: mid-term results. *Bone Joint J* 2013;95-B(02):230-238
- Perumal R, Vallari DP, Gessesse MT, Jayaramaraju D, Rajasekaran S. Marginal impaction in complex posterior wall acetabular fractures: role of allograft and mid-term results. *Eur J Orthop Surg Traumatol* 2020;30(03):435-440
- Kasha S, Yalamanchili RK. Articular disimpaction in acetabular fractures. *J Clin Orthop Trauma* 2020;11(06):1025-1030
- Arts E, Nijsink H, Verhamme L, et al. The value of 3D reconstructions in determining post-operative reduction in acetabular fractures: a pilot study. *Eur J Trauma Emerg Surg* 2021;47(06):1873-1880
- Papachristos IV, Johnson JP, Giannoudis PV. Treatment of incarcerated impaction of acetabular fractures with concomitant osteochondral femoral head fractures by the use of a posterior wall osteotomy and surgical hip dislocation: a novel technique. *J Am Acad Orthop Surg* 2019;27(24):e1086-e1092