




# Pedicle First Anterior Approach to Harvest Anterolateral Thigh Flap—Review of 304 Cases

G.S. Kalra<sup>1</sup> Samarth Gupta<sup>1</sup> Sushrut Kalra<sup>1</sup> 

<sup>1</sup>Department of Plastic, Reconstructive and Burns Surgery, SMS Hospital Jaipur, Rajasthan, India

Indian J Plast Surg 2022;55:272–276.

Address for correspondence Samarth Gupta, MBBS, MS, MCh, Department of Plastic, Reconstructive and Burns Surgery, SMS Hospital Jaipur 302001, Rajasthan, India (e-mail: guptasamarth@hotmail.com).

## Abstract

**Background** Although considered as a workhorse flap, the anterolateral thigh (ALT) flap has a steep learning curve that makes it difficult for microsurgeons to perform it early in their practice. In over 85% of patients, the perforator takes an intramuscular course making it difficult for beginners to safely secure the perforator dissection. In this technique, the pedicle is dissected first, utilizing the proximal incision by palpating the groove in between vastus lateralis and rectus femoris on the anterior aspect and extending the incision from 2 to 3 cm distal to the inguinal ligament to the flap markings caudally. Exposing the pedicle first makes it easier to proceed toward the skin perforator due to its easy identification and larger size at its origin.

**Patients and Methods** This retrospective study was conducted from 2005 to 2020 in which 304 ALT flaps were performed by the pedicle first technique. Flap harvest time, incidence of injury to the skin perforator during harvest, flap re-exploration rates, and postoperative complications including incidence of flap necrosis, infection, and bleeding were the parameters that were measured.

**Results** This study included a total of 304 patients of which 220 were male (72.3%). The average flap harvest time was  $26 \pm 3.2$  minutes. Adverse events included perforator injury ( $n = 1$ ), flap re-exploration ( $n = 15$ ), and complete flap loss ( $n = 8$ ). The last eight patients were reconstructed secondarily with ALT flap from the opposite side and free latissimus dorsi flap ( $n = 2$ ).

**Conclusion** The pedicle first technique makes ALT flap harvest easy, safe, and faster for plastic surgeons. The chances of injury to the skin perforator are markedly less thereby reducing postoperative complications.

## Keywords

- ▶ pedicle first
- ▶ ALT flap harvest
- ▶ anterior approach
- ▶ antegrade approach
- ▶ rapid harvest

## Introduction

First described by Song in 1984, the anterolateral thigh (ALT) flap has proved to be a reliable workhorse flap for microsurgical reconstruction in the last decade. Various modifications have been described, and the flap can be harvested as a cutaneous, fasciocutaneous, musculo fasciocutaneous, adi-

pofascial, chimeric including the tensor fascia lata (TFL), sensate, and, more recently, supra-thin flap.<sup>1,2</sup> With a long pedicle, reliable anatomy, and low donor site morbidity, its use has been further extended to reconstructing various parts of the body, the head and neck region being one of them.<sup>3,4</sup> The utility of this flap as a chimeric flap helps to reconstruct three-dimensional defects in the head and neck

published online  
September 25, 2022

DOI <https://doi.org/10.1055/s-0042-1756128>.  
ISSN 0970-0358.

© 2022. Association of Plastic Surgeons of India. All rights reserved. This is an open access article published by Thieme under the terms of the Creative Commons Attribution-NonDerivative-NonCommercial-License, permitting copying and reproduction so long as the original work is given appropriate credit. Contents may not be used for commercial purposes, or adapted, remixed, transformed or built upon. (<https://creativecommons.org/licenses/by-nc-nd/4.0/>)  
Thieme Medical and Scientific Publishers Pvt. Ltd., A-12, 2nd Floor, Sector 2, Noida-201301 UP, India

region. Today ALT flap is one of the most performed free flap surgeries owing to its versatility and a relatively obscured scar.

The flap is based on either the septocutaneous or the musculocutaneous perforators, the latter is found in up to 85% of the patients.<sup>5,6</sup> Dissecting the intramuscular perforator safely needs good surgical skill which required long hours of training. In fact, previously, it was considered futile to dissect the intramuscular perforator as mentioned by Koshima et al in their article.<sup>7,8</sup> With the development of new microsurgical instruments and improved optics, it has become possible to dissect the perforator intramuscularly.<sup>9,10</sup> Despite these advances, young microsurgeons often feel hesitant to dissect the perforator in its intramuscular course, leading to anxiety, frustration, and sub-optimal results. We believe that dissecting perforator from skin to the source vessel imparts the risk of damaging the perforator, especially when it follows a long and curved course. It is often observed that the perforator is damaged during this process which leaves the surgeon with minor perforators supplying the skin and often with none, resulting in flap necrosis. To avoid this, we dissect the pedicle in an antegrade manner toward the skin as this is potentially safe due to the direct visualization of the whole vessel and the perforators arising from the pedicle into the muscle toward the skin. Further, the diameter is larger toward the pedicle which makes it easier for identification, leading to reduced chances of injury. This paper presents our experience with the pedicle first technique with an emphasis on the surgical technique and tips and tricks that the author has acquired over years of experience. We also present the results from our series shedding light on the time of harvest and complications associated with this technique.

## Patients and Methods

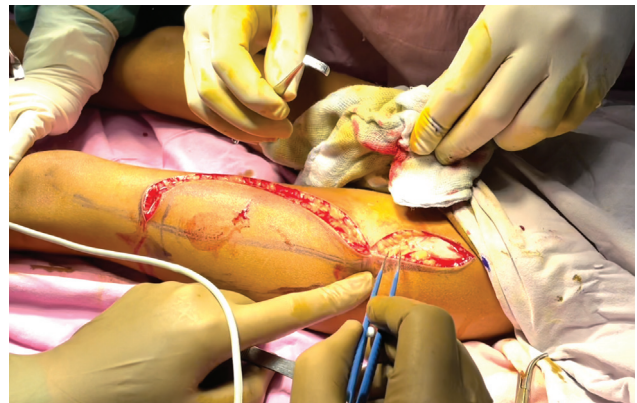
A retrospective chart review of all patients undergoing ALT flap reconstruction was conducted between 2005 and 2020 in which 304 ALT flaps were performed by the pedicle first technique. All the surgeries were performed by a single surgeon. The patient's age, sex, and site of defect were recorded as demographic and clinical variables. Flap harvest time was measured and defined as time taken from skin incision to division of the pedicle. In addition, the incidence of injury to the skin perforator during harvest, flap re-exploration rates, and postoperative complications, including the incidence of flap necrosis, infection, and bleeding were other parameters that were measured. Statistical analysis was performed by means of Jamovi 1.2.27.0 (Jamovi, Sydney, Australia). Values were expressed as mean  $\pm$  standard deviation.

## Surgical Technique

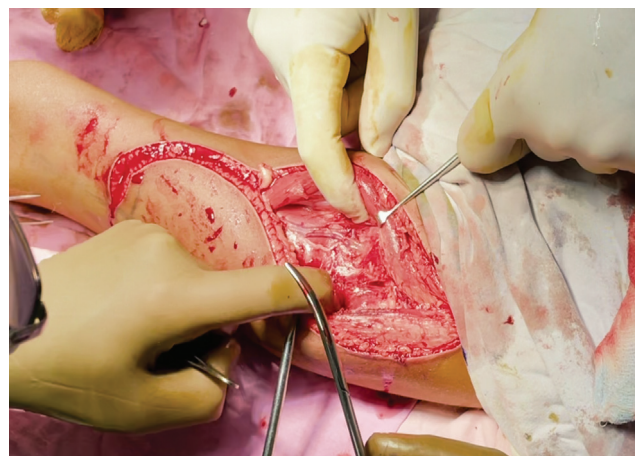
Skin markings are initiated by first palpating the groove in between vastus lateralis and rectus femoris, which denotes the site of the pedicle. The markings span from 2 to 3 cm distal to the inguinal ligament to join the flap markings caudally. The flap markings are done by marking the skin

perforators by hand-held Doppler after assessing the defect size. An exploratory incision is kept on the anterior aspect of the thigh beginning 2 to 3 cm caudal to the inguinal ligament to expose the pedicle in the septum between vastus lateralis and rectus femoris. The incision is then extended along the medial flap boundaries that are marked preoperatively, thereby elevating the flap to the intramuscular septum (**Fig. 1**). The vessel is dissected from proximal to distal in the septum between the two muscles (**Fig. 2**). The pedicle is now visible in its entire length along with the line of perforators arising from it. Per-operative Doppler can be used at this point of time to look for all the perforators to the skin thereby confirming the preoperatively marked perforators to affirm that they are supplying the overlying skin. This also allows us to visualize all the nearby perforators such as those from anteromedial thigh flap and the TFL flap to supply a separate island of skin (**Fig. 3**). Often one encounters a separate proximal branch that goes directly into the skin and can also be used to base the flap.

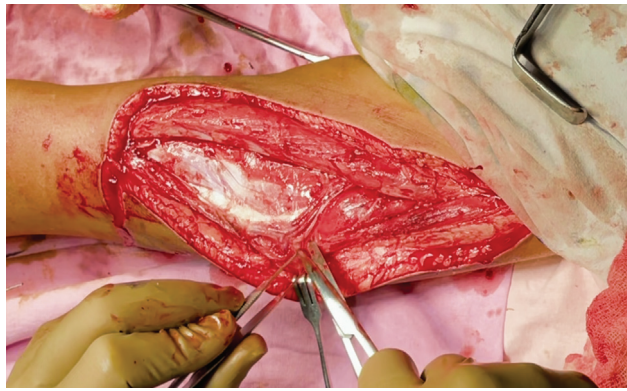In our experience, we observed that 95% of the patients were found to have musculocutaneous perforators. Sometimes, a part of the perforator begins as a septocutaneous perforator but dips into the muscle before reaching the skin. If a sizeable perforator is found, it is dissected off the



**Fig. 1** Anteromedial exploratory incision.



**Fig. 2** Identification of the pedicle.



**Fig. 3** Identification of perforators—two in this case.

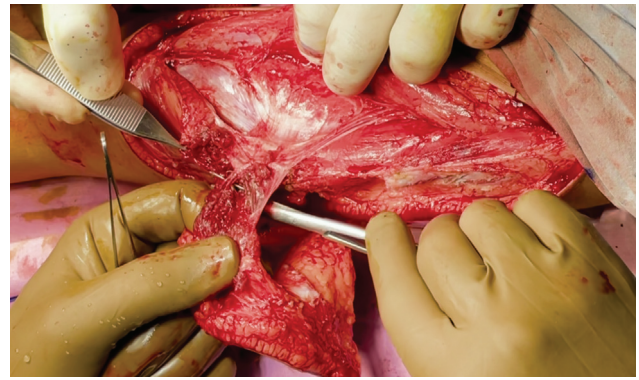
surrounding muscle in an anterograde manner from the descending branch of the lateral circumflex femoral artery toward the skin paddle. Multiple branches on the way are clipped or cauterized with bipolar thermy; however, it is preferential to use clips as heat generated by cautery can cause spasms and damage to the main pedicle. Coagulation, if done, should be performed slightly away from the source vessel to prevent its damage. The flaps are raised supra-fascially to begin with, but a cuff of fascia is preserved as we proceed toward the pedicle. The lateral incision is then kept raising the flap which can be done again in a supra-fascial manner sparing the TFL.

In case of injury to the skin perforator or absence of one corresponding to the ALT flap, other perforators can be used to mark the flap through the same incision. In case two perforators are found in proximity, a thin strip of muscle between the perforators is preferably taken to avoid inadvertent damage to the perforators without compromising postoperative muscle function. If the perforators are observed traversing into the muscle but not seen to pierce the skin, multiple perforators can be taken along with some muscle under the flap to ensure good vascularity to the skin. This is technically easier by the pedicle first technique as we can observe the muscle perforators well in advance in contrast to when we go from the skin side when the entire flap has the risk of being elevated without the cutaneous perforator. Whenever a portion of muscle is taken, we prefer to suture the ends with a negative suction drain to prevent postoperative hematoma formation.

The flap is then elevated carefully dissecting the nerve away from the pedicle after ligating the distal end (► **Fig. 4**). The vascularity of the skin paddle is checked by scratch test following which the distal end is ligated, hence completing the flap harvest. A point to be emphasized here is that since the pedicle is dissected first which aids in visualizing all its branches and with the aid of per-operative Doppler, it is easier to plan chimeric flaps such as the TFL and the rectus muscle flap.

## Results

During a period of 15 years between 2005 and December 2020, 304 patients who underwent ALT flap reconstruc-



**Fig. 4** Dissecting the nerve to the vastus lateralis away from the pedicle.

tion were recorded by means of the medical record of the hospital. The mean age of the patients in the study was  $48 \pm 12.5$  years (range 22–67 years) and comprised of 55.2% ( $n = 168$ ) males. The ALT flap was used most commonly for lower limb reconstruction (57.2%,  $n = 174$ ) followed by head and neck reconstruction (28.9%,  $n = 88$ ) and upper limb reconstruction (13.8%,  $n = 42$ ).

The mean flap harvest time was observed to be  $26 \pm 3.2$  minutes (range 20–41). During the flap harvest, iatrogenic injury to the skin perforator occurred in one patient and none of the flaps had to be discarded intraoperatively. Postoperatively, adverse events included flap re-exploration ( $n = 15$ ) and complete flap loss ( $n = 8$ ). Arterial occlusion occurred in three (20%) flaps, and only one flap was salvaged. Venous occlusions occurred in 12 flaps (80%), and it was noted that the rate of successful salvage for venous occlusion ( $n = 4$ , 33.3%) was similar to that of arterial occlusion.

Six patients suffered from postoperative bleeding which were either managed conservatively or taken to the theater where the bleeder was cauterized. Six patients suffered from infection that was managed effectually by antibiotics based on culture sensitivity reports. The overall incidence of infection and bleeding is presented in ► **Table 1**. The patients who

**Table 1** Intraoperative findings and postoperative outcomes of patients

Mean flap harvest time, minutes	$26 \pm 3.2$ (range 20–41)
Iatrogenic injury to major skin perforator	0.3% ( $n = 1$ )
Flap discarded	Nil
Flap re-exploration	4.93% ( $n = 15$ ) Three arterial 12 venous
Complete necrosis needing salvage procedure	2.67% ( $n = 8$ ) Two arterial Six venous
Partial necrosis managed conservatively	1.97% ( $n = 6$ )
Postoperative bleeding	1.97% ( $n = 6$ )
Infection	1.97% ( $n = 6$ )

suffered from partial necrosis ( $n = 6$ ) were managed conservatively with dressings and debridement without any need for additional procedures.

The mean age in patients whose flaps underwent necrosis was  $60.5 \pm 4$  years. Two of these patients suffered from cardiac disease. Out of eight patients who suffered from flap necrosis, ALT flap from the opposite side was the most commonly performed procedure for reconstruction ( $n = 3$ ), followed by free latissimus dorsi flap ( $n = 2$ ). Two other patients were treated by negative pressure wound therapy followed by grafting, and one was treated with a local flap.

## Discussion

The ALT flap is a versatile flap that has become one of the commonest flaps used by reconstructive microsurgeons. The cutaneous perforators from the pedicle are located near the midpoint of a line linking the anterior superior iliac spine to the lateral border of the patella.<sup>11,12</sup> A considerable variation is observed in the distribution of the perforators and in some cases, these may even be absent. The prevalence of this anomaly ranges from 1.37 to 5.4% in the literature.<sup>13</sup> Most of these perforators are musculocutaneous with long and oblique course, which result in difficult dissection and increase in chances of injury.<sup>14</sup> In our experience, we observed that 95% of the patients had musculocutaneous perforators and rarely we could find pure septocutaneous perforators. In contrast to septocutaneous perforators where the dissection is straightforward, musculocutaneous perforators demand meticulous dissection and failure to do so complicate flap harvesting and can even lead to intraoperative ALT flap transplantation failure. Even though the skin may still get its supply from minor perforators, the blood supply is too precarious to get optimum results. Liu et al reported that intraoperative failure of flap elevation or transplantation occurred mainly because of perforator injury or mistaken ligation in 13 out of 1,143 (0.01%) patients.<sup>15</sup> In our study, it was found that in only one patient the perforator was damaged during flap harvest.

Many authors have given their own protocols to manage injury to perforators. In emergency cases requiring salvage,

conventional remedial management has consisted of using a contralateral ALT flap or other flap for reconstruction from the same side. In a study by Liu et al, it was shown that several perforators are located in the ALT region both in the upper and lower parts.<sup>15</sup> In our experience whenever a sizable perforator is not found or has been accidentally injured, the patient is managed by taking some part of vastus lateralis underlying skin paddle which includes minor perforators. Alternatively, the anteromedial thigh perforator can be marked and used for flap harvest. This prevents immediate abandonment of the ALT flap.

In the first few cases that we performed, we observed a high incidence of perforator injury and flap necrosis. Realizing this, exposing the pedicle first through the medial side and proceeding toward the skin perforators was found to reduce injury to the perforator. The advantage of this technique over the standard method of harvest lies in the direct visualization of the skin perforator from the pedicle. Tracing the perforator from the pedicle is easy as one does not have to blindly guess its course. Further, because of the larger diameter of the perforator near its origin, its identification becomes easier.

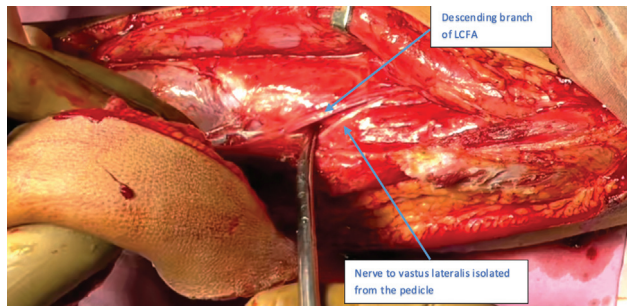
The mean harvest time was  $26 \pm 3.2$  minutes. This difference is significant when compared with the mean time (56.2 minutes) taken for flap harvest in the study published by Chen et al.<sup>16</sup> A study by Lueg et al also reported a mean harvest time of 50 minutes (range 41–75 minutes).<sup>17</sup> Similar to these, other studies report longer harvest time for dissecting musculocutaneous perforator in comparison to septocutaneous one. We have demonstrated that this technique is faster while dissecting musculocutaneous perforators. Additionally, the time saved can reduce the potential postoperative complications due to anesthesia and reduce the overall costs.<sup>18</sup>

In the postoperative course, 15 patients were re-explored for vascular issues; of these, eight flaps suffered from complete necrosis, five of them for lower extremity, two for head and neck, and one for hand reconstruction. Venous occlusions occurred in 12 flaps, while arterial occlusions occurred in 3 flaps. This was found to be due to twisting, kinking, or thrombosis at the anastomosis site. We also found that the

**Table 2** Summary of patient characteristics in failed cases

	Age, in years	Sex	Flap used for	Flap failure cause	Management	Complications
1.	54	M	Leg defect	Arterial thrombosis	Opposite side ALT	None
2.	43	M	Foot defect	Venous thrombosis	Opposite side ALT	None
3.	65	F	Leg defect	Venous thrombosis	Opposite side ALT	None
4.	44	M	Foot defect	Venous thrombosis	Debridement after 3 days followed by VAC and grafting	None
5.	75	F	Cheek defect	Venous thrombosis	Local flap	None
6.	72	F	Hand defect	Venous thrombosis	Debridement after 5 days followed by VAC and grafting	None
7.	65	M	Head and neck	Arterial thrombosis	LD flap	None
8.	63	F	Foot defect	Venous thrombosis	LD flap	None

Abbreviations: ALT, anterolateral thigh; LD, latissimus dorsi; VAC, vacuum-assisted closure.



**Fig. 5** Preserved cuff of muscle around the perforators.

rate of successful salvage for venous occlusion ( $n = 4$ , 33.3%) was similar to that of arterial occlusion. Our study matches the standards of published literature stated by Li et al in their systematic literature review in which 3.3% failure rate was observed in free flaps for head and neck reconstruction.<sup>19,20</sup> These patients were managed as opposite side ALT flap in three cases, free latissimus dorsi flap in two cases, vacuum-assisted closure with grafting in two cases, and local flap in one. Summary of outcomes of failed cases is given in **Table 2**.

The pedicle first technique is easier to perform in obese patients owing to direct visualization of the pedicle and the perforators toward the skin. ALT flap was largely unpopular in the beginning, especially in countries with a significant population of obese patients. It resulted in increased operative time as well as intra-operative complications.<sup>21</sup> In our series, we have performed this technique in obese individuals with no difficulty during dissection; therefore, we believe that this technique is equally useful in obese patients.

In a few selected patients, it is observed that the perforator size is very thin toward the skin; in such cases, it is wiser to take a small cuff of muscle around it to prevent its damage (**Fig. 5**). This makes this technique safer as we begin the dissection where the diameter of the perforator is large.

## Conclusion

The pedicle first technique makes ALT flap harvest easy, safe, and timesaving for plastic surgeons to employ this flap in their reconstruction armamentarium. The chances of injury to the skin perforator are markedly less during dissection, thereby indicating the superiority of this technique over the conventional one.

### Disclosure

No funding was received for this work. The authors have no financial interest to declare in relation to the content of this article. The article processing charge was paid for by the authors.

### Conflict of Interest

None declared.

## References

- Graboyes EM, Hornig JD. Evolution of the anterolateral thigh free flap. *Curr Opin Otolaryngol Head Neck Surg* 2017;25(05):416–421
- Zaretski A, et al. Anterolateral thigh perforator flaps in head and neck reconstruction. *Semin Plast Surg* 2006;20(02):64–72
- Wong CH, Wei FC. Anterolateral thigh flap. *Head Neck* 2010;32(04):529–540
- Demirkan F, Chen HC, Wei FC, et al. The versatile anterolateral thigh flap: a musculocutaneous flap in disguise in head and neck reconstruction. *Br J Plast Surg* 2000;53(01):30–36
- Chang WC, Chang CF, Cheng CM, Yang CY, Chen YW. Comparison of the hospitalization period after microvascular reconstruction flap in trismus patients: free anterolateral thigh flap versus free forearm flap. *Clin Oral Investig* 2019;23(07):2951–2957
- Yildirim S, Avci G, Aköz T. Soft-tissue reconstruction using a free anterolateral thigh flap: experience with 28 patients. *Ann Plast Surg* 2003;51(01):37–44
- Koshima I, Fukuda H, Utunomiya R, Soeda S. The anterolateral thigh flap; variations in its vascular pedicle. *Br J Plast Surg* 1989;42(03):260–262
- Tzouma G, Kopanakis NA, Tsakotos G, Skandalakis PN, Filippou D. Anatomic variations of the deep femoral artery and its branches: clinical implications on anterolateral thigh harvesting. *Cureus* 2020;12(04):e7867
- Smith RK, Wykes J, Martin DT, Niles N. Perforator variability in the anterolateral thigh free flap: a systematic review. *Surg Radiol Anat* 2017;39(07):779–789
- Lee YC, Chen WC, Chou TM, Shieh SJ. Anatomical variability of the anterolateral thigh flap perforators: vascular anatomy and its clinical implications. *Plast Reconstr Surg* 2015;135(04):1097–1107
- Kimata Y, Uchiyama K, Ebihara S, Nakatsuka T, Harii K. Anatomic variations and technical problems of the anterolateral thigh flap: a report of 74 cases. *Plast Reconstr Surg* 1998;102(05):1517–1523
- Dayan JH, Lin CH, Wei FC. The versatility of the anterolateral thigh flap in lower extremity reconstruction. *Handchir Mikrochir Plast Chir* 2009;41(04):193–202
- Hong JP, Kim EK. Sole reconstruction using anterolateral thigh perforator free flaps. *Plast Reconstr Surg* 2007;119(01):186–193
- Choi SW, Park JY, Hur MS, et al. An anatomic assessment on perforators of the lateral circumflex femoral artery for anterolateral thigh flap. *J Craniofac Surg* 2007;18(04):866–871
- Liu C, Li P, Liu J, Xu Y, Wu H, Gong Z. Management of intraoperative failure of anterolateral thigh flap transplantation in head and neck reconstruction. *J Oral Maxillofac Surg* 2020;78(06):1027–1033
- Chen HC, Tang YB. Anterolateral thigh flap: an ideal soft tissue flap. *Clin Plast Surg* 2003;30(03):383–401
- Lueg EA. The anterolateral thigh flap: radial forearm's "big brother" for extensive soft tissue head and neck defects. *Arch Otolaryngol Head Neck Surg* 2004;130(07):813–818
- Haughey BH, Wilson E, Kluwe L, et al. Free flap reconstruction of the head and neck: analysis of 241 cases. *Otolaryngol Head Neck Surg* 2001;125(01):10–17
- Li D, Long F, Lei M. Predictors affecting anterolateral thigh flap in reconstruction of upper extremity. *Medicine (Baltimore)* 2019;98(46):e17884
- Song YG, Chen GZ, Song YL. The free thigh flap: a new free flap concept based on the septocutaneous artery. *Br J Plast Surg* 1984;37(02):149–159
- Cleveland EC, Fischer JP, Nelson JA, Wink JD, Levin LS, Kovach SJ III. Free flap lower extremity reconstruction in the obese population: does weight matter? *J Reconstr Microsurg* 2014;30(04):263–270