







Use of Heparin Cream for Venous Congestion in the Extended Reverse Metacarpal Artery Flap: A Case Report

Burak Ergün Tatar, MD¹  Fahri Sabancıoğulları, MD¹  Caner Gelbal, MD¹ 
Mehmet Bozkurt, MD¹ 

¹ Department of Plastic Surgery, University of Health Sciences, Bağcılar Training and Research Hospital, Istanbul, Turkey

Address for correspondence Burak Ergün Tatar, MD, Büyükdere Street, Eclipse Apartment no. 55, Maslak District, 34100, Istanbul, Turkey (e-mail: burakerguntatar@gmail.com).

Arch Plast Surg 2022;49:663–667.

Abstract

Finger dorsum defects are a challenging situation. Many reconstruction methods are used in these defects. Extended reverse dorsal metacarpal artery (RDMA) flap is used in dorsal finger reconstruction. Venous congestion in this flap is most important cause of flap failure. In this case, we presented a case in which we used heparin cream due to development of venous congestion in our patient who underwent an extended RDMA flap. A 24-year-old female patient presented to the emergency department with a defect of dorsal of left-hand fourth finger. Defect was covered with an extended RDMA flap. On postoperative first day, venous congestion was observed, and heparin cream was applied three times a day on flap. The signs of venous congestion were regressed. Tissue healed as a result of superficial epidermolysis and skin grafting. No functional limitation was observed in sixth-month postoperative control. Venous congestion is the most important cause of flap failure of extended RDMA flaps. Generally, subcutaneous heparin administration and leech therapy are used. In our case, heparin was applied as a cream instead of subcutaneously, and flap healing was observed as a result of superficial epidermolysis. Heparin cream application can also be used as a treatment option in flaps with venous congestion.

Keywords

- ▶ heparin cream
- ▶ finger defects
- ▶ flap
- ▶ microsurgery

Introduction

The fact that the skin of the dorsum of the finger is thin and prone to scarring makes the dorsal defect reconstruction difficult.¹ Many uses such as homodigital, heterodigital, local and distant flap are used in dorsum defect reconstruction.¹ In addition to these flaps, with the development of microsurgery, free flaps usage is also increasing day by day.²

Reverse dorsal metacarpal artery (RDMA) flap is a flap used in the reconstruction of the dorsum of the finger.^{2,3} It

is used by tunneling propeller, cutaneous, pedicled, or subcutaneously according to the defect locations in the dorsal finger. Extended RDMA flap is used in distal dorsal finger defects.⁴ Like RDMA flaps, the major problem in extended dorsal metacarpal artery flaps is venous congestion.⁴ Although methods such as hyperbaric oxygen therapy, subcutaneous heparin injection, and leech therapy are used in the formation of venous congestion, no study or case report has been found in the literature regarding

received

January 14, 2022

accepted after revision

April 12, 2022

DOI <https://doi.org/>

10.1055/s-0042-1756344.

ISSN 2234-6163.

© 2022. The Korean Society of Plastic and Reconstructive Surgeons. All rights reserved.

This is an open access article published by Thieme under the terms of the Creative Commons Attribution-NonDerivative-NonCommercial-License, permitting copying and reproduction so long as the original work is given appropriate credit. Contents may not be used for commercial purposes, or adapted, remixed, transformed or built upon. (<https://creativecommons.org/licenses/by-nc-nd/4.0/>)

Thieme Medical Publishers, Inc., 333 Seventh Avenue, 18th Floor, New York, NY 10001, USA

the application of heparin cream in the extended RDMA flap.

In this article, we presented our case in which we used heparin cream due to the development of venous congestion in our patient who had an extended RDMA flap for dorsal finger defect.

Case

A 24-year-old female patient was admitted to the emergency department due to a chemical burn. A 1×2.5 cm defect was seen at the midphalanx level on the dorsal side of the left-hand ring finger (► **Fig. 1**). No fracture was found on X-ray. No motor deficit was found on physical examination. After the preparations were completed, the patient was transferred to the operating room. A perforator was detected in the dorsal and distal of the left wrist with a doppler device. As a result of debridement, a drawing was made suitable for the defect, and the drawing was extended between the third and fourth fingers (► **Fig. 2**). An incision was made from the proximal wrist under the pneumatic tourniquet, and elevation was continued with the loose areolar tissue plan on the paratenon on the extensor tendon. The drawing between the third and fourth fingers was continued with a meticulous dissection, the flaps were elevated over the paratenon in a lazy s shape from the proximal phalanx to the defect, and the tourniquet was opened and covered on wet and hot gauze for 10 minutes. Afterward, bleeding was controlled and flap flow was confirmed with a Doppler device. The flap was inserted into the defect area with 5-0 polypropylene. Wound dressing was done, and volar splint was used. The extremity was kept

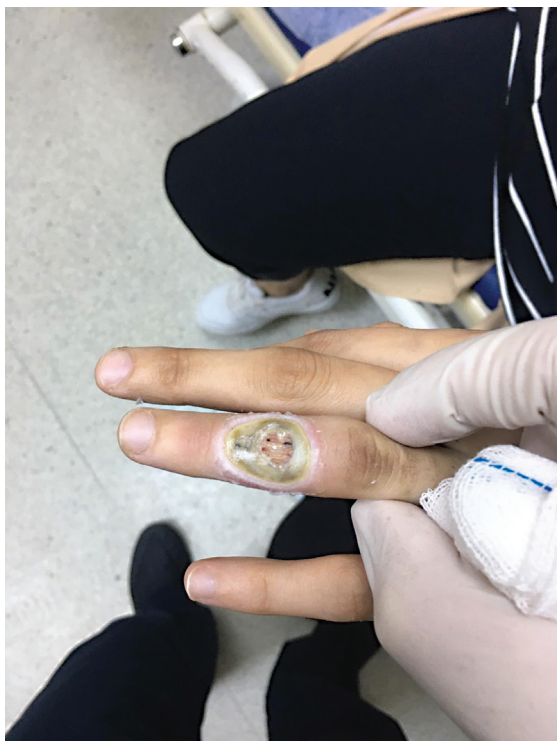

Fig. 1 Defect after burn injury.

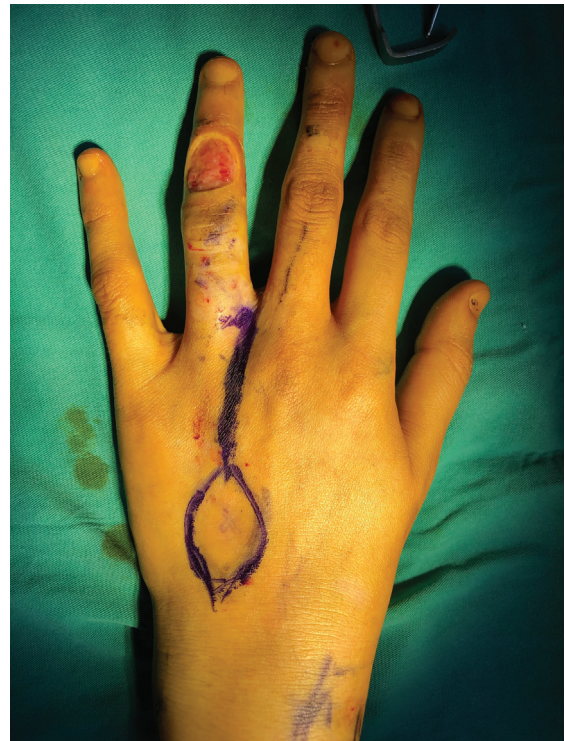

Fig. 2 The perforator located between the third and fourth metacarpal bones.

in elevation in the postoperative period. Antibiotherapy and subcutaneous clexane were administered.

Signs of venous congestion were observed on the first postoperative day (► **Fig. 3**). Sutures were removed, but no regression to congestion was observed. Heparin-Ratiopharm (Ulm, Germany) cream was applied on the flap three times a day, enough for the flap size. There was a regression in venous congestion on the third postoperative day (► **Fig. 4**). Heparin cream application was continued for 4 days. On the fifth postoperative day, healing was observed in the proximal flap, and epidermolysis occurred in the distal flap. A full-thickness skin graft was applied to the distal of the flap (► **Fig. 5**).

In the sixth-month postoperative control, a wound healing was observed that did not restrict the patient's movements. The patient did not have any functional complaints, but she stated that she was disturbed by the linear scar line on the dorsum of the hand (► **Figs. 6-7**). The patient signed the informed consent for the use of the photographs.

Discussion

Finger injuries are a common occurrence in plastic surgery. Ideally, the reconstruction should be done with a method that has good aesthetic and functional results. Since the dorsal finger skin is very thin and pliable, its reconstruction is also very difficult. Many flaps are used from local flaps to free flaps.⁵ In small defects, dorsal rotation flaps, advancement flaps, or hatchet flaps are used.⁶⁻¹¹ In moderate defects, cross finger flaps with adipofascial variants are

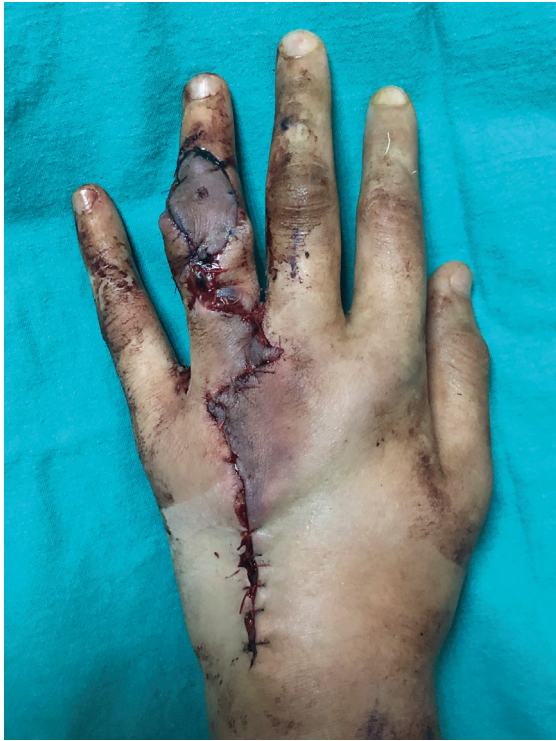

Fig. 3 Venous congestion on postoperative first day.

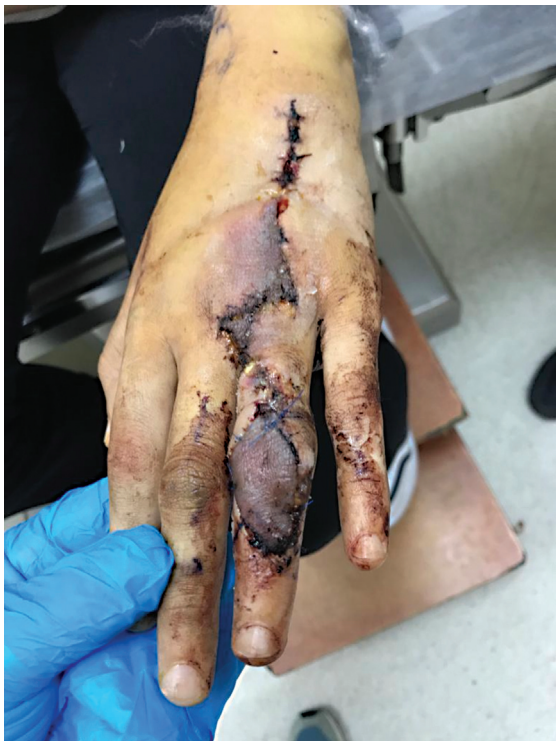

Fig. 4 Venous congestion decreased on the second day (third postoperative day) of heparin cream application.

especially used. Immobilization and two-stage operation procedure are important disadvantages in cross finger flaps. Size-independent free tissue transfer is used in volar finger defects, but free flap option is considered especially in large

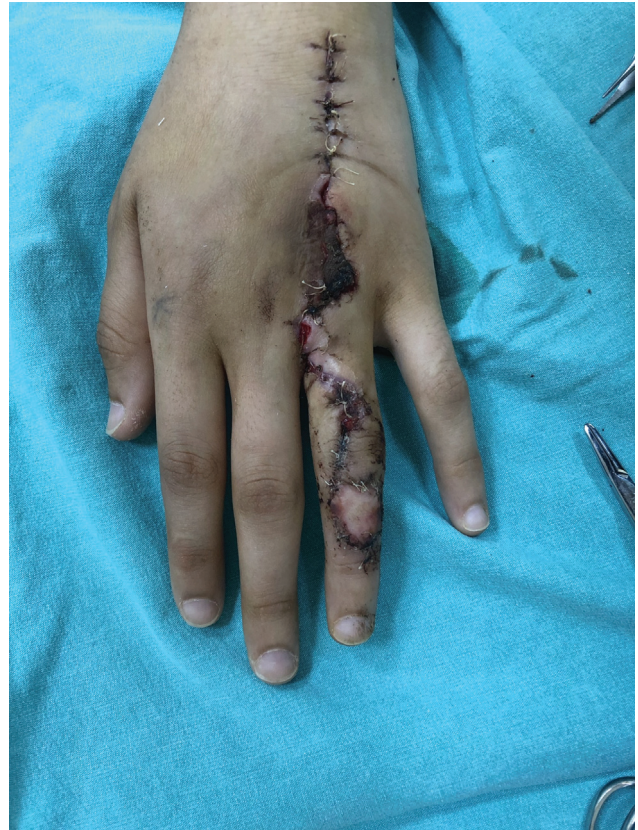

Fig. 5 The proximal flap healed, and epidermolysis was observed in the distal flap; it was covered with a full-thickness skin graft.

defects in dorsal defects.¹² Venous flaps should be considered as a choice, especially in dorsal hand-related dorsal hand defects.¹³

The RDMA flap was first described by Maruyama and Quaba in 1990.^{2,3} Beldame et al showed communication between dorsal metacarpal arteries and palmar digital arteries in their anatomical studies. In the same study, they detected plexiform communications especially in the distal juncturae.¹⁴ In their study in which they covered the defects at the proximal phalanx and proximal interphalangeal (PIP) joint level, Sebastin et al observed venous insufficiency as well as arterial insufficiency in distal defects.¹⁵

Koch et al in their study on communication at the level of the proximal phalanx observed venous congestion in approximately 20% of their cases.¹⁶ The most distal level defects cannot be covered with conventional RDMA flaps. For this reason, extended RDMA flap is used.

The pivot point of extended RDMA, defined in 1997, is the middle of the proximal phalanx, where the dorsal metacarpal artery and palmar common digital artery are anastomosed.^{17,18} According to clinical and cadaveric studies, extended blood supplies are from tiny dorsal branches coming from the palmar digital artery. To open the choaked veins here, it is necessary to wait 5 to 10 minutes of heating after elevating flap.¹⁸ The study of Shen et al stated that there is no significant difference between the classical RDMA flap and the extended in terms of complications. While the

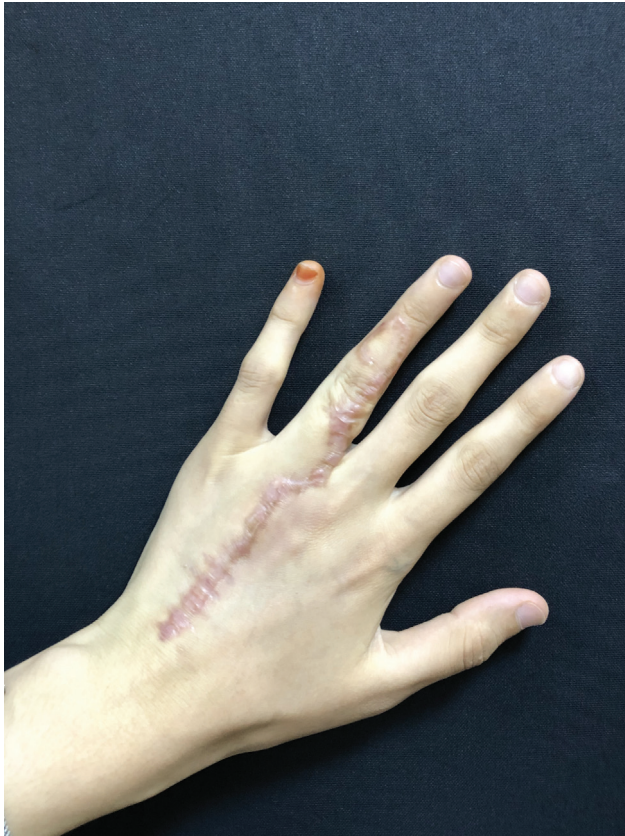

Fig. 6 The view of the dorsum of the hand at 6 months postoperatively.

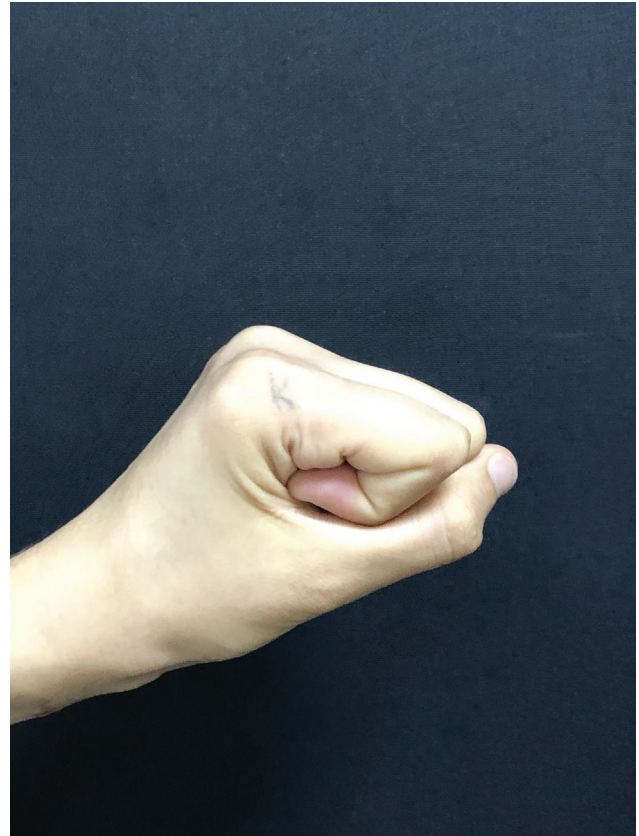

Fig. 7 Motor function is normal at 6 months postoperatively.

complication rate is 14% in classical RDMA flaps, it is 17% in extended RDMA flaps.⁴ Advantages of extended RDMA flaps are reliable blood supply, one stage finger reconstruction, reconstruction of distal of PIP joint, easy and simple dissection, primary closure of the donor site in generally, and isolation in composite form. The most important disadvantage is the presence of venous congestion, although not as much as RDMA flap, due to retrograde tissue nutrition. In case of venous congestion, the sutures are removed first, and if there is no regression, we apply 0.1 mL of subcutaneous heparin. At each point, it recovers in 7 days.

Heparin creams are used for lichen planus, thrombophlebitis, burns, or venous congestion in the nipple during breast operations.¹⁹ Although there are experimental studies on its use in flaps,^{19,20} no study has been found regarding its use in clinical practice. There is 60,000 IU heparin in 100 g of Heparin-Ratiopharm (Germany) cream that we used in our case.

Venous congestion in the extended dorsal metacarpal artery flaps is the main problem.⁴ Shen et al observed venous congestion in 5 of their studies on 16 patients. In these cases, they administered subcutaneous heparin. Since subcutaneous injection from many points is likely to damage the flap skin, we used heparin cream to cover the entire flap in our case. After the third day, there was a positive development of the flap color. As a result of partial epidermolysis, a complete recovery was achieved without any limitation of movement.

In conclusion, heparin creams can be used as an alternative to subcutaneous heparin administration in small flaps with a high probability of venous congestion, such as the extended dorsal metacarpal artery flap.

Authors' Contributions

M.B. was involved in conceptualization. B.E.T. contributed to data curation. F.S. did formal analysis. B.E.T. was involved in project administration and methodology. C. G. contributed to visualization. B.E.T. and C.G. wrote the original draft. B.E.T. reviewed and edited the manuscript. All authors were involved in approval of final manuscript.

Ethical Approval

We received the informed consent form from the patients for this study.

Conflict of Interest

None declared.

References

- 1 Balan JR, Mathew S, Kumar P, et al. The reverse dorsal metacarpal artery flap in finger reconstruction: a reliable choice. *Indian J Plast Surg* 2018;51:054–9
- 2 Quaba AA, Davison PM. The distally-based dorsal hand flap. *Br J Plast Surg* 1990;43(01):28–39

- 3 Maruyama Y. The reverse dorsal metacarpal flap. *Br J Plast Surg* 1990;43(01):24–27
- 4 Shen H, Shen Z, Wang Y, Zhang K, Zhang Z, Dai X. Extended reverse dorsal metacarpal artery flap for coverage of finger defects distal to the proximal interphalangeal joint. *Ann Plast Surg* 2014;72(05):529–536
- 5 Balan JR. Free toe pulp flap for finger pulp and volar defect reconstruction. *Indian J Plast Surg* 2016;49(02):178–184
- 6 Jiao H, Ding X, Liu Y, Zhang H, Cao X. Clinical experience of multiple flaps for the reconstruction of dorsal digital defects. *Int J Clin Exp Med* 2015;8(10):18058–18065
- 7 Rehim SA, Kowalski E, Chung KC. Enhancing aesthetic outcomes of soft-tissue coverage of the hand. *Plast Reconstr Surg* 2015;135(02):413e–428e
- 8 Eberlin KR, Chang J, Curtin CM, Sammer DM, Saint-Cyr M, Taghnia AH. Soft-tissue coverage of the hand: a case-based approach. *Plast Reconstr Surg* 2014;133(01):91–101
- 9 Chen S-L, Chou T-D, Chen S-G, Cheng TY, Chen TM, Wang HJ. The boomerang flap in managing injuries of the dorsum of the distal phalanx. *Plast Reconstr Surg* 2000;106(04):834–839
- 10 Chen C, Tang P, Zhang X. The dorsal homodigital island flap based on the dorsal branch of the digital artery: a review of 166 cases. *Plast Reconstr Surg* 2014;133(04):519e–529e
- 11 Karakol P, Sezgiç M, Tatar BE, Gelbal C, Uslu C. The use of dorsoradial forearm flap for the treatment of dorsal hand defect. *J Surg Case Rep* 2020;2020(07):rjaa153
- 12 Al-Qattan MM. The cross-digital dorsal adipofascial flap. *Ann Plast Surg* 2008;60(02):150–153
- 13 Yan H, Fan C, Zhang F, Gao W, Li Z, Zhang X. Reconstruction of large dorsal digital defects with arterialized venous flaps: our experience and comprehensive review of literature. *Ann Plast Surg* 2013;70(06):666–671
- 14 Beldame J, Havet E, Auquit-Auckbur I, Lefebvre B, Mure JP, Duparc F. Arterial anatomical basis of the dorsal digito-metacarpal flap for long fingers. *Surg Radiol Anat* 2008;30(05):429–435
- 15 Sebastin SJ, Mendoza RT, Chong AKS, et al. Application of the dorsal metacarpal artery perforator flap for resurfacing soft-tissue defects proximal to the fingertip. *Plast Reconstr Surg* 2011;128(03):166e–178e
- 16 Koch H, Bruckmann L, Hubmer M, Scharnagl E. Extended reverse dorsal metacarpal artery flap: clinical experience and donor site morbidity. *J Plast Reconstr Aesthet Surg* 2007;60(04):349–355
- 17 Karacalar A, Özcan M. A new approach to the reverse dorsal metacarpal artery flap. *J Hand Surg Am* 1997;22(02):307–310
- 18 Vuppalapati G, Oberlin C, Balakrishnan G. “Distally based dorsal hand flaps”: clinical experience, cadaveric studies and an update. *Br J Plast Surg* 2004;57(07):653–667
- 19 He Y-F, Wang Y-R, Li L-F, Wang SH, Ye JW. [Effect of low molecular heparin sodium cream on the content of serum nitric oxide in random pattern skin flap: experiment with rats]. *Zhonghua Yi Xue Za Zhi* 2007;87(43):3092–3094
- 20 Liu B, Li L, He Y, et al. The influence of zi-hua burn cream on the survival of random skin flaps in rats. *Zhonghua zhengxing wai ke za zhi= Zhonghua zhengxing waikesazhi= Zhonghua Zheng Xing Shao Shang Wai Ke Za Zhi* 2013;29:370–375