




Efficacy and Safety of Endoscopic Mucosal Resection with the Two-Person Method

Akinori Sasaki¹  Yuji Inada² Eriko Yamaguchi¹ Risa Okamoto¹ Yasuaki Motomura¹

¹Department of Gastroenterology, Tokyo Bay Urayasu Ichikawa Medical Center, Urayasu City, Chiba, Japan

²Department of General Internal Medicine, Aso Iizuka Hospital, Iizuka City, Fukuoka, Japan

Address for correspondence Akinori Sasaki, PhD, Department of Gastroenterology, Tokyo Bay Urayasu Ichikawa Medical Center, Urayasu City, Chiba 279-0001, Japan (e-mail: akinorisasaki6@gmail.com).

J Digest Endosc 2022;13:229–234.

Abstract

Objectives Endoscopic mucosal resection (EMR) is useful for removing colon polyps and is generally carried out by one doctor. It is occasionally difficult for colorectal polyps to be removed by EMR. In such cases, EMR is performed by the main doctor and an assistant doctor (the two-person method). However, the efficacy and safety of EMR in the two-person method remain unclear. This study aimed to compare the procedure time and incomplete resection rate (IRR) by the two- and single-person methods of EMR for polyp removal.

Materials and Methods Data from colorectal polyps resected by EMR were reviewed retrospectively and divided into two groups: general procedure/single- ($n = 215$) or two-person method ($n = 56$). The IRR, the procedure time, and the incidence of adverse events were compared between these methods.

Results A total of 152 patients and 271 lesions were included in this study. The mean procedure time for polypectomy was significantly shorter in the two-person method group than in the general procedure group (median time: 3.38 minutes vs. 6.56 minutes; $p < 0.001$). Additionally, the IRR for polyps was significantly lower in the two-person methods group than in the single-person methods group (2/56, 3.6% vs. 47/215, 21.9%; $p = 0.001$). None of the patients in the two-person method group presented with delayed bleeding.

Conclusions The two-person method for EMR was more effective than the single-person method. Therefore, this method may replace the conventional one-operator method in the future.

Keywords

- ▶ endoscopic mucosal resection
- ▶ two-person method
- ▶ procedure time
- ▶ incomplete resection rate

Introduction

Colorectal cancer is the third most common cancer globally, accounting for more than 1.8 million cases and 900,000 deaths yearly.¹ The purpose of screening and surveillance colonoscopy is to prevent colorectal cancer by identifying

and removing early and precancerous lesions. In most cases, colorectal cancer arises via the progression of neoplastic low-grade dysplasia to high-grade dysplasia.

Endoscopic resection (ER) is an efficacious and safe treatment for colorectal polyps. Cold snare polypectomy and EMR

DOI <https://doi.org/10.1055/s-0042-1756484>.
ISSN 0976-5042.

© 2022. The Author(s).

This is an open access article published by Thieme under the terms of the Creative Commons Attribution License, permitting unrestricted use, distribution, and reproduction so long as the original work is properly cited. (<https://creativecommons.org/licenses/by/4.0/>)

Thieme Medical and Scientific Publishers Pvt. Ltd., A-12, 2nd Floor, Sector 2, Noida-201301 UP, India

are widely accepted as the standard procedure for resecting polyps by ER. In particular, EMR for colorectal lesions is useful for removing polyps more than 10 mm, high-grade dysplasia, adenoma, adenocarcinoma in situ, and other abnormal lesions from the gastrointestinal tract.² Submucosal injections lift lesions and decrease the risk of positive margins, perforation, and thermal injury.^{3,4} In addition, the EMR procedure is easier than endoscopic submucosal dissection.

Traditionally, endoscopists perform EMR alone. However, it is sometimes difficult to perform EMR for certain tumor locations (location behind folds and lesions of the ileocecal valve) and morphology (nongranular pseudodepressed lateral spreading tumors). The EMR procedure for difficult lesions, such as large polyps and sessile, serrated adenomas/polyps, is related to the risk of incomplete polyp resection.⁵

Several devices are used during EMR for difficult lesions. In addition, the endoscopic procedure is sometimes conducted by two endoscopists (i.e., with an assistant doctor) in difficult cases to define the margins of the target lesion easily and completely secure it.

However, the efficacy and safety of the two-person method of EMR for colorectal lesions remain unclear. Therefore, this study aimed to determine whether the two-person EMR is more efficacious and safer than traditional EMR.

Materials and Methods

Patients

A retrospective study was performed to examine the usefulness of the two-person EMR method through an image evaluation study of digital endoscopic images of tumor lesions in patients who had undergone EMR between April and August 2021. In addition, we distinguished the single- and two-person EMR methods using the date of the electronic medical record.

The exclusion criteria were no endoscopic image before or after EMR, the procedure as precutting EMR, and the recurrence of lesions after previous treatment procedures. Additionally, we included the en bloc resection EMR cases and

excluded the piecemeal EMR cases. Clinical and clinicopathological information was collected from hospital records and reviewed retrospectively.

All patients provided written, informed consent before participating in this observational study.

Endoscopic Procedure (Definition of Two-Person Method)

The primary objective of our study was to evaluate the procedure time of EMR and the IRR with the two-person method. Secondary endpoints were the total procedure time and safety of the two-person method. Safety was defined as the presence or absence of bleeding and perforation.

The two-person method was defined as the treatment procedure with two endoscopists (i.e., a doctor performed the endoscopy, and an assistant doctor operated endoscopic devices like a snare, injection needle, and clip procedure). Assistant doctors were endoscopists or gastroenterology fellows. Assistant doctors generally operate the endoscopic devices and do not guide the procedure. **Fig. 1** shows the two-person method. The assistant doctor stood on the left of the main doctor and handled the endoscopic devices. On the other hand, the single-person method is performed by one doctor. Although a nurse assists with the procedure during EMR, only the doctor operates both endoscopy and endoscopic devices.

The procedure time was defined as the time from initial submucosal injection to removing tumors or closure with clips. The procedure time was calculated using digital files describing the correct time. Colon screening time was calculated using medical records for reference.

Histopathological Evaluation

Pathologists assessed the histology, tumor invasion, and margin status. The resected lesion was evaluated for the presence or absence of free lateral and deep resection margins. Complete histologic excision was defined as no visible adenoma or hyperplasia on histology of the forceps

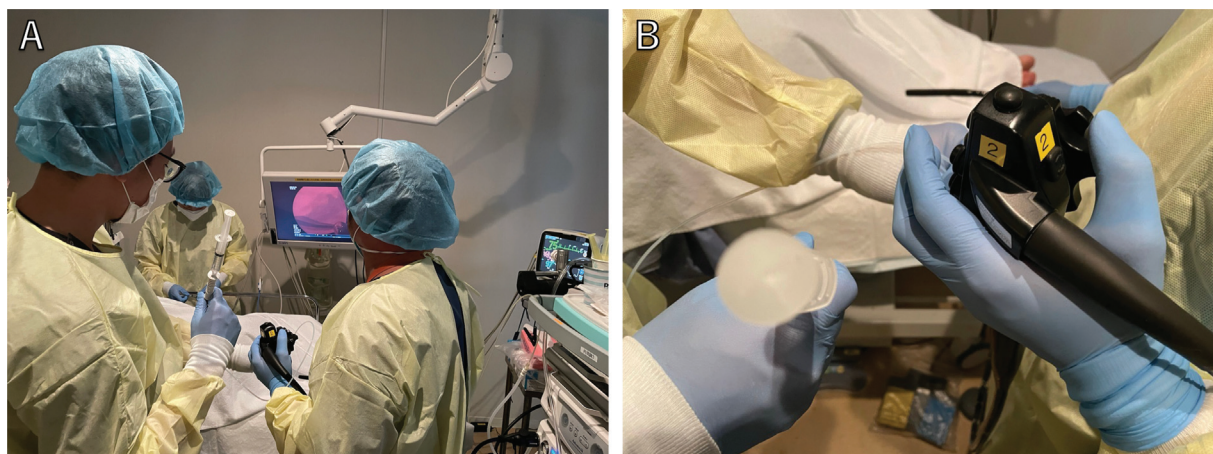


Fig. 1 Two-person methods. (A) Main operator, the person on the right, handles endoscopy. Assistant doctor, the person on the left, deals with device. (B) Assistant doctor withdraws and deposits the device like in this picture.

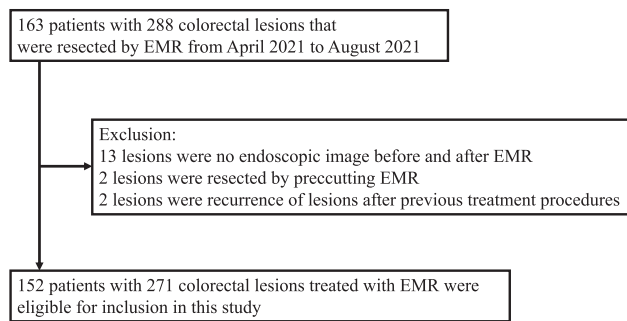


Fig. 2 Consort flow diagram. EMR, endoscopic mucosal resection.

samples taken from the base and four quadrant tissues of the wound margins.⁶

Statistical Analysis

Statistical comparisons of baseline characteristics between single and double procedure cases were performed using the χ^2 test or Fisher's exact test for categorical data and the Student's t-test or Mann-Whitney U test for continuous data. All statistical analyses were performed with 5% alpha risk or 95% confidence intervals (CIs) using SPSS version 25 (IBM, Chicago, Illinois, United States). A multivariate analysis was conducted to adjust the odds ratio (OR) using clinical factors associated with IRR.

Results

Patient Characteristics

Among 163 patients and 288 colorectal lesions treated with EMR between April and August 2021, 17 cases were excluded because of the above criteria. Thus, 152 patients with 271 lesions were eligible for inclusion in this study (► **Fig. 2**).

► **Table 1** shows the patient characteristics. The median patient age was 68.0 years (range: 35.0–81.0), and 98 patients (64.4%) were male. The median polyp size was 8.0 mm (range: 6.0–10.0). Tumor size, histology, and morphology were not significantly different between the two groups. However, tumor location was significantly different between each group. Additionally, prophylactic clip placement was at a significantly lower rate in the two-person method than in the single-person method (62.5 vs. 81.9%; $p = 0.003$).

Two-Person Method Efficacy and Safety

The efficacy and safety are reported in ► **Table 2**. The IRR for resected polyps was significantly lower in the two-person method than in the single-person method (2/56, 3.6 vs. 47/215, 21.9%; $p = 0.001$).

The mean procedure time for EMR was significantly shorter in the two-person method than in the single-person method (median time: 3.38 min vs 6.56 min; $p < 0.001$). Additionally, the total time for colonoscopy was significantly shorter in the two-person method than in the single-person method (median time: 30.06 min vs 45.00 min; $p < 0.001$).

There was no difference in postpolypectomy bleeding between the single- and two-person method groups. How-

ever, 8/215 (3.7%) single-person method cases were complicated by postpolypectomy bleeding, whereas no postpolypectomy bleeding occurred with the two-person method. There was no perforation due to EMR in either group.

► **Table 3** shows the factors associated with IRR. On univariate analysis, tumor location (right side) and single-person method were correlated with IRR, with p -values of 0.011 and 0.001, respectively. On multivariate analysis, the single-person method was an independent risk factor for IRR ($p = 0.021$, OR = 5.637, 95% CI = 1.30–24.431).

Discussion

This study evaluated the efficacy and safety of the two-person EMR method. To our knowledge, this is the first report on the efficacy and safety of two-person EMR. This study demonstrated that the two-person EMR method could reduce treatment time more than the single-person method. Moreover, the IRR for resected polyps was significantly lower in the two-person method than in the single-person method.

EMR is safe and effective for treating colorectal polyps. EMR is more effective than polypectomy in the following factors: (1) easy-to-grip lesions, (2) complete resection with negative lateral margins because of resection of the tumor and surrounding intestinal mucosa, (3) complete resection with negative vertical margins because of resection including the submucosal layer, (4) less bleeding during resection due to the effect of injection, and (5) less wound-to-muscle layer because of separating the lesion from the underlying muscle layer.

However, some lesions are difficult to remove en bloc by EMR. Failure of en bloc EMR was associated with tumor size, morphology (especially laterally spreading tumor), and location (especially right colon).⁷ Piecemeal resection of colorectal lesions was associated with moderate recurrence rates. A previous systematic review and meta-analysis supported the view that the risk of local recurrence is significantly higher after piecemeal EMR than en bloc EMR, with recurrence rates of 20 and 3%, respectively.⁸ In addition, resectioning recurrent lesions tends to be difficult because of submucosal scarring. Failure of en bloc EMR tends to decrease in experienced hands. However, it is difficult for experienced hands to perform the procedure while grasping the endoscope with their right hand during EMR.

In a two-person EMR, the main operator grasps the endoscope, and the assistant maneuvers the devices. Therefore, it makes EMR easier and safer than the general procedure. In fact, with two-person EMR, 96.4% of 56 polyps were completely resected, leaving only 3.6% of patients with incompletely resected polyps. The mean procedure time for EMR was also significantly shorter in the two-person method than in the single-person method (median time: 3.38 min vs. 6.56 min; $p < 0.001$). In addition, there were no complications, including postoperative bleeding, in the two-person method group. It suggested that the two-person method was also valid for the procedure of clip placement. These results suggest that EMR with the two-person method is efficacious and safe.

Table 1 Patient characteristics in the both group

Features	Two-person method (n = 56)	Single-person method (n = 215)	p-Value
Age, median (range)	67 (42–80)	69 (35–81)	0.497
Male, n (%)	40 (71.4%)	143 (66.5%)	0.525
Antibleding drug	7 (12.5%)	16 (7.4%)	0.279
Polyp size (mm)	8.0 (5.0-15.0))	8.0 (4.8-15.0)	0.255
Clip closure	35 (62.5%)	176 (81.9%)	0.003
Location			
Cecum	2 (3.6%)	15 (7.0%)	0.037
Ascending colon	6 (10.7%)	44 (20.5%)	
Transverse colon	7 (12.5%)	46 (21.4%)	
Descending colon	6 (10.7%)	24 (11.2%)	
Sigmoid colon	19 (33.9%)	56 (26.0%)	
Rectum	16 (28.6%)	30 (14.0%)	
Histology			
Low-grade adenoma	48 (85.7%)	154 (71.6%)	0.245
High-grade adenoma	0 (0%)	13 (6.0%)	
Tubulovillous adenoma	0 (0%)	1 (0.5%)	
Cancer in situ	1 (1.8%)	8 (3.7%)	
Submucosal superficial cancer	0 (0%)	3 (1.4%)	
Submucosal deep cancer	0 (0%)	2 (0.9%)	
Hyperplastic polyp	0 (0%)	13 (6.0%)	
Sessile serrated adenoma/polyp	5 (8.9%)	14 (6.5%)	
Traditional serrated adenoma	1 (1.8%)	1 (0.5%)	
Juvenile polyp	0 (0%)	3 (1.4%)	
Inflammatory polyp	1 (1.8%)	1 (0.5%)	
Morphology			
0-Ip	2 (3.6%)	10 (4.7%)	0.301
0-Isp	27 (48.2%)	89 (41.4%)	
0-Is	8 (14.3%)	17 (7.9%)	
0-IIa	16 (28.6%)	94 (43.7%)	
0-IIa + c	1 (1.8%)	3 (1.4%)	
0-Is + IIa	1 (1.8%)	1 (0.5%)	
0-Is + IIc	1 (1.8%)	1 (0.5%)	

It is important to note the limitations of our study. First, this was a retrospective, single-institution study with limited sample size. Therefore, the differences in polyp characteristics and location between the two- and single-person methods might have contributed to the procedure time and IRR. Second, endoscopists were not randomly assigned to the single- or two-person method group. As such, it is unclear if these results would be reproducible in all settings and by endoscopists who were not already experienced with conventional EMR techniques. This study might have been prone to selection bias. Third, the frequency of clip placement was significantly lower with the two-person method than with the single-person method. This might be attributed to more polyp lesions on the right side

of the colon in the single-person method group. This result might also have influenced procedure time. However, carrying out a clip placement is optional after the endoscopic removal of large polyps. We performed a clip placement of lesions with hemorrhagic risks, such as large tumors.⁹ There was no case of bleeding after EMR in the two-person method group. Fourth, EMR was successful in about 90% of patients in previous studies.^{10,11} Conversely, over 20% of EMR led to incomplete polyp resection in the single-person procedure group. Finally, two doctors (one for the main procedure and one assistant) were needed for the two-person methods. In small hospitals, EMR with the two-person method would be difficult. Regarding this point, we will conduct a clinical trial to assess the

Table 2 Efficacy and safety in the both group

Results	Two-person method (n = 56)	Single-person method (n = 215)	p-Value
Procedure time, median (minutes), 95% CI	3.38 (1.06–14.14)	6.56 (2.52–20.39)	<0.001
Total time, median (minutes), 95% CI	30:06 (11:07–54:42)	45:00 (9:28–1:17:42)	<0.001
IRR	2 (3.6%)	47 (21.9%)	0.001
Postbleeding	0 (0%)	8 (3.7%)	0.212
Perforation	0 (0%)	0 (0%)	–

Abbreviations: CI, confidence interval; IRR, incomplete resection rate.

Table 3 Factors associated with IRR

Factor	n	Incident of IRR	Univariate analysis		Multivariate analysis	
			Odds ratio (95% CI)	p-Value	Odds ratio (95% CI)	p-Value
Size						
Median >	161	33 (20.5)	1.515 (0.788–2.912)	0.261	1.278 (0.629–2.5974)	0.497
Median <	101	16 (14.5)				
Morphology						
Nonpolypoid	114	27 (23.7)	1.904 (1.020–3.555)	0.054	1.531 (0.768–3.048)	0.226
Polypoid	157	22 (14.0)				
Location						
Right	120	30 (25.0)	2.314 (1.228–4.366)	0.011	1.944 (0.968–3.906)	0.062
Left	151	19 (12.6)				
Histology						
Adenoma	229	39 (17.0)		0.28		0.284
Adenocarcinoma	14	5 (10.2)				
SSAP/TSA	21	3 (14.3)				
Other	7	2 (28.6)				
Method						
Single-person method	215	47 (21.9)	7.575 (1.776–32.25)	0.001	5.637 (1.300–24.431)	0.021
Two-person method	56	2 (3.6)				

Abbreviations: CI, confidence interval; IRR, incomplete resection rate; SSAP, Sessile serrated adenoma/polyp; TSA, traditional serrated adenoma.

efficacy of the two-person method with well-trained nurses or technicians in the future.

Given these limitations, the current study only generated a hypothesis, and a more detailed system needs further evaluation. In conclusion, the two-person method for EMR is an efficacious and safe procedure for endoscopic polypectomy. These findings deserve further investigation in a larger cohort to validate the efficacy of EMR with two-person methods.

Conclusions

The two-person method of EMR is more efficacious and safer than traditional EMR. This method may replace the conventional one-operator method in the future.

Abbreviations

CRC Colorectal cancer
EMR endoscopic mucosal resection

ER endoscopic resection
IRR incomplete resection rate
OR odds ratio

Authors' Contributions

AS conceptualized the study. AS, IY, EY, RO, and YM were involved in data curation. AS did formal analysis. AS was involved in methodology. AS and YM were involved in project administration. YM did supervision. AS and YM were involved in visualization. AS and YM wrote, reviewed, and edited the original draft.

Ethical Statement

The corresponding author, on behalf of all authors, jointly and severally, certifies that their institution has approved the protocol for any investigation involving humans or animals and that all experimentation was conducted in conformity with ethical and humane principles of research.

Funding

None.

Conflict of Interest

None declared.

Acknowledgments

None declared.

References

- 1 Bray F, Ferlay J, Soerjomataram I, Siegel RL, Torre LA, Jemal A. Global cancer statistics 2018: GLOBOCAN estimates of incidence and mortality worldwide for 36 cancers in 185 countries. *CA Cancer J Clin* 2018;68(06):394–424
- 2 Conio M, Repici A, Demarquay JF, Blanchi S, Dumas R, Filiberti R. EMR of large sessile colorectal polyps. *Gastrointest Endosc* 2004;60(02):234–241
- 3 Rosenberg N. Submucosal saline wheal as safety factor in fulguration or rectal and sigmoidal polypi. *AMA Arch Surg* 1955;70(01):120–122
- 4 Norton ID, Wang L, Levine SA, et al. Efficacy of colonic submucosal saline solution injection for the reduction of iatrogenic thermal injury. *Gastrointest Endosc* 2002;56(01):95–99
- 5 Pohl H, Srivastava A, Bensen SP, et al. Incomplete polyp resection during colonoscopy—results of the complete adenoma resection (CARE) study. *Gastroenterology* 2013;144(01):74–80.e1
- 6 Nagtegaal ID, Odze RD, Klimstra D, et al; WHO Classification of Tumours Editorial Board. The 2019 WHO classification of tumours of the digestive system. *Histopathology* 2020;76(02):182–188
- 7 Walsh RM, Ackroyd FW, Shellito PC. Endoscopic resection of large sessile colorectal polyps. *Gastrointest Endosc* 1992;38(03):303–309
- 8 Belderbos TD, Leenders M, Moons LM, Siersema PD. Local recurrence after endoscopic mucosal resection of nonpedunculated colorectal lesions: systematic review and meta-analysis. *Endoscopy* 2014;46(05):388–402
- 9 Nishizawa T, Suzuki H, Goto O, Ogata H, Kanai T, Yahagi N. Effect of prophylactic clipping in colorectal endoscopic resection: a meta-analysis of randomized controlled studies. *United European Gastroenterol J* 2017;5(06):859–867
- 10 Buchner AM, Guarner-Argente C, Ginsberg GG. Outcomes of EMR of defiant colorectal lesions directed to an endoscopy referral center. *Gastrointest Endosc* 2012;76(02):255–263
- 11 Moss A, Bourke MJ, Williams SJ, et al. Endoscopic mucosal resection outcomes and prediction of submucosal cancer from advanced colonic mucosal neoplasia. *Gastroenterology* 2011;140(07):1909–1918