



Aldosterone-Secreting Large Oncocytic Neoplasm of the Adrenal Gland with Borderline Potential

Maher Alshaheen¹ Krishanu Das² Mary Jean³ Mhd Firas Safadi⁴

¹Department of Internal Medicine, Bahrain Specialist Hospital, Manama, Kingdom of Bahrain

²Department of Urology and Andrology, Bahrain Specialist Hospital, Manama, Kingdom of Bahrain

³Department of Pathology, Bahrain Specialist Hospital, Manama, Kingdom of Bahrain

⁴Department for Visceral, Thoracic and Vascular Surgery, University Hospital Carl Gustav Carus, Technische Universität Dresden, Germany

Address for correspondence Mhd Firas Safadi, MD, FHEA, Department for Visceral, Thoracic and Vascular Surgery, University Hospital Carl Gustav Carus, Technische Universität, Fetscherstraße 74, 01307 Dresden, Germany (e-mail: doctor.safadi@gmail.com).

Avicenna J Med 2022;12:182–185.

Abstract

Adrenal oncocytomas are rare tumors that are mostly benign and non-functional although they may be hormonally active and can exhibit a borderline or malignant potential. We present a case of a 40-year-old female patient with known hypertension who presented with abdominal discomfort. Radiologic investigations showed a large mass on the left adrenal gland. In the hormonal study, an aldosterone-secreting tumor was identified. After laparoscopic resection, the histological assessment of the 12-cm mass showed an oncocytic neoplasm with borderline characteristics. The laboratory results returned to normal and the hypertensive disease improved. The patient was doing well after 14 months of follow-up. This is the seventh documented case of aldosterone-secreting oncocytoma, the first borderline tumor of this type, and the largest reported tumor so far.

Keywords

- ▶ adrenal gland
- ▶ hyperaldosteronism
- ▶ oncocytoma
- ▶ laparoscopy
- ▶ hypertension

Introduction

Adrenocortical oncocytic neoplasms are rare tumors that are characterized by the presence of oncocytes.¹ The majority of these tumors are non-functional, but they may be associated with hormonal secretion, causing a variety of adrenal hormonal syndromes.² Although most tumors are benign, borderline and malignant variants were described.³ In this article, we describe the seventh documented case of aldosterone-secreting oncocytoma, the first borderline tumor of this type, and the largest reported tumor so far.

Case Report

A 40-year-old female patient presented to her general practitioner with increasing abdominal discomfort in the left

hypochondrium over a few months. Her medical history included arterial hypertension for around 8 years, which was treated with amlodipine 5 mg once daily. On ultrasonography, the general practitioner found a mass between the spleen and the left kidney. The patient was referred to our center for further study. On computed tomography, the mass was consistent with an adrenal tumor (▶Fig. 1).

We initiated a comprehensive laboratory workup. Pheochromocytoma, Cushing's syndrome, and androgen-secreting tumors were excluded (▶Table 1). The results showed low plasma renin relative to the normal plasma aldosterone with elevated aldosterone to renin ratio (ARR). We established the diagnosis of an aldosterone-secreting adrenal tumor and made the indication of surgical treatment.

The operation was performed laparoscopically through a transperitoneal approach using three ports. The specimen

article published online
September 15, 2022

DOI <https://doi.org/10.1055/s-0042-1756675>.
ISSN 2231-0770.

© 2022. Syrian American Medical Society. All rights reserved.
This is an open access article published by Thieme under the terms of the Creative Commons Attribution-NonDerivative-NonCommercial-License, permitting copying and reproduction so long as the original work is given appropriate credit. Contents may not be used for commercial purposes, or adapted, remixed, transformed or built upon. (<https://creativecommons.org/licenses/by-nc-nd/4.0/>)
Thieme Medical and Scientific Publishers Pvt. Ltd., A-12, 2nd Floor, Sector 2, Noida-201301 UP, India

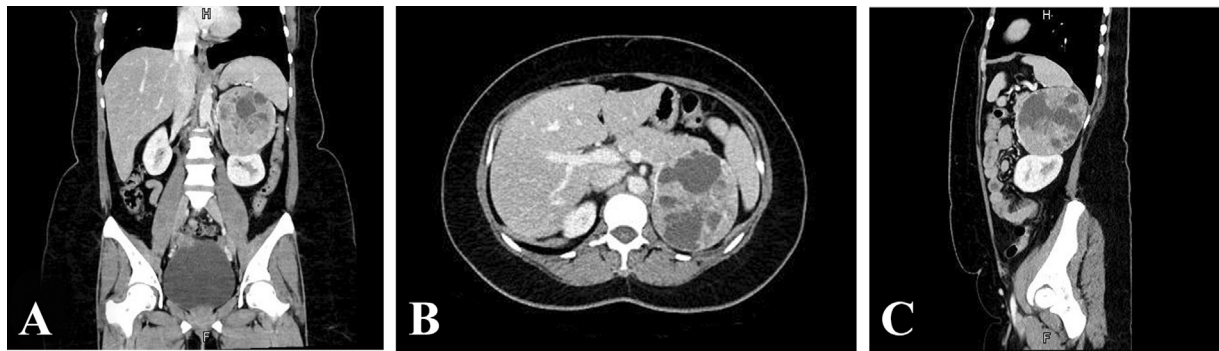

Fig. 1 (A) Coronal, (B) transverse, and (C) sagittal sections of the computed tomography of the abdomen in the arterial phase of contrast enhancement. A large inhomogeneous lesion with cystic components can be seen in the left upper quadrant of the abdomen. The lesion abuts and compresses both the spleen and the upper pole of the left kidney (B and C). There is no evidence of local invasion, other masses, regional lymphadenopathy, or metastases to the parenchymal organs.

was extracted through a Pfannenstiel incision (→Fig. 2). The patient was discharged home on the second postoperative day.

The histopathologic study showed an oncocytic adrenocortical neoplasm of uncertain malignant potential. The immunohistochemical tests showed a positive melan A and Ki67 with a score of 3%, whereas calretinin, chromogranin, S-100, and inhibin were all negative (→Fig. 3).

One week postoperatively, the hormonal profile showed a significant decrease in ARR from 67.8 to 22, and the maintenance dose of amlodipine could be reduced to 2.5 mg daily. One year postoperatively, ARR was normal at 3.8. After 14 months of follow-up, the patient was well with no signs of local or distant recurrence.

Table 1 Serum laboratory results

Laboratory assay	Patient's results	Reference range
Creatinine, mg/dL	0.67	0.5–0.9
Blood urea nitrogen, mg/dL	14.9	5–50
Sodium, mmol/L	138	135–145
Potassium, mmol/L	3.89	3.5–5.1
Chloride, mmol/L	104.4	98–107
Adrenalin, ng/L	76	< 82
Noradrenalin, ng/L	460	< 499
Metanephrine, ng/L	50	< 90
Normetanephrine, ng/L	96	< 126
Cortisol (at 4 AM), nmol/L	490.6	171–536
Cortisol (at 4 PM), nmol/L	260.6	64–327
Testosterone, ng/mL	0.051	0.084–0.481
DHEA-S, µg/dL	66.51	35.4–256
Aldosterone, ng/dL	14.7	1.2–35
Renin, ng/dL	0.22	0.26–2.8
ARR	67.8	< 19

Abbreviations: ARR, aldosterone to renin ratio; DHEA-S, dehydroepiandrosterone sulfate.

Discussion

Adrenocortical oncocytic neoplasms are rare tumors that include oncocytoma, oncocytic neoplasm of uncertain malignant potential, and oncocytic carcinoma.¹ The hallmark of these tumors is the presence of oncocytes, which are polygonal cells with abundant granular eosinophilic cytoplasm.⁴ These tumors predominate in females and occur more often on the left side.¹ Most adrenal oncocytomas are benign and up to 70% are nonfunctional.² The differential diagnosis includes mainly adrenal adenomas in addition to gangliomas, gangliocytic paragangliomas, and lipomas.⁵

Some adrenal oncocytic neoplasms are hormonally active. Reported associations include pheochromocytoma, Cushing's syndrome, and hyperandrogenism.^{1,6} However, aldosterone-secreting oncocytoma is a very rare variant,⁷ and there are only six documented cases in the literature, with this case being the seventh. →Table 2 presents a review of all described cases.

Our patient was previously considered to have essential hypertension but without a proper workup. This stresses the importance of investigating secondary causes in every patient with hypertension.⁸ Hypokalemia was long considered a sine qua non for the diagnosis of aldosterone-secreting adrenal tumors, but most patients show normal potassium levels.⁸ The preoperative aldosterone level was also in the normal range and the diagnosis was based on the elevated aldosterone to renin ratio (ARR). A saline infusion test was not performed because it would not have influenced the treatment decision.

Elevated aldosterone levels are not a prerequisite for the diagnosis of aldosteronoma. Stowasser et al found that plasma aldosterone was less than 15 ng/dL in 36% of 74 patients who were diagnosed with primary aldosteronism based on an ARR greater than 30.⁸ The other two observations that confirm the hormonal nature of the tumor in this patient are the gradual return of the ARR to the normal range and the improvement of hypertension during follow-up. A recent meta-analysis revealed that ARR has a sensitivity of 89% and a specificity of 96% at cut-offs ranging from 26.35 to 59.66, which suggests that ARR is an effective and convenient screening tool for primary aldosteronism.⁹

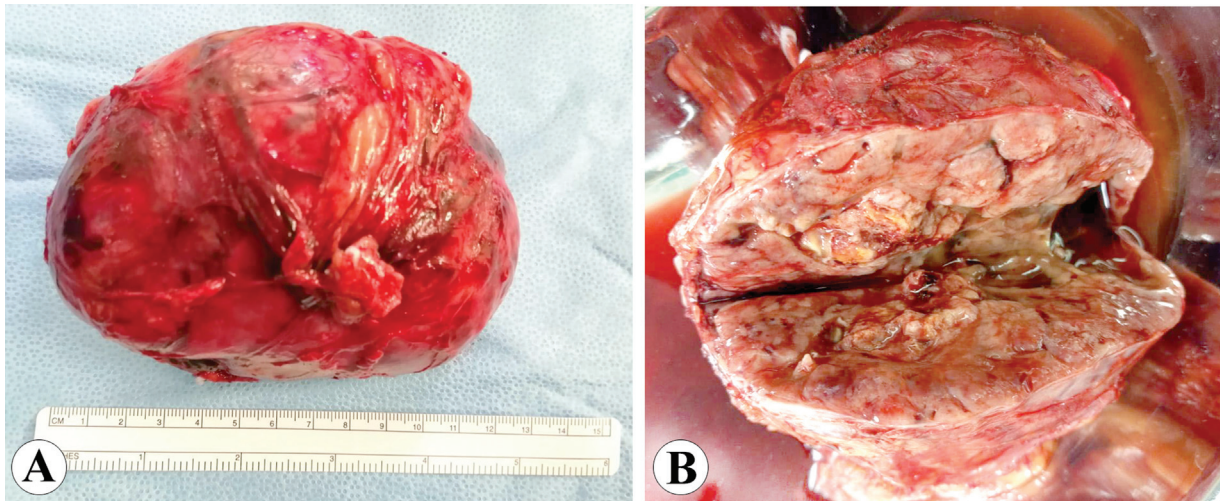


Fig. 2 Gross examination of the specimen. (A) The nodular mass measures $12 \times 9 \times 6$ cm and weighs 329 g. (B) The cut section shows solid grayish areas as well as soft hemorrhagic spaces in between.

In the absence of local invasion, the malignancy potential of adrenal oncocytomas is determined based on the modified Lin–Weiss–Bisceglia (LWB) scoring system. Tumors are classified into benign, borderline, or malignant according to major or minor criteria. The major criteria include a mitotic rate > 5 per 50 high power fields, atypical mitoses, or venous invasion.

The minor criteria are size > 10 cm or weight > 200 g, microscopic necrosis, capsular invasion, or sinusoidal invasion. The tumor is considered malignant if it shows one major criterion, borderline if it shows one or more minor criteria, and benign if it does not show any major or minor criteria.³ The tumor in our case measured 12 cm and weighed 329 g. There was no

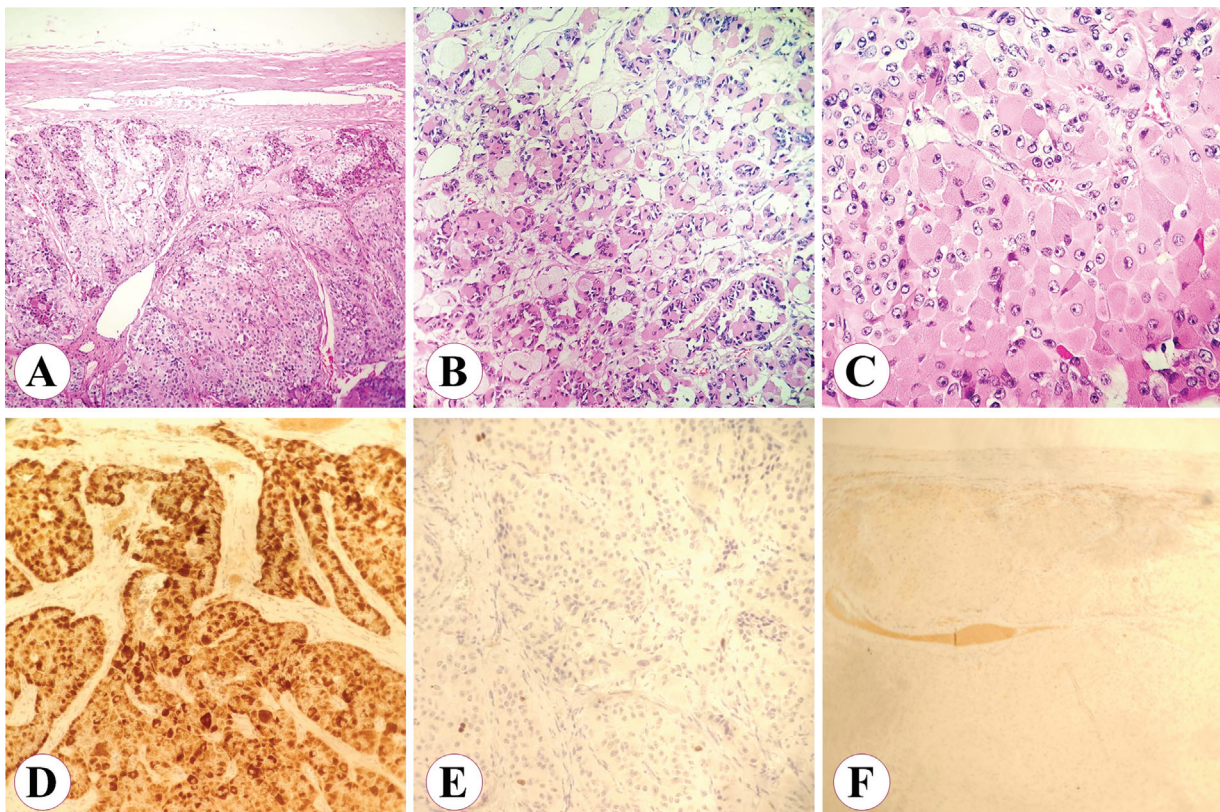


Fig. 3 Microscopic examination of the tumor with the hematoxylin and eosin (H&E) stain (upper row) and with immunostaining (lower row). (A) The mass is well-circumscribed with no capsular invasion (original magnification $\times 40$). (B) The tumor cells are arranged in a diffuse and sinusoidal pattern (original magnification $\times 100$). (C) Close-up of oncocytic cells showing the abundant eosinophilic cytoplasm with hyperchromatic nuclei and prominent nucleoli. Mitotic activity equals 2 to 3 per 50 high power fields (original magnification $\times 400$). The immunohistochemistry was positive for melanin (D), positive for Ki67 with a score of 3% (E), and negative for chromogranin (F).

Table 2 Reported cases of aldosterone-secreting oncocytic tumors of the adrenal gland

No.	Authors	Year	Country	Gender	Age (y)	Side	Size (cm)	Symptoms	Surgery	Classification	Follow-up
1	Ali and Raphael ⁵	2007	Canada	M	25	R	8.5	Hypertension	NA	Malignant	NA
2	Mete and Asa ⁶	2009	Canada	F	72	L	1.4	Hypertension	L	Benign	NA
3	Wong et al ²	2010	Australia	M	22	L	5.5	Asymptomatic	NA	Benign	ANED at 108 months
4	Duregon et al ¹	2011	Italy	F	66	R	5	NA	NA	Benign	NA
5	Duregon et al ¹	2011	Italy	F	40	R	4	NA	NA	Benign	NA
6	Akin et al ¹⁰	2014	Turkey	M	11	R	4.5	Metabolic	L	Benign	NA
7	Alshaheen et al	2022	Bahrain	F	40	L	12.0	Pain and hypertension	L	Borderline	ANED at 14 months

Abbreviations: ANED, alive with no evidence of disease; F, female; L, laparoscopic adrenalectomy; L, left; M, male; NA, not available; R, right.

vascular invasion, and the mitotic activity equaled 2 to 3 per 50 high power fields. Accordingly, this tumor is the first described aldosterone-secreting oncocytoma with borderline potential. Interestingly, the Ki67-score as one of the immunohistochemical tests is considered the single most important factor for predicting the recurrence after R0 resection of adrenocortical carcinoma and it equaled 3% in our case, which is associated with a favorable prognosis.⁴

The tumor presented in this case is the largest aldosterone-secreting oncocytoma described so far. As shown in **Table 1**, five of the seven reported aldosterone-secreting oncocytomas were benign. In their literature review, Wong et al reported three cases of recurrence out of 47 borderline oncocytomas over a median follow-up of 96 months.² Our patient was doing well after 14 months, and further follow-up is planned over the next 5 years.

Conclusion

Adrenal oncocytomas are rare tumors that are usually diagnosed after the surgical resection of an adrenal neoplasm. The histological diagnosis requires the differentiation of these tumors from adrenal adenomas. Based on the major and minor criteria of the modified Lin–Weiss–Bisceglia scoring system, these tumors are classified into benign, borderline, or malignant. As in other adrenal tumors, laparoscopic adrenalectomy is feasible for large oncocytomas after the exclusion of local invasion in the preoperative imaging.

Patient Consent

Written informed consent was obtained from the patient and is available on request.

Authors' Contributions

K.D. operated on the patient and wrote the first draft. M.A. was involved in the diagnostic work-up and follow-up, collected the clinical data, and edited the manuscript. M.J. examined the specimen and contributed to the pathologic details of the work. M.F.S. researched the documented

cases, organized the figures and tables, and edited the discussion. All authors reviewed and approved the final manuscript before submission.

Funding

None.

Conflict of Interest

None declared.

References

- Duregon E, Volante M, Cappia S, et al. Oncocytic adrenocortical tumors: diagnostic algorithm and mitochondrial DNA profile in 27 cases. *Am J Surg Pathol* 2011;35(12):1882–1893
- Wong DD, Spagnolo DV, Bisceglia M, Havlat M, McCallum D, Platten MA. Oncocytic adrenocortical neoplasms—a clinicopathologic study of 13 new cases emphasizing the importance of their recognition. *Hum Pathol* 2011;42(04):489–499
- Bisceglia M, Ludovico O, Di Mattia A, et al. Adrenocortical oncocytic tumors: report of 10 cases and review of the literature. *Int J Surg Pathol* 2004;12(03):231–243
- Beuschlein F, Weigel J, Saeger W, et al. Major prognostic role of Ki67 in localized adrenocortical carcinoma after complete resection. *J Clin Endocrinol Metab* 2015;100(03):841–849
- Panizzo V, Rubino B, Piozzi GN, et al. Laparoscopic trans-abdominal right adrenalectomy for a large primitive adrenal oncocytic carcinoma: a case report and review of literature. *Am J Case Rep* 2018;19:1096–1102
- Ali AE, Raphael SJ. Functional oncocytic adrenocortical carcinoma. *Endocr Pathol* 2007;18(03):187–189
- Mete O, Asa SL. Aldosterone-producing adrenal cortical adenoma with oncocytic change and cytoplasmic eosinophilic globular inclusions. *Endocr Pathol* 2009;20(03):182–185
- Stowasser M, Gordon RD, Gunasekera TG, et al. High rate of detection of primary aldosteronism, including surgically treatable forms, after 'non-selective' screening of hypertensive patients. *J Hypertens* 2003;21(11):2149–2157
- Li X, Goswami R, Yang S, Li Q. Aldosterone/direct renin concentration ratio as a screening test for primary aldosteronism: a meta-analysis. *J Renin Angiotensin Aldosterone Syst* 2016;17(03):1470320316657450
- Akin M, Erginel B, Tanik C, et al. The first laparoscopic resection of an aldosterone-secreting adrenocortical oncocytoma in a child. *J Pediatr Surg Case Rep* 2014;2(09):424–427