




# An Infant with Persistent Respiratory Failure Associated with Refractory Pulmonary Hypertension: Pulmonary Interstitial Glycogenosis

Gianfranco Tomarelli<sup>1</sup>  Alejandro Donoso<sup>1</sup> Francisca Andrades<sup>2</sup> Soledad Montes<sup>3</sup>

<sup>1</sup>Pediatric Intensive Care Unit, Hospital Clínico Dra. Eloísa Díaz I. La Florida, Santiago, Chile

<sup>2</sup>Department of Pediatrics, Diego Portales University, Santiago, Chile

<sup>3</sup>Department of Pediatric Pulmonology, Hospital Clínico Dra. Eloísa Díaz I, La Florida, Santiago, Chile

Address for correspondence Gianfranco Tomarelli, Pediatric Intensive Care Unit, Hospital Clínico Dra. Eloísa Díaz I., Froilán Roa 6542, Santiago, Chile (e-mail: gtomarelli@hotmail.com).

J Child Sci 2022;12:e108–e111.

## Abstract

### Keywords

- ▶ pulmonary interstitium
- ▶ pulmonary interstitial glycogenosis
- ▶ interstitial lung disease
- ▶ pulmonary hypertension
- ▶ respiratory failure

Pulmonary interstitial glycogenosis (PIG) is a disease of unknown etiology. It is part of the interstitial lung diseases, corresponding to the compartment of the fetal pulmonary interstitium. It typically presents within the first week of life as refractory respiratory distress with tachypnea and persistent hypoxemia, and it is not associated with glycogen deposition in other organs. Usually, there is a clinical improvement and good prognosis after steroid therapy unless there are associated conditions such as congenital heart disease, pulmonary hypertension, or genetic disorders. We report a case diagnosed by lung biopsy at 4 months of age in a male preterm born, small for gestational age infant, who developed refractory hypoxemia and pulmonary hypertension with fatal outcome. There was no response to steroids and hydroxychloroquine. He was not candidate for extracorporeal membrane oxygenation. PIG should be considered in the differential diagnosis of persistent respiratory distress and hypoxemia despite standard treatment, even after the first month of life.

## Introduction

Among the causes of neonatal respiratory distress syndrome, interstitial lung diseases (ILDs) are a heterogeneous group of rare diseases, with a prevalence of 0.36 cases per 100,000 children aged 0 to 16 years.<sup>1</sup> These conditions causes impaired gas exchange and respiratory failure in neonates.

Pulmonary interstitial glycogenosis (PIG) was first reported two decades ago. It is a rare ILD, part of the spectrum of alveolar developmental abnormalities, mainly affecting the fetal pulmonary interstitium, and is the result of numerous and heterogeneous mechanisms.<sup>2,3</sup>

It usually presents as refractory respiratory distress with tachypnea and persistent hypoxemia within the first week of life. In addition, pulmonary hypertension may be present. Computed tomography (CT) findings in isolated PIG are nonspecific but include ground-glass opacities (GGOs) and septal thickening. The diagnosis is confirmed by lung biopsy (gold standard). Patients usually require supportive treatment with oxygen therapy and, in some cases, assisted ventilation.<sup>4,5</sup>

Regarding PIG treatment, it is based on corticosteroid therapy, and it generally has a good prognosis. However, mortality is determined by comorbidities, such as severe

received  
November 23, 2021  
accepted after revision  
June 28, 2022

DOI <https://doi.org/10.1055/s-0042-1757143>.  
ISSN 2474-5871.

© 2022. The Author(s).

This is an open access article published by Thieme under the terms of the Creative Commons Attribution License, permitting unrestricted use, distribution, and reproduction so long as the original work is properly cited. (<https://creativecommons.org/licenses/by/4.0/>)  
Georg Thieme Verlag KG, Rüdigerstraße 14, 70469 Stuttgart, Germany

lung growth abnormalities, complex congenital heart disease, pulmonary hypertension, and associated chromosomal abnormalities.<sup>5,6</sup>

There are reports of patients with PIG and pulmonary hypertension refractory to standard treatment, even in the absence of significant comorbidities such as prematurity and congenital heart disease.<sup>7</sup>

We report a fatal case of a 4-month-old premature patient with acute hypoxemic respiratory failure and refractory pulmonary hypertension with confirmed PIG.

## Case Presentation

A 31-week preterm, small for gestational age, male infant, with birth weight of 1,340 g, without significant perinatal disease, was hospitalized for 1 month in his community general hospital due to prematurity. Nevertheless, 45 days after discharge, he was taken to the emergency room (of the same center) for apnea, loss of muscle tone, and cyanosis. He was promptly transferred to the intensive care unit, where he was intubated and mechanically ventilated due to respiratory failure. A severe cytomegalovirus and *Pneumocystis jirovecii* pneumonia was diagnosed by polymerase chain reaction (PCR) test in the endotracheal aspirate. Echocardiography revealed pulmonary hypertension with shunt due to foramen ovale, minor ventricular septal defect, and exclusively left-to-right shunt through the arterial duct. He received sildenafil and furosemide and required invasive mechanical ventilation (MV) for 15 days.

Regarding the immunological study, cytopenia of T lymphocytes was detected in the lymphocyte subpopulations. Severe combined immunodeficiency and Di George syndrome were ruled out (the latter by multiplex ligation-dependent probe amplification and application of fluorescence in situ hybridization analysis). Therefore, idiopathic T-lymphocytopenia was proposed at that time as a diagnostic possibility.<sup>8</sup>

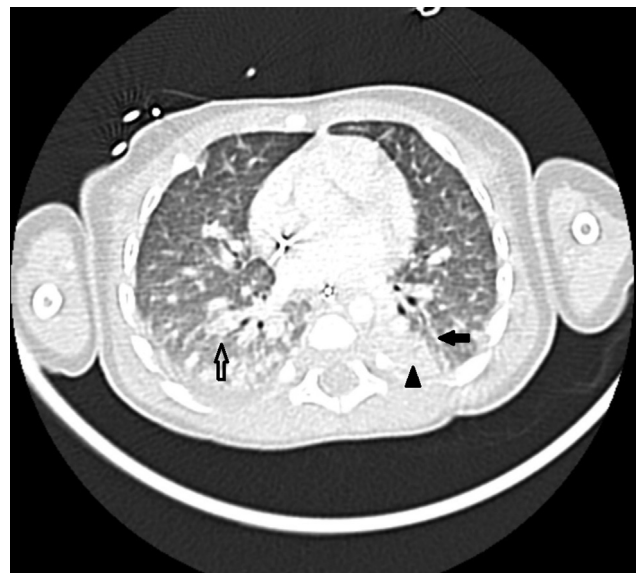After 24 hours of discharge from his second hospitalization, he presented progressive respiratory distress. He was transferred to our center, a tertiary hospital, with a chronological age of 4 months (47 weeks of postmenstrual age). He was admitted to the intensive care unit with a diagnosis of pneumonia. During hospitalization, supplemental oxygen requirements progressively increased, and bilateral consolidations appeared on chest X-rays, requiring invasive MV. An echocardiogram revealed moderate pulmonary hypertension with dilation of the right cavities and partial collapse of the left cavities, interatrial septum bulging toward the left atrium, a 18.5-mm right ventricle diastolic diameter, and hypertrophy of the interventricular septum. The infectious disease workup showed the presence of *Klebsiella pneumoniae* in endotracheal aspirate culture and cytomegalovirus PCR in blood <1,000 copies. Thus, he was treated with amikacin and ganciclovir, with a good response. The rest of the study was negative (blood and urine cultures, mycobacterium PCR of endotracheal aspirate, enzyme-linked immunosorbent assay test for human immunodeficiency virus, *Pneumocystis jirovecii* PCR of endotracheal aspirate, Epstein-

Barr virus serology, and galactomannan in endotracheal aspirate).

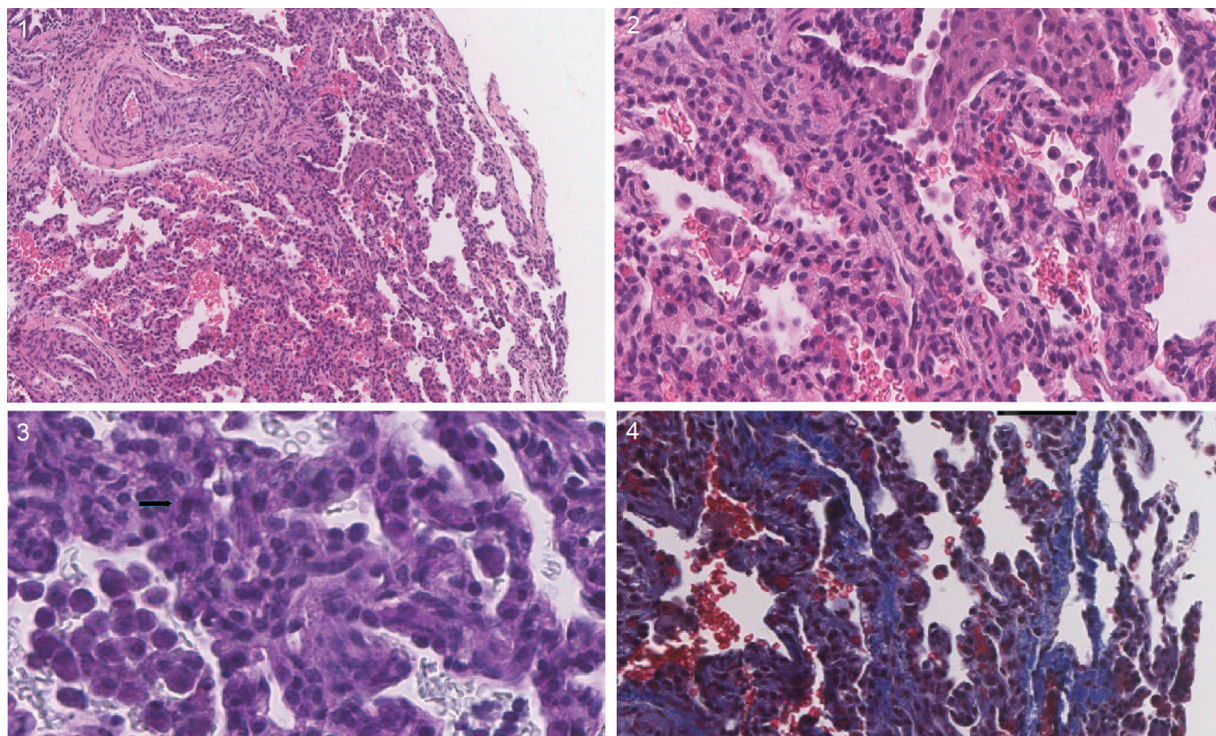
After controlling the infection and completing antimicrobial treatment, he was successfully weaned from MV and extubated. However, he presented respiratory distress and progressive hypoxemia 72 hours after extubation, requiring invasive MV. Infectious disease workup was negative, including blood, urine, and endotracheal aspirate cultures.

A chest CT was performed, which showed diffuse peribronchial interstitial thickening with GGO in the middle third and peribronchial areas, with peripheral bilateral pseudonodules of up to 5 mm (→ Fig. 1). He evolved with suprasystemic pulmonary hypertension and refractory hypoxemia, requiring prone positioning, and inhaled nitric oxide (iNO) was initiated at 20 ppm. ILD diagnostic studies were done, considering patient history with prolonged, recurrent, and unexpectedly severe respiratory failure with prolonged dependence on MV and CT scan findings. Genetic studies for ILD or surfactant disorders were not performed. A lung wedge biopsy of the right lower lobe was done at day of life 140, showing lung tissue with thickening of the interstitial wall at the expense of mononuclear cells. Some of these cells had periodic acid-Schiff (PAS) stain positive intracytoplasmic granular particles (glycogen). Focal collagen fibrosis and thickening of the arterial wall were also observed; finally, the findings were consistent with PIG (→ Fig. 2).

Systemic methylprednisolone of 10 mg/kg/d for 5 days was started, achieving a partial and transient response with an improvement of hypoxemia and pulmonary hypertension. Unfortunately, the patient developed refractory hypoxemia again, and interstitial infiltrates on chest radiography in the following days. New echocardiography showed biventricular hypertrophic cardiomyopathy without systemic hypertension (right ventricular end-diastolic diameter of



**Fig. 1** Chest computed tomography showing atelectasis in the dorsal segments of the lungs (arrowhead) and signs of global interstitial septae thickening (black arrow) with bilateral peribronchial and peripheral alveolar filling foci associated with areas of ground-glass opacifications (white arrow).



**Fig. 2** Histological sections from lung wedge biopsy shows (1) thickened alveolar septae. Hematoxylin-eosin (H&E) staining, 10X. (2) Increased amount mononuclear cells in the interstitium. H&E staining, 20X. (3) Some cells with the presence of fine granules periodic acid-Schiff (PAS)-positive. PAS staining, 40X. (4) Partial collagenous fibrosis of the wall. Masson's trichrome staining, 40X.

18.5 mm and left ventricular end-diastolic diameter of 16.8 mm), probably due to steroids. Sildenafil (1 mg/kg/dose, four times a day), iNO (up to 20 ppm for 15 days), and hydroxychloroquine (10 mg/kg/d) were added to the therapy. He developed progressive refractory hypoxemia and pulmonary hypertensive crisis, triggering multiple organ failure and finally death at 47 days of evolution. The patient's parents did not authorize autopsy.

## Discussion

PIG is a rare and idiopathic disease currently classified within the maturational disorders of the interstitial compartment of the fetal lung.<sup>9</sup> It is pointed out that the onset of this anomaly is of mesenchymal origin, specifically at the level of the differentiation of interstitial fibroblasts, which play a critical role in the development and differentiation of type 2 pneumocytes or lipofibroblasts.<sup>10</sup> However, it is not known whether PIG precedes or follows structural developmental defects or if the affected cells contribute to, or are markers of, abnormal development.

In the case reported here, the lateness of its presentation was unusual, beginning to manifest more clearly after the third month of life,<sup>4</sup> as well as the severity and refractoriness of pulmonary hypertension with no response to treatment<sup>2</sup> and its fatal outcome.

Given the previous echocardiographic findings in our patient, with hypertrophy of the interventricular septum, we believe that this may have been caused by corticosteroid therapy.<sup>11</sup>

Regarding the diagnostic process, radiological findings are usually nonspecific. However, chest CT may show segmental or subsegmental atelectasis, irregular (patchy) or diffuse GGOs, and interstitial thickening.<sup>5</sup>

Its definitive diagnosis is confirmed by histological examination, which shows (1) reduced alveolar growth and (2) diffuse or patchy interstitial thickening by poorly differentiated mesenchymal spindle-shaped cells that contain accumulated cytoplasmic glycogen PAS positive in the absence of inflammatory cells.<sup>2</sup> The histopathological pattern in PIG can exist in diffuse or patchy distribution.<sup>3,5,12</sup> If more than half of the interstitial tissue is thickened, the pattern is defined as diffuse, and if less, it is defined as patchy.<sup>12</sup> Interestingly, both phenotypes can be found in lung biopsies of patients independent of gestational age.<sup>3</sup> Therefore, it has been hypothesized that patchy PIG is associated with anatomical abnormal lung development and pulmonary vascular growth corresponding to an early developmental disorder, whereas diffuse PIG could be a late development disorder.<sup>4,5</sup>

There is no consensus regarding the efficacy of systemic corticosteroid therapy for PIG. However, there is some pathophysiological basis. Since there is no inflammation, the mechanism involved would be the promotion of tissue maturation, accelerating the lipofibroblast apoptosis.<sup>13</sup>

Given the negative consequences of corticosteroids on postnatal alveolarization,<sup>14,15</sup> it is not recommended the routine use of high dose corticosteroids for cases in which patchy PIG occurs in the setting of a significant lung growth abnormality. Nonetheless, in patients with more diffuse

histological involvement of PIG and respiratory compromise refractory to best supportive care, a trial of corticosteroids may be warranted.<sup>5</sup>

PIG is usually described as an entity with a good prognosis;<sup>12,16</sup> however, there are some fatal cases reported.<sup>4</sup> The prognosis is less favorable when PIG is associated with comorbidities such as congenital heart disease, pulmonary hypertension, lung lesion, or genetic disorders.

It seems difficult to consider PIG as one of the first diagnostic possibilities in the context of an infant with hypoxemic respiratory failure and pulmonary hypertension.<sup>7</sup> However, prolonged and unexplained respiratory failure associated with disproportionate pulmonary hypertension should raise suspicion of ILD.

Probably the clinical manifestations of this disease in our patient appeared earlier; however, the presence of many comorbidities made the diagnostic process difficult. Furthermore, in this case, the prolongation of MV may have increased lung damage and influenced the final prognosis.

In a young infant with a history of prematurity, the main differential diagnoses of a pulmonary parenchymal condition are infections and bronchopulmonary dysplasia. After his second intubation, viral, bacterial, and fungal infections were ruled out in the presented case. Also, there was no history of supplementary oxygen or ventilation requirements in the first 2 months of life. In this clinical scenario, the next step is to study ILD, which includes diffuse developmental disorders, growth abnormalities, specific conditions of undefined etiology (neuroendocrine cell hyperplasia of infancy and PIG), and surfactant protein disorders.<sup>17</sup>

Due to the rapid deterioration without a clear diagnosis, a lung wedge biopsy was finally performed. However, considering that it is an invasive and risky procedure, its use is reserved for patients with a lung disease without a clear etiology and a poor evolution that require a definitive diagnosis to define prognosis and specific therapies. In this case, lung biopsy confirmed PIG, and also, there were no signs of surfactant proteins disorders (electronic microscopy). Although the treatment in PIG is supportive, an empiric trial with methylprednisolone and later hydroxychloroquine was given, with no improvement.

Finally, ILD should be considered even beyond the neonatal period when respiratory distress and hypoxemia worsen despite standard treatment.

**Conflict of Interest**  
None declared.

## References

- Dinwiddie R, Sharief N, Crawford O. Idiopathic interstitial pneumonitis in children: a national survey in the United Kingdom and Ireland. *Pediatr Pulmonol* 2002;34(01):23–29
- Mallory GB Jr, Spielberg DR, Silva-Carmona M. Pulmonary growth abnormalities as etiologies for pediatric pulmonary hypertension. *Pediatr Pulmonol* 2021;56(03):678–685
- Canakis AM, Cutz E, Manson D, O'Brodovich H. Pulmonary interstitial glycogenosis: a new variant of neonatal interstitial lung disease. *Am J Respir Crit Care Med* 2002;165(11):1557–1565
- Jiskoot-Ermers ME, Antonius TA, Looijen-Salamon MG, Wijnen MH, Loza BF, Heijst AF. Irreversible respiratory failure in a full-term infant with features of pulmonary interstitial glycogenosis as well as bronchopulmonary dysplasia. *AJP Rep* 2015;5(02):e136–e140
- Deutsch GH, Young LR. Pulmonary interstitial glycogenosis: words of caution. *Pediatr Radiol* 2010;40(09):1471–1475
- Alkhorayyef A, Ryerson L, Chan A, Phillipos E, Lacson A, Adatia I. Pulmonary interstitial glycogenosis associated with pulmonary hypertension and hypertrophic cardiomyopathy. *Pediatr Cardiol* 2013;34(02):462–466
- Still GG, Li S, Wilson M, Sammut P. Persistent pulmonary hypertension without underlying cardiac disease as a presentation of pulmonary interstitial glycogenosis. *Fetal Pediatr Pathol* 2018;37(01):22–26
- Vijayakumar S, Viswanathan S, Aghoram R. Idiopathic CD4 lymphocytopenia: current insights. *ImmunoTargets Ther* 2020;9:79–93
- Bush A, Gilbert C, Gregory J, Nicholson AG, Semple T, Pabary R. Interstitial lung disease in infancy. *Early Hum Dev* 2020;150:105186
- Galambos C, Wartchow E, Weinman JP, Abman SH. Pulmonary interstitial glycogenosis cells express mesenchymal stem cell markers. *Eur Respir J* 2020;56(04):2000853
- Dani C, Bertini G, Simone P, Rubaltelli FF. Hypertrophic cardiomyopathy in preterm infants treated with methylprednisolone for bronchopulmonary dysplasia. *Pediatrics* 2006;117(05):1866–1867
- Seidl E, Carlens J, Reu S, et al. Pulmonary interstitial glycogenosis—a systematic analysis of new cases. *Respir Med* 2018;140:11–20
- Deutsch GH, Young LR. Histologic resolution of pulmonary interstitial glycogenosis. *Pediatr Dev Pathol* 2009;12(06):475–480
- Roth-Kleiner M, Berger TM, Gremlich S, et al. Neonatal steroids induce a down-regulation of tenascin-C and elastin and cause a deceleration of the first phase and an acceleration of the second phase of lung alveolarization. *Histochem Cell Biol* 2014;141(01):75–84
- Grier DG, Halliday HL. Effects of glucocorticoids on fetal and neonatal lung development. *Treat Respir Med* 2004;3(05):295–306
- Liptzin DR, Baker CD, Darst JR, et al. Pulmonary interstitial glycogenosis: Diagnostic evaluation and clinical course. *Pediatr Pulmonol* 2018;53(12):1651–1658
- Ferraro VA, Zanconato S, Zamunaro A, Carraro S. Children's Interstitial and Diffuse Lung Diseases (CHILD) in 2020. *Children (Basel)* 2020;7(12):280