Article published online: 2022-09-29

Outcome of Pediatric Anti-N-Methyl-D-Aspartate (NMDA) Receptor Encephalitis in Rural Area of Thailand

Vitchayaporn Emarach Saengow[1] Kasama Bhudhisawasdi[2]

[1] Department of Pediatrics, Maharat Nakhon Ratchasima Hospital, Nakhon Ratchasima, Thailand
[2] Department of Pediatrics. Khon Kaen Hospital, Khon Kaen, Thailand

J Child Sci 2022;12:e112–e116.

Address for correspondence Vitchayaporn Emarach Saengow, MD, Department of Pediatrics, Maharat Nakhon Ratchasima Hospital, Chang Peuk Road, Muang, Nakhon Ratchasima 30000, Thailand (e-mail: vitchayaporn.sa@cpird.in.th).

Abstract

Anti-N-methyl-d-aspartate receptor (NMDAR) encephalitis has a very good outcome; however, there are few reports in developing countries regarding the outcome of pediatric anti-NMDAR encephalitis. We aimed to report the clinical outcome of pediatric anti-NMDAR encephalitis in the rural area of Thailand. This retrospective cohort study recruited children between the age of 1 month and 15 years with the diagnosis of anti-NMDAR encephalitis admitted at Maharat Nakhon Ratchasima Hospital from 1st May 2015 to 31th March 2020. Baseline characteristics and investigation were recorded. The first-line treatment was intravenous pulse methylprednisolone alone, pulse methylprednisolone plus intravenous immune globulin (IVIG), or IVIG alone. The second-line treatment was monthly intravenous cyclophosphamide or azathioprine. The modified Rankin Scale (MRS) was used for evaluation at 1, 3, 6, 12, 18, and 24 months after receiving first-line treatment to determine clinical outcomes. The factors that may affect the outcomes were evaluated. In total, 17 patients were recruited, with the mean age of 8 years, and 76.46% were female. 82.35% of patients developed seizures, and 52.94% turned to status epilepticus. 70.59% received first-line treatment as pulse methylprednisolone plus IVIG. 82.35% received complete follow-up at 12 months. According to MRS score, at first diagnosis 94.12% reported severe disability, at 1 month after receiving treatment, 47.06% improved to moderate–mild disability, and at 6 and 12 months, 40% and 78.57% had complete recovery, respectively. Different types of first-line and second-line treatments did not affect the clinical outcome. Comorbidity of status epilepticus affected MRS. Anti-NMDAR encephalitis has a very good prognosis; prompt diagnosis is necessary. Comorbidity as status epilepticus may affect the clinical outcome.

Keywords
- Anti-NMDAR encephalitis
- Pediatric
- Outcome
- Factors

Introduction

Anti-N-methyl-d-aspartate receptor (NMDAR) encephalitis has emerged as the most common immune encephalitis discovered in 2007.[1–3] The mechanism of anti-NMDAR encephalitis was influenced by antibodies attached to the brain's GluR1 subunit of NMDAR. In particular, these specific antibodies were associated with ovarian teratoma.[1] The symptoms of anti-NMDAR encephalitis are psychiatric symptoms, movement disorder, sleep cycle disturbance,

received
April 13, 2022
accepted after revision
June 28, 2022

DOI https://doi.org/10.1055/s-0042-1757144.
ISSN 2474-5871.

© 2022. The Author(s).
This is an open access article published by Thieme under the terms of the Creative Commons Attribution License, permitting unrestricted use, distribution, and reproduction so long as the original work is properly cited. (https://creativecommons.org/licenses/by/4.0/)
Georg Thieme Verlag KG, Rüdigerstraße 14, 70469 Stuttgart, Germany

autonomic disturbance, and seizure/epilepsy.[1–4] The development of symptoms in children is different from adults as children frequently present with nonpsychotic symptoms such as movement disorder and seizure, while adults have predominating symptoms such as psychosis.[5]

The treatment of anti-NMDAR encephalitis is immunosuppressive drugs. The first-line treatment is intravenous pulse methylprednisolone, intravenous immune globulin (IVIG), or plasmapheresis.[1–5] For those who do not respond to first-line immunosuppressive drugs, the second-line immunosuppressive drugs (cyclophosphamide, Cellcept, and rituximab) are added.[4,5]

The outcome of anti-NMDAR encephalitis is excellent, as 80% of patients showed recovery at 18 months follow-up.[4,5] The associated factors, including intensive care unit (ICU) admission and receiving first-line treatment in a shorter duration, impacted the improvement of functional outcomes.[5] The studies in developing countries in regard to outcome and prognostic factors in pediatric patients are limited, leading to our study to determine the outcome of children with anti-NMDAR encephalitis in the rural area of Thailand.

Method

This is a retrospective/prospective cohort study. After the institutional review board approval (IRB001/2020), we obtained informed consent from the patients' parents as the submitted study was investigational research on human subjects. We recruited pediatric patients younger than 15 years of age with the diagnosis of anti-NMDAR encephalitis who were admitted at the pediatric ward of Maharat Nakhon Ratchasima Hospital from the 1st January 2015 to 31st March 2020. The diagnosis of anti-NMDAR encephalitis was defined by positive serum or cerebrospinal fluid (CSF) IgG antibody. The clinical manifestation and investigation results were recorded. Demographic data such as clinical manifestation, type of first-line medication, duration before receiving first-line treatment, type of second-line treatment, the investigation such as CSF and serum antibody to NMDAR, CSF profile, metabolic investigation, brain magnetic resonance imaging (MRI brain), electroencephalogram (EEG) results, paraneoplastic screening results (screening for ovarian teratoma using ultrasound abdomen or computed tomography [CT] abdomen) were recorded.

The first-line treatment was intravenous pulse methylprednisolone, IVIG, or both intravenous pulse methylprednisolone and IVIG. The second-line treatment was monthly intravenous cyclophosphamide, azathioprine, rituximab, or prednisolone. The severity of the disease and outcome of treatment were determined using the modified Rankin Scale (MRS). The MRS was used for evaluation at first diagnosis and at 1, 3, 6, 12, 18, and 24 months after receiving first-line treatment.

The descriptive data were analyzed using median ± standard deviation and percent. The clinical outcome and factors that might affect the MRS were determined by univariate and multivariate analyses and Fisher exact test. The program stata 10 was used, and the significant p-value was less than 0.05.

Results

Total 17 patients were recruited, between the age of 3 to 13 years and with the mean age of 8 years. Most of patients were female (76.46%). As the first clinical manifestation, 58.82% presented with psychosis and 41.18% presented with new onset seizure. In total, 88.24% of patients had movement disorder (choreoathetosis and orofacial dyskinesia), 82.35% developed seizures, and 52.94% turned to status epilepticus. The summary of clinical manifestation is shown in ►**Fig.1**.

70.59% received first-line treatment as intravenous pulse methylprednisolone and IVIG, and 76.47% received cyclophosphamide as second-line treatment. Most of the patient received first-line treatment within 14 days after the onset of the symptoms. 88.24% of patients had severe symptoms leading to pediatric intensive care unit (PICU) admission. Serum anti-NMDA was positive in 82.35%, while CSF anti-NMDA was positive in 100%. Paraneoplastic screening of 94.12% was negative. Follow-up paraneoplastic screening (CT abdomen) was performed in three cases who clinically did not respond after receiving second-line treatment and had a clinical relapse of disease; one case detected ovarian teratoma at 7 months after receiving first-line treatment and showed no clinical response. Due to the budget constraint, we did not follow up on the titer of the anti-GluR1 antibody, exempting two cases with clinical relapses.

The EEG results identified extreme delta brush (47.05%) which is common EEG finding in anti-NMDAR encephalitis. Most of the MRI brain finding was nonspecific white matter lesion. One case showed a pattern of leukoencephalopathy on MRI brain, and the hypothesis of this finding was drug-induced leukoencephalopathy (patients received metronidazole as the treatment of infectious diarrhea during admission and the abnormal finding disappeared after withdrawing metronidazole). Regarding history of recent infection or coinfection, 58.82% were evaluated using CSF polymerase chain reaction for Herpes simplex virus which gave 100% negative result. There was only one case who had history of mycoplasma pneumoniae infection before the onset of encephalopathy. The demographic data are shown in ►**Table 1**.

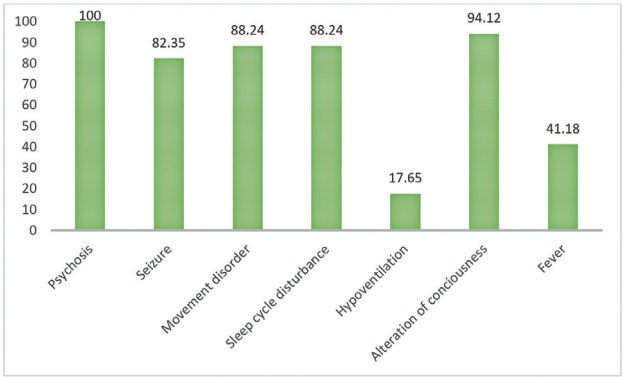

Fig. 1 Clinical manifestation of pediatric anti-NMDAR encephalitis. NMDAR, N-methyl-d-aspartate receptor.

Table 1 Demographic data

	N (%)
Age	
<12 years	14 (82.35)
>12 years	3 (17.65)
Sex	
Male	4 (23.53)
Female	13 (76.47)
Type of first line treatment	
Pulse methylprednisolone	4 (23.53)
Immunoglobulin (IVIG)	1 (5.88)
Pulse methylprednisolone plus IVIG	12 (70.59)
Type of second line treatment	
Intravenous cyclophosphamide	13 (86.67)
Azathioprine	1 (6.67)
None	1 (6.67)
Duration before received first line treatment	
< 14 days	13 (76.47)
> 14 days	4 (23.53)
PICU admission	
Yes	15 (88.24)
No	2 (11.76)
Episode of status epilepticus	
Yes	9 (52.94)
No	8 (47.06)
Serum anti-NMDAR encephalitis	
Positive	14 (82.35)
Negative	3 (17.65)
CSF anti-NMDAR encephalitis	
Positive	17 (100)
Negative	0 (0)
Paraneoplastic screening	
Positive	1 (5.88)
Negative	16 (94.12)
MRI brain	
Normal	7 (41.16)
Abnormal	
- Nonspecific white matter lesion	3 (17.64)
- Leukoencephalopathy	1 (5.89)
- Arachnoid cyst at left temporal lobe	1 (5.89)
Not evaluated	5 (29.42)
EEG	
Delta brush	8 (47.05)
Other abnormalities	
- Generalized slow background	3 (17.65)
- Focal epileptiform discharge	1 (5.88)
Not done	5 (29.42)

Abbreviations: CSF, cerebrospinal fluid; EEG, electroencephalogram; MRI, magnetic resonance imaging; NMDAR, N-methyl-d-aspartate receptor; PICU, pediatric intensive care unit.

82.35% received complete follow-up at 12 months. According to the MRS score, at the first diagnosis 94.12% reported severe disability (MRS 4–5), at 1 month after receiving treatment, 47.06% improved to moderate-mild disability (MRS 2–3), and at 6 and 12 months, 40 and 78.57% had complete recovery (MRS 0) as shown in ►**Fig. 2**, respectively. At 24 months follow-up, there were 10 cases' follow-ups and 9 cases had completely recovered (90%). Three cases (17.6%) of patients developed subsequent epilepsy, but after receiving the complete course of immunosuppressive drug, seizure was controlled and antiseizure medication was tapered off within 6 to 12 months. There was no mortality in our study.

There were two patients (11.7%) with clinical relapse, and the onset of clinical relapse occurred more than 24 months after diagnosis. Both patients were from the nontumor group. The MRS score at the relapsing time was less severe than the first episode of symptom. The second-line treatment in relapsed cases was four doses of rituximab. The clinical outcome improved within 1 month after the diagnosis of clinical relapse and receiving treatment.

Multivariate analysis showed that different types of first-line treatments, duration before receiving first-line treatment, and PICU admission did not affect the clinical outcome. Comorbidity of status epilepticus affected the MRS as shown in ►**Table 2**.

Discussion

Our study reported the clinical outcome of anti-NMDAR encephalitis in children in rural area of Thailand. We reported the female predominant and common age group younger than 12 years. The first clinical manifestation was psychosis and new onset seizure, and most of the patients were nontumorous which is correlated with previous studies.[4–6] The maximum MRS at diagnosis reported severe disability (MRS 5) in most of the patients, and the first-line treatment was intravenous pulse methylprednisolone followed by IVIG in regard to those who clinically did not respond to steroids. The second-line immunosuppressive drug was monthly cyclophosphamide for 6 months.

As most of the patients had severe neurological deficit as the maximum MRS was 5, we noticed the tremendous improvement in MRS at 1 month after receiving first-line immunosuppressive drug. A significant response was noticed 3 months after the treatment where most of the patients showed moderate-to-severe disability. More than

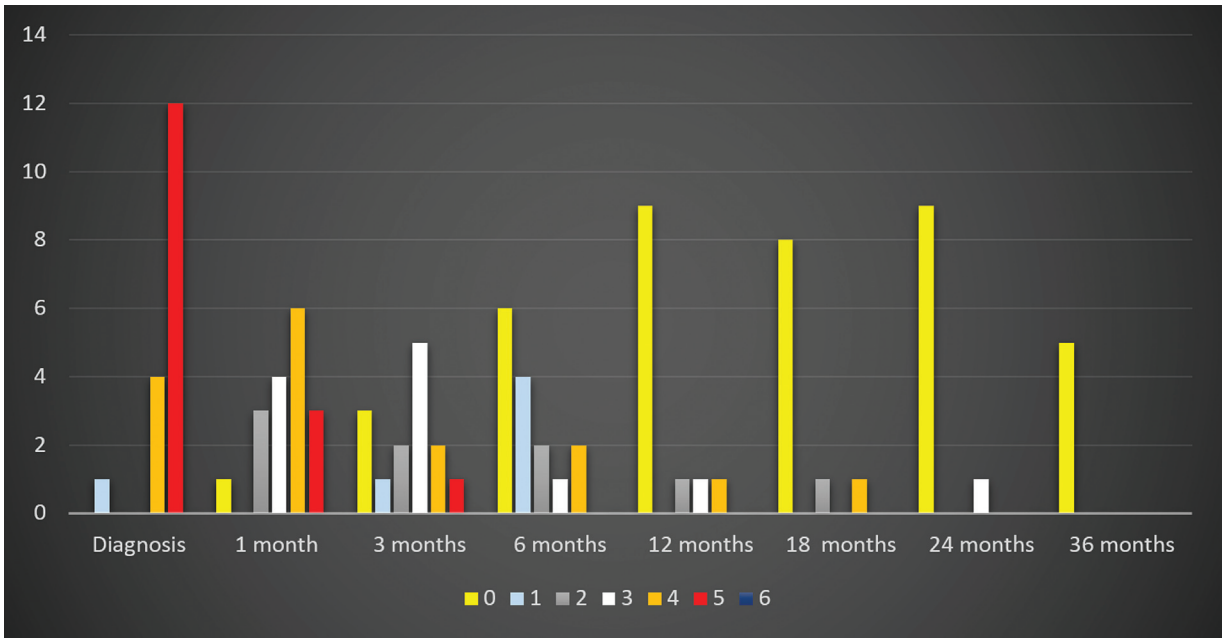

Fig. 2 MRS at diagnosis and follow-up. MRS, modified Rankin Scale.

Table 2 Multivariate analysis

Factor	*p*-Value	OR	95% CI
Episode of status epilepticus	0.01	17.5	1.22–250.35
PICU admission	0.18	1	0.69–7.30
Type of first line treatment	0.054	1	0.97–20.82
Duration before received first line treatment	0.46	2.5	0.19–32.19

Abbreviations: CI, confidence interval; OR, odds ratio; PICU, pediatric intensive care unit.

70% of patients had full recovery at 1 year after receiving first-line treatment. Our result correlates with previous studies that showed the response rate of treatment is 70 to 80% in 2 years and the duration for the response with the improvement in MRS was around 5 weeks in previous studies.[5,6] We found that 81% of the patients had clinical improvements at 12 and 24-month follow-ups, similar to the main findings of Pruetarat et al.[7] This emphasized that anti-NMDAR encephalitis has a very good outcome, so the corrected diagnosis is very important.

We noticed that the types of first-line and second-line immunosuppressive drugs did not affect the MRS and relapsing rate, and the duration before receiving the first-line treatment did not significantly affect MRS as well. These outcomes were different from those of previous studies of Titulaer et al that showed the early received treatment and lack of ICU admission affected clinical improvement.[5,8] The study of Kong et al showed the significant change in MRS in patients who received rituximab and cyclophosphamide as second-line therapy.[9]

Regarding the clinical effect on the outcome, we can conclude that the episodes of status epilepticus affect the change in MRS which is the unique finding in our study. Compared to previous studies, our study showed the factors that may affect MRS such as the presence of hypoventilation and alteration of consciousness. Our study showed that the lack of episodes of status epilepticus may improve the MRS, and this may be explained by the fact that prolonged seizures cause injury to neurons.

Analogous to key findings of previous studies 10–12, two patients, categorized as non-tumor, had clinical relapses with less severe symptoms. We prescribed the rituximab only for the relapsing group due to financial problems. Patients showed significant clinical improvement at 1 month after receiving rituximab. This result correlated with the study of Titulaer et al, and Xu et al showed that the clinical relapsing occurred within 2 years after the first diagnosis with less severity.[5,12]

Conclusions

Anti-NMDAR encephalitis in children has a very good prognosis. Correct diagnosis and crucial treatment are important. Status epilepticus may affect the clinical outcome.

Conflict of Interest

None declared.

References

1 Graus F, Titulaer MJ, Balu R, et al. A clinical approach to diagnosis of autoimmune encephalitis. Lancet Neurol 2016;15(04): 391–404

2 Dalmau J, Tüzün E, Wu HY, et al. Paraneoplastic anti-N-methyl-D-aspartate receptor encephalitis associated with ovarian teratoma. Ann Neurol 2007;61(01):25–36

3 Dalmau J, Gleichman AJ, Hughes EG, et al. Anti-NMDA-receptor encephalitis: case series and analysis of the effects of antibodies. Lancet Neurol 2008;7(12):1091–1098

4 Dalmau J, Lancaster E, Martinez-Hernandez E, Rosenfeld MR, Balice-Gordon R. Clinical experience and laboratory investigations in patients with anti-NMDAR encephalitis. Lancet Neurol 2011;10(01):63–74

5 Titulaer MF, McCracken L, Gabilonda I, et al. Treatment and prognostic factors for long-term outcome in patients with anti-N-methyl-D-aspartate (NMDA) receptor encephalitis: a cohort study. Lancet Neurol 2013;12(02):157–165

6 Florance NR, Davis RL, Lam C, et al. Anti-N-methyl-D-aspartate receptor (NMDAR) encephalitis in children and adolescents. Ann Neurol 2009;66(01):11–18

7 Pruetarat N, Netbaramee W, Pattharathitikul S, Veeravigrom M. Clinical manifestations, treatment outcomes, and prognostic factors of pediatric anti-NMDAR encephalitis in tertiary care hospitals: a multicenter retrospective/prospective cohort study. Brain Dev 2019;41(05):436–442

8 Broadley J, Seneviratne U, Beech P, et al. Prognosticating autoimmune encephalitis: a systematic review. J Autoimmun 2019;96:24–34

9 Kong SS, Chen YJ, Su IC, et al; CHEESE Study Group. Immunotherapy for anti-NMDA receptor encephalitis: experience from a single center in Taiwan. Pediatr Neonatol 2019;60(04):417–422

10 Zhang L, Wu MQ, Hao ZL, et al. Clinical characteristics, treatments, and outcomes of patients with anti-N-methyl-d-aspartate receptor encephalitis: a systematic review of reported cases. Epilepsy Behav 2017;68:57–65

11 Saraya AW, Worachotsueptrakun K, Vutipongsatorn K, Sonpee C, Hemachudha T. Differences and diversity of autoimmune encephalitis in 77 cases from a single tertiary care center. BMC Neurol 2019;19(01):273

12 Xu X, Lu Q, Huang Y, et al. Anti-NMDAR encephalitis: a single-center, longitudinal study in China. Neurol Neuroimmunol Neuroinflamm 2019;7(01):633