



Subxiphoid Mediastinoscopic Autonomous Double Fenestration

Claudiu-Eduard Nistor^{1,2} Anca Pati Cucu¹ Camelia Gavan¹ Adrian Ciuche^{1,2}

¹Thoracic Surgery Clinic, Spitalul Universitar de Urgență Militar Central Dr Carol Davila, Bucuresti, Romania

²Cardio-Thoracic Pathology, Carol Davila University of Medicine and Pharmacy Faculty of General Medicine, Bucuresti, Romania

Address for correspondence Anca Pati Cucu, MD, Thoracic Surgery Clinic, Spitalul Universitar de Urgenta Militar Central Dr Carol Davila, 134 Calea Plevnei, 1st District Bucuresti 010825, Romania (e-mail: ancutapati@gmail.com).

Thorac Cardiovasc Surg 2023;71:76–78.

Abstract

Keywords

- ▶ pleuropericardial effusion
- ▶ subxiphoid mediastinoscopic approach
- ▶ autonomous double fenestration

The coexistence of pleural and pericardial effusions in frail patients with or without confirmed neoplasia necessitates the use of a minimally invasive technique that has a minor impact on the patient's general status and allows for fast fluid evacuation and biopsy sampling if necessary. We present a subxiphoid mediastinoscopic autonomous (simultaneous noncommunicating) double fenestration approach for these patients with both diagnostic and therapeutic advantages in selected cases. Using the mediastinoscope alone through the subxiphoid incision can considerably reduce the duration of operation, allow for fluid evacuation, and significantly alleviate the patient's symptoms. This method enables the sampling of pleural and pericardial fluids and targeted tissue, if necessary.

Introduction

Malignant pleural and pericardial effusions (MPPEs) represent a complication in the evolution of many cancers and might become a therapeutic emergency.^{1–3} There is insufficient data in the literature regarding the epidemiology of malignant pleuropericarditis, with most studies focusing on each entity separately.⁴ Malignant pericardial effusions have some risk of recurrence, while malignant pleural effusion generally occurs in advanced-stage cancer and indicates a poor prognosis.⁵ In compromised patients with pleuropericardial effusions, there is an increased pressure caused by the pleural and pericardial effusion on the lung parenchyma and the heart. In such cases, due to subsequent hypodiastolia, selective orotracheal intubation is almost impossible; therefore, a supine positioning of the patient and nonselective intubation are preferred.⁴ The management of these individuals would require a less minimally invasive technique than video-assisted thoracic surgery (VATS), with a shorter dura-

tion, addressing both cavities (pleural and pericardial), allowing for metastases sampling, and, in certain situations, talc poudrage.

Surgical Technique

The technique was performed in patients without a history of pleurodesis/pericardiodesis and with echocardiographic signs of moderate right ventricular collapse and clinical manifestations of tachycardia and orthopnea.

A 3-cm median subxiphoid incision under general anesthesia with nonselective endotracheal intubation was made (▶ Fig. 1A). After mobilization of the rectus abdominis sheath and linea alba from the xiphoid followed by resection of the xiphoid process, the sternum was retracted upward, and pericardial fat was reached. In most cases, the pericardial fat was mobilized, but it was resected when excessive pericardial fat blocked the mediastinoscope's field of view. The sternal retraction was temporarily achieved by

received

May 10, 2022

accepted after revision

August 15, 2022

article published online

October 10, 2022

DOI <https://doi.org/>

10.1055/s-0042-1757177.

ISSN 0171-6425.

© 2022. The Author(s).

This is an open access article published by Thieme under the terms of the Creative Commons Attribution-NonDerivative-NonCommercial-License, permitting copying and reproduction so long as the original work is given appropriate credit. Contents may not be used for commercial purposes, or adapted, remixed, transformed or built upon. (<https://creativecommons.org/licenses/by-nc-nd/4.0/>)

Georg Thieme Verlag KG, Rüdigerstraße 14, 70469 Stuttgart, Germany

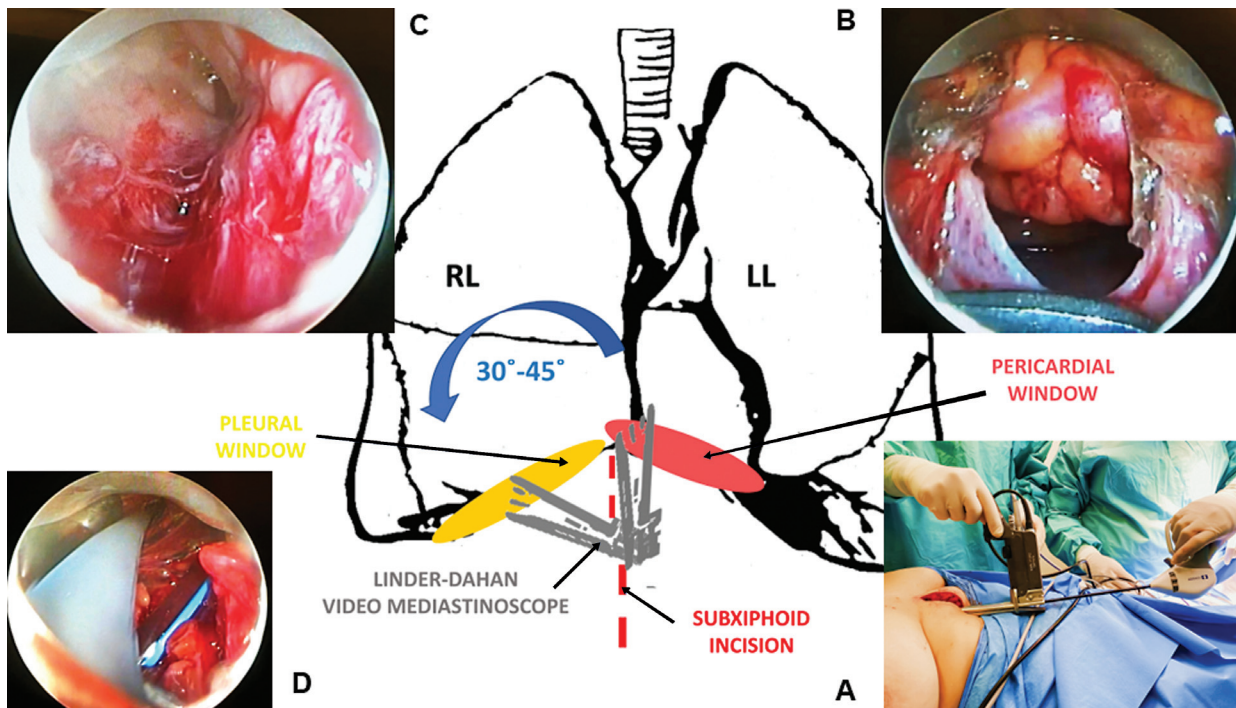


Fig. 1 (A) Using a 3-cm subxiphoid incision, the LigaSure Maryland Jaw Laparoscopic Sealer/Divider is inserted through the working channel of the mediastinoscope. (B) Pericardial window. (C) Pleural window. (D) Separate pleural and pericardial drainage tubes inserted through the unique subxiphoid incision.

the secondary surgeon until the insertion of the mediastinoscope, which acted itself as a retractor.

Under video-mediastinoscopic control, the distended pericardium was initially notched with a hook monopolar and, after the slow, controlled, partial fluid evacuation, was divided with LigaSure Maryland Jaw Laparoscopic Sealer/Divider (→**Fig. 1A**) inserted through the working channel of the mediastinoscope; thus, a 2 cm² pericardectomy was created (→**Fig. 1B**). After the pericardial cavity was entered and visualized with the mediastinoscope, the fluid was progressively evacuated, and pericardial biopsies were performed under visual control.

By retracting and changing the angle of the mediastinoscope by 45 degrees to the left of the surgeon, the right anterior pleural recess was identified, the mediastinal pleura was sectioned with the LigaSure device, the pleural fluid was progressively evacuated, and a pleural window, independent of the pericardial one, was created (→**Fig. 1C**).

Targeted pleural biopsies were performed and two 24-Fr chest tubes were brought out via the subxiphoid incision through each window, each tube entering one of the open cavities through the corresponding window (→**Fig. 1D**).

Discussion

A reduction in hospitalization time, prevention of recurrence, and improved quality of life are the goals of palliative therapy for patients with MPPE,⁶ but, in the absence of a standard common approach,² the treatment options are being customized according to general functional status, the amount and rate of fluid accumulation, recurrence, and prognosis.⁷

Various drainage options have been used,^{1,7-10} but the usual approach for concomitant pleural and pericardial effusions implies the creation of a pericardiopleural window (pleural cavity accessed via pericardial cavity) or pleuro-pericardial window (pericardial cavity accessed via pleural cavity). So far, subxiphoid mediastinoscopic pericardial window and VATS pericardial window has been described in the literature. However, we could not find any reference for a subxiphoid mediastinoscopic pleural window,^{11,12} nor subxiphoid mediastinoscopic autonomous (noncommunicating simultaneous) pericardial and pleural windows.

Since 1959, when Carlens designed and used the mediastinoscope for the first time, this instrument has become widely used, entering the mediastinum by either supra-sternal notch, parasternal, or subxiphoid incision,¹¹⁻¹³ and almost 60 years later, it is still a handy tool that can be used instead of classic thoracoscopy.

The subxiphoid mediastinoscopic approach for pericardial effusions described by Santos and Frater in 1977 has become an everyday procedure, allowing for both fluid evacuation and biopsy sampling.

Most MPPE patients have respiratory and circulatory symptoms secondary to respiratory restriction, decreased venous return, and, sometimes, low cardiac output syndrome with or without cardiac tamponade. According to the literature, the most used approach is VATS pleuropericardial window performed under general anesthesia, associated with pleural and pericardial biopsy and chemical pleurodesis and pericardiodesis with a sclerosing agent. This intervention can be completed in hemodynamically stable cardiorespiratory patients who can tolerate general

anesthesia with single-lung ventilation. Still, in critically ill patients with altered functional status, subxiphoid pericardial drainage, usually performed under local anesthesia, remains the method of choice.

The decision for the median subxiphoid incision is rather a personal one, the left paraxiphoid approach being an alternative that can be considered.

The advantages of the median subxiphoid incision include a simultaneous approach and better visualization of both serous cavities, including the anterior pleural recesses, avoidance of phrenic nerve injury, avoidance of repetitive thoracic surgery, intercostal nerve damage, intercostal chest tube drainage, while preserving the possibility of visually controlled biopsy. With the removal of the xiphoid process, enhanced visualization of the bilateral anterior pleural recesses and the superior part of the dome of the diaphragm are possible. Also, in extreme situations such as cardiac perforation during pericardial notching, sternotomy might be performed immediately, as the patient is already positioned appropriately.

The Linder/Hurtgen Distending DCI video mediastinoscope with its spreadable blades allows for enhanced visibility and easy manipulation of the endoscopic instruments, and merely by changing its direction, access to the mediastinal pleura and pleural cavity. The mediastinoscope has two major advantages: a built-in camera and its blades, which act like a retractor. When we thought of this procedure, we also considered the lack of consumables such as Alexis retractor in some hospitals. Concerning the possible visual impairment due to the small size of the mediastinoscope, the targeted areas are within the safe visual limit of the camera (pleural carcinomatosis is usually located in the inferior parietal pleura). The LigaSure sealer/divider enables efficient bleeding control and the creation of an enlarged pericardiectomy, thus decreasing the recurrence risk.

The possibility of targeted biopsy sampling was evaluated during the first surgical procedures. The pathology reports confirmed or reconfirmed the malignancy diagnosis upon the case.

This approach is indicated in patients with a history of VATS pleuropericardial fenestration, who cannot tolerate selective anesthesia, and who require a fluid evacuation and biopsy procedure. It is useful in recurrent pleuropericarditis. It can also be used in hemodynamically compromised patients in whom a pericardial catheter can be inserted in the operating room to slowly partially decompress the pericardium, allowing general anesthesia and surgery to proceed, without changing the patient's position on the operating table.

This technique has limitations: unavailability of selective intubation makes the visualization of the pleural cavity difficult, the xiphoid process can be an obstacle while approaching the pericardial cavity and the length of the mediastinoscope does not permit a comprehensive inspection of the pleural cavity. Lung cancer patients presenting with simultaneous pleural and pericardial effusion are, in most cases, underweight or with average weight due to their advanced stage. Still, this approach is not recommended in obese patients and in those with a history of sternotomy or operated gastric ulcer by subxiphoid approach. The left

pleural approach is almost impossible to perform in patients with dilated cardiomyopathy. Also, the procedure is probably unsuitable if the pericardial fluid cannot be visualized by ultrasound from the subxiphoid view.

This procedure is recommended for selected patients and is not mandatory in all cases with malignant pleuropericarditis.

Informed Consent Statement

Written informed consent has been obtained from the patients to publish this paper.

Conflict of Interest

None declared.

Institutional Review Board Statement

The study was approved by the Institutional Review Board of "Dr. Carol Davila" Central University Emergency Military Hospital Bucharest (protocol code: 390/09.06.2020).

References

- Adler Y, Charron P, Imazio M, et al; Società Europea di Cardiologia Task Force for the Diagnosis and Management of Pericardial Diseases of the European Society of Cardiology (ESC) 2015 ESC Guidelines for the diagnosis and management of pericardial diseases [in Italian]. *G Ital Cardiol (Rome)* 2015; 16(12):702–738
- Imazio M. Noninfectious pericarditis: management challenges for cardiologists. *Kardiol Pol* 2020;78(05):396–403
- Ciuche A, Nistor C, Motaş C, Horvat T. Chirurgia miniinvasivă în tratamentul pleuro-pericarditelor maligne. [Minimally invasive surgery in the treatment of malignant pleuro-pericardial effusions] *Chirurgia (Bucur)* 2012;107(02):206–212
- Nistor C-E, Găvan CS, Ciritel A-A, Nemes AF, Ciuche A. The association of minimally invasive surgical approaches and mortality in patients with malignant pleuropericarditis—a 10 year retrospective observational study. *Medicina (Kaunas)* 2022;58(06):718
- Nistor CI, Ranetti AE, Ciuche A, Pantile D, Constantin LM, Brincoveanu R. Betadine® in chemical pleurodesis. *Farmacia* 2014;62(05):897–906
- Ricciardi S, Jaus MO, Cardillo G. Possibilities of surgical pleurodesis for malignant pleural effusion. *AME Med J* 2020;5:20
- Koegelenberg CFN, Shaw JA, Irusen EM, Lee YCG. Contemporary best practice in the management of malignant pleural effusion. *Ther Adv Respir Dis* 2018;12:1753466618785098
- Porcel JM, Lui MM, Lerner AD, Davies HE, Feller-Kopman D, Lee YC. Comparing approaches to the management of malignant pleural effusions. *Expert Rev Respir Med* 2017;11(04):273–284
- Barone A, Priolella M, Cipollone G, Nuzzo D, Camplese P, Mucilli F. Surgical management of cardiac tamponade: is left anterior minithoracotomy really safe and effective? *J Emerg Pract Trauma* 2017;3(02):53–58
- Nistor C, Ciuche A, Davidescu M, Horvat T. Pleurotomy—an operation by the general surgeon [in Romanian]. *Chirurgia (Bucur)* 2009;104(03):323–328
- Carlens EA. Author. Mediastinoscopy: a method for inspection and tissue biopsy in the superior mediastinum. *Dis Chest* 1959; 36:343–352
- Mack MJ, Landreneau RJ, Hazelrigg SR, Acuff TE. Video thoracoscopic management of benign and malignant pericardial effusions. *Chest* 1993;103(4, Suppl):390S–393S
- Santos GH, Frater RW. The subxiphoid approach in the treatment of pericardial effusion. *Ann Thorac Surg* 1977;23(05):467–470