



Two Case Reports of *Ochrobactrum anthropi* Bacteremia: An Overlooked Pathogen

Aravinda Anjana¹ Ranjeeta Adhikary¹ Malavalli Venkatesh Bhavana¹ Hosdurg Bhaskar Beena¹

¹Department of Lab Medicine, Manipal Hospital, Bangalore, Karnataka, India

Address for correspondence Aravinda Anjana, MD, Department of Lab Medicine, Manipal Hospital, Bangalore, Karnataka 560017, India (e-mail: anjoo.prabhu@gmail.com).

J Lab Physicians 2023;15:166–168.

Abstract

Ochrobactrum anthropi, due to its robust survival abilities, has been known to cause nosocomial and opportunistic infections, posing both diagnostic and therapeutic challenges. Low virulence, indolent clinical presentation, and lack of awareness on their clinical significance attribute to the underreporting of the same. We report two cases of bacteremia in oncology patients presented to us in a short span of 6 months, which indicates that such infections might be quite common in immunocompromised hosts. Both our strains were susceptible to carbapenems, trimethoprim/sulfamethoxazole, and minocycline, and recovered with monotherapy. More vigilant and accurate diagnostic techniques need to be followed not to miss such pathogens. Early identification and administration of appropriate antibiotics have been associated with a good outcome.

Keywords

- ▶ *Ochrobactrum anthropi*
- ▶ bacteremia
- ▶ oncology
- ▶ immunocompromised

Introduction

Ochrobactrum anthropi (OA) is been increasingly recognized as an opportunistic and nosocomial pathogen since the last decade. It is an aerobic Gram-negative bacterium which is known for its ubiquitous nature.¹ Its robust survival ability even in antiseptic solutions and invasive medical devices in addition to biofilm producing property attributes to the increased incidences of hospital-acquired infections.² Because of its low virulent nature, it has been considered to cause invasive infections mostly in immunocompromised hosts. More worrisome is its resistance to the commonly used β -lactam group of antibiotics like penicillins and cephalosporins.^{1,3} Sporadic reporting of *Ochrobactrum* species with limited literature mainly accounts to its underreporting due to lack of awareness of its clinical significance.

We hereby report two culture-proven cases of OA bacteremia in oncology patients presented to us in a short span of 6 months. We would like to highlight the fact that it cannot be

considered a rare pathogen anymore. More effective and vigilant diagnostic techniques need to be followed not to miss such pathogens.

Case 1

An 18-year-old girl who was a known case of acute lymphoblastic leukemia undergoing treatment for the same, presented to us with complaints of fever. Clinical examination showed poor general condition with severe pallor. She was febrile without lymphadenopathy or organomegaly. Chest X-ray was normal. She was admitted for further fever workup. Her hematology profile revealed anemia with hemoglobin level of 7.2 g %, total leukocyte count (TLC) 560/mm³, differential leucocyte count (DLC): N 54, L 30, E 00, and M 16, and a reduced platelet count of 36,000/mm³. Urine analysis was normal.

Blood was collected and sent in Bact/ALERT bottle (BioMérieux) for microbiological workup. It flashed positive

article published online
October 20, 2022

DOI <https://doi.org/10.1055/s-0042-1757235>.
ISSN 0974-2727.

© 2022. The Indian Association of Laboratory Physicians. All rights reserved.

This is an open access article published by Thieme under the terms of the Creative Commons Attribution-NonDerivative-NonCommercial-License, permitting copying and reproduction so long as the original work is given appropriate credit. Contents may not be used for commercial purposes, or adapted, remixed, transformed or built upon. (<https://creativecommons.org/licenses/by-nc-nd/4.0/>)

Thieme Medical and Scientific Publishers Pvt. Ltd., A-12, 2nd Floor, Sector 2, Noida-201301 UP, India

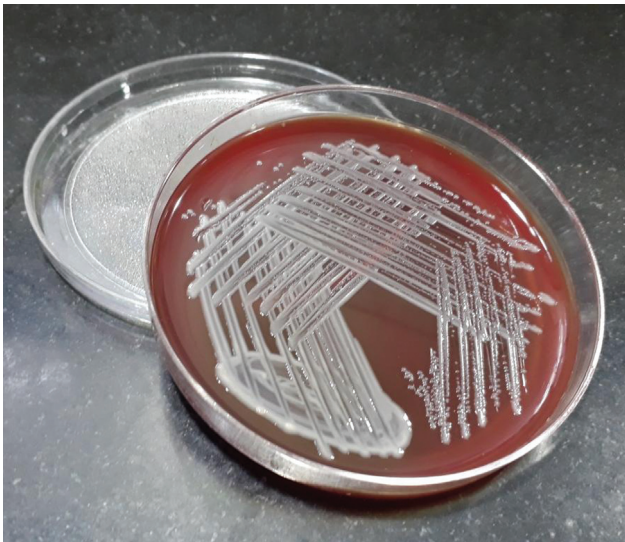


Fig. 1 Growth on blood agar.

within 24 hours of incubation. Subculture from the bottle on to 5% sheep blood agar and MacConkey agar grew nonlactose fermenting colonies as shown in ►Figs. 1 and 2. They were Gram-negative bacilli, motile, oxidase, and catalase positive, indole negative, and urease positive. Phenotypic and antimicrobial susceptibility testing (AST) by automated VITEK-2 identification system (BioMérieux, France) further identified it as OA with 99% probability. The minimum inhibitory concentration (MIC) values and the interpretations are summarized in ►Table 1. The AST for the same was reported following the Clinical and Laboratory Standards Institute 2021 MIC breakpoint guidelines for “other non-enterobacterales.”⁴

Accordingly, the patient was started on meropenem along with other supportive management. The patient became afebrile and was discharged. A fresh blood culture sample collected during her follow-up visit showed no growth of bacteria after 5 days of incubation.

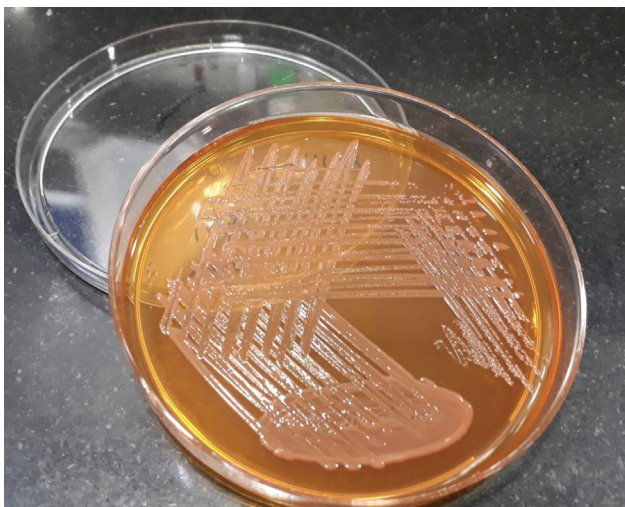


Fig. 2 Growth on MacConkey agar.

Case 2

A 28-year-old male, a known case of B-cell non-Hodgkin lymphoma who was admitted for his chemotherapy developed high grade fever on day 1. Laboratory parameters workup showed hemoglobin 14.3 g%, TLC 6,440/mm³, and DLC: N 60, L 26, E 3.4, M 11, B 0.5, and a platelet count of 391,000/mm³. Liver function test was normal.

BacT/ALERT blood culture bottle for microbiological workup grew nonlactose fermenting Gram-negative bacteria. It was motile, oxidase, and catalase positive, indole negative, and urease positive. Automated identification and AST with VITEK-2 identification system (BioMérieux, France) identified it as OA, the AST pattern of which is summarized in ►Table 1. The patient was started on trimethoprim/sulfamethoxazole and symptomatically recovered.

Discussion

Opportunistic infections (OIs) are defined as infections occurring due to bacteria, fungi, viruses, or parasites that normally do not cause a disease, but become pathogenic in impaired defense system.⁵ In such infections, pathogens take advantage of a host with a weakened immune system and/or with an altered microbiota. *Ochrobactrum* species has been considered as an emerging OI only since last decade but still not included in the “common” OI and hence likely to be underdiagnosed and underreported. In this study, we are reporting two such cases presented to us in the same year within a time span of 6 months. Environmental sampling as a part of infection control protocol of the hospital did not grow OA in any given niches.

Though *Ochrobactrum* species is frequently encountered in immunocompromised patients, there are infections being reported in previously healthy individuals also. These include cases of sepsis, endophthalmitis, osteomyelitis, pelvic abscess, necrotizing fasciitis, etc. Vaidya et al, in their review study on such cases have suggested that the spectrum of disease caused by this organism is wide and the demonstration of its presence cannot be underestimated even in immunocompetent individuals.⁶

The major diagnostic challenge faced is the nonreliable result in the correct identification and differentiation from brucellae using routine biochemical test systems, due to their high phenotypic similarity.³ Automation is the key in clinical microbiology which facilitates rapid and correct identification of such unusual pathogen which are likely to be missed by conventional methods.⁷ In addition, the therapeutic challenge being its frequent non response to standard empiric antimicrobial therapy due to the AmpC β-lactamase production.⁸ Thoma et al, in their study on 103 isolates showed that *Ochrobactrum* strains were highly resistant to β-lactam antibiotics, susceptible to ciprofloxacin, and 97.1% were susceptible to trimethoprim/sulfamethoxazole.⁴ Similarly, Zhu et al, in their 7-year study on OA blood stream infections recommended monotherapy with quinolones or carbapenems or both to be used in adverse patient conditions. They concluded that removing the catheter was not always necessary.⁹ The

Table 1 MIC values and the interpretations of the OA isolates

Antibiotic	Case 1	Case 2
	MIC values (Interpretation)	MIC values (Interpretation)
Gentamicin	≥ 16 (R)	≥ 16 (R)
Amikacin	16 (S)	≥ 64 (R)
Ciprofloxacin	≥ 4 (R)	0.25 (S)
Levofloxacin	4 (R)	0.25 (S)
Trimethoprim/sulfamethoxazole	≤ 20 (S)	≤ 20 (S)
Minocycline	≤ 1 (S)	≤ 0.5 (S)
Imipenem	≤ 0.25 (S)	1 (S)
Meropenem	0.5 (S)	1 (S)
Piperacillin-tazobactam	≤ 4 (S)	≥ 128 (R)
Cefoperazone-sulbactam	≤ 8 (S)	≥ 64 (R)

Abbreviations: MIC, minimum inhibitory concentration; OA, *Ochrobactrum anthropi*; R, resistant; S, susceptible.

available few Indian studies also found their OA isolates to be sensitive to carbapenem and quinolones.^{7,10} In our study, both the isolates were susceptible to carbapenems, trimethoprim/sulfamethoxazole, and minocycline and recovered with monotherapy. However, only one of the isolates was sensitive to the quinolone group of antibiotics.

The findings of the present study indicate that OA infections might be quite common in immunocompromised hosts. We would like to stress that there are high chances of missing out such unconventional pathogens in the routine microbiological reporting due to lack of awareness on its clinical significance and also due to inaccurate diagnostic techniques. This in turn is attributing to the sporadic case reports of the same. Early identification and administration of appropriate antibiotics is associated with good outcome.

Conflict of Interest

None declared.

References

- Kettaneh A, Weill F-X, Poilane I, et al. Septic shock caused by *Ochrobactrum anthropi* in an otherwise healthy host. *J Clin Microbiol* 2003;41(03):1339–1341
- Khan D, Mukherjee T, Gupta S, et al. *Ochrobactrum anthropi* sepsis in intensive tertiary care. *J Basic Clin Med* 2014;3(01):18–20
- Thoma B, Straube E, Scholz HC, et al. Identification and antimicrobial susceptibilities of *Ochrobactrum* spp. *Int J Med Microbiol* 2009;299(03):209–220
- CLSI Performance Standards for Antimicrobial Susceptibility Testing 31st ed. CLSI supplement M100. Clinical and Laboratory Standards Institute; 2021
- CDC Opportunistic Infections definition. Accessed July 14, 2022 at: <https://www.cdc.gov/hiv/basics/livingwithhiv/opportunistic-infections.html>
- Vaidya SA, Citron DM, Fine MB, Murakami G, Goldstein EJ. Pelvic abscess due to *Ochrobactrum intermedium* [corrected] in an immunocompetent host: case report and review of the literature. *J Clin Microbiol* 2006;44(03):1184–1186
- Gupta A, Chauhan K, Pandey A. Neonatal Septicaemia by *Ochrobactrum anthropi*: a missed pathogen. *Int J Curr Microbiol Appl Sci* 2018;7(05):1651–1654
- Cieslak TJ, Robb ML, Drabick CJ, Fischer GW. Catheter-associated sepsis caused by *Ochrobactrum anthropi*: report of a case and review of related nonfermentative bacteria. *Clin Infect Dis* 1992;14(04):902–907
- Zhu M, Zhao X, Zhu Q, et al. Clinical characteristics of patients with *Ochrobactrum anthropi* bloodstream infection in a Chinese tertiary-care hospital: a 7-year study. *J Infect Public Health* 2018;11(06):873–877
- Arora U, Kaur S, Devi P. *Ochrobactrum anthropi* septicaemia. *Indian J Med Microbiol* 2008;26(01):81–83