






Letter: Abdominal *Mycobacterium avium-intracellulare* Infection—A Series in Immunocompromised and Port Site Infections

Anuraag Jena¹  Kusum Sharma² Anupam Singh¹  Harjeet Singh³ Vishal Sharma¹ 

¹ Department of Gastroenterology, Postgraduate Institute of Medical Education & Research, Chandigarh, India

² Department of Microbiology, Postgraduate Institute of Medical Education & Research, Chandigarh, India

³ Department of Surgical Gastroenterology, Postgraduate Institute of Medical Education & Research, Chandigarh, India

Address for correspondence Vishal Sharma, MD, DM, Department of Gastroenterology, Postgraduate Institute of Medical Education & Research, Chandigarh 160012, India (e-mail: sharma.vishal@pgimer.edu.in).

J Gastrointest Infect 2023;13:103–104.

Nontuberculous mycobacteria (NTM) or atypical mycobacteria are a group of around 200 species that may cause human disease in certain specific situations like human immunodeficiency virus (HIV), immunodeficiency or certain specific clinical situations.^{1–3} We report about three cases we encountered recently, one in the setting of HIV infection and two as port site infections.

A 35-year-old man, recently diagnosed to have HIV infection and initiated on anti-retroviral therapy, presented with abdominal pain, generalized weakness, and loss of weight for the last 2 months. He had received four drug antitubercular therapy for sputum-positive pulmonary tuberculosis 5 years back. On abdominal ultrasound, a lymph nodal mass was seen and fine-needle aspiration (FNA) revealed granulomas with multiple acid-fast bacilli (AFB). Sputum AFB was positive. He had been started on five drug antitubercular therapy (isoniazid, rifampin, pyrazinamide, ethambutol, and streptomycin). After 2 months of treatment, patient's condition had worsened with further loss of weight and progressive weakness. Abdominal examination confirmed the presence of a lump. Computed tomography (CT) confirmed the presence of an abdominal mass that was encasing the superior mesenteric artery and vein with retroperitoneal lymphadenopathy (→ Fig. 1A). FNA was repeated that revealed multiple AFB with foamy macrophages. The Gene-Xpert for *Mtb/Rif* was negative both from sputum and FNA material. Laboratory investigations included CD 4 count of 36/mm³, normocytic normochromic anemia (80 g/L), with normal leukocyte

and platelet count. In view of presence of AFB, foamy macrophages with negative Gene-Xpert in the setting of HIV infection and worsening on five-drug regimen, he was started on therapy for disseminated *Mycobacterium avium* complex (MAC) infection. He was started on clarithromycin, rifampicin, and ethambutol. Patient was followed up clinically on second and fourth week and thereafter monthly. At 1 month, Ziehl–Neelsen stain done on sputum showed no AFB positivity. Contrast-enhanced computed tomography (CECT) abdomen showed decrease in the size of conglomerate mass. After 12 months of therapy, the lymph nodal mass had completely regressed.

A 60-year-old female presented to us with a history of laparoscopic cholecystectomy done 1 year back for gallstone disease, with chief complaints of fever for the last 2 months, pain abdomen for the last 2 months, loss of weight, and loss of appetite. On enquiry, she gave history discharge of purulent material from port site. Physical examination showed discharge from port site. Rest of the abdomen examination was normal. Laboratory investigations revealed hepatitis B surface antigen positive with hepatitis B virus DNA of 2.6×10000 IU/mL. Routine blood investigations with renal functions tests were normal. Liver function tests showed bilirubin—0.6, aspartate aminotransferase—35 IU/L, alanine aminotransferase—62 IU/L, and alkaline phosphatase—170 IU/L. Hepatitis B e-antigen was positive, while anti-Hbe antibody was negative. Blood cultures and port site pus culture were sterile. CECT abdomen showed increased

received

April 3, 2022

first decision

May 5, 2022

accepted

May 25, 2022

article published online

October 12, 2023

DOI <https://doi.org/>

10.1055/s-0042-1757400.

ISSN 2277-5862.

© 2023. Gastrointestinal Infection Society of India. All rights reserved.

This is an open access article published by Thieme under the terms of the Creative Commons Attribution-NonDerivative-NonCommercial-License, permitting copying and reproduction so long as the original work is given appropriate credit. Contents may not be used for commercial purposes, or adapted, remixed, transformed or built upon. (<https://creativecommons.org/licenses/by-nc-nd/4.0/>)

Thieme Medical and Scientific Publishers Pvt. Ltd., A-12, 2nd Floor, Sector 2, Noida-201301 UP, India

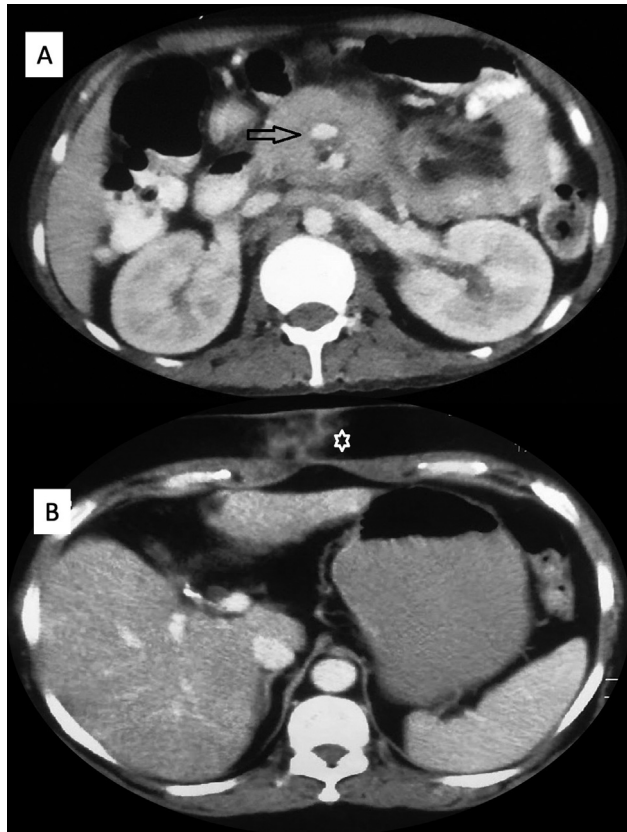


Fig. 1 (A) Computed tomography showing a lymph nodal mass encasing superior mesenteric artery (arrow). (B) Inflammatory changes at the port site (asterisk).

attenuation in subcutaneous plane at port site in epigastrium (→**Fig. 1B**). She was started on intravenous antibiotics; however, fever was persistent. Port site FNA showed ill formed symmetric granulomas; however, no AFB were seen. Port site polymerase chain reaction (PCR) was positive for MAC. She was started on clarithromycin, rifampicin, and ethambutol. On follow-up after 1 month, she was doing fine with improved appetite and had weight gain of 2 kg and resolution of cutaneous fistula. She completed 1 year of treatment and is now on tenofovir for her hepatitis B infection.

A 42-year-old male presented to us with complaints of pain abdomen for the last 3 months, fever for the last 2 months, loss of weight and appetite, and discharging sinus in the abdomen at the site of previous port placed for laparoscopic cholecystectomy. CECT abdomen showed soft tissue thickening in rectus abdominis in anterior abdominal wall. FNA of the lesion showed epithelioid granulomas and giant cells with caseation with the presence of AFB. He was started on four drugs antitubercular therapy (isoniazid, rifampin, pyrazinamide, and ethambutol). However, at 2 months follow-up, his condition worsened with further loss of weight and appetite. He underwent PCR from the mass that was positive for MAC and was initiated on MAC therapy.

He responded with weight gain at 1 month and improved appetite. Repeat imaging showed decreasing size of soft tissue lesion.

We report about these cases to highlight the diverse presentations and also bring to attention the risk of NTM infections after surgery. These organisms, being ubiquitous and also present in water, may infect the port site or postoperative sites if the sterilization practices are suboptimal and if tap water is used for the instruments.^{4,5} Interestingly one of our cases presented late (after one year of surgery). It is unclear if some indolent infection at the local site had been ignored. The present series highlights the need to consider NTM in clinical settings like immunocompromised conditions, postoperative infections, and lack of response to standard antitubercular therapy in patients thought to have tuberculosis.

Patient Consent

Written informed consent to publish was taken from the patients.

Ethical Statement

Not applicable.

Author's Contributions

All authors contributed equally to the article.

Data Availability Statement

There is no data associated with this work.

Funding

None.

Conflict of Interest

None declared.

Acknowledgments

None.

References

- 1 Rivero-Lezcano OM, González-Cortés C, Mirsaiedi M. The unexplained increase of nontuberculous mycobacteriosis. *Int J Mycobacteriol* 2019;8(01):1–6
- 2 Rahama O, Thaker H. Atypical mycobacteria: an important differential for the general physician. *Clin Med (Lond)* 2013;13(05):504–506
- 3 Daley CL, Iaccarino JM, Lange C, et al. Treatment of nontuberculous mycobacterial pulmonary disease: an official ATS/ERS/ESCMID/IDSA clinical practice guideline. *Clin Infect Dis* 2020;71(04):905–913
- 4 Ghosh R, Das S, De A, Kela H, Saha ML, Maiti PK. Port-site infections by nontuberculous mycobacterium: a retrospective clinico-microbiological study. *Int J Mycobacteriol* 2017;6(01):34–37
- 5 Lahiri KK, Jena J, Pannicker KK. Mycobacterium fortuitum infections in surgical wounds. *Med J Armed Forces India* 2009;65(01):91–92